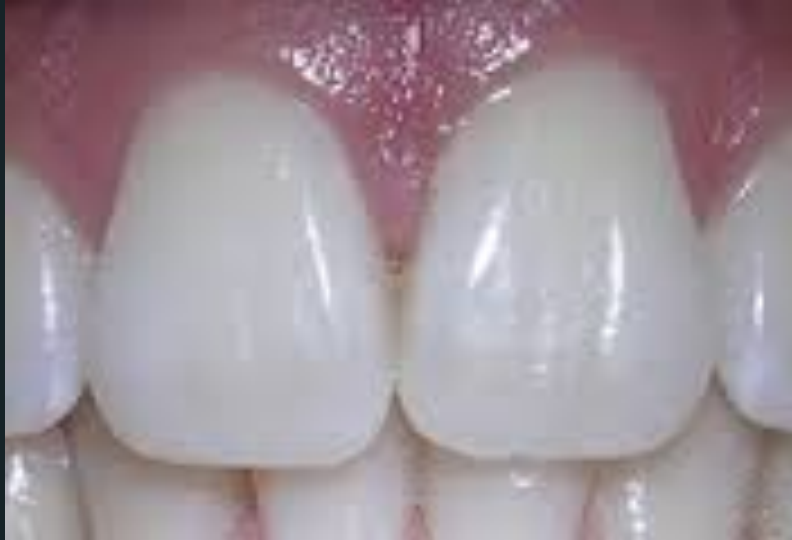



# Dental Anatomy

## Lecture 3

### Central Incisor

DR.Ahmed Al-Jobory  
B.D.S.,M.Sc. Conservative  
Department

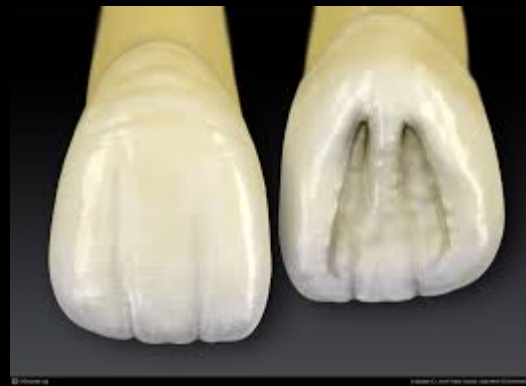

AHMAD  
AL JOBORY

## *The permanent maxillary Incisors*

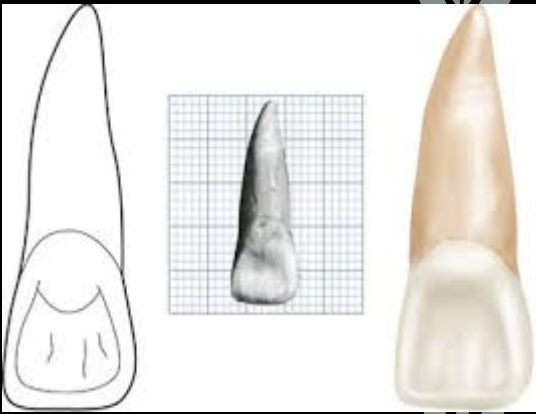
---

- Maxillary incisor are four in number. The maxillary central incisor is larger than the lateral incisor & they are similar anatomically, these teeth supplement each other in function, their major function is to punch & cut food material during the process of mastication.

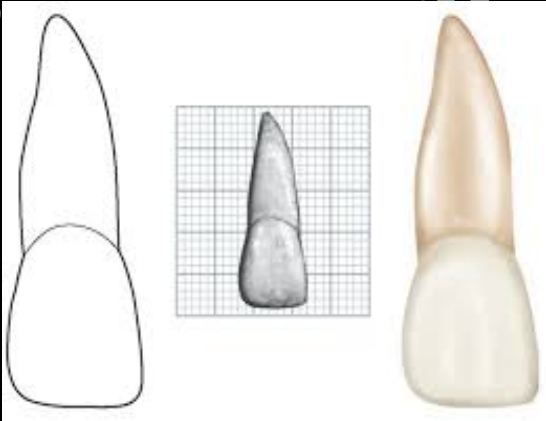


*Principal identifying  
features of maxillary  
central incisor*

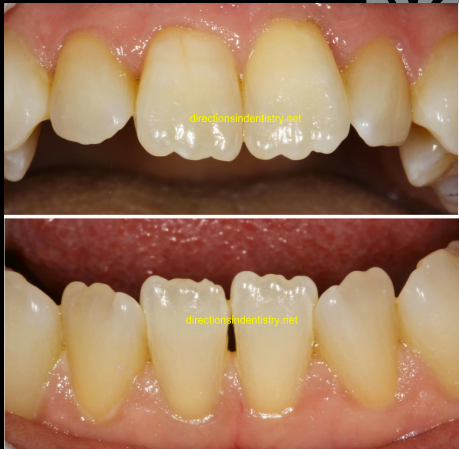



- 1) It is the widest anterior tooth mesio-distally.
- 2) It has a square or rectangular appearance.
- 3) Straight mesial outline and rounded distal outline.
- 4) Sharp mesio incisal angle and rounded distal incisal angle.



- 5) Mamelons on the incisal ridges (in newly erupted teeth)-( Presence of mamelons ).



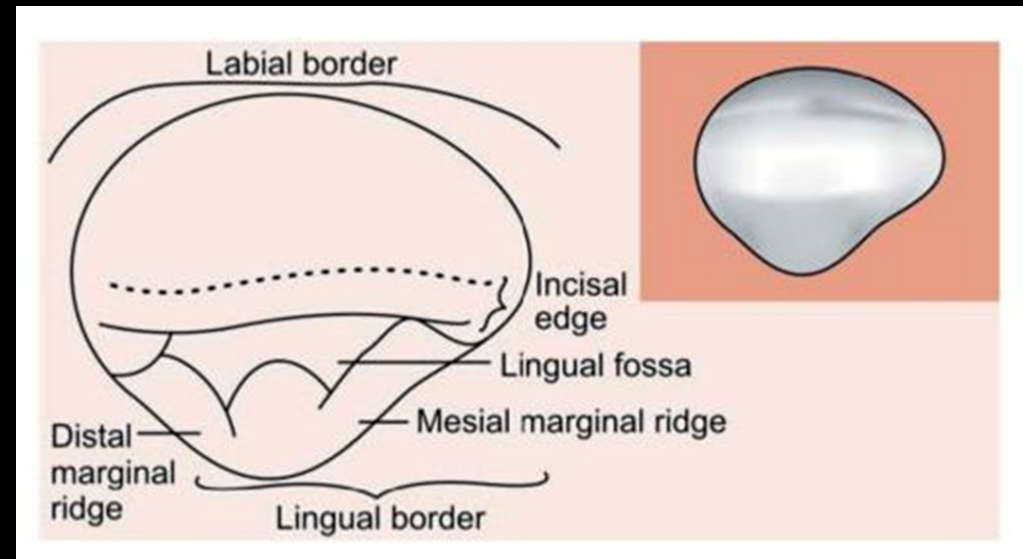
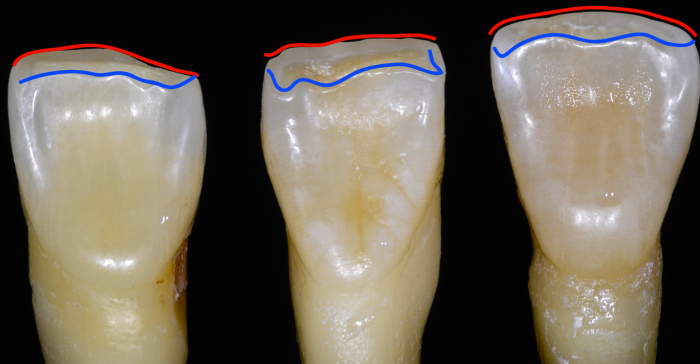- 6) Well marked marginal ridges, lingual fossa & well developed cingulum.
- 7) Single tapered root.
- 8) Cingulum.


*Characteristic features  
of Incisor crown*



**Incisal ridge**: is that portion of the crown, which makes up the complete incisal portion.

**Incisal edge** used when the occlusal wear creates flattened surface linguo-incisally and angle formed by linguo-incisal surface & labial surface.



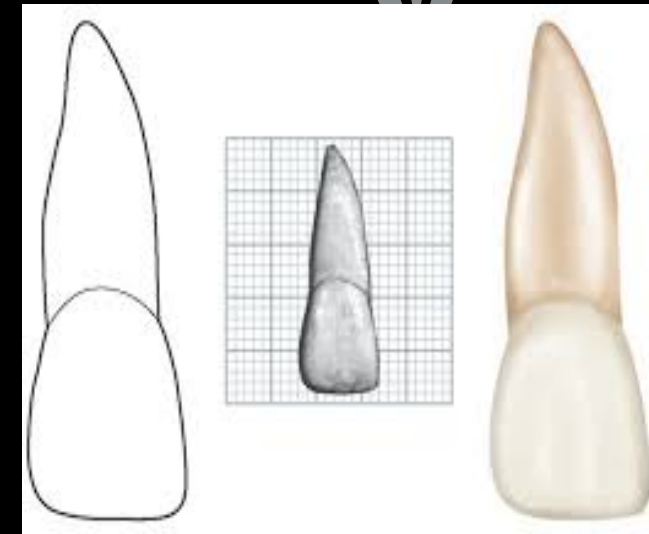
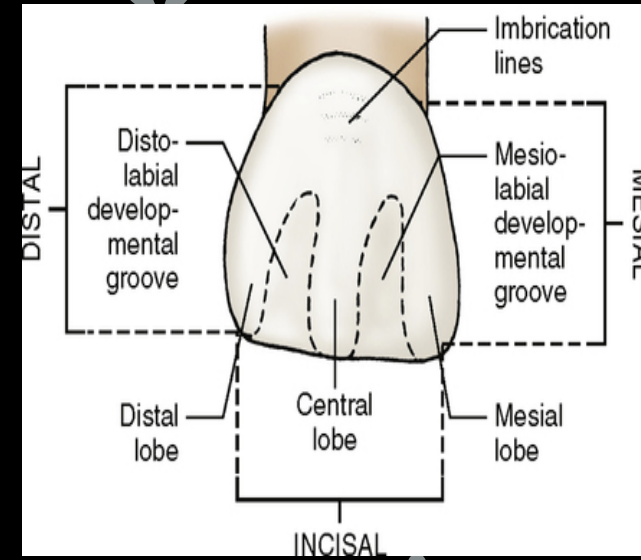


# THE LABIAL ASPECT



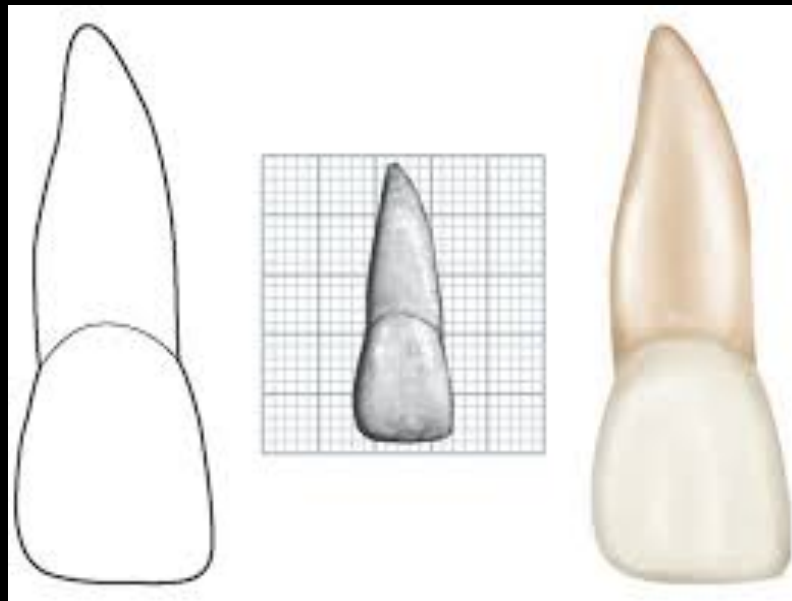
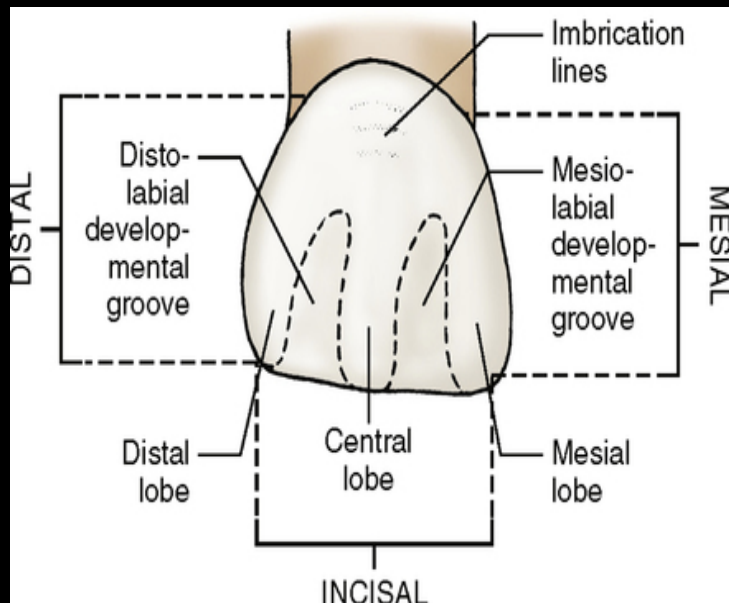



1. The mesial outline is slightly convex with a crest of curvature (representing the contact area) near the mesio-incisal angle.
2. The distal outline is more convex than mesial outline with crest of curvature being higher toward the cervical line of the junction between incisal and middle thirds.
3. The incisal outline is newly erupted teeth has elevations called mamelons, with age the mamelons will obliterated and straight incisal outline is seen.
4. The incisal outline tend to curve downward toward the center of the crown making the crown length greater at the center.





5. The cervical, outline of the crown follows a semicircular direction with the curvature directed towards the root.
6. The root is cone shaped with a blunt apex, It is 2-3mm longer than the crown.
7. A line drawn through the center of the root & crown tends to parallel the mesial outline of the crown & root.

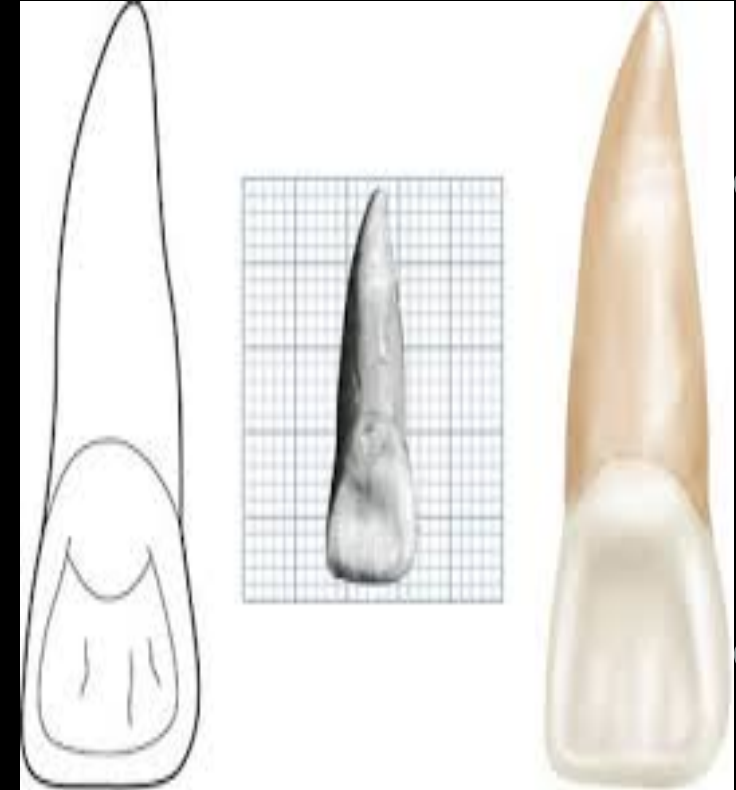




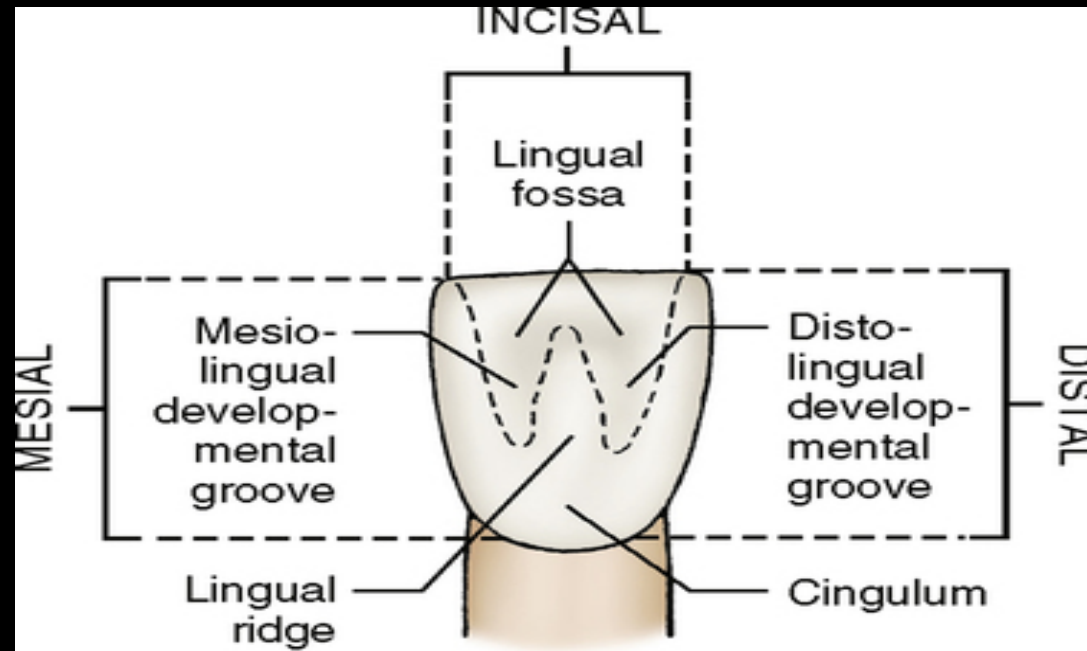
# THE LINGUAL ASPECT




- The lingual outline of the maxillary central incisor is the reverse of that found on the labial aspect .The lingual aspect of the crown has convexities & concavity.
- Below the cervical line, there is a smooth convexity called cingulum which confluent with raised marginal ridge mesially and distally.
- The crown & root taper lingually therefore mesio-distal dimension of the lingual surface is narrower than that of the labial surface
- Below the cingulum, a shallow concavity is present called the lingual fossa.



- The lingual fossa is bordered mesially by the mesial marginal ridge, distally by the distal marginal ridge, cervically by the cingulum, incisally by the lingual portion of the incisal ridge, usually there are developmental groove extending from the cingulum into the lingual fossa.

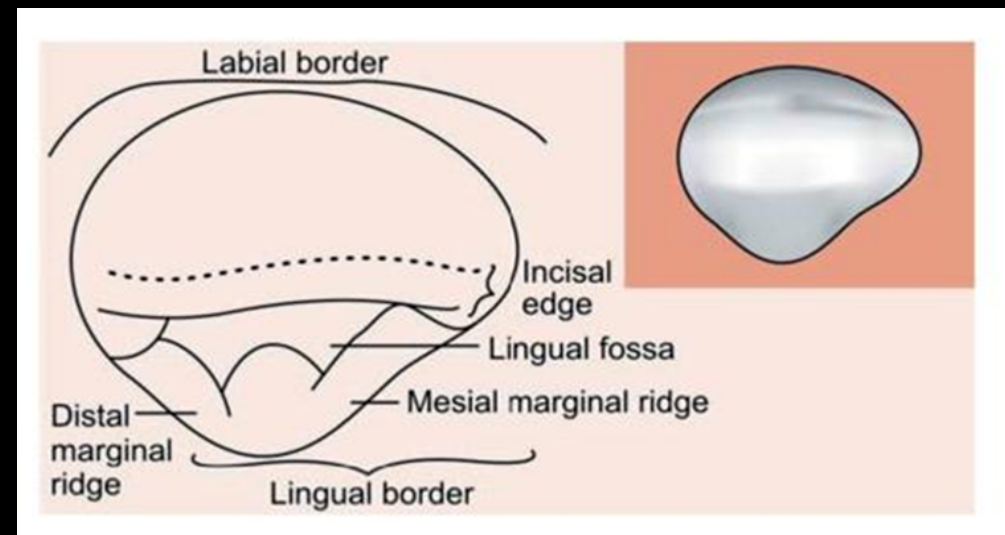





# THE INCISAL ASPECT



- The incisal edge is center over the root.
- The labial outline is broad & flat.
- The incisal edge & incisal ridge are well defined.
- The outline of the lingual part tapers lingually to the cingulum.
- The crown has triangular shape, as the root shape in cross section.
- The mesio-distal dimension labially is greater than that lingually.



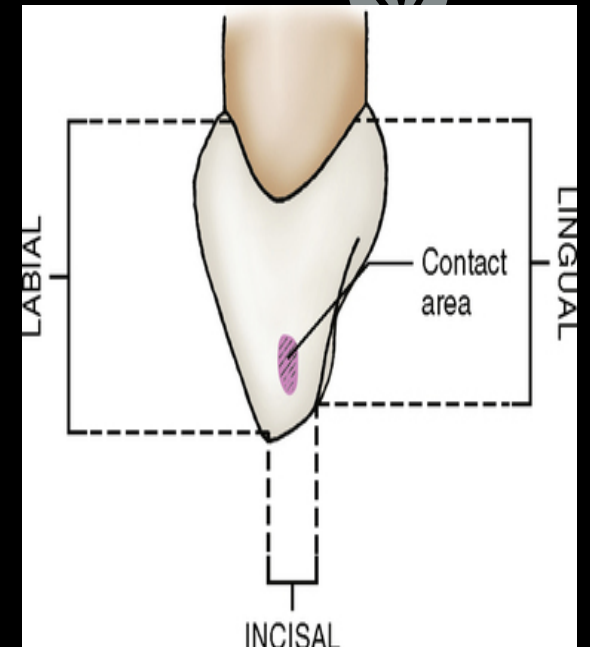


# THE MESIAL ASPECT

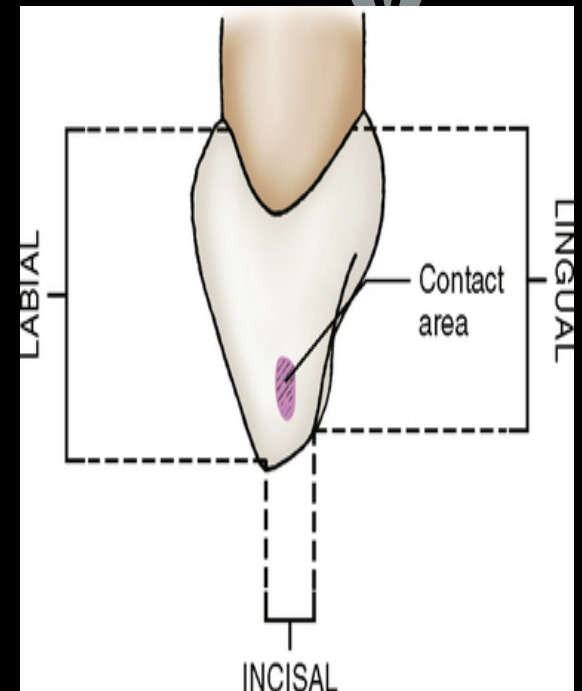





- The crown is wedge shaped or triangular with the base of the triangle at the cervix and the apex at the incisal ridge .
- A line which bisects the crown will bisect the root.
- The crest of curvature labially and lingually are immediately coronal to the cervical line, These crests of contour give the crown its greatest labio-lingual measurement.



- The labial outline of the crown from crest of curvature to the incisal ridge is very slightly convex.
- The lingual outline of the crown is convex at the cingulum then becomes concave at the mesial marginal ridge then slightly convex at the incisal ridge.
- The cervical outline curves incisally more than any surface on any tooth, about 3-4mm.

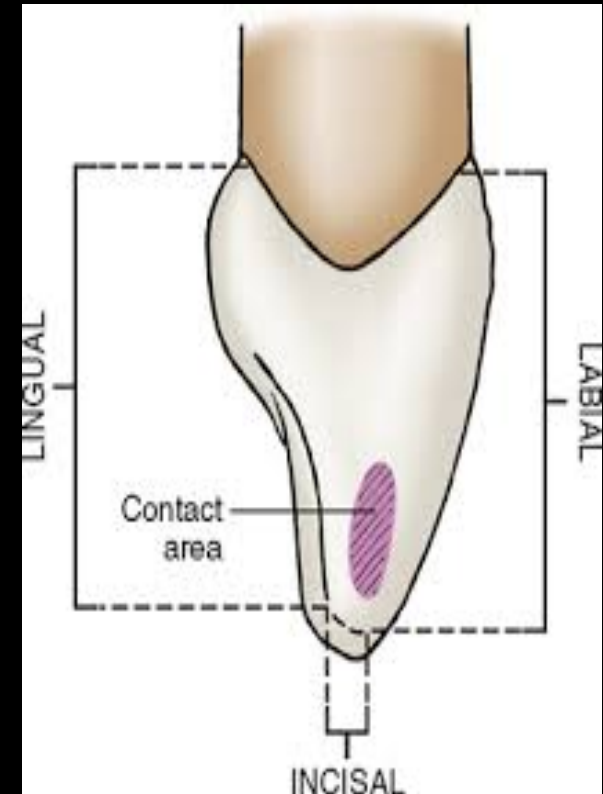




# THE DISTAL ASPECT



- There is little difference between mesial & distal outline .
- The curvature of the cervical line is less on extent distally than mesially.



הודות.  
Mh'gōi  
arigatō  
danke  
nandri  
takk  
grazie  
hvala  
gracias  
dziękuję  
dēkuji  
kiitos  
Xièxiè  
спасибо  
a dank  
ευχαριστώ  
mahalo  
tānan  
dank u  
gràcies  
tack  
köszönöm  
благодаря  
Thank you  
•  
Հնորհալալություն  
tak  
paldies  
ngiyabonga  
choukrane  
Dakujem  
Баярлалаа  
diolch  
blagodaram  
merci  
Дякую  
ačiū  
teşekkür ederim  
dhanyavād  
faleminderit  
dankie  
grazzi  
хвала  
muljamesic  
terima kasih