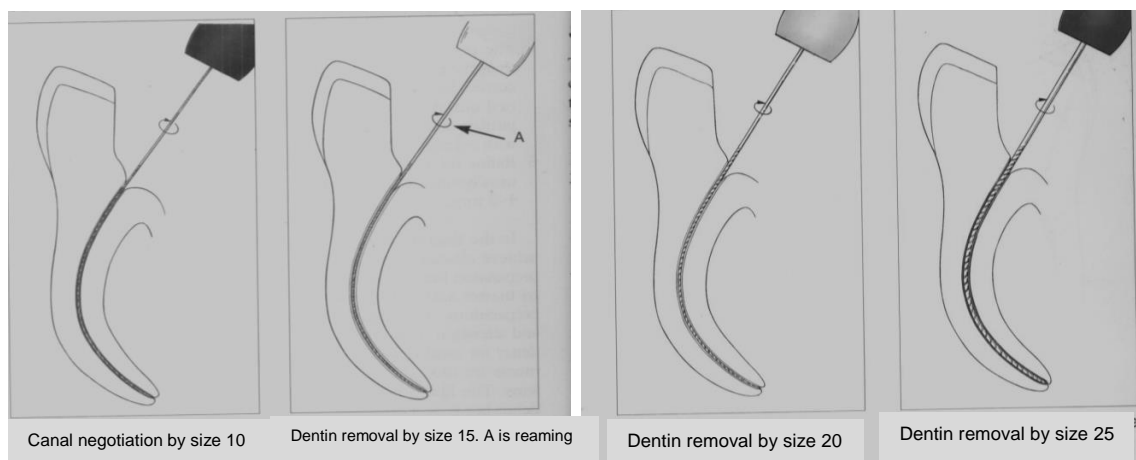


### Manual or Hand instrumentation techniques:

Several methods were developed for manual root canal preparation:

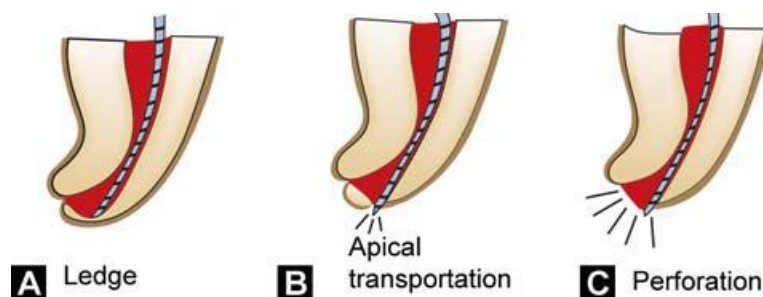
**1- Standardized technique:** (you can follow this link below to explore a video about this technique (<https://youtu.be/LpFsGISNBkl>)).

- This technique is developed by Ingle. The concept for this technique is by doing cleaning and shaping for the entire length of the canal at the same time by using the same working length (WL) definition for all instruments introduced into a root canal. Therefore, it relies on the inherent shape of the instruments to impart the final shape of the canal. It is also called 'single-length technique'.
- In the beginning the canal is irrigated, then negotiation of fine canals is initiated with lubricated fine files in a so-called watch-winding movement until reaching to full WL. In watch winding motion, a gentle clockwise and anticlockwise rotation of file with minimal apical pressure is given.
- Canal preparation then continues with reaming or quarter-turn-and-pull motions until a next large instrument reached.
- This technique will produce a canal shape or taper that resembles the tapering of the final instrument which is called the master apical file (MAF).
- Creation of a true standardized tapered preparation is difficult in ideal straight canals and impossible in curved canals.
- A single match gutta percha point may then be used for root canal filling with inadequate space to do lateral compaction of gutta percha in such small canal tapering (0.02).



### ***Disadvantages of Standardized technique:***

- 1- Chances of loss of working length due to accumulation of dentin debris.
- 2- Improper irrigation because of the minimal tapering of the canal.
- 3- Inadequate space for lateral compaction of the gutta percha which impairs good obturation.
- 4- Increased incidences of ledging, zipping and perforation in curved canals.
- 5- Because of the file is working on the entire canal space during instrumentation, this may increase the load on the file and the chance for its separation within the canal.



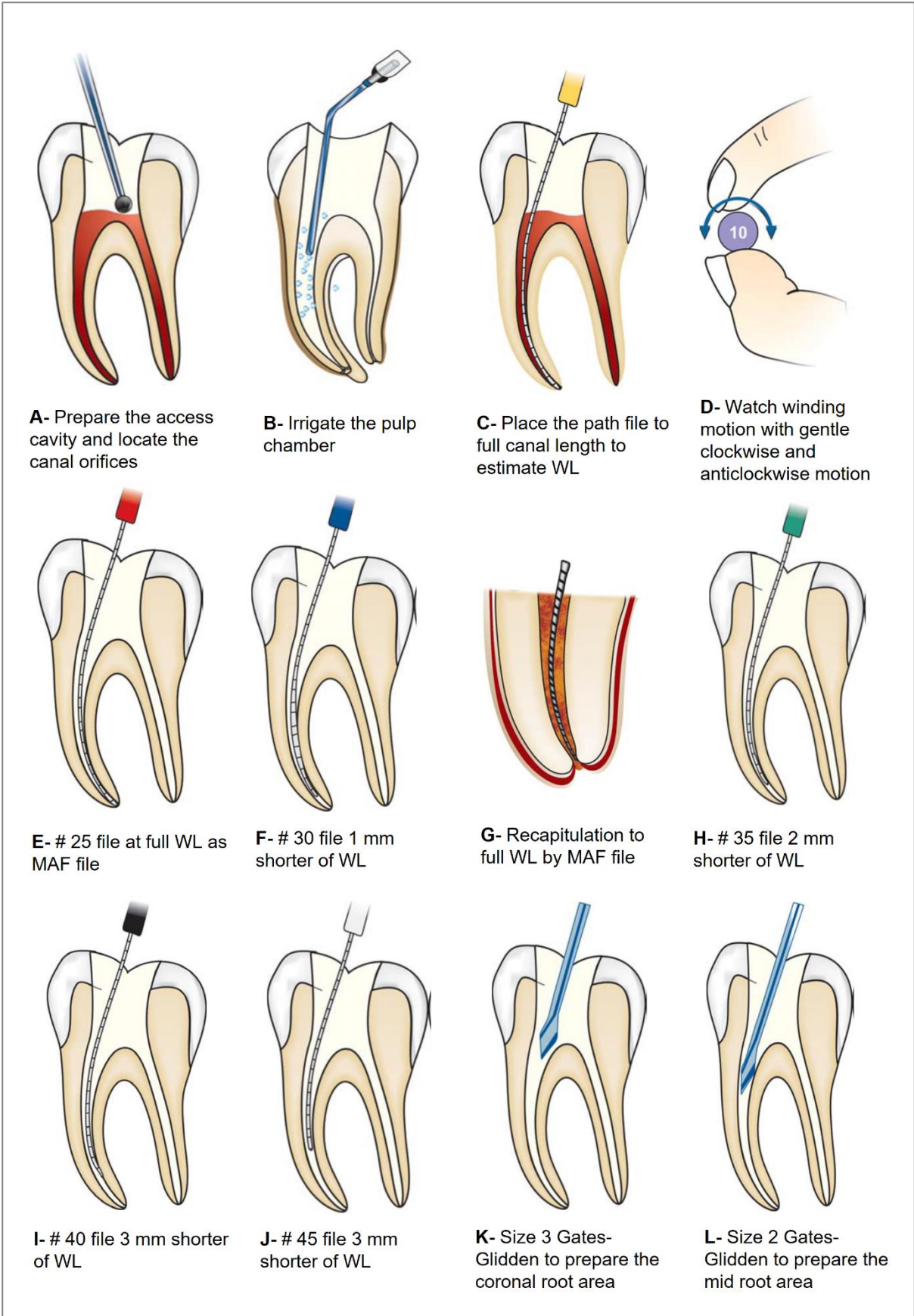
**Diagram represent procedural errors**

### **2- Step-back technique:**

Realizing the funnel shape of the canal and the coronal canal diameter is larger than that produced with the standardized approach, the step-back technique was introduced by Clem and Weine in 1960. This technique relies on stepwise reduction of WL for larger files, typically in 0.5 to 1mm steps, resulting in flared shapes with 0.05 and 0.10 mm tapering, respectively. The final result is a preparation with small apical enlargement and marked taper from apical to coronal. The wide, less flexible instruments are avoided in the preparation of the apical portion of the canal. This will lessen the forces by these instruments on the canal walls, which in turn preserve the original shape of the canal. Filling with gutta-percha is made easier because more room space will be available for spreader & plugger to penetrate more apically to get maximum compaction. The technique is as follow: (Also you can follow this link to watch a video about this technique: <https://youtu.be/PfkfiJ6oGIQ>)

- After access of the pulp chamber and opening of the canal orifices, flood the pulp chamber with irrigant (Fig A and B).

- Establish the working length of each canal using path file which could be file # 10 (Fig C).
- Insert the next size file (# 15) into the full WL of the canal with a gentle watch-winding motion (for watch-winding motion see Fig D). Then start acting the file on the canal walls either with filling or quarter-turn-and-pull motion until the file becomes loosely moved within the canal.
- Remove the instrument and irrigate the canal.
- Place the next larger size files to the working length in similar manner and again irrigate the canal, until a clean white dentin will appear on the file tip. This file is called the MAF which is the final instrument that goes to the full working length (Fig E).
- Don't forget to recapitulate the canal with the previous smaller size instrument. This breaks up apical debris to be easily washed away with the irrigant.
- Next use a larger file, i.e. one size larger than MAF into 0.5 to 1 mm shorter than WL (Fig F). Then recapitulate the canal with MAF to full WL of the canal (Fig G) with irrigation to remove apical debris and maintain the WL.
- This process can be repeated to 3 or more, larger files until a good flaring and cleaning of the canal is obtained (Fig H, I and J). Furthermore, flaring of the coronal third of the canal can be more enlarged by using Gates Glidden rotary drills to obtain better canal cleaning coronally (Fig K and L).



**Diagram represent step-back root canal instrumentation technique.**

**Advantages of step-back technique:**

More flaring of the canal at the coronal part with proper apical stop.

**Disadvantages of step-back technique:**

1. Difficult to irrigate apical region.
2. Alteration of the WL after canal flaring.
3. More chances of pushing debris periapically.
4. Time consuming.
5. Increased chances of iatrogenic errors for example ledge formation in curved canals.
6. Difficult to penetrate instruments in the canal.
7. More chances of instrument fracture.

**Step-down technique:**

This technique was developed to shape the coronal part (coronal pre-flaring) of the canal before instrumentation of the apical part.

The objectives of this technique is

- 1- To permit straight access to the apical region of the canal by eliminating coronal interference
- 2- To remove the bulk of necrotic tissue and microorganisms before apical shaping to minimize extruded debris through the apical foramen during instrumentation.
- 3- To allow deeper penetration of irrigant deeply into the apical part of the canal. In addition, it provide coronal escape way for debris extrusion from the apex.
- 4- The WL is less likely to change with less chance of zipping near the apical constriction.

**Procedure:** (you can follow this link to watch a video about this technique:

<https://youtu.be/uLAstzZeSc0>)

- Preparation of two coronal root canal thirds using Hedstrom files of size #15, #20, and #25 to 16 to 18 mm or where they bind. These files are used with circumferential filing motion on the canal walls.
- Thereafter, increasing the coronal flaring of the canal by using Gates-Glidden drills size 2, 3, and 4, in sequential order and 1mm shorter length between each file.

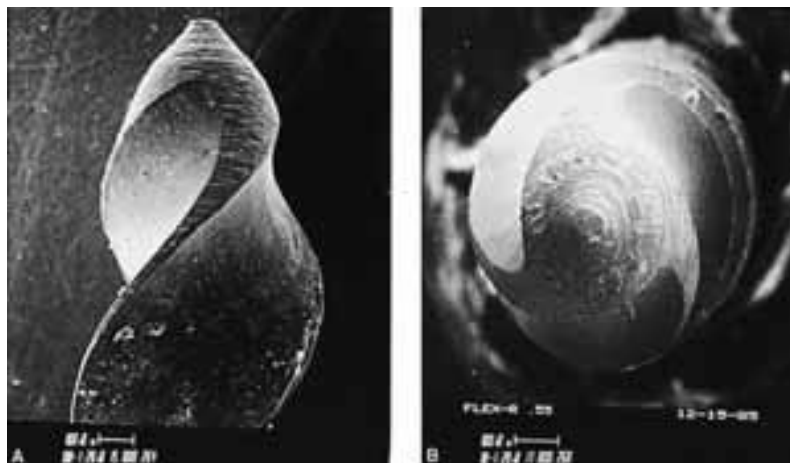
- Followed by canal WL estimation, then instrumentation of the remaining apical part of the canal. This includes using small K-file # 15, 20 and 25 to prepare the apical seat.
- Combining the two parts, step-down and apical shape, by stepwise decreasing of WL of incrementally larger files. Frequent recapitulation with a #25 K-file to WL is advised to prevent blockage.

***Disadvantages of step-down technique:***

It is only time consuming technique.

**Balanced force technique:**

This technique was introduced by Roane and Sabala in 1985, after the development of new file 'Flex-R file'. This file has "safe tip design" with a guiding land area behind the tip which allows the file to follow the canal curvature without binding in the outside wall of the curved canal. While the old K-type files have pyramidal tips with cutting angles which can be quite aggressive with clockwise rotation. This technique can be described as positioning of instrument with a counterclockwise rotation with apical pressure for shaping canal followed by preloading the instrument with canal debris through clockwise rotation then pulling.



**Fig shows Flex-R file with non-cutting tip.**

***Procedure:***

1. In balanced force technique, preparation is completed in a step-down approach. The coronal and mid-thirds of a canal are flared with GG drills, beginning with small sizes as described previously.

2- After that, the balanced force hand instrumentation begins in the apical preparation by placing, cutting, and removing instrument using only rotation motion. First file which binds short of working length is inserted into the canal and rotated clockwise a quarter of a turn. This movement causes flutes to engage a small amount of dentin.

3. Now file is rotated counterclockwise with apical pressure at least one third of a revolution. It is the counterclockwise rotation with apical pressure which actually provides the cutting action by shearing off small amount of dentin engaged during clockwise rotation.

4. Then a final clockwise rotation is given to the instrument which loads the flutes of file with loosened debris and the file is withdrawn.

5. Balanced Force instrumentation initiated from the belief that the apical area should be shaped to sizes larger than were generally practiced. The original Balanced Force concept then refers to apical control zones by, for example, first using sizes #15 and #20 files to the periodontal ligament (i.e., through the apical foramen) and then reducing the working depth by 0.5 mm for subsequent sizes #25, #30, and #35. The apical shape is then completed 1 mm short using sizes #40 and #45 under continuing irrigation with NaOCl.

#### ***Advantages of balanced force technique***

Lesser chances of creating a ledge, blockage or canal transportation.

#### **Crown-down (pressure-less) technique**

The crown-down instrumentation concept based on the canal shaping technique moving from the crown toward the apical portion of the canal. This concept was the introductory for the most recent rotary instrumentation technology.

***Procedure:*** (please follow this link to watch a video about the steps of this technique: [https://youtu.be/qfBYMA2\\_evQ](https://youtu.be/qfBYMA2_evQ))

1. After preparing the access opening and locating the canal, flood the pulp chamber with irrigation solution and start pre-flaring of the canal orifices. This can be done by using hand instruments, Gates-Glidden drills or the nickle-titanium rotary instruments. After that a glide-path for each canal have to be obtained from the canal orifice till the apical foramen by using # 10 or 15 file.

2. Coronal preparation of the canal can be started with Gates-Glidden drills. The crown down approach begins with larger Gates-Glidden first (Fig A) (size 4 or 5), followed by smaller diameter Gates-Gliddens are worked into the canal with additional mm to complete coronal flaring. A care should be taken to avoid carrying all the Gates-Glidden drills to same level which may lead to excessive cutting of the dentin.
3. Frequent irrigation with sodium hypochlorite and recapitulation with a smaller file (usually No. 10 file) to prevent canal blockage.
4. After establishing coronal and mid root enlargement, explore the canal and establish the working length with small instruments (# 10 or 15 file) (Fig B).
5. Introduce larger files to coronal part of the canal and prepare it (Fig C and D). Subsequently introduce progressively smaller number files deeper into the canal in sequential order and prepare the apical part of the canal (Fig E).
6. Final apical preparation is prepared and finished along with frequent irrigation of the canal system.



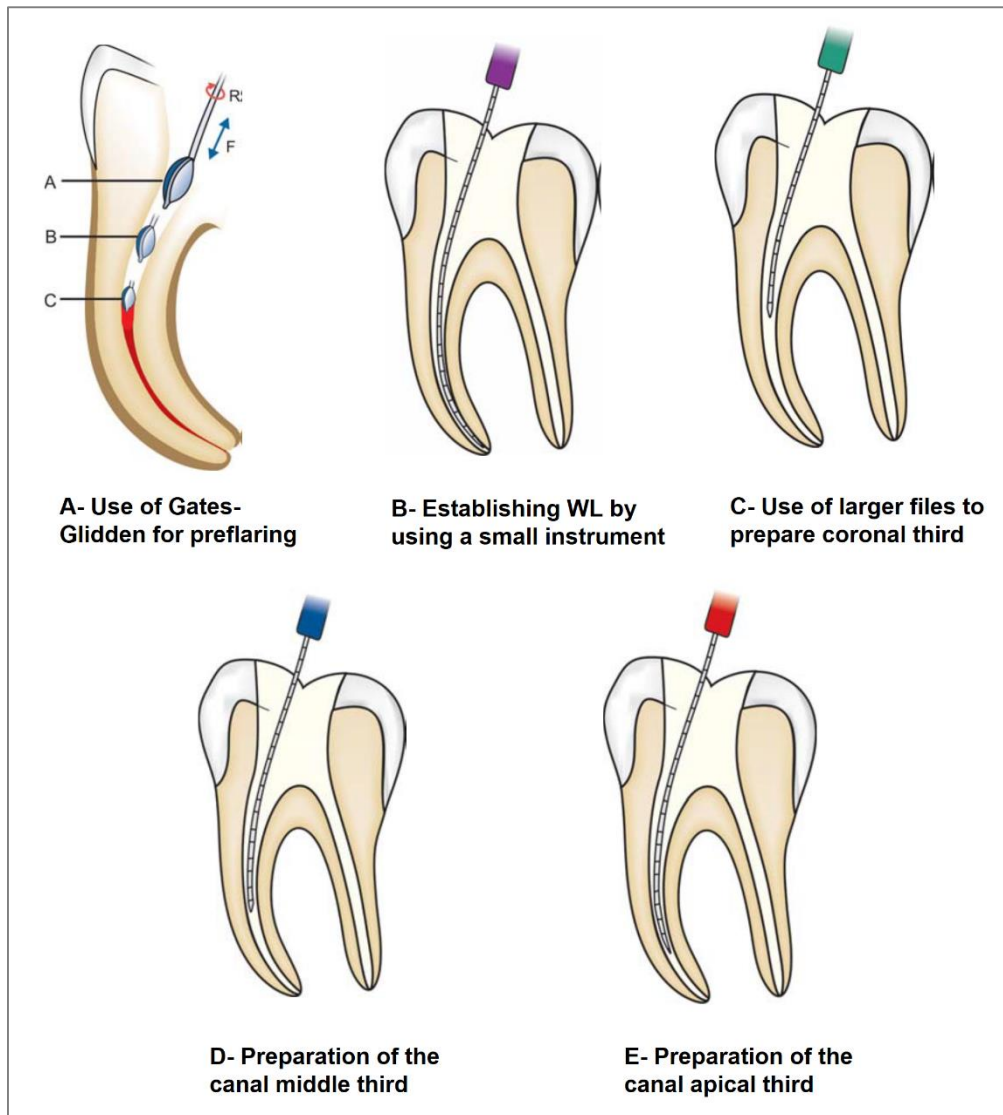


Diagram presenting Crown down (pressure-less) technique

***Biological Advantages of crown down technique:***

1. Removal of tissue debris coronally, thus minimizing the extrusion of debris periapically.
2. Reduction of postoperative sensitivity which could result from periapical extrusion of debris.
3. Greater volumes of irrigants can reach in canal irregularities in early stages of canal preparation because of coronal flaring.
4. Better dissolution of tissue with increased penetration of the irrigants.

***Clinical advantages of crown down technique:***

1. Enhanced tactile sensation with instruments because of removal of coronal interferences.
2. Flexible (smaller) files are used in apical portion of the canal; whereas larger (stiffer) files need not be forced but kept short of the apex. This decrease the chance for canal ledging, transportation and perforation.
3. Straight line access to root curves and canal junctions.
4. Provides more space for irrigants.
5. Enhance canal debridement and decrease frequency of canal blockages.
6. Desired shape of canal can be obtained that is narrow apically and wider coronally. This provides better room for gatta percha compaction to obtain proper three dimensional obturation of the root canal.

## Root Canal Irrigation

- Studies have shown that mechanical instrumentation, whether using manual or rotary instruments, can not sufficiently debride and disinfect root canals.
- Every root canal system has spaces that cannot be cleaned mechanically.
- The only way for cleaning webs, fins and anastomoses is through the effective using of irrigation solutions (See Fig 1).

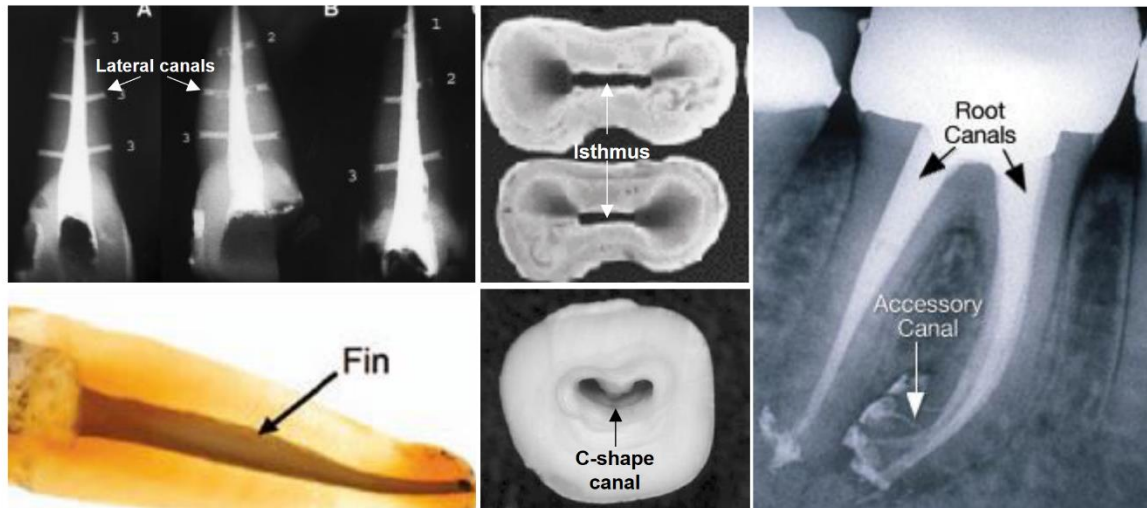


Figure 1: Variations in root canal anatomy

### Requirements of ideal irrigant solution:

- 1- Have a broad spectrum antimicrobial activity.
- 2- Be able to effectively sterile the canal (or at least disinfect them).
- 3- Have the ability to dissolve necrotic tissue and debride the canal.
- 4- Lubricant solution.
- 5- Low level of toxicity.
- 6- Have low surface tension to be able to penetrate into inaccessible areas.
- 7- Prevent the formation of smear layer during or after instrumentation.
- 8- Inhibiting bacterial toxins such as endotoxin.

## **Functions of irrigants**

- 1- Removal of dentinal shavings by physical flushing to prevent their packing at the apical region of the root canal.
- 2- Canal wetting material which effectively increase the efficacy of root canal instruments. Instruments are less likely to break when the canal walls are lubricated by irrigant.
- 3- Irrigants act as a solvent for necrotic tissue, so they loosen debris, pulp tissue and microorganisms from irregular dentinal walls.
- 4- Irrigants facilitate the removal of debris from inaccessible regions of root canals.
- 5- Most irrigants have germicidal and antibacterial properties.
- 6- Irrigants also have bleaching action to lighten teeth discolored by necrotic pulp tissue, caries or restorative material.
- 7- Irrigants facilitate the removal of smear layer and opening of the dentinal tubules.

## **Factors that modifying the activity of irrigating solution**

There are several factors that can be controlled to increase the efficacy of irrigant solutions:

- 1- Concentration: the dissolving capacity of some irrigation solution, such as sodium hypochlorite, can be increased with higher concentration (5.2 rather than 2.5%). However the cytotoxicity of higher concentrations is extremely higher.
- 2- Contact: the irrigant must contact the intracanal substrate (organic tissue, or microbes) to be effective, otherwise it won't be able to dissolve or flushout the debris. Therefore, it is critical that the canal diameter should be mechanically enlarged to facilitate the delivery of the irrigant solution up to the apical region of the prepared canal.
- 3- Presence of organic tissue: the organic tissue must be removed mechanically or chemomechanically to increase the efficacy of intracanal irrigation. This can be obtained by simultaneous use of instruments and irrigating solutions.
- 4- Quantity and frequency of the irrigant used:
  - More irrigation causes better tissue debridement.
  - Each time a flush of fresh potent irrigant plays an action.
- 5- Gauge of irrigating needle: usually the 27 or 28 irrigation needle is preferable for better penetration into the canal.

6- Surface tension of irrigation solution: the lower surface tension, the better wettability and the more penetration into narrowest areas of the canals, and even into the dentinal tubules.

7- Level of penetration of the irrigant: Maximum actions of irrigant occurs on coronal part of root canal whereas minimal on apical end.

8- Age of irrigant: Freshly prepared solution is more effective than older one.

### **Irrigant solutions:**

There are several irrigation solution that are currently used in root canal chemomechanical debridement nowadays (See Figure 2). But none of these irrigants fulfil all the required criteria. The main irrigants include sodium hypochlorite, chlorhexidine and ethylene diamine tetraacetic acid. A combination of several irrigants can be used to get maximum action.

Some of the commonly used irrigation solutions

#### *Chemically non-active solution*

- Water
- Saline
- Local anesthetic

#### *Chemically active materials:*

- Alkalis: Sodium hypochlorite 0.5-5.25 percent
- Chelating agents: Ethylene diamine tetra acetic acid (EDTA)
- Oxidizing agents: Hydrogen peroxide, carbamide peroxide
- Antibacterial agents: Chlorhexidine, Bisdequalinium acetate
- Acids: 30 percent hydrochloric acid
- Enzymes: Streptokinase, papain, trypsin
- Detergents: Sodium lauryl sulfate

**Figure 2: A list of the currently used irrigant in root canal treatment.**

### ***Normal saline:***

Normal saline as 0.9% W/V is commonly used irrigant in endodontics. It is very mild in action and can be used in adjunct to chemical irrigant. It causes gross debridement and lubrication of the root canal. Normal saline basically acts in flushing action. It can also be used as a final rinse for root canals to remove the chemical irrigant left after root canal preparation.

*Advantages:* it is a biocompatible solution with no adverse effect even if extruded periapically, because its osmotic pressure is the same as that of the blood.

*Disadvantages:*

- It has no dissolution, disinfectant and antimicrobial properties.
- Too mild to thoroughly clean the canal.
- Does not remove smear layer.

***Sodium hypochlorite (NaOCl):***

NaOCl encompasses many desirable properties of the main root canal irrigant and has therefore been described as the most ideal irrigant solution. It can be used with different concentrations (0.5 to 6%) but the recommended concentration in many studies is 5.25%. Commercially available household bleach (Clorox) contains 6.15% NaOCl.

- NaOCl dissolve organic material such as pulp tissue, collagen, organic material in smear layer and bacteria. With lower concentrations (0.5%) it dissolve only necrotic tissue, however in higher concentrations dissolve both necrotic and vital which is not always a desirable property.
- NaOCl possess a broad-spectrum antimicrobial activity against endodontic microorganisms and biofilms, including microbiota difficult to eradicate from root canals, such as *Enterococcus*, *Actinomyces*, and *Candida* organisms. This depends on its concentration and the contact time. With higher concentration and longer contact time its antimicrobial action increase.
- NaOCl minimally remove dentin debris or smear layer. Therefore, the use dentin demineralizing agent (EDTA) is recommended post instrumentation to eliminate smear layer and enhance cleaning of difficult-to-reach areas such as dentinal tubules and lateral canals.
- When using NaOCl over extended periods of time during treatment, it has an undesired side effect by decreasing the flexural strength and modulus of elasticity of dentin. Therefore it has to be flushed out by using normal saline after the end of instrumentation visit.
- NaOCl also has bleaching action by the function of the hypochlorite ions which is important in whitening the discolouration caused by pulp necrosis or endodontic and restorative material such as some endodontic sealers, and amalgam restoration. However, NaOCl cause bleaching in contact with clothes, so cautions have to be taken during its use.

- Although NaOCl is nontoxic during intracanal use, it could cause serious tissue damage if it injected periapically especially with higher concentration. This is associated with severe pain, swelling and periapical bleeding. Medication like antibiotics, analgesics, antihistamine should be prescribed accordingly. In addition to these, reassurance to the patient is the prime consideration. Thus irrigation with NaOCl should always be performed passively especially in cases with larger apical diameters and needles with very small diameter.

*Advantages of NaOCl:*

- 1- It has antibacterial and bleaching action.
- 2- It help in canal debridement by dissolution of the organic debris.
- 3- It cause lubrication of canals
- 4- Economical.
- 5- Easily available.

*Disadvantages:*

- 1- Because of high surface tension, its ability to wet dentin is less.
- 2- Irritant to tissues, if extruded periapically, it can result in severe cellular damage.
- 3- If comes in contact, it cause inflammation of gingiva because of its caustic nature.
- 4- It causes clothes bleaching in contact.
- 5- It has bad odor and taste
- 6- Vapours of NaOCl can irritate the eyes.
- 7- It has a corrosive effect to instruments.

**References:**

- 1- Garg N., Garg A. Textbook of Endodontics. Jaypee Brother Medical Publisher (P) LTD. 2<sup>nd</sup> Edition, 2010.
- 2- Hargreaves K M., Cohen S., Berman L H., Cohen's Pathways of the Pulp. Mosby. 10<sup>th</sup> Edition, 2011.
- 3- Hülsmann M., Peters O A., Dummer P MH. Mechanical preparation of root canals: shaping goals, techniques and means. Endodontic Topics. 2005; 10 (1): 30-76.

- 4- Ingle J I., Bakland L K., Baumgartner J C., Ingle's ENdodontics 6. BC Decker Inc Hamilton. 6<sup>th</sup> Edition, 2008.
- 5- Ruddle C J. Endodontic Access Preparation The Tool for Success. Just in Time Online Education, Dental Products Report. 2007: 1-9.
- 6- Vertucci F J., Fla G., Root Canal Anatomy of the Human Permanent Teeth. Oral surgery, oral medicine, oral pathology. 1984; 85 (5): 589-599.
- 7- West J., Endodontic Update 2006. Journal of Esthetic and Restorative Dentistry. 2006; 18 (5): 280- 300.



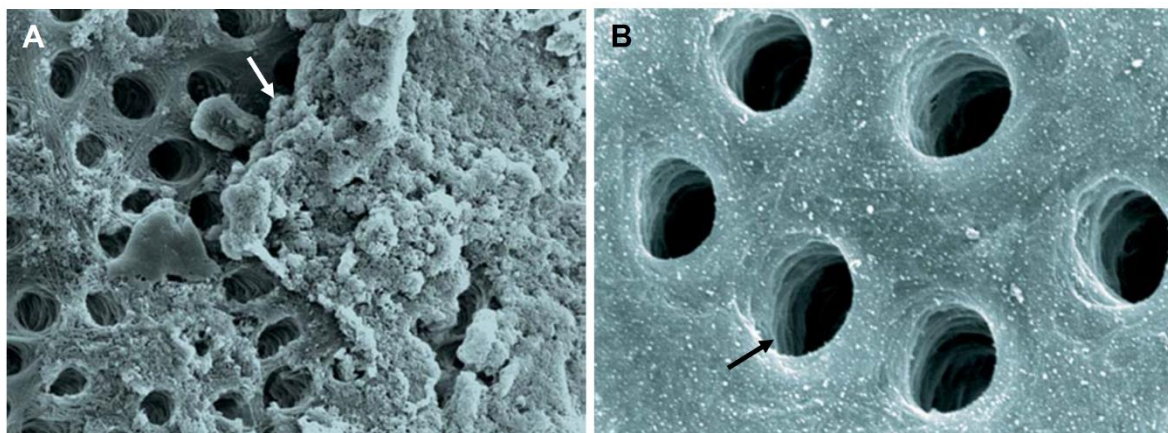


### Continue with irrigation Lec.

#### ***Chelating agent:***

After root canal instrumentation, a layer of cutting remnants will cover the dentinal tubules which contain both organic and inorganic materials. This layer is called the smear layer (Fig 1). A big controversy still exist whether to remove or maintain the smear layer which may affect permeability of dentin and root canal treatment.

However, most of studies have recommended the removal of this layer because it is the source of microorganism. Also its removal increase the adaptation and adhesiveness of root filling materials.



**Figure 1: (A) shows smear layer blocking dentinal tubules. (B) shows opening of dentinal tubules after using EDTA.**

EDTA (ethylenediaminetetraacetic acid) is the most commonly used chelating agent, which composed of 4 acetic acid groups attached to ethylenediamine. These acetic acid groups create stable calcium complexes with dentin, smear layer or calcific deposits along canal walls. This will aid in dissolving these calcific debris for easily flushing-out the root canal. The effect of EDTA on dentin depends on its concentration and the contact time. With higher concentration and longer contact time its action is increase. Studies recommended 17% concentration with neutral pH for better decalcification results.

#### *The functions and uses of EDTA:*

- 1- Lubrication for easily manipulating instruments.
- 2- Emulsification and dentin dissolving properties which reduce canal debridement time.
- 3- It helps in enlarging narrow canals.



4- Smear layer removal for better adhesion and dentinal tubules penetration of root filling material.

***Chlorhexidine:***

It is a broad spectrum antimicrobial agent and its activity is related to the cationic molecular structure, which can be absorbed by the anionic bacterial cell membrane and causes leakage of intracellular components. At low concentration chlorhexidine acts as a bacteriostatic, whereas at higher concentrations it causes coagulation and precipitation of cytoplasm therefore acts as bactericidal. Although the 0.2% chlorhexidine concentration is used in mouth washes for controlling plaque, the recommended concentration as a root canal irrigation is 2% for better results.

***Disadvantages:***

- 1- It is not considered as the main irrigant in standard endodontic therapy.
- 2- It is unable to dissolve necrotic tissue remnants.
- 3- It is less effective on gram-negative than on gram-positive bacteria.

**Methods of irrigation**

There are different methods available in delivering and activating the irrigants within root canal:

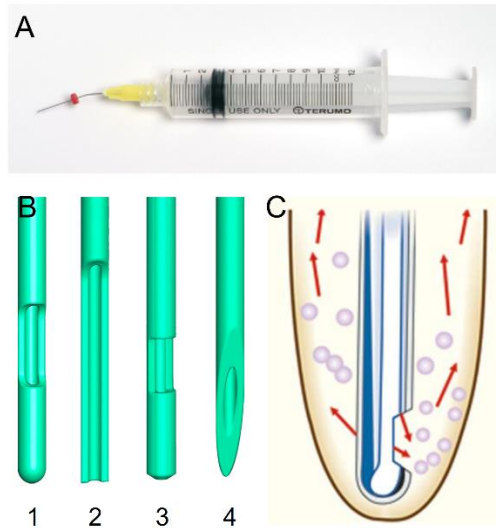
***Irrigation syringe and needle:***

Plastic syringe of different sizes (1-20ml) are used for irrigation (Fig 2 A). The preferable sizes is between 1- 5ml to maximize safety and control instead of larger syringes which required more pressure.

Although needle gauge 27 is the recommended size in many research, there are also smaller sizes available nowadays (30 and 31 gauge). The 27-G is corresponding to size 0.42mm and 30-G to size 0.31. Also several modifications of the needle tip design have been introduced (Fig 2 B), such as rounded tips and side holes to facilitate moving irrigant sideways in the canal rather than pushing the irrigant apically to reduce side effects (Fig 2 C).

***Disadvantages:*** the irrigant solutions cannot be pushed beyond the tip of the irrigation needle (Fig 2 C) because of the dead-water zone or air bubbles trapping in the apical canal region.

Figure 2: (A) Irrigation syringe, (B) different needle tip designs (1-3) compared to conventional hypodermic needle (4). (C) flow of irrigation fluid no further than the irrigation needle.



### **Ultrasonic**

The use of ultrasonic energy for oscillating file with the present of irrigant have been shown to clean root canal better than conventional hand instrumentation. The ultrasonically oscillated file cause an energy which passes to the irrigant solution and exert 'acoustic streaming or scrubbing' effect on the canal walls. This mechanical energy dislodge the debris and smear layer from the canal walls.

#### **Disadvantages:**

- 1- Ultrasonic preparation of the canal is found to be unpredictable.
- 2- It can lead to excessive cutting of canal walls and may damage the finished preparation.

### **Sonic:**

The irrigation solution also can be activated sonically to create kinetic energy which could facilitate debridement of the root canal. EndoActivator (Fig 3) is one of these irrigation facilitator methods. It is based on sonic vibration (up to 10,000 cpm) of a plastic tip in the root canal after delivery of the irrigant by using irrigation syringe.

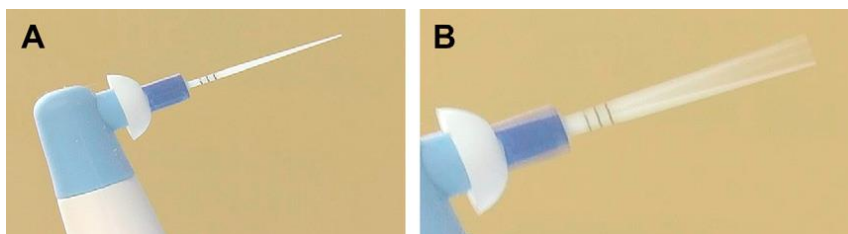


Figure 3: (A) EndoActivator with plastic tip. (B) Sonic motion of the plastic tip.



## Obturation of root canal system

- After chemo-mechanical debridement of root canal system by instrumentation and irrigation, the next step is complete (3 dimensional) obturation of root canal space to maintain the tooth functional within the dental arch.
- The remaining non-vital pulp within incompletely debrided root canal will undergo autolysis and the disintegrated by products will diffuse into the surrounding tissue.
- The fundamental aim of obturation is to provide 3 dimensional hermetic seal of root canal space to prevent the leakage from or into root canal system.
- The obturation method include the use of a solid or semisolid core material (gutta percha) surrounding by a sealer type of material to produce the fluid tight seal, by filling the main root canal(s), the accessory canals, voids, spaces and irregularities.

### Aims of root canal obturation:

- 1- The achievement of 3 dimensional obliteration of the root canal space to prevent ingress of bacteria and body fluids into root canal space, as well as egress of bacteria or their toxins out of the root canal.
- 2- To provide fluid tight seal within all regions of root canal space to prevent microleakage.
- 3- The replacement of the root canal space filled with necrotic tissue by an inert filling material to create a favourable healing environment and avoid recurrent infection.
- 4- To provide adequate coronal seal with proper coronal restoration to obtain long term success of root canal therapy.

### Timing of obturation:

Several factors should be checked before doing obturation:

- 1- Patient symptoms: the sensitivity to percussion indicative that the inflammation of the periapical periodontal ligament is present. Therefore the obturation has to be postponed until the inflammation subside. In cases of irreversible pulpitis with no tenderness to percussion present, the root canal treatment can be completed in a single visit as soon as the cause of the pain and inflammation has been removed.



- 2- Canal wettability: presence of wet canal with purulent exudate, blood or pus is a strong evidence that the periradicular inflammation is still present. Obturation of the root canal at this stage increase the pressure within periradicular region and subsequent tissue destruction may proceed rapidly. Therefore, in cases of active periradicular infection, delaying obturation until all signs and symptoms of inflammation have to be subside is extremely recommended.
- 3- Negative culture: most of the endodontist do not relay on this test because researches have approved that the false negative results inaccurately assess the intracanal microbial flora. Furthermore, the positive results is not an indicative for the potential bacterial pathogenicity.

**Features of an ideal root canal obturation:**

- 1- Complete 3 dimensional obturation from the coronal orifice of the root canal until CDJ.
- 2- Radiographically, the root filling should be within 0.5- 0.75 mm from radiographical apex.
- 3- The root canal should be completely filled, mainly with root filling material with a minimum amount of sealer.

**Underfilling:** occur when the root canal filling is shorter that total root canal space (See figure 4 A). This definitely provide an environment for initiation, persistence or recurrence of periradicular infection.

**Overfilling:** occur when the root filling material extended beyond the CDJ (See figure 4 B). According to Ng et al. 2007<sup>1</sup> the extrusion of root canal filling is considered to be acceptable within 2mm beyond (longer than) the radiographical apex, if it is associated with 3 dimensional sealing of root canal system.

---

<sup>1</sup> Ng Y-L, Mann V, Rahbaran S, Lewsey J, Gulabivala K. Outcome of primary root canal treatment: systematic review of the literature – Part 2. Influence of clinical factors. Int Endod J, 41, 6–31, 2008.

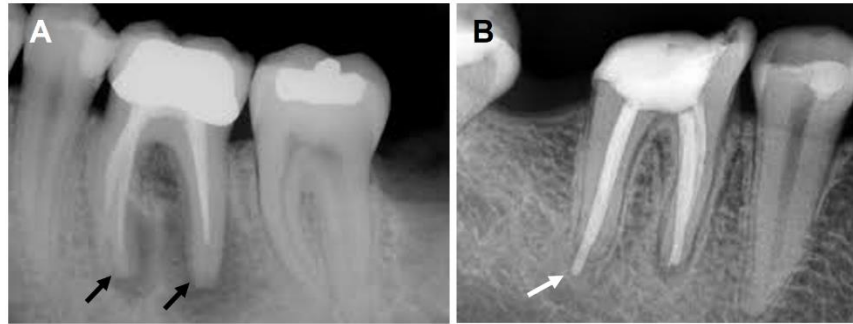


Figure 4: Underfilling (A) and overfilling (B) of root canal treatment.

### Characteristics of an ideal root filling material:

- 1- Easily introduced in the root canal.
- 2- Provide an apical and lateral sealing of the root canal.
- 3- Dimensionally stable after usage.
- 4- Impervious to moisture.
- 5- Bacteriostatic or at least should not encourage bacterial growth.
- 6- Radiopaque.
- 7- Non staining to tooth structure.
- 8- Non irritating
- 9- Sterile or easily sterilized.
- 10- Removed easily from canal if required.

#### Materials used for obturation

- Plastics: Gutta-percha, resilon
- Solids or metal cores: Silver points, Gold, stainless steel, titanium and irridio-platinum.
- Cements and pastes:
  - Hydron
  - MTA
  - Calcium phosphate
  - Gutta flow

### Gutta percha

Gutta percha is a natural material extracted as a dried coagulated from a Brazilian trees (Palaquium). Its molecular structure is close to natural rubber. Chemically gutta percha is available into two crystalline forms: alpha ( $\alpha$ ) and beta ( $\beta$ ).



The most commercially available product is in  $\beta$ -form which composed of the following:

Organic content: gutta percha 20% + waxes and resins 3%

Inorganic: zinc oxide filler 66% + heavy metal sulfates as radioopacifiers 11%

### **Forms of Gutta percha:**

Gutta percha available in different forms. The  $\beta$ -form is produced as gutta percha points (cones) which is available in different sizes and tapering as follow:

- 1- Standard cones of the same size and shape of the ISO endodontic instruments.
- 2- Greater taper gutta percha points: available with taper 4%, 6%, 8% and 10%.
- 3- Auxiliary points: non-standard cones.

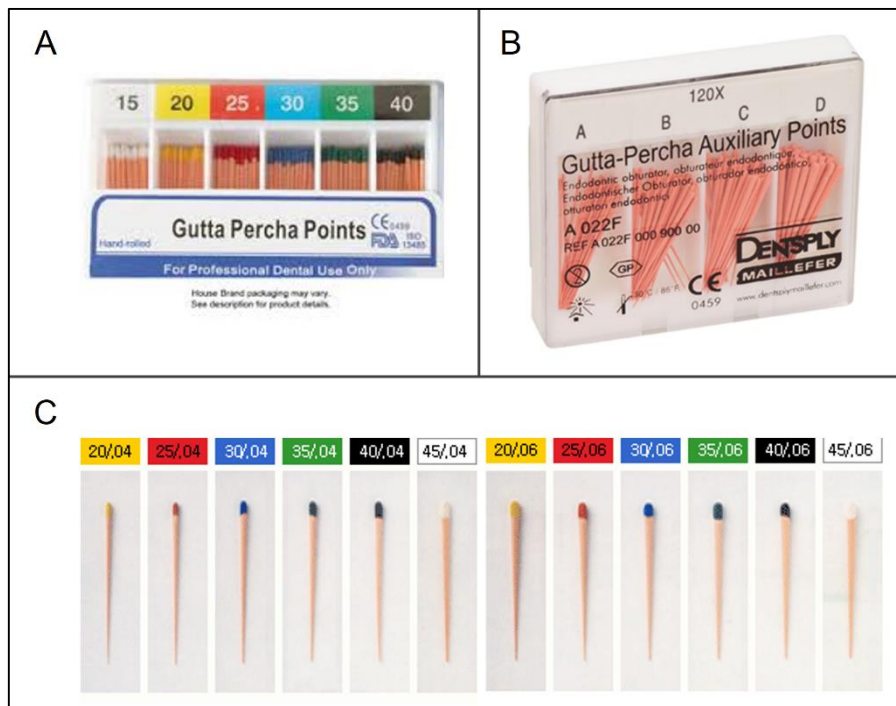


Figure 5: Gutta percha forms. (A) Standard cones, (B) auxiliary cones, (C) greater taper cones, which shows (size / taper) above each gutta percha cone.

### **Properties of gutta percha:**

- Gutta percha expand on heating and increase volume which could be advantageous to compact into root canal spaces. However, Gutta percha shrink on cooling. Therefore, vertical pressure should be applied on warm gutta percha to compensate for volume loss after cooling.

- Heat sterilization is inapplicable with gutta percha. For disinfection, gutta percha points can be immersed in ethanol alcohol (96%) for one minute prior to its use.
- Because gutta percha has no adherence property, it should always be used with sealers to seal the root canal space.
- Gutta percha can be dissolved in certain chemical solvent such as chloroform, eucalyptus oil, and orange oil. The chemically plasticized property of gutta percha is important in soften gutta percha points for better filling or in easily removal of gutta percha from the canal during re-endodontic treatment.

***Advantages of gutta percha:***

- 1- Compatibility: adaptation to the canal wall.
- 2- Inertness: do not interact with the tissue.
- 3- Tissue tolerance.
- 4- Dimensionally stable.
- 5- Radiopacity.
- 6- Plasticity: can be soften either with heat or using chemical solvent.

***Disadvantages:***

- 1- Lack of rigidity: can be bend easily with pressure which make its application difficult especially in narrow canals.
- 2- Lack of adhesiveness so it should always be used with sealers and cements.
- 3- Easily displaced by pressure.

**Silver points:**

Old endodontic filling points which were made from silver. They are stiff points with rounded cross section which can be easily used in rounded and narrow canals. However, because of their silver corrosive products which are toxic in nature, their use have been declined nowadays. In addition, silver points are not compatibles, lacking plasticity, and cannot adhere to the canal wall.

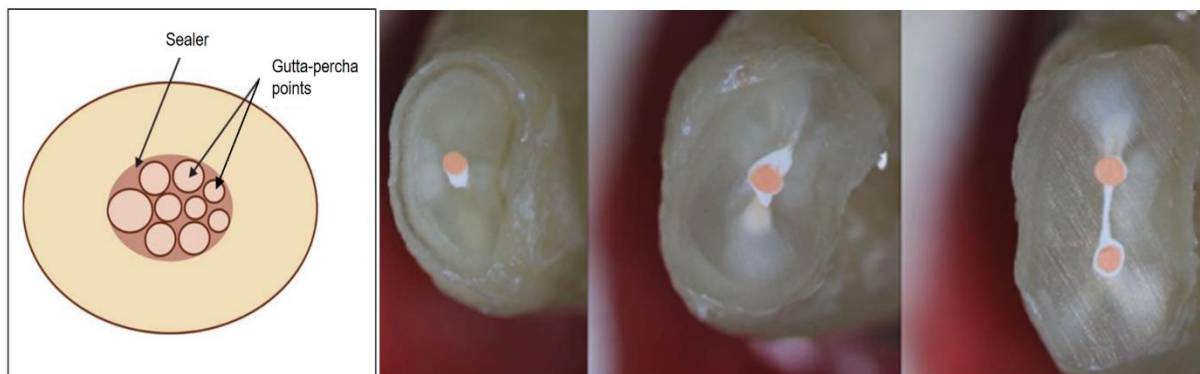**Root canal sealers:**

Sealers can serve several functions:

- 1- Lubricate and aid the seating of gutta percha cones.
- 2- Facilitate the bonding between gutta percha and root canal walls.



- 3- Filling the gaps and anatomical spaces where the primary filling cannot reach (See Fig 6).
- 4- The combination between sealer and primary filling effectively increase the fluid tight seal and prognosis of endodontic treatment. However, there are some sealers (cements) that can be used as obturating material without gutta percha.
- 5- Antimicrobial agent: the germicidal property is exerted immediately after placement.
- 6- Radiopacity: this property helps to identify the presence of auxiliary canals, resorption regions, root fracture, and the shape of apical foramen.



**Figure 6: Cross sections of roots with root canal filling (gutta percha and sealer).**

Different types of sealers are available in the market such as: zinc oxide–eugenol formulations, calcium hydroxide sealers, glass ionomers, epoxy resin sealers, silicon sealers, bioceramics and medicated sealers. These types have different physical and biological properties. Therefore, a care should be taken to evaluate all characteristics of a sealer before selection.

### **Obturation Techniques**

Different methods are available for obturating root canal system. This lecture will focussed on the following:

1. Lateral compaction technique.
2. Vertical compaction technique.

***Armamentarium for obturation:*** See figure 7.

- Primary and auxiliary (accessory) cones of gutta percha.



- Absorbent paper point for dryness of the root canal after irrigation complete. These point are available with different sizes and tapering matching that of gutta percha cones.
- Spreaders and pluggers for compaction of gutta percha. These instrument also available in different sizes to fit the size of the prepared canal. The spreaders are either hand or finger spreaders with pointed tips and sizes starting from ISO size 20 to 45 or 50. The pluggers are mainly available with handles and flat tips to vertically compact the soften gutta percha. The tip sizes are available from 0.4 to 1.2mm.
- Endodontic ruler for measuring the length of gutta percha point.
- Scissor for cutting gutta percha points during fitting inside the canal.
- Heating device such as spirit lamp or gas torch.
- Heating instrument such as spoon excavator.




Figure 7: Armamentarium of obturation. (1) ISO sizes gutta-percha points, (2) auxiliary gutta-percha, (3) absorbing paper points, (4) endodontic ruler, (5 A) hand spreader, (B) finger spreader, (6) pulgger.

**Lateral compaction technique:**

The most common obturation compaction technique involves the placement of the master gutta-percha point and accessories under lateral pressure against the canal walls by using a spreader. The canal should be continuously tapered shape with a definitive apical stop. The procedure is as follow (See Fig 8):

- 4- After canal preparation, select the master gutta-percha cone, whose size is consistent to the size of the largest file used in instrumentation up to the full working length. This gutta-percha cone is called master apical cone (MAC). This cone have to:
  - a- Fit to the full WL of the canal.
  - b- Should feel resistance when you pull the cone out of the canal. This resistance comes from the engagement of MAC between walls of the apical region of the prepared canal (3-5mm of the apical canal region) (Fig 8 A). This feeling of resistance is called tugback. If the MAC fit the entire WL but no tugback, you can either choose larger cone size or cut 0.5 to 1mm from the cone tip until a tugback has to be felt. After that mark the WL on the MAC at the level of incisal or occlusal reference point. This can be done by making a notch on the MAC at this level.
  - c- Check the fit of MAF radiographically.
    - If the master cone fit within canal WL, remove the cone from the canal and place it over a piece of cotton socked in either sodium hypochlorite or 96% ethanol.
    - If the MAC fits shorter of the WL, check for any canal blocking by dentin chips, ledge or canal curvature and treat them accordingly.
    - If the MAC going beyond the apical foramen, either select larger cone size or cut the cone to the WL (Fig 8 B).
    - If the tip of MAC shows "S" shape in radiograph this means that the cone is too small for the canal. A larger size can be selected to fit the canal.
- 5- Select suitable size of a spreader to be used for lateral compaction, which should reach 1-2mm shorter of the canal WL.
- 6- Dry the canal completely with paper point.



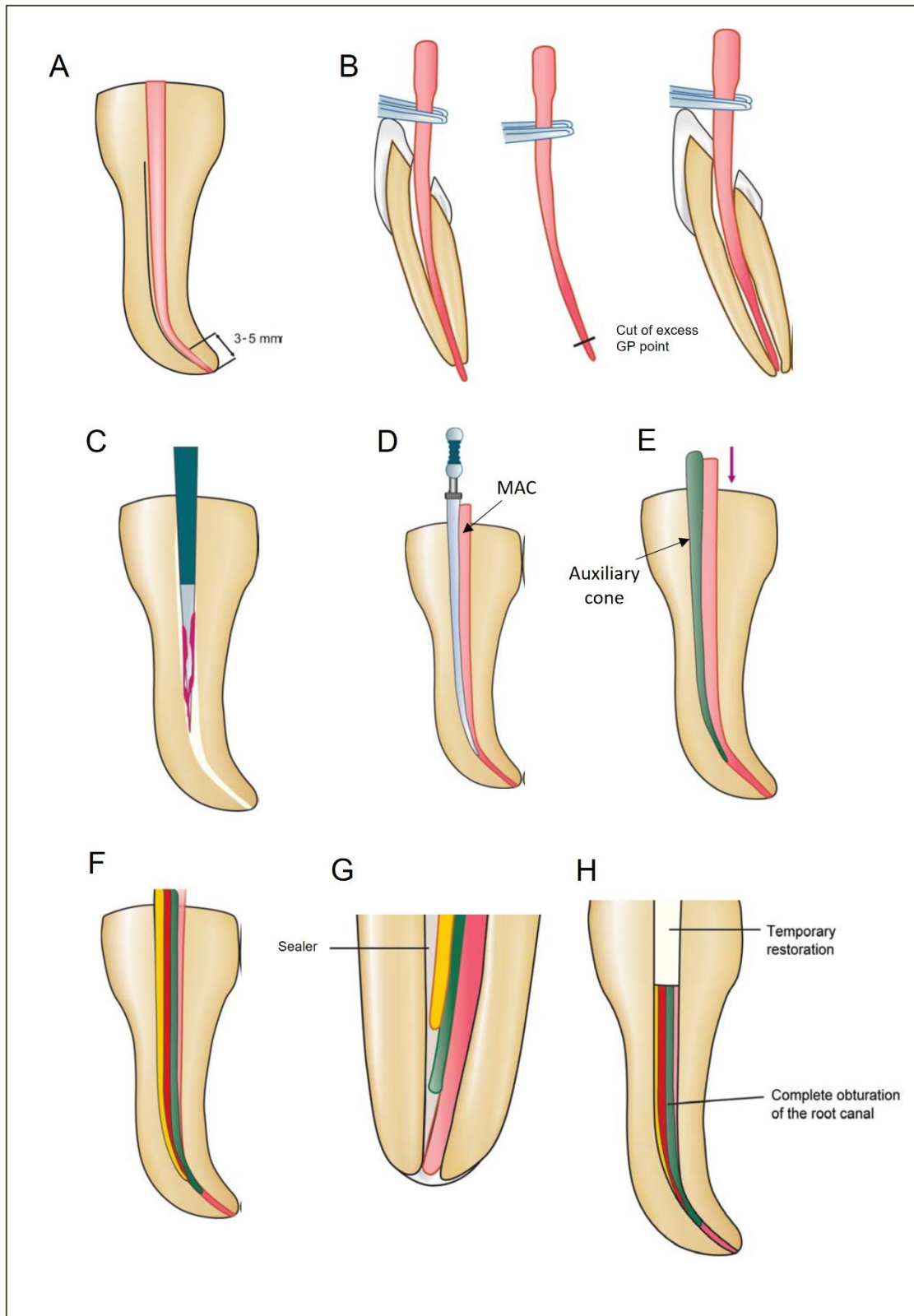
- 7- Mix the sealer according to the manufacturer instruction and apply it within the canal either by a paper point or a clean file with counter clockwise rotation inside the canal (Fig 8 C).
- 8- Coat the measured MAF with small amount of sealer and place it inside the canal. The spreader then placed into the canal alongside the MAF with vertical gentle pressure. The spreader will act as a wedge to compact gutta percha laterally under vertical pressure on the wall of the canal (Fig 8 D).
- 9- After that the spreader can be removed from the canal by rotating it back and forth. This will leave a space alongside the MAF for the accessory gutta percha.
- 10- An accessory cone can then be placed into the left space (Fig 8 E-G) and the above procedure is repeated until the spreader can no longer penetrate beyond the cervical line.
- 11- Finally the cut the protruded parts of gutta percha points with hot instrument such as spoon excavator or the endo plugger (Fig 8 H). A gentle vertical compaction can also be done by the plugger to seal the coronal orifice of the canal with the melted gutta percha.

***Advantages of lateral compaction:***

- 1- It can be used with the most routine clinical situations.
- 2- During lateral compaction, it provides length control with less chance of overfilling and post-operative pain.

***Disadvantages:***

- 1- May not sufficiently fill the irregularities within the canal.
- 2- Does not produce homogenous mass.
- 3- Voids and spaces may exist between accessory and master cones.



**Figure 8: Lateral compaction technique. A and B is fitting of MAC, C is application of sealer by paper point, D is lateral compaction of MAC by spreader, D-G is lateral compaction of auxiliary cones, H is complete obturation.**

**Vertical compaction technique:**

This technique was introduced to overcome the drawbacks of lateral compaction technique. It uses hot plugger with vertical pressure to compact the heat softened gutta percha to flow into canal irregularities. The prepared canal that can be filled by this technique should have:

- A funnel shape with continuous tapering to the apex.
- Good apical stop region (apical constriction is as small as possible).

The procedure is as follow (See Fig 9):

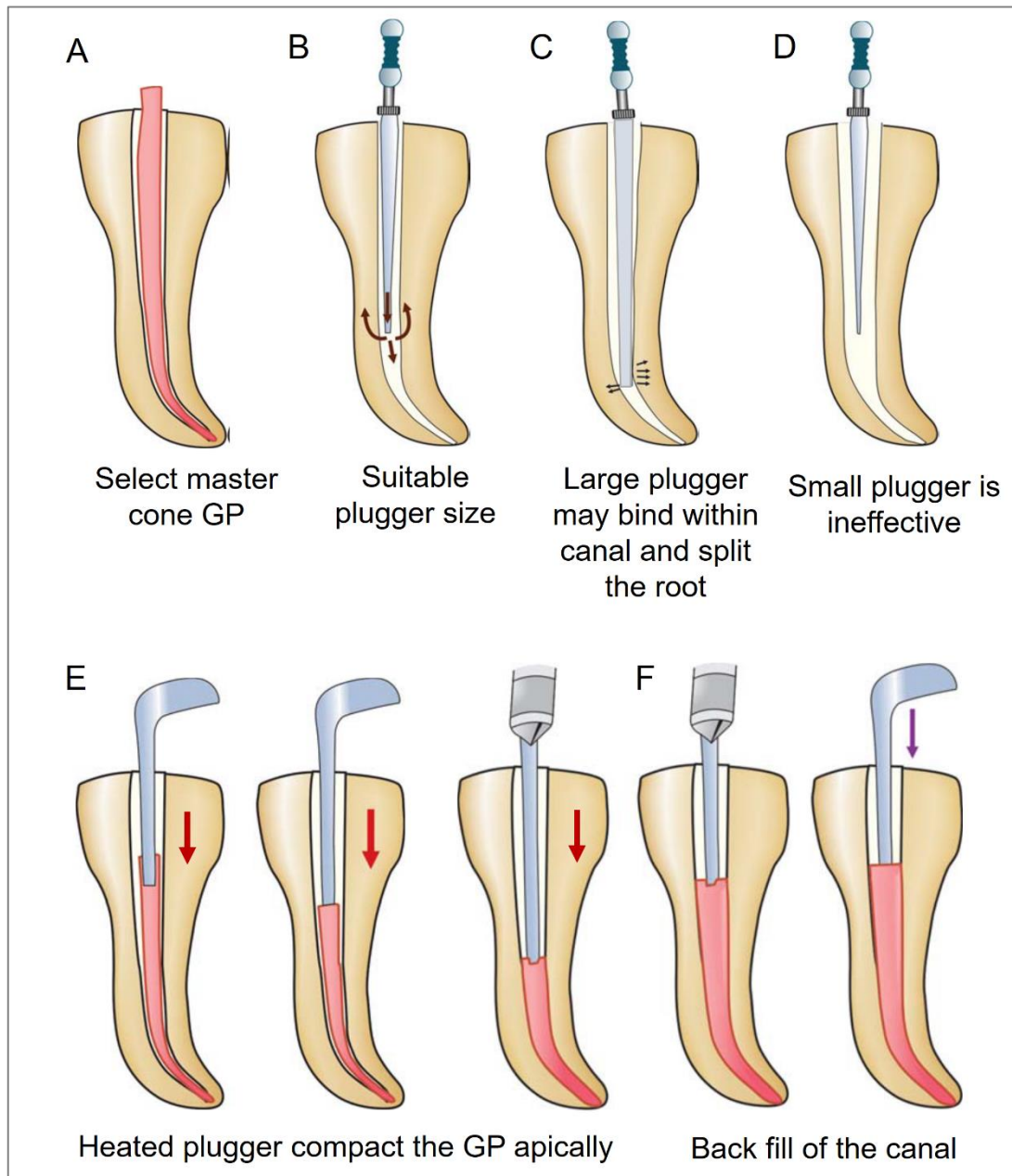
- 1- Select the master cone gutta percha which should fit the canal size and taper, and check its fitness by radiograph.
- 2- Dry the canal completely with paper point.
- 3- Select the sizes of pluggers according to the size and taper of the canal. Pluggers should be prefitted at 5 mm intervals in order to capture maximum cross section area of the softened gutta percha (Fig 9 B-D).
- 4- Coat the canal lightly with sealer by a paper point.
- 5- Cut the coronal end of the gutta percha cone at the incisal or occlusal reference point.
- 6- Use the heated plugger to vertically force the master cone into the canal. Fold the soften gutta-percha inward to fit apically and laterally. If the soften gutta-percha stuck into the plugger tip, just slight rotate the plugger to loosen it. This vertical compaction will free 2-3 mm of space coronally to allow adding more gutta-percha (Fig 9 E).
- 7- After finish the apical filling, complete obturation by doing backfilling. This can be done by heating small segment of gutta-perch and carrying them into the canal using heated larger pluggers (Fig 9 F).
- 8- Be careful not to overheat the gutta-percha to facilitate its handling.
- 9- Don't apply more sealer into the soften gutta-percha because this will prevent the adhesion between the soften layers of gutta-percha.
- 10- After completion, clean the pulp chamber from the excess of sealer and gutta-percha by a piece of cotton socked in alcohol then put the temporary or final restoration.

**Advantages of the vertical compaction technique:**

Provide excellent sealing of the canal apically and laterally with filling of the lateral and accessory canals.

**Disadvantages:**

- 1- Increase the risk of vertical root fracture.
- 2- Overfilling and apical extrusion of the gutta-percha and sealer periapically.
- 3- Time consuming procedure.



**Figure 9: Vertical compaction technique.**



**References:**

- 1- Garg N., Garg A. Textbook of Endodontics. Jaypee Brother Medical Publisher (P) LTD. 2<sup>nd</sup> Edition, 2010.
- 2- Hargreaves K M., Cohen S., Berman L H., Cohen's Pathways of the Pulp. Mosby. 10<sup>th</sup> Edition, 2011.
- 3- Ingle J I., Bakland L K., Baumgartner J C., Ingle's ENdodontics 6. BC Decker Inc Hamilton. 6<sup>th</sup> Edition, 2008.
- 4- Ng Y-L, Mann V, Rahbaran S, Lewsey J, Gulabivala K. Outcome of primary root canal treatment: systematic review of the literature – Part 2. Influence of clinical factors. Int Endod J, 41, 6–31, 2008.

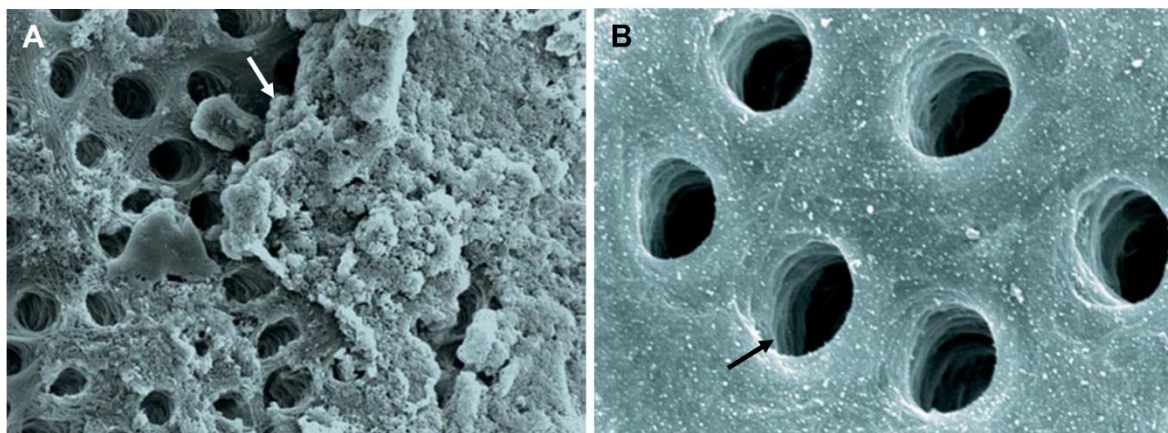


### Continue with irrigation Lec.

#### ***Chelating agent:***

After root canal instrumentation, a layer of cutting remnants will cover the dentinal tubules which contain both organic and inorganic materials. This layer is called the smear layer (Fig 1). A big controversy still exist whether to remove or maintain the smear layer which may affect permeability of dentin and root canal treatment.

However, most of studies have recommended the removal of this layer because it is the source of microorganism. Also its removal increase the adaptation and adhesiveness of root filling materials.



**Figure 1: (A) shows smear layer blocking dentinal tubules. (B) shows opening of dentinal tubules after using EDTA.**

EDTA (ethylenediaminetetraacetic acid) is the most commonly used chelating agent, which composed of 4 acetic acid groups attached to ethylenediamine. These acetic acid groups create stable calcium complexes with dentin, smear layer or calcific deposits along canal walls. This will aid in dissolving these calcific debris for easily flushing-out the root canal. The effect of EDTA on dentin depends on its concentration and the contact time. With higher concentration and longer contact time its action is increase. Studies recommended 17% concentration with neutral pH for better decalcification results.

#### *The functions and uses of EDTA:*

- 1- Lubrication for easily manipulating instruments.
- 2- Emulsification and dentin dissolving properties which reduce canal debridement time.
- 3- It helps in enlarging narrow canals.

4- Smear layer removal for better adhesion and dentinal tubules penetration of root filling material.

***Chlorhexidine:***

It is a broad spectrum antimicrobial agent and its activity is related to the cationic molecular structure, which can be absorbed by the anionic bacterial cell membrane and causes leakage of intracellular components. At low concentration chlorhexidine acts as a bacteriostatic, whereas at higher concentrations it causes coagulation and precipitation of cytoplasm therefore acts as bactericidal. Although the 0.2% chlorhexidine concentration is used in mouth washes for controlling plaque, the recommended concentration as a root canal irrigation is 2% for better results.

***Disadvantages:***

- 1- It is not considered as the main irrigant in standard endodontic therapy.
- 2- It is unable to dissolve necrotic tissue remnants.
- 3- It is less effective on gram-negative than on gram-positive bacteria.

**Methods of irrigation**

There are different methods available in delivering and activating the irrigants within root canal:

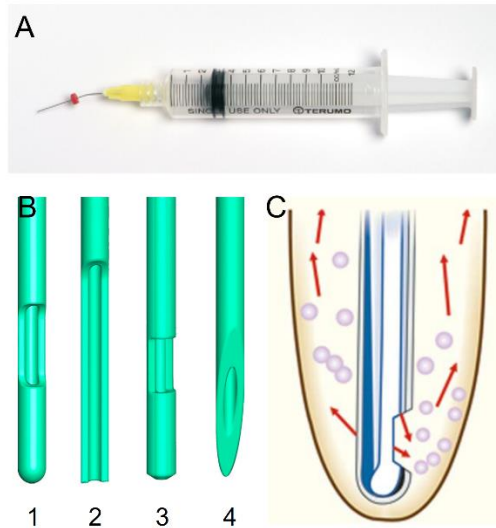
***Irrigation syringe and needle:***

Plastic syringe of different sizes (1-20ml) are used for irrigation (Fig 2 A). The preferable sizes is between 1- 5ml to maximize safety and control instead of larger syringes which required more pressure.

Although needle gauge 27 is the recommended size in many research, there are also smaller sizes available nowadays (30 and 31 gauge). The 27-G is corresponding to size 0.42mm and 30-G to size 0.31. Also several modifications of the needle tip design have been introduced (Fig 2 B), such as rounded tips and side holes to facilitate moving irrigant sideways in the canal rather than pushing the irrigant apically to reduce side effects (Fig 2 C).

***Disadvantages:*** the irrigant solutions cannot be pushed beyond the tip of the irrigation needle (Fig 2 C) because of the dead-water zone or air bubbles trapping in the apical canal region.

Figure 2: (A) Irrigation syringe, (B) different needle tip designs (1-3) compared to conventional hypodermic needle (4). (C) flow of irrigation fluid no further than the irrigation needle.



### **Ultrasonic**

The use of ultrasonic energy for oscillating file with the present of irrigant have been shown to clean root canal better than conventional hand instrumentation. The ultrasonically oscillated file cause an energy which passes to the irrigant solution and exert 'acoustic streaming or scrubbing' effect on the canal walls. This mechanical energy dislodge the debris and smear layer from the canal walls.

#### *Disadvantages:*

- 1- Ultrasonic preparation of the canal is found to be unpredictable.
- 2- It can lead to excessive cutting of canal walls and may damage the finished preparation.

### **Sonic:**

The irrigation solution also can be activated sonically to create kinetic energy which could facilitate debridement of the root canal. EndoActivator (Fig 3) is one of these irrigation facilitator methods. It is based on sonic vibration (up to 10,000 cpm) of a plastic tip in the root canal after delivery of the irrigant by using irrigation syringe.

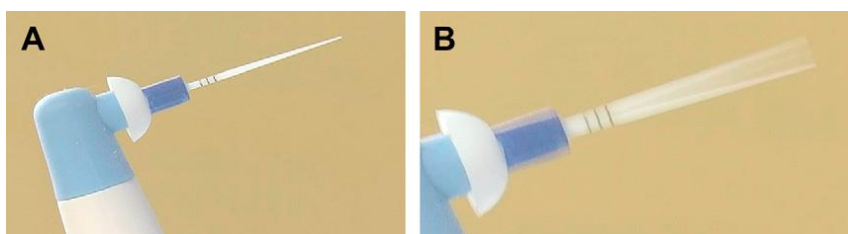


Figure 3: (A) EndoActivator with plastic tip. (B) Sonic motion of the plastic tip.

## Obturation of root canal system

- After chemo-mechanical debridement of root canal system by instrumentation and irrigation, the next step is complete (3 dimensional) obturation of root canal space to maintain the tooth functional within the dental arch.
- The remaining non-vital pulp within incompletely debrided root canal will undergo autolysis and the disintegrated by products will diffuse into the surrounding tissue.
- The fundamental aim of obturation is to provide 3 dimensional hermetic seal of root canal space to prevent the leakage from or into root canal system.
- The obturation method include the use of a solid or semisolid core material (gutta percha) surrounding by a sealer type of material to produce the fluid tight seal, by filling the main root canal(s), the accessory canals, voids, spaces and irregularities.

### Aims of root canal obturation:

- 1- The achievement of 3 dimensional obliteration of the root canal space to prevent ingress of bacteria and body fluids into root canal space, as well as egress of bacteria or their toxins out of the root canal.
- 2- To provide fluid tight seal within all regions of root canal space to prevent microleakage.
- 3- The replacement of the root canal space filled with necrotic tissue by an inert filling material to create a favourable healing environment and avoid recurrent infection.
- 4- To provide adequate coronal seal with proper coronal restoration to obtain long term success of root canal therapy.

### Timing of obturation:

Several factors should be checked before doing obturation:

- 1- Patient symptoms: the sensitivity to percussion indicative that the inflammation of the periapical periodontal ligament is present. Therefore the obturation has to be postponed until the inflammation subside. In cases of irreversible pulpitis with no tenderness to percussion present, the root canal treatment can be completed in a single visit as soon as the cause of the pain and inflammation has been removed.

- 2- Canal wettability: presence of wet canal with purulent exudate, blood or pus is a strong evidence that the periradicular inflammation is still present. Obturation of the root canal at this stage increase the pressure within periradicular region and subsequent tissue destruction may proceed rapidly. Therefore, in cases of active periradicular infection, delaying obturation until all signs and symptoms of inflammation have to be subside is extremely recommended.
- 3- Negative culture: most of the endodontist do not relay on this test because researches have approved that the false negative results inaccurately assess the intracanal microbial flora. Furthermore, the positive results is not an indicative for the potential bacterial pathogenicity.

**Features of an ideal root canal obturation:**

- 1- Complete 3 dimensional obturation from the coronal orifice of the root canal until CDJ.
- 2- Radiographically, the root filling should be within 0.5- 0.75 mm from radiographical apex.
- 3- The root canal should be completely filled, mainly with root filling material with a minimum amount of sealer.

**Underfilling:** occur when the root canal filling is shorter that total root canal space (See figure 4 A). This definitely provide an environment for initiation, persistence or recurrence of periradicular infection.

**Overfilling:** occur when the root filling material extended beyond the CDJ (See figure 4 B). According to Ng et al. 2007<sup>1</sup> the extrusion of root canal filling is considered to be acceptable within 2mm beyond (longer than) the radiographical apex, if it is associated with 3 dimensional sealing of root canal system.

---

<sup>1</sup> Ng Y-L, Mann V, Rahbaran S, Lewsey J, Gulabivala K. Outcome of primary root canal treatment: systematic review of the literature – Part 2. Influence of clinical factors. Int Endod J, 41, 6–31, 2008.

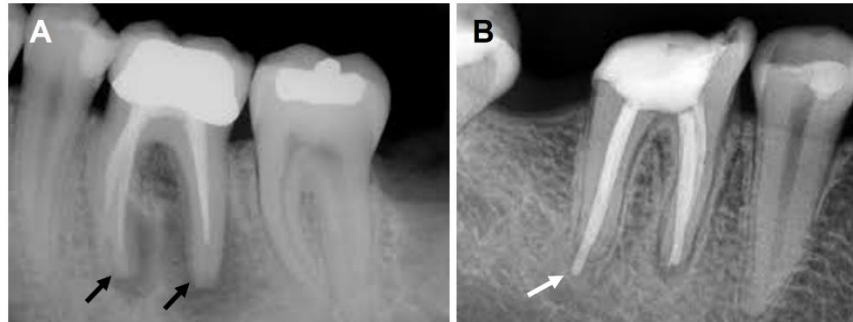


Figure 4: Underfilling (A) and overfilling (B) of root canal treatment.

### Characteristics of an ideal root filling material:

- 1- Easily introduced in the root canal.
- 2- Provide an apical and lateral sealing of the root canal.
- 3- Dimensionally stable after usage.
- 4- Impervious to moisture.
- 5- Bacteriostatic or at least should not encourage bacterial growth.
- 6- Radiopaque.
- 7- Non staining to tooth structure.
- 8- Non irritating
- 9- Sterile or easily sterilized.
- 10- Removed easily from canal if required.

#### Materials used for obturation

- Plastics: Gutta-percha, resilon
- Solids or metal cores: Silver points, Gold, stainless steel, titanium and irridio-platinum.
- Cements and pastes:
  - Hydron
  - MTA
  - Calcium phosphate
  - Gutta flow

### Gutta percha

Gutta percha is a natural material extracted as a dried coagulated from a Brazilian trees (Palaquium). Its molecular structure is close to natural rubber. Chemically gutta percha is available into two crystalline forms: alpha ( $\alpha$ ) and beta ( $\beta$ ).

The most commercially available product is in  $\beta$ -form which composed of the following:

Organic content: gutta percha 20% + waxes and resins 3%

Inorganic: zinc oxide filler 66% + heavy metal sulfates as radioopacifiers 11%

### **Forms of Gutta percha:**

Gutta percha available in different forms. The  $\beta$ -form is produced as gutta percha points (cones) which is available in different sizes and tapering as follow:

- 1- Standard cones of the same size and shape of the ISO endodontic instruments.
- 2- Greater taper gutta percha points: available with taper 4%, 6%, 8% and 10%.
- 3- Auxiliary points: non-standard cones.

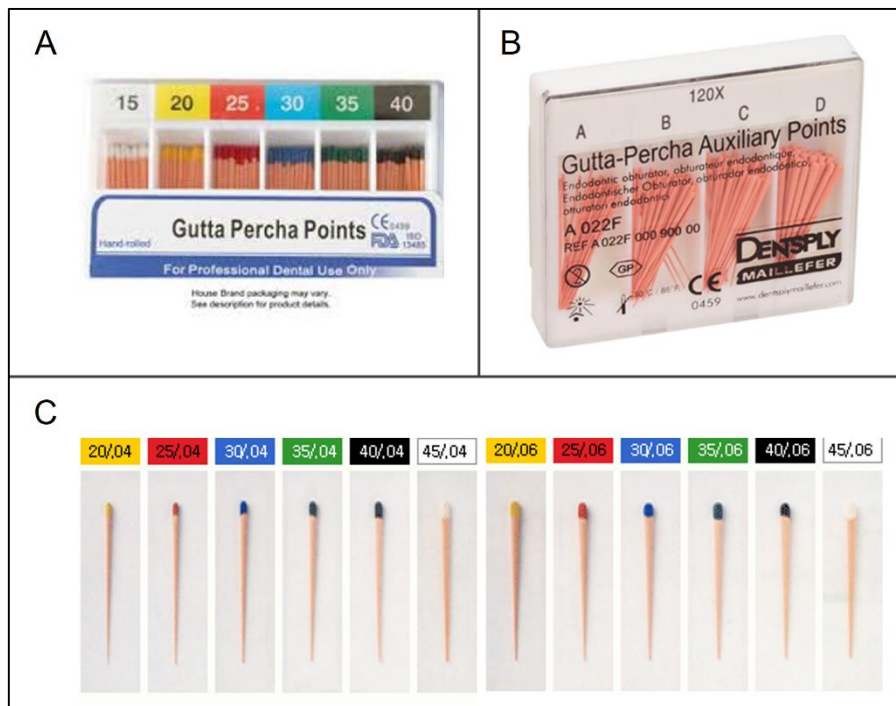


Figure 5: Gutta percha forms. (A) Standard cones, (B) auxiliary cones, (C) greater taper cones, which shows (size / taper) above each gutta percha cone.

### **Properties of gutta percha:**

- Gutta percha expand on heating and increase volume which could be advantageous to compact into root canal spaces. However, Gutta percha shrink on cooling. Therefore, vertical pressure should be applied on warm gutta percha to compensate for volume loss after cooling.



- Heat sterilization is inapplicable with gutta percha. For disinfection, gutta percha points can be immersed in ethanol alcohol (96%) for one minute prior to its use.
- Because gutta percha has no adherence property, it should always be used with sealers to seal the root canal space.
- Gutta percha can be dissolved in certain chemical solvent such as chloroform, eucalyptus oil, and orange oil. The chemically plasticized property of gutta percha is important in soften gutta percha points for better filling or in easily removal of gutta percha from the canal during re-endodontic treatment.

***Advantages of gutta percha:***

- 1- Compatibility: adaptation to the canal wall.
- 2- Inertness: do not interact with the tissue.
- 3- Tissue tolerance.
- 4- Dimensionally stable.
- 5- Radiopacity.
- 6- Plasticity: can be soften either with heat or using chemical solvent.

***Disadvantages:***

- 1- Lack of rigidity: can be bend easily with pressure which make its application difficult especially in narrow canals.
- 2- Lack of adhesiveness so it should always be used with sealers and cements.
- 3- Easily displaced by pressure.

**Silver points:**

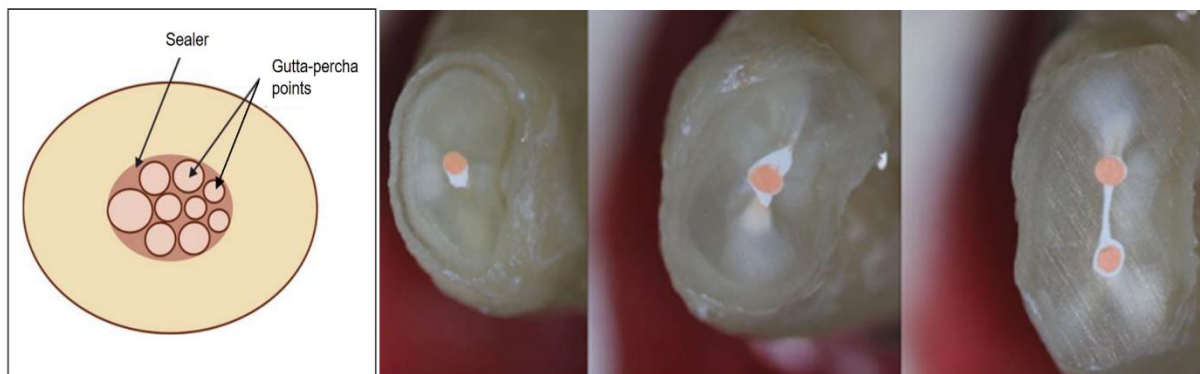
Old endodontic filling points which were made from silver. They are stiff points with rounded cross section which can be easily used in rounded and narrow canals. However, because of their silver corrosive products which are toxic in nature, their use have been declined nowadays. In addition, silver points are not compatibles, lacking plasticity, and cannot adhere to the canal wall.

**Root canal sealers:**

Sealers can serve several functions:

- 1- Lubricate and aid the seating of gutta percha cones.
- 2- Facilitate the bonding between gutta percha and root canal walls.

- 3- Filling the gaps and anatomical spaces where the primary filling cannot reach (See Fig 6).
- 4- The combination between sealer and primary filling effectively increase the fluid tight seal and prognosis of endodontic treatment. However, there are some sealers (cements) that can be used as obturating material without gutta percha.
- 5- Antimicrobial agent: the germicidal property is exerted immediately after placement.
- 6- Radiopacity: this property helps to identify the presence of auxiliary canals, resorption regions, root fracture, and the shape of apical foramen.



**Figure 6: Cross sections of roots with root canal filling (gutta percha and sealer).**

Different types of sealers are available in the market such as: zinc oxide–eugenol formulations, calcium hydroxide sealers, glass ionomers, epoxy resin sealers, silicon sealers, bioceramics and medicated sealers. These types have different physical and biological properties. Therefore, a care should be taken to evaluate all characteristics of a sealer before selection.

### **Obturation Techniques**

Different methods are available for obturating root canal system. This lecture will focussed on the following:

1. Lateral compaction technique.
2. Vertical compaction technique.

***Armamentarium for obturation:*** See figure 7.

- Primary and auxiliary (accessory) cones of gutta percha.

- Absorbent paper point for dryness of the root canal after irrigation complete. These point are available with different sizes and tapering matching that of gutta percha cones.
- Spreaders and pluggers for compaction of gutta percha. These instrument also available in different sizes to fit the size of the prepared canal. The spreaders are either hand or finger spreaders with pointed tips and sizes starting from ISO size 20 to 45 or 50. The pluggers are mainly available with handles and flat tips to vertically compact the soften gutta percha. The tip sizes are available from 0.4 to 1.2mm.
- Endodontic ruler for measuring the length of gutta percha point.
- Scissor for cutting gutta percha points during fitting inside the canal.
- Heating device such as spirit lamp or gas torch.
- Heating instrument such as spoon excavator.




Figure 7: Armamentarium of obturation. (1) ISO sizes gutta-percha points, (2) auxiliary gutta-percha, (3) absorbing paper points, (4) endodontic ruler, (5 A) hand spreader, (B) finger spreader, (6) pulgger.

**Lateral compaction technique:**

The most common obturation compaction technique involves the placement of the master gutta-percha point and accessories under lateral pressure against the canal walls by using a spreader. The canal should be continuously tapered shape with a definitive apical stop. The procedure is as follow (See Fig 8):

- 4- After canal preparation, select the master gutta-percha cone, whose size is consistent to the size of the largest file used in instrumentation up to the full working length. This gutta-percha cone is called master apical cone (MAC). This cone have to:
  - a- Fit to the full WL of the canal.
  - b- Should feel resistance when you pull the cone out of the canal. This resistance comes from the engagement of MAC between walls of the apical region of the prepared canal (3-5mm of the apical canal region) (Fig 8 A). This feeling of resistance is called tugback. If the MAC fit the entire WL but no tugback, you can either choose larger cone size or cut 0.5 to 1mm from the cone tip until a tugback has to be felt. After that mark the WL on the MAC at the level of incisal or occlusal reference point. This can be done by making a notch on the MAC at this level.
  - c- Check the fit of MAF radiographically.
    - If the master cone fit within canal WL, remove the cone from the canal and place it over a piece of cotton socked in either sodium hypochlorite or 96% ethanol.
    - If the MAC fits shorter of the WL, check for any canal blocking by dentin chips, ledge or canal curvature and treat them accordingly.
    - If the MAC going beyond the apical foramen, either select larger cone size or cut the cone to the WL (Fig 8 B).
    - If the tip of MAC shows "S" shape in radiograph this means that the cone is too small for the canal. A larger size can be selected to fit the canal.
- 5- Select suitable size of a spreader to be used for lateral compaction, which should reach 1-2mm shorter of the canal WL.
- 6- Dry the canal completely with paper point.

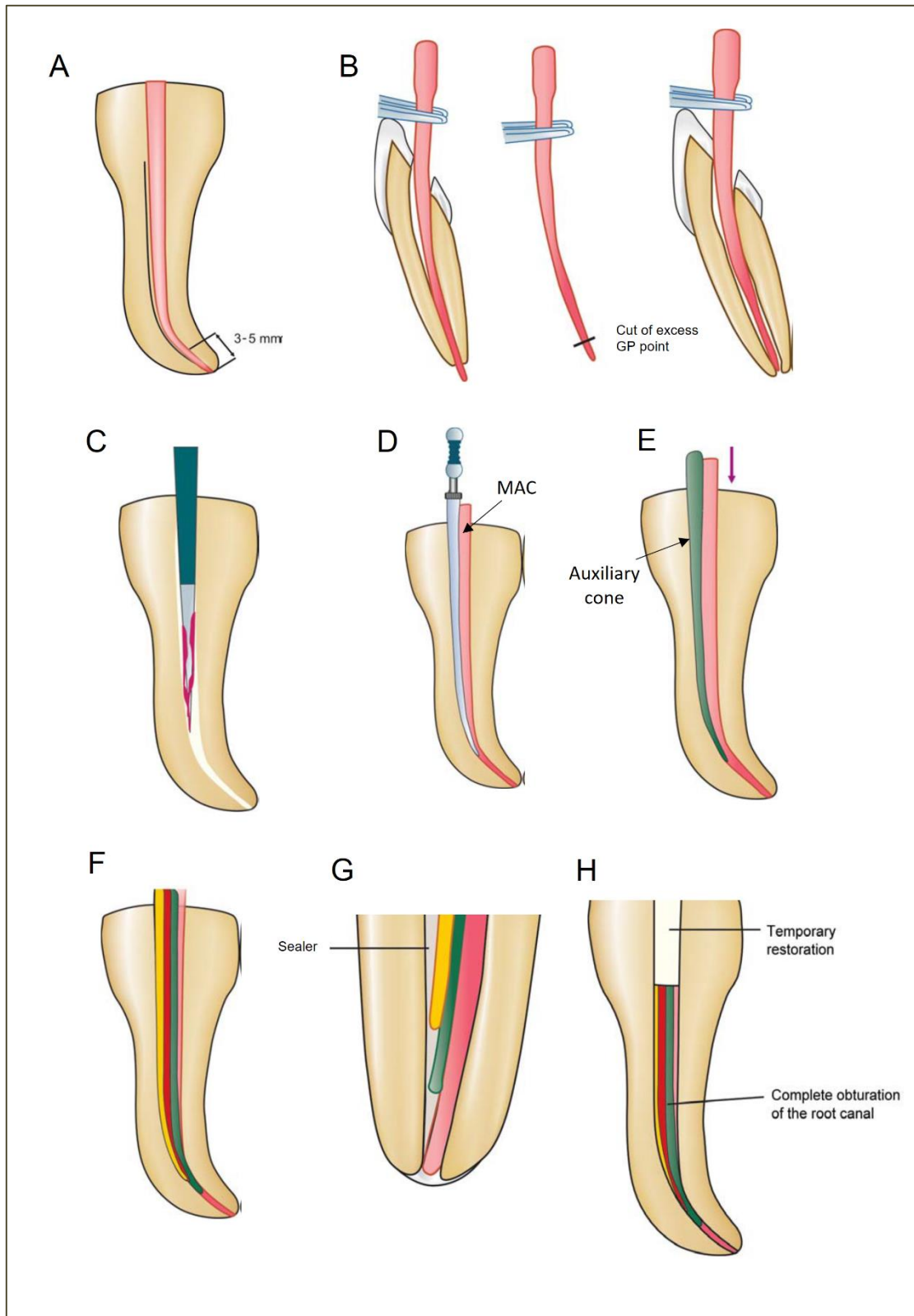
- 7- Mix the sealer according to the manufacturer instruction and apply it within the canal either by a paper point or a clean file with counter clockwise rotation inside the canal (Fig 8 C).
- 8- Coat the measured MAF with small amount of sealer and place it inside the canal. The spreader then placed into the canal alongside the MAF with vertical gentle pressure. The spreader will act as a wedge to compact gutta percha laterally under vertical pressure on the wall of the canal (Fig 8 D).
- 9- After that the spreader can be removed from the canal by rotating it back and forth. This will leave a space alongside the MAF for the accessory gutta percha.
- 10- An accessory cone can then be placed into the left space (Fig 8 E-G) and the above procedure is repeated until the spreader can no longer penetrate beyond the cervical line.
- 11- Finally the cut the protruded parts of gutta percha points with hot instrument such as spoon excavator or the endo plugger (Fig 8 H). A gentle vertical compaction can also be done by the plugger to seal the coronal orifice of the canal with the melted gutta percha.

***Advantages of lateral compaction:***

- 1- It can be used with the most routine clinical situations.
- 2- During lateral compaction, it provides length control with less chance of overfilling and post-operative pain.

***Disadvantages:***

- 1- May not sufficiently fill the irregularities within the canal.
- 2- Does not produce homogenous mass.
- 3- Voids and spaces may exist between accessory and master cones.



**Figure 8: Lateral compaction technique. A and B is fitting of MAC, C is application of sealer by paper point, D is lateral compaction of MAC by spreader, D-G is lateral compaction of auxiliary cones, H is complete obturation.**

**Vertical compaction technique:**

This technique was introduced to overcome the drawbacks of lateral compaction technique. It uses hot plugger with vertical pressure to compact the heat softened gutta percha to flow into canal irregularities. The prepared canal that can be filled by this technique should have:

- A funnel shape with continuous tapering to the apex.
- Good apical stop region (apical constriction is as small as possible).

The procedure is as follow (See Fig 9):

- 1- Select the master cone gutta percha which should fit the canal size and taper, and check its fitness by radiograph.
- 2- Dry the canal completely with paper point.
- 3- Select the sizes of pluggers according to the size and taper of the canal. Pluggers should be prefitted at 5 mm intervals in order to capture maximum cross section area of the softened gutta percha (Fig 9 B-D).
- 4- Coat the canal lightly with sealer by a paper point.
- 5- Cut the coronal end of the gutta percha cone at the incisal or occlusal reference point.
- 6- Use the heated plugger to vertically force the master cone into the canal. Fold the soften gutta-percha inward to fit apically and laterally. If the soften gutta-percha stuck into the plugger tip, just slight rotate the plugger to loosen it. This vertical compaction will free 2-3 mm of space coronally to allow adding more gutta-percha (Fig 9 E).
- 7- After finish the apical filling, complete obturation by doing backfilling. This can be done by heating small segment of gutta-perch and carrying them into the canal using heated larger pluggers (Fig 9 F).
- 8- Be careful not to overheat the gutta-percha to facilitate its handling.
- 9- Don't apply more sealer into the soften gutta-percha because this will prevent the adhesion between the soften layers of gutta-percha.
- 10- After completion, clean the pulp chamber from the excess of sealer and gutta-percha by a piece of cotton socked in alcohol then put the temporary or final restoration.

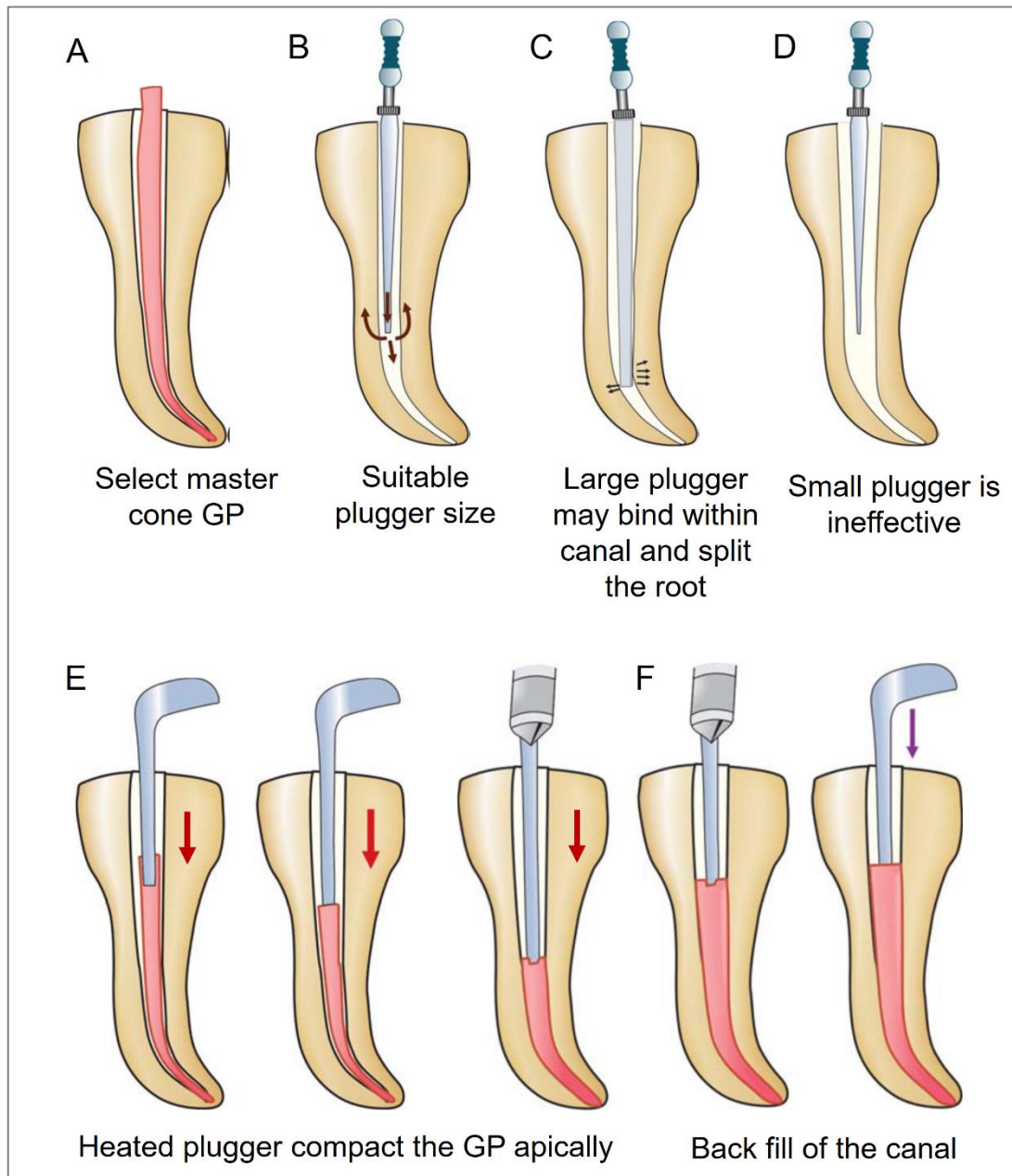


**Advantages of the vertical compaction technique:**

Provide excellent sealing of the canal apically and laterally with filling of the lateral and accessory canals.

**Disadvantages:**

- 1- Increase the risk of vertical root fracture.
- 2- Overfilling and apical extrusion of the gutta-percha and sealer periapically.
- 3- Time consuming procedure.



**Figure 9: Vertical compaction technique.**

**References:**

- 1- Garg N., Garg A. Textbook of Endodontics. Jaypee Brother Medical Publisher (P) LTD. 2<sup>nd</sup> Edition, 2010.
- 2- Hargreaves K M., Cohen S., Berman L H., Cohen's Pathways of the Pulp. Mosby. 10<sup>th</sup> Edition, 2011.
- 3- Ingle J I., Bakland L K., Baumgartner J C., Ingle's ENdodontics 6. BC Decker Inc Hamilton. 6<sup>th</sup> Edition, 2008.
- 4- Ng Y-L, Mann V, Rahbaran S, Lewsey J, Gulabivala K. Outcome of primary root canal treatment: systematic review of the literature – Part 2. Influence of clinical factors. Int Endod J, 41, 6–31, 2008.

# Endodontics

## Lecture 1

### **Introduction and Scope of Endodontics**

Endo is a Greek word for "Inside" and Odont is Greek word for "Tooth". Endodontic treatment treats inside of the tooth. **Endodontics** is the branch of clinical dentistry associated with the prevention, diagnosis and treatment of the pathosis of the dental pulp and peri-radicular tissue. That is, the main aim of the endodontic therapy involves to:

- i. Maintain vitality of the pulp.
- ii. Preserve and restore the tooth with damaged and necrotic pulp.
- iii. Preserve and restore the teeth which have failed to the previous endodontic therapy, to allow the tooth to remain functional in the dental arch.

### **OBJECTIVE OF ENDODONTIC TREATMENT**

The primary objective of endodontic therapy is to create a biologically acceptable environment within the root canal system which allows the healing and continued maintenance of the health of the peri-radicular tissue. This objective can be achieved by eliminating the bacteria (source of infection) from within the root canal system, and sealing the root canal and tooth to prevent re-infection. Since nothing is as good as the natural teeth, one should take care of them.

The endodontic therapy is a necessary treatment to cure a damaged or diseased tooth. Endodontics has been defined as art as well as science of clinical dentistry because in spite of all the factual scientific foundation on which the endodontics is based, to provide an ideal endodontic treatment is an art in itself.

Endodontic treatment encompasses procedures that are designed to maintain the health of all or part of the dental pulp. When the dental pulp is diseased or injured, treatment is aimed at preserving normal peri-radicular tissues. When apical periodontitis has occurred treatment is aimed at restoring the peri-radicular tissues to health: this is usually carried out by root canal treatment, occasionally in combination with surgical endodontics.

## **SCOPE OF ENDODONTICS**

Scope of endodontics includes following:

- a. Vital pulp therapy (pulp capping, pulpotomy)
- b. Diagnosis and differential diagnosis of oro-facial pain.
- c. Root canal treatment of teeth with or without periradicular pathology of pulpal origin.
- d. Surgical management of pathology resulting from pulpal pathosis.
- e. Management of avulsed teeth (replantation)
- f. Endodontic implants
- g. Root end resections, hemisections and root resections
- h. Retreatment of teeth previously treated endodontically
- i. Bleaching of discolored teeth.
- j. Coronal restorations of teeth using post and cores

## **INDICATIONS FOR ROOT CANAL TREATMENT**

Root canal treatment may be carried out on all patients where other dental procedures may be undertaken. Specific indications are

1. An irreversibly damaged or necrotic pulp with or without clinical and/or radiological findings of apical periodontitis.
2. Elective devitalization, e.g. to provide post space, prior to construction of an overdenture, doubtful pulp health prior to restorative procedures, likelihood of pulpal exposure when restoring a (misaligned) tooth and prior to root resection or hemisection.

## **CONTRAINDICATIONS FOR ROOT CANAL TREATMENT**

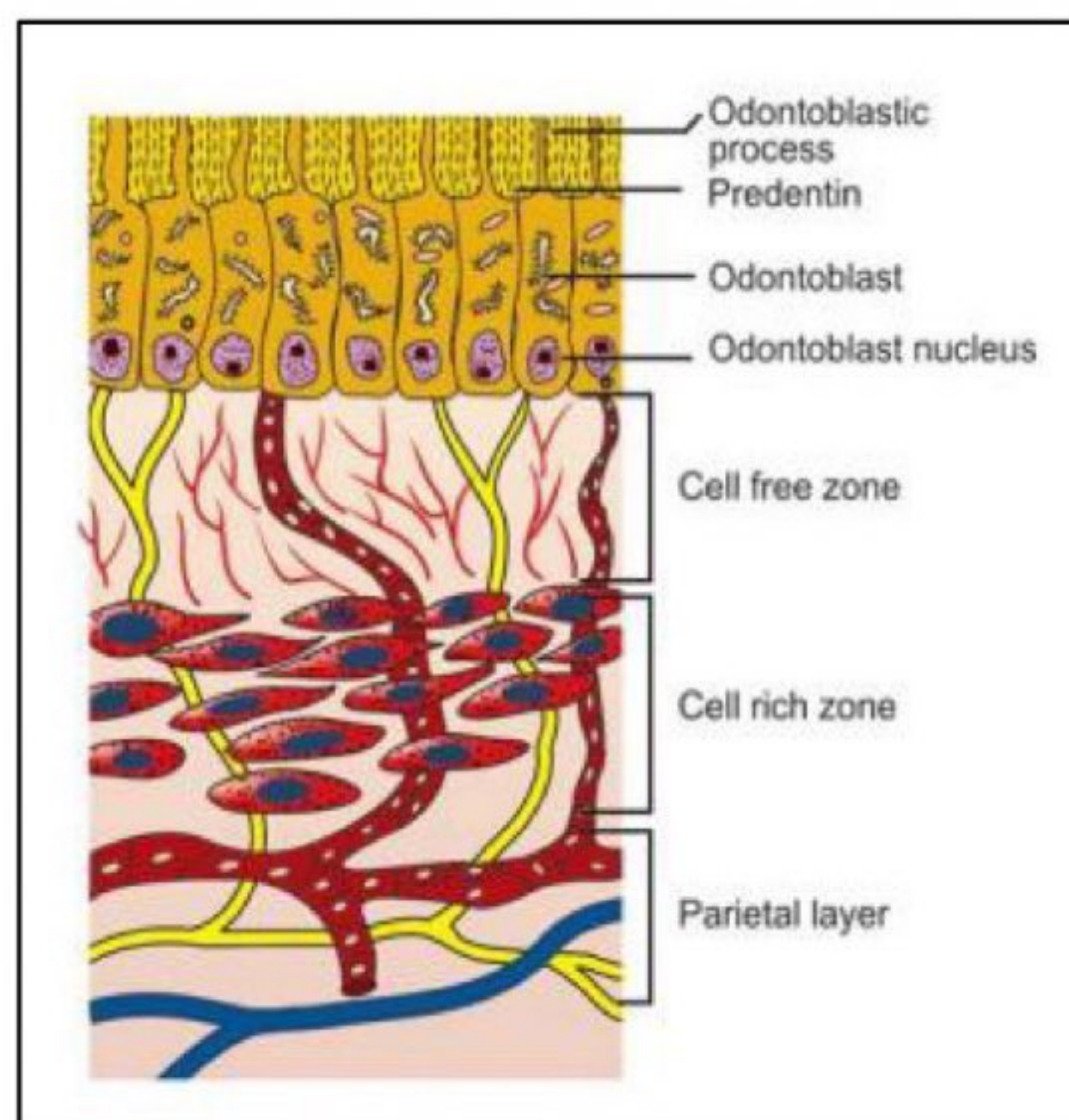
1. Teeth that cannot be made functional nor restored.
2. Teeth with insufficient periodontal support.
3. Teeth with poor prognosis, uncooperative patients or patients where dental treatment procedures cannot be undertaken.
4. Teeth of patients with poor oral condition that cannot be improved within a reasonable period.

## **HISTOLOGY OF DENTAL PULP**

The dental pulp is soft tissue of mesenchymal origin located in the centre of the tooth. It consists of specialized cells, odontoblasts arranged peripherally in direct contact with dentin matrix. This close relationship between odontoblasts and dentin is known as “pulp-dentine complex”. The pulp is connective tissue system composed of cells, ground substances,

fibres, interstitial fluid, odontoblasts, fibroblasts and other cellular components. Pulp is actually a microcirculatory system consists of arterioles and venules as the largest vascular component. When pulp is examined histologically, it can be distinguished into four distinct zones from periphery to centre of the pulp as shown in Figure below. The zones are as following:

- A. Odontoblastic layer at the pulp periphery:** Odontoblasts consists of cell bodies and cytoplasmic processes.
- B. Cell free zone of Weil:** Central to odontoblasts is sub-odontoblastic layer, it contains plexuses of capillaries and small nerve fibres
- C. Cell rich zone:** It contains fibroblasts, undifferentiated cells which maintain number of odontoblasts by proliferation and differentiation
- D. Pulp core:** It contains large vessels and nerves from which branches extend to peripheral layers.



Contents of the pulp	
I. Cells	<ol style="list-style-type: none"> <li>1. Odontoblasts</li> <li>2. Fibroblasts</li> <li>3. Undifferentiated mesenchymal cells</li> <li>4. Defense cells - Macrophages Plasma cells Mast cells</li> </ol>
II. Matrix	<ol style="list-style-type: none"> <li>1. Collagen fibers - Type I Type II</li> <li>2. Ground Substance - Glycosaminoglycans - Glycoproteins - Water</li> </ol>
III. Blood Vessels	- Arterioles, Venules, Capillaries
IV. Lymphatics	- Draining to submandibular, submental and deep cervical nodes
V. Nerves	- Subodontoblastic plexus of Raschkow - Sensory afferent from Vth nerve and Superior cervical ganglion

Figure 1. Zones of pulp

## ANATOMY OF DENTAL PULP

Pulp lies in the centre of tooth and shapes itself to miniature form of tooth. This space is called pulp cavity which is divided into a pulp chamber and root canal/s starting from the orifice to the apical foramen. There are also accessory and lateral canals. The roof of pulp chamber consists of dentin covering the pulp chamber occlusally. Canal orifices are openings in the floor of pulp chamber leading into the root canals. The shape of root canal varies with size, shape, number of the roots in different teeth.

## FUNCTIONS OF PULP

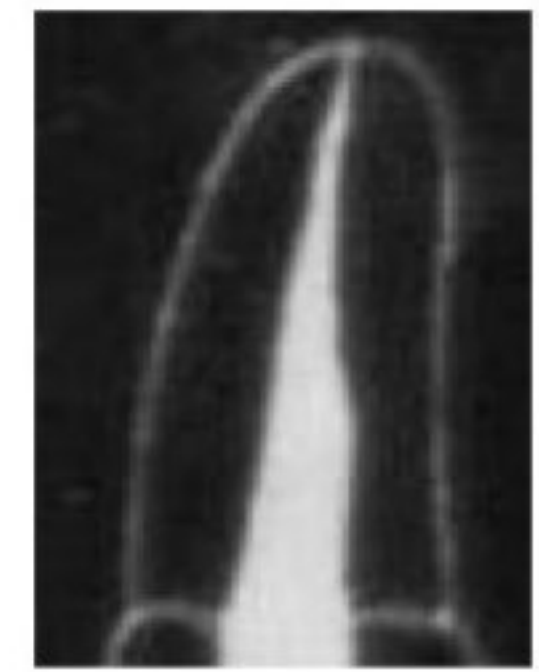
Pulp performs four basic functions:

1. Formation of dentine
2. Nutrition of dentine
3. Innervation of tooth
4. Defense of tooth

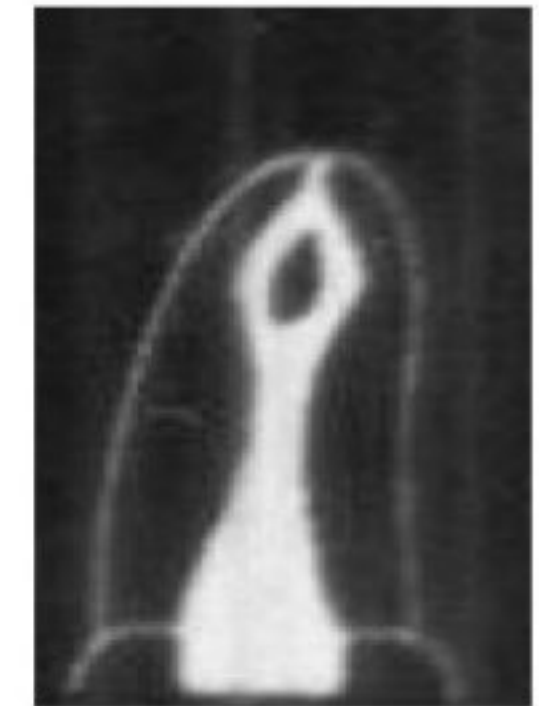## ROOT CANAL CONFIGURATION

The shape of root canals is divided into four types:

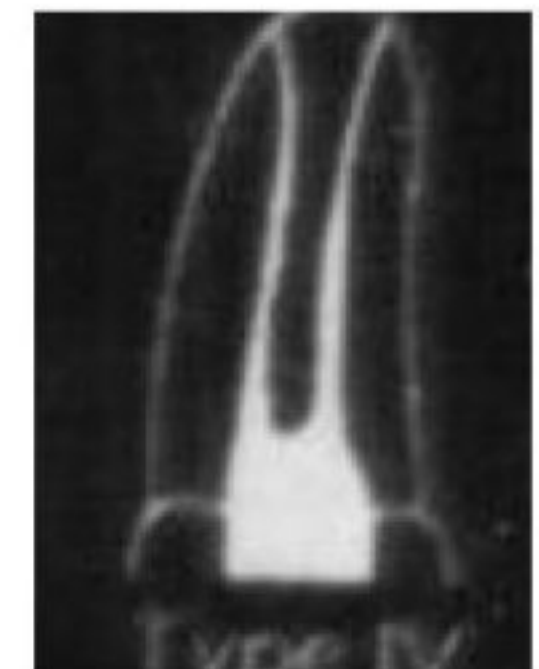**Type 1:** A single canal leaving the pulp chamber and continuing as a single canal to the root apex and opens in a single apical foramen. It refers to **1-1-1**



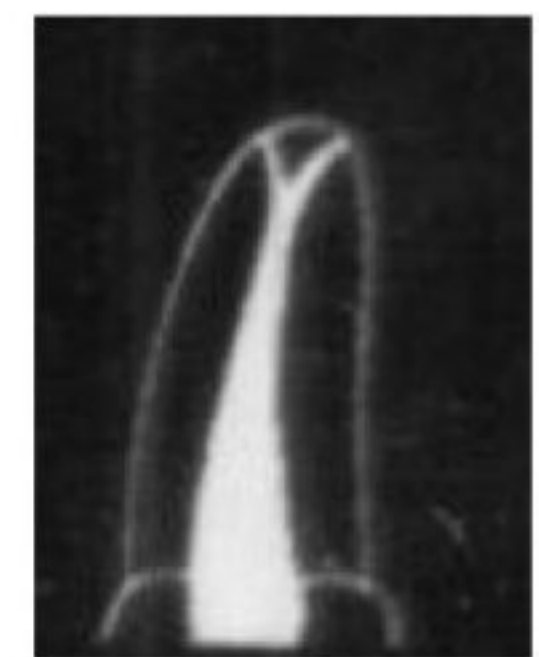
**Type 2:** Two canals leave the pulp chamber then join each other at the apical third to open in a single apical foramen. It refers to **2-1-1**



**Type 3:** Two canals leave the pulp chamber and continue as two canals to be opened in two separate apical foramina. It refers to **2-2-2**



**Type 4:** A single canal leaving the pulp chamber, and bifurcating at the apical third into two canals and open in two apical foramina. It refers to **1-2-2**



## BASIC PHASES OF TREATMENT

There are three basic phases of treatment:

- 1- The Diagnostic phase in which the disease to be treated is “determined “and the treatment plan developed.
- 2- The Preparatory phase in which the contents of the root canal are removed and the canal is prepared to receive a filling material.

3- The obliteration Phase in which the canal is filled or obliterated with an inert material to obtain an adequate seal as close as possible to C.D.J. (cementodentinal junction).

If there is a defect in any phase, the endodontic treatment will not be succeeded.

## **PULP AND PERI-RADICULAR PATHOLOGY**

Etiology of pulpal diseases can be broadly classified into:

### **I. Bacterial irritant**

Bacteria, usually from dental caries, are the main source of injury to the pulpal and periradicular tissues and they enter either directly or through dentine tubules.

Modes of entry for bacteria to the pulp are as follows:

- 1- Through the carious cavity.
- 2- Through the dentinal tubules as in contamination during cavity preparation, through exposed root surface, and surfaces with erosion, abrasion and attrition.
- 3- Through the apical foramen as in advanced periodontitis where microorganisms reach the apical foramen and then the pulp.
- 4- Through the blood stream (anachoresis: it is a process by which microorganisms get carried by the bloodstream from another source localize on inflamed tissue). Following trauma or inflammation to the pulp any bacteria in the blood might be attracted to the pulp causing pulpitis.
- 5- Through faulty tooth restoration.
- 6- Through extension of a periapical infection from adjacent infected tooth.

Bacteria most often recovered from infected vital pulps are:

- Streptococci
- Staphylococci
- Diphtheroids, etc.

### **II. Mechanical irritants**

Examples of mechanical irritation include trauma, operative procedures, excessive orthodontic forces, subgingival scaling and overinstrumentation using root canal instruments.

### **III. Chemical irritants**

Pulpal irritation may result from bacterial toxins or some restorative materials/conditioning agents. Peri-radicular irritation may occur from irrigating solutions, phenol-based intra-canal medicaments or extrusion of root canal filling materials.

### **IV. Radiation injury to pulp**

Radiation therapy affect pulps of fully formed teeth in patients exposed to radiation therapy. The pulp cells exposed to ionizing radiation may become necrotic, there may occur vascular damage and the interference in mitosis of cells.

### **Classification of Pulp Disease**

Diagnosis of pulp disease is usually based on patient symptoms and clinical findings. Pulpal disease may result in changes to both the soft and hard tissues.

#### **Soft tissue changes**

***Reversible pulpitis (Pulpal Hyperaemia):*** It is a transient condition that may be precipitated by any insult (ex. caries) to the pulp and characterised by increase in vascular vasodilation.

The symptoms are usually:

- Pain needs an external stimulus and it subsides immediately after removal of stimulus.
- Pain is difficult to localise (as the pulp does not contain proprioceptive fibres).
- Normal periradicular radiographic appearance.
- Teeth are not tender to percussion but sensitive to cold stimulus.

Treatment involves covering up exposed dentine, removing the stimulus or dressing the tooth.

***Irreversible pulpitis:*** Irreversible pulpitis usually occurs as a result of more severe insults than in the reversible pulpitis. It may develop as a progression from a reversible state.

1) **Acute pulpitis.** The pulp experiences increased inflammatory process and intrapulpal pressure. The symptoms experienced are:

- Severe pain develops spontaneously or from stimuli which may last from minutes to hours.



- Heat stimulus increases pain due to expansion of blood vessels therefore increasing pressure in the pulp.
- Cold stimulus decreases pain due to contractile action on the blood vessels therefore lowering intrapulpal pressure
- Not tender to percussion and normal radiographic apical region.
- a widened periodontal ligament may be seen radiographically in the later stages.

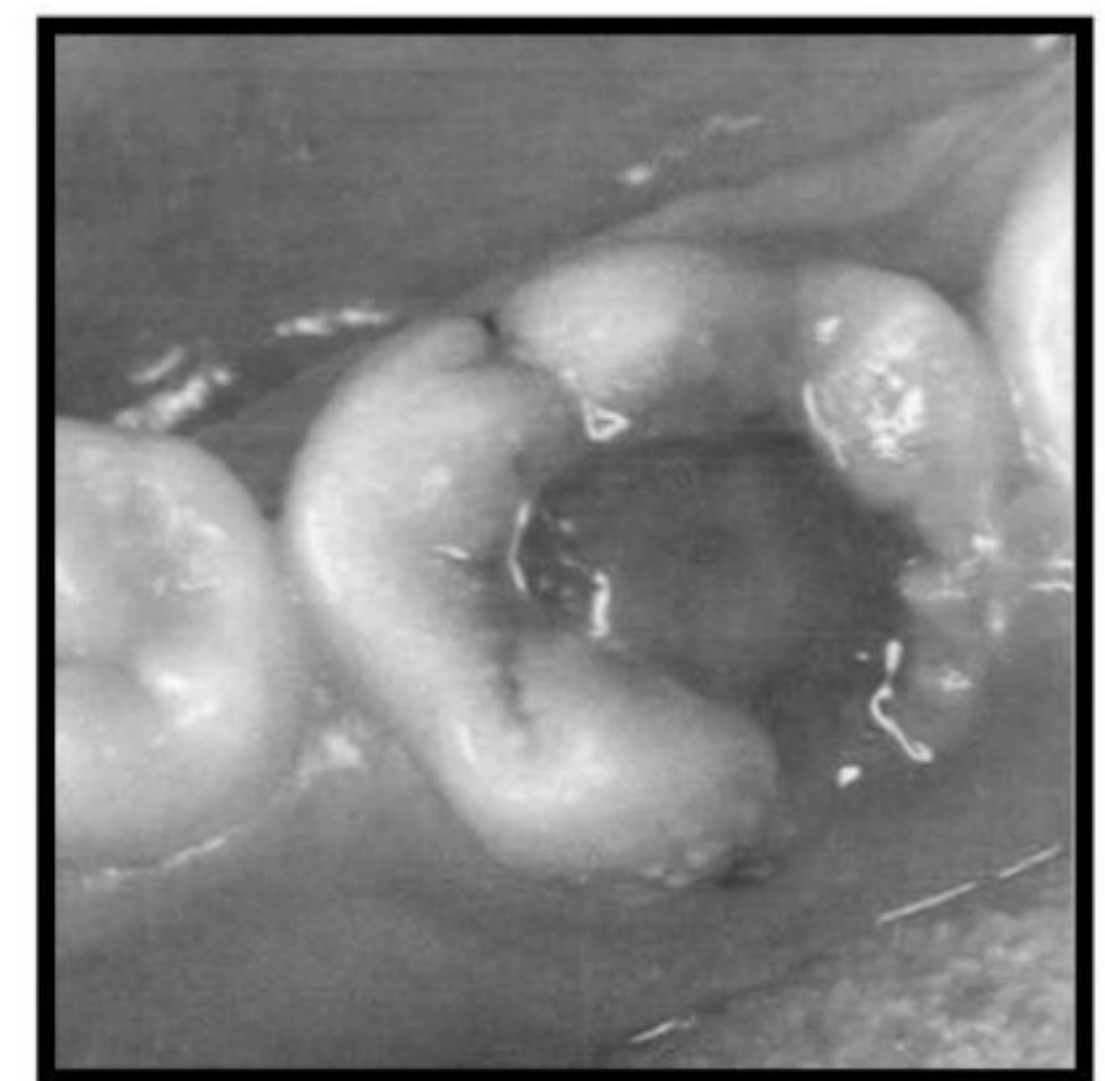
Treatment involves either root canal therapy or extraction of the tooth.

2) Chronic pulpitis. After the acute phase the pulp might enter the chronic phase. The symptoms experienced are:

- Mild to moderate intermittent pain may be tolerated by the patient for long period of time.
- Thermal tests are of little value.
- Tenderness to percussion and radiographic changes are not seen until infection reaches the periapical region.

Treatment involves either root canal therapy or extraction of the tooth.

***Hyperplastic pulpitis:*** Hyperplastic pulpitis is a form of irreversible chronic pulpitis and is also known as a **pulp polyp**. It occurs as a result of proliferation of chronically inflamed young pulp tissue. Treatment involves root canal therapy or extraction.

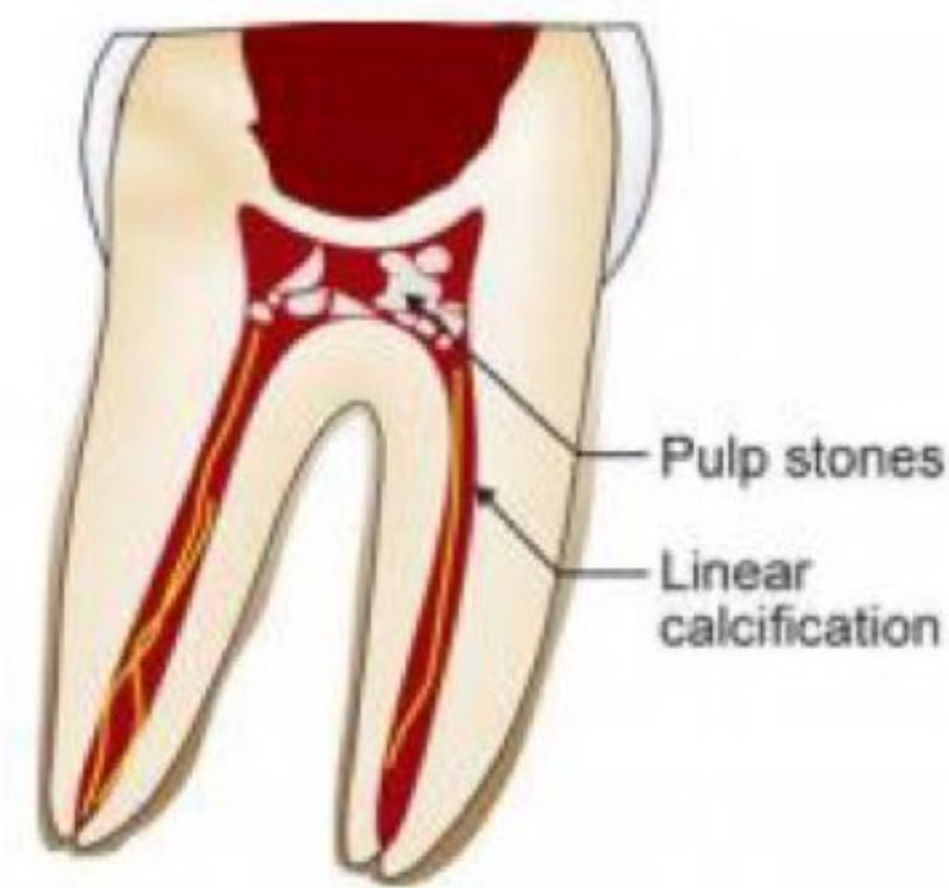


***Pulp necrosis:*** Pulp necrosis occurs as the end result of irreversible pulpitis; treatment involves root canal therapy or extraction.

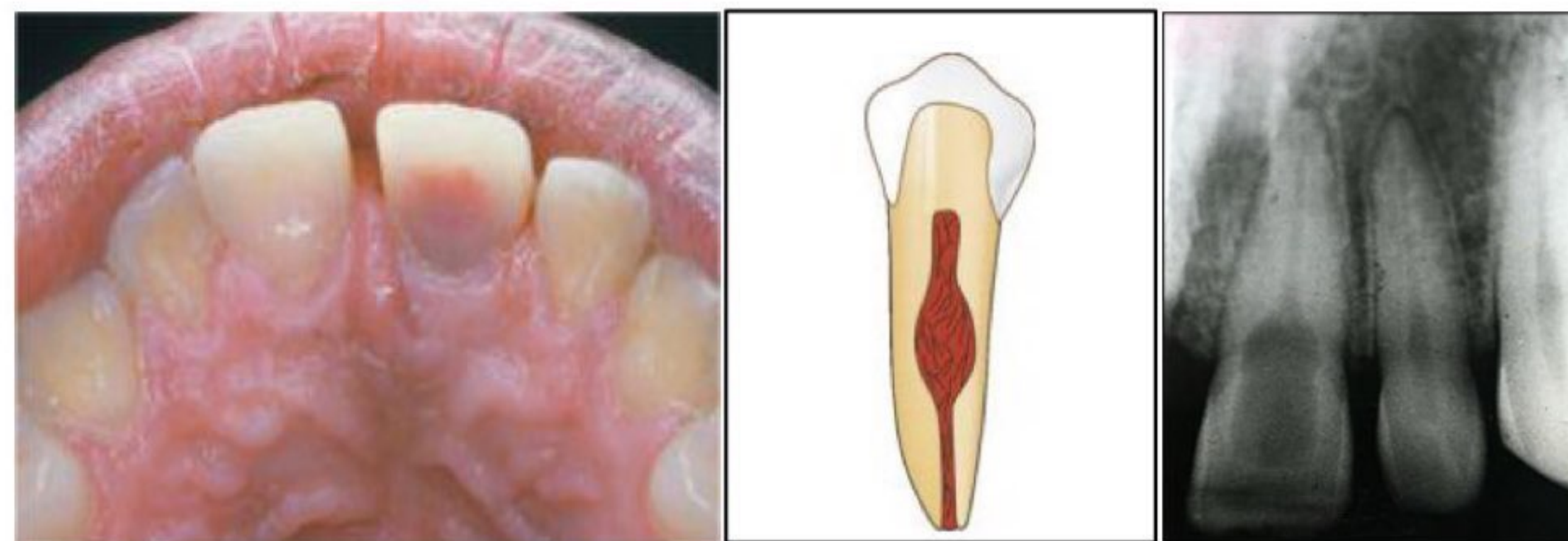
### **Hard tissue changes**

***Pulp calcification:*** Physiological secondary dentine is formed after tooth eruption and the completion of root development. It is a condition in which hardening, or calcification, of pulp tissue results in hypersensitivity and extreme pain because the dental nerves become compressed. A root canal is usually necessary to clear away hardened tissue. Pulp calcification is deposited on the floor and ceiling of the pulp chamber rather than the walls and with time can result in occlusion of the pulp chamber. Pulp calcification may be composed of irregular dentine (true denticle) or due to ectopic calcification of pulp tissue (false denticle). Tertiary dentine is laid down in response to environmental stimuli as

reparative dentine where it is deposited directly beneath the path of injured dentinal tubules as a response to strong noxious stimuli. Treatment is dependent upon the pulpal symptoms.



**Internal resorption:** Internal resorption is initiated within the pulp cavity and results in loss of substance from dentinal tissue. Occasionally, pulpal inflammation may cause changes that result in dentinoclastic activity. Such changes result in resorption of dentine; clinically, a pink spot may be seen in the later stages if the lesion is in the crown. Radiographic examination reveals a radiolucency that is seen to be continuous with the rest of the pulp cavity. Root canal therapy will result in arrest of the resorptive process; however, if destruction is very advanced extraction may be required.



### **Who performs an endodontic therapy?**

Generally, all dentists receive basic education in endodontic treatment but an endodontist is preferred for endodontic therapy. General dentists often refer patients needing endodontic treatment to endodontists.

### **Why does patient Feel Pain?**

When pulp becomes infected, it causes increased blood flow and cellular activity, and pressure cannot be relieved from inside the tooth. This causes pain. Pulp can even die without causing significant pain; it may depend on pain threshold and pain reaction of the patient.

### **How can You Tell if Pulp is infected?**

When pulp gets inflamed, it may cause toothache on taking hot or cold, spontaneous pain, pain on biting or on lying down. On occasion a damaged pulp is noticed by drainage, swelling, and abscess at the root end (Fig. 2). Sometimes, however, there are no symptoms.

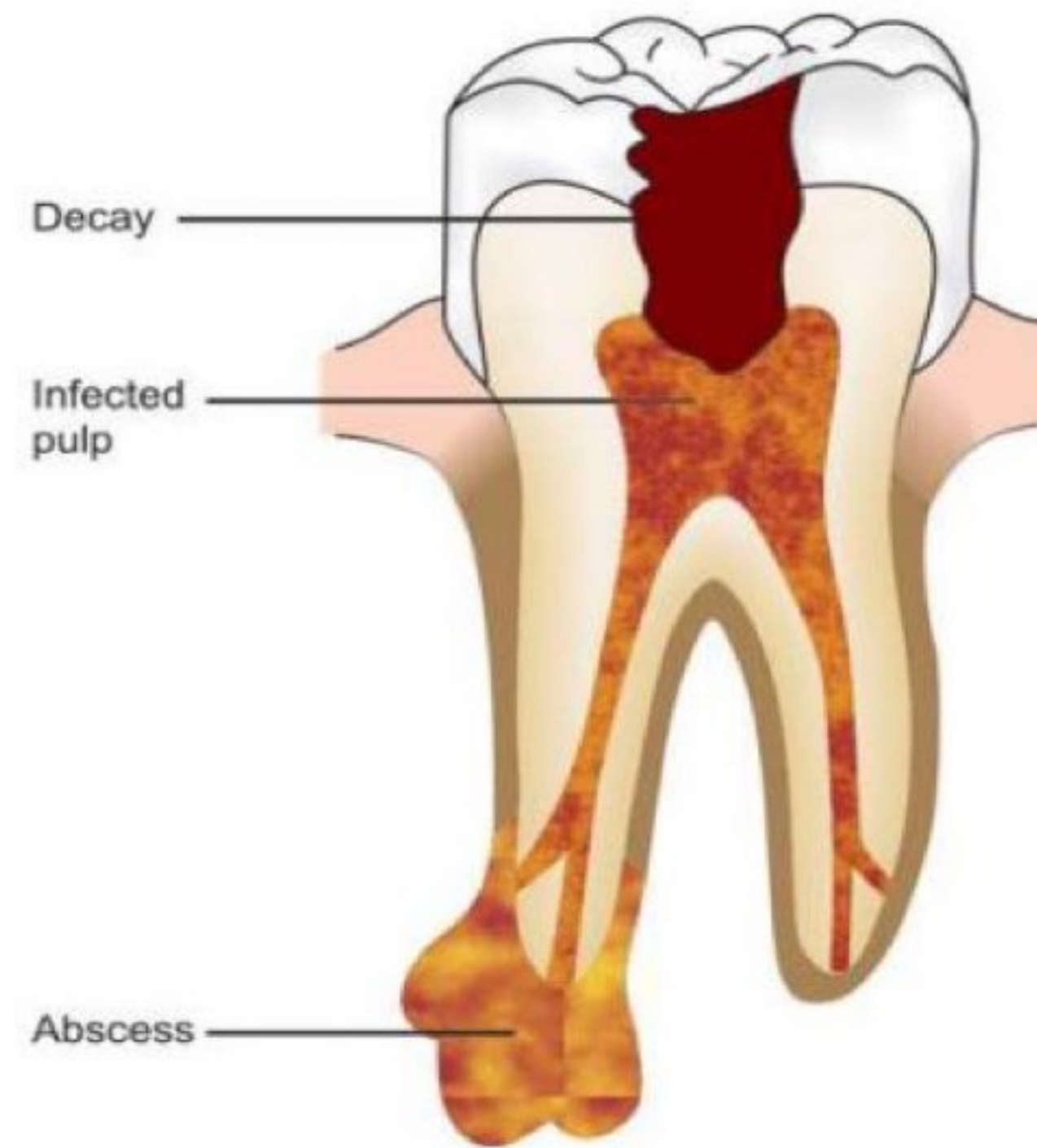


Figure 2. Tooth with infected pulp and abscess formation

### **Why does patient Need Root Canal Therapy?**

Because tooth will not heal by itself, the infection may spread around the tissues causing destruction of bone and supporting tissue. This may cause tooth to fall out. Root canal treatment is done to save the damaged pulp by thorough cleaning and shaping of the root canal system and then filling it with gutta-percha (rubber like) material to prevent recontamination of the tooth. Tooth is permanently restored with crown with or without post.

### **What are Alternatives to Root Canal Therapy?**

If tooth is seriously damaged and its support is compromised, then extraction is only alternative.

### **What is Root Canal Treatment Procedure?**

Once the endodontic therapy is recommended, your endodontist will numb the area by injecting local anesthetic. After this a rubber sheet is placed around the tooth to isolate it. Then the opening is made in the crown of the tooth and very small sized instruments are used to clean the pulp from pulp chamber and root canals (Fig. 2). After thorough cleaning and shaping of root canals (Fig. 3), they are filled with rubber like material called gutta-percha, which will prevent the bacteria from entering this space again (Figs 4 and 5). After

completion of endodontic therapy, the endodontist places the crown or other restoration so as to restore the tooth to full function (Fig. 6).

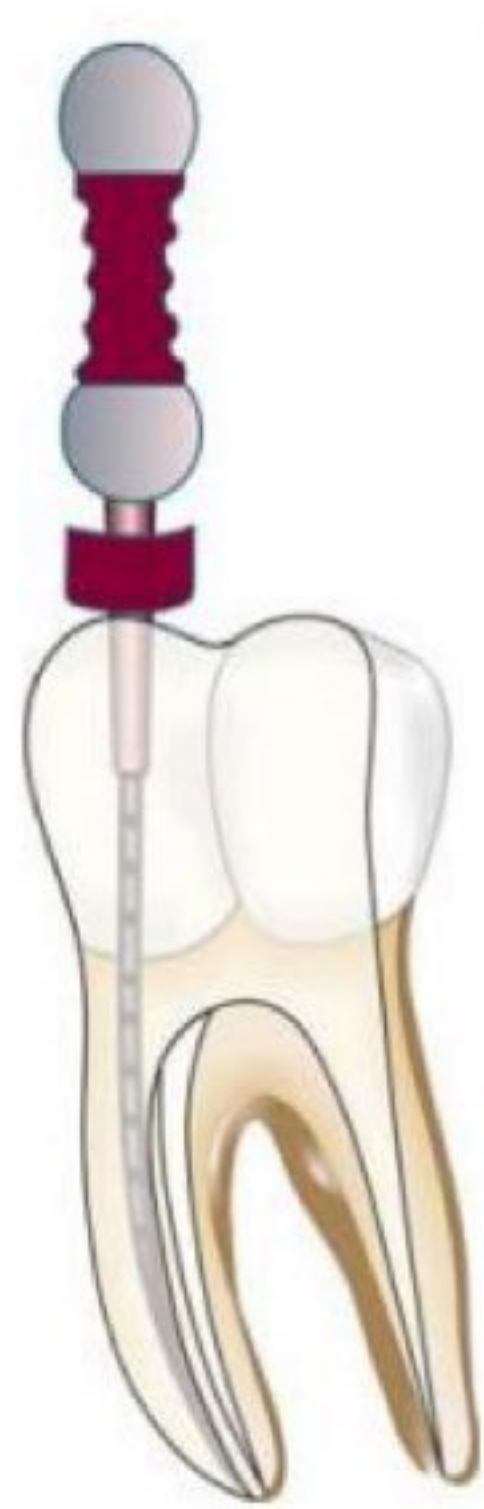

Figure 2. Cleaning and shaping of root Canal system

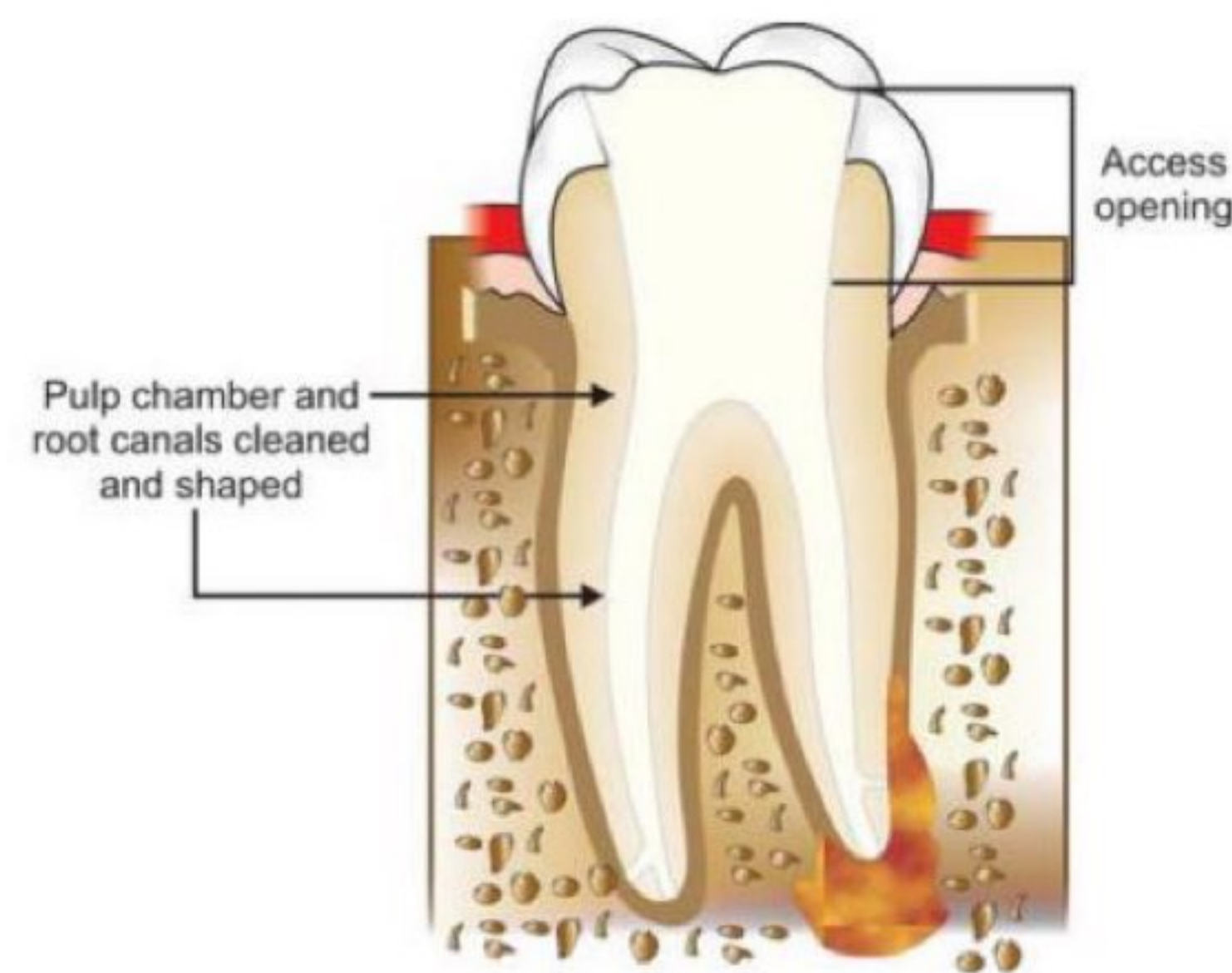


Figure 3. Cleaned and shaped tooth

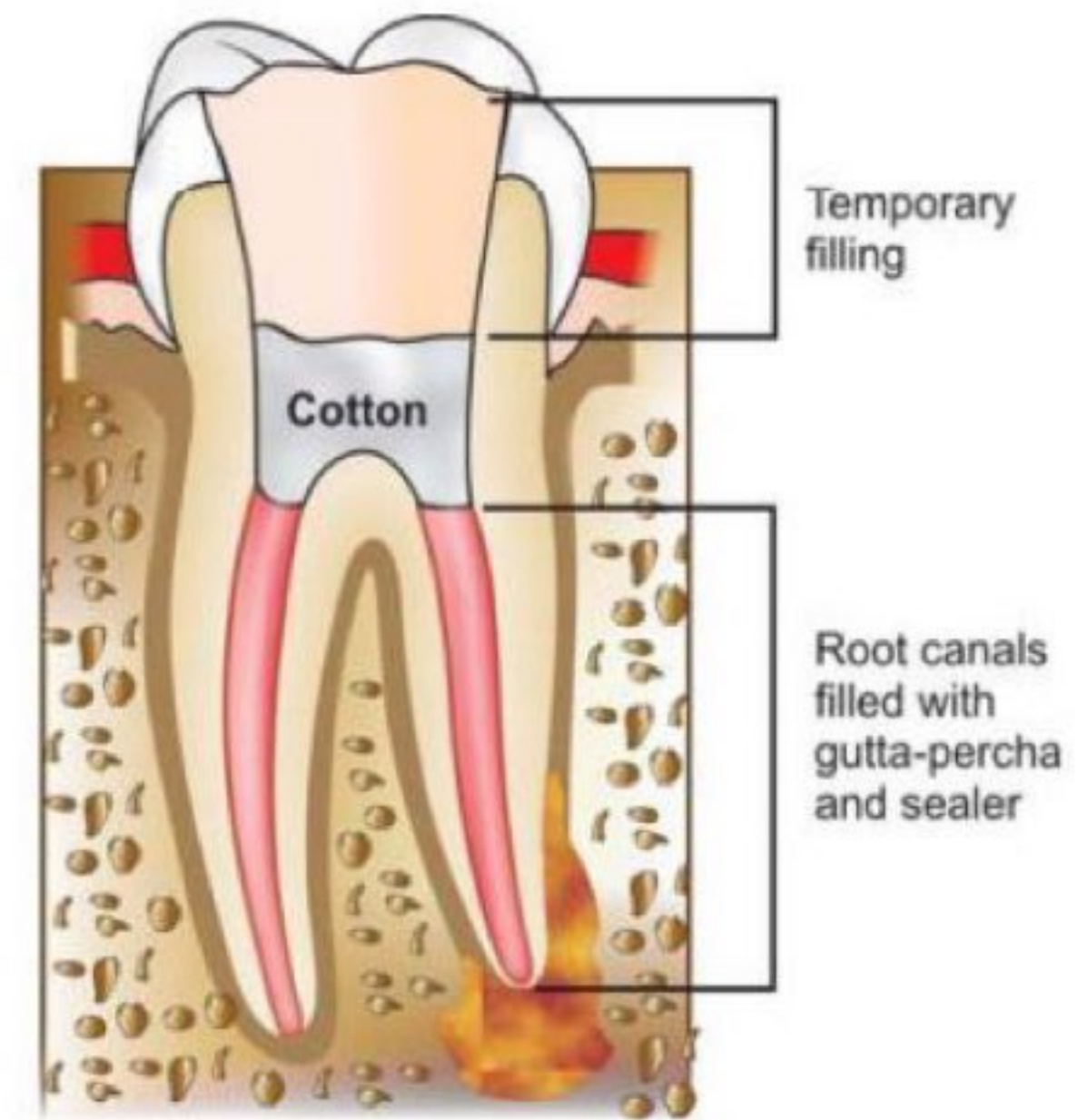


Figure 4. Obturation of root canal system

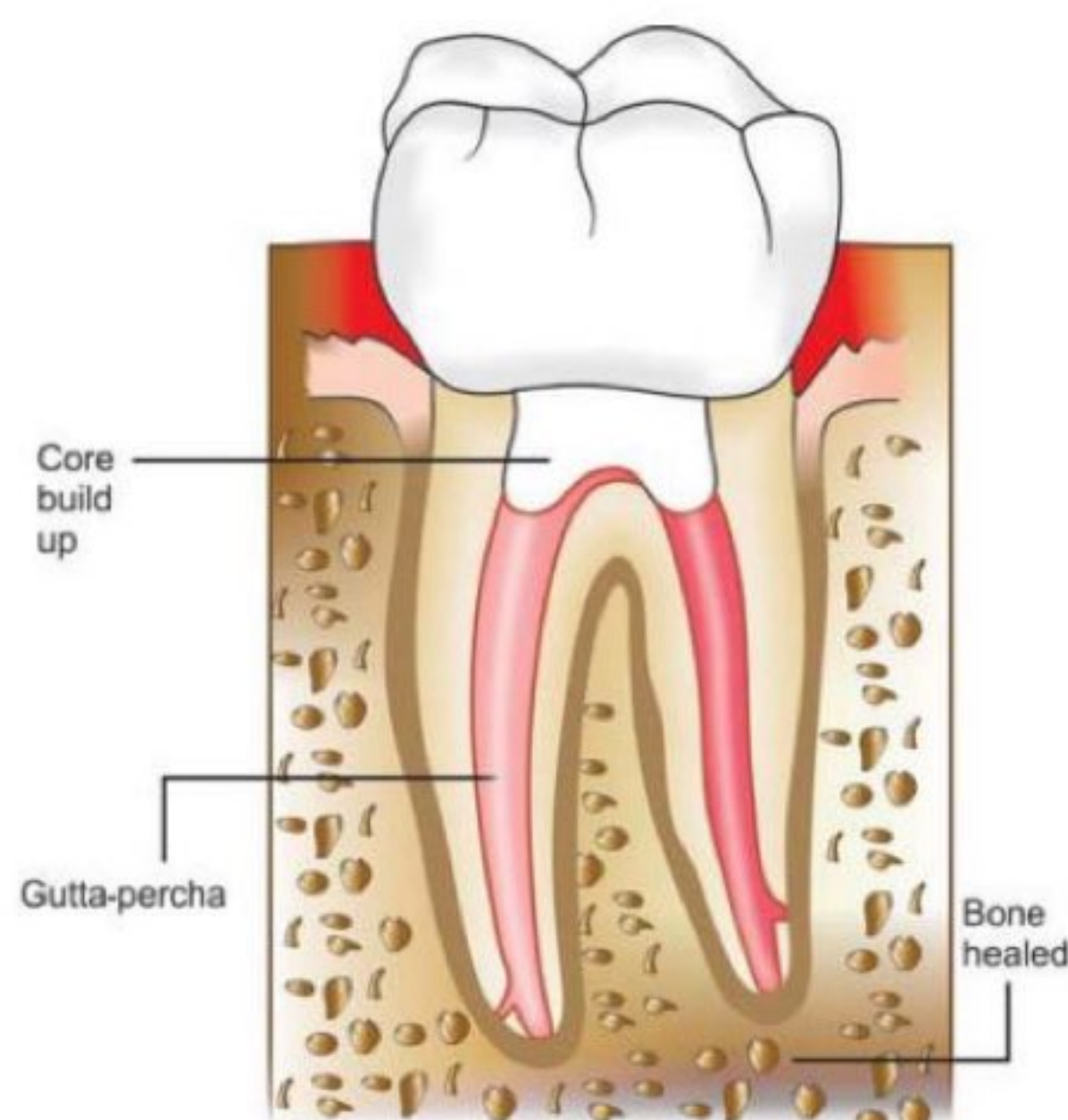


Figure 5. Complete restoration of tooth with crown placed over the restored tooth

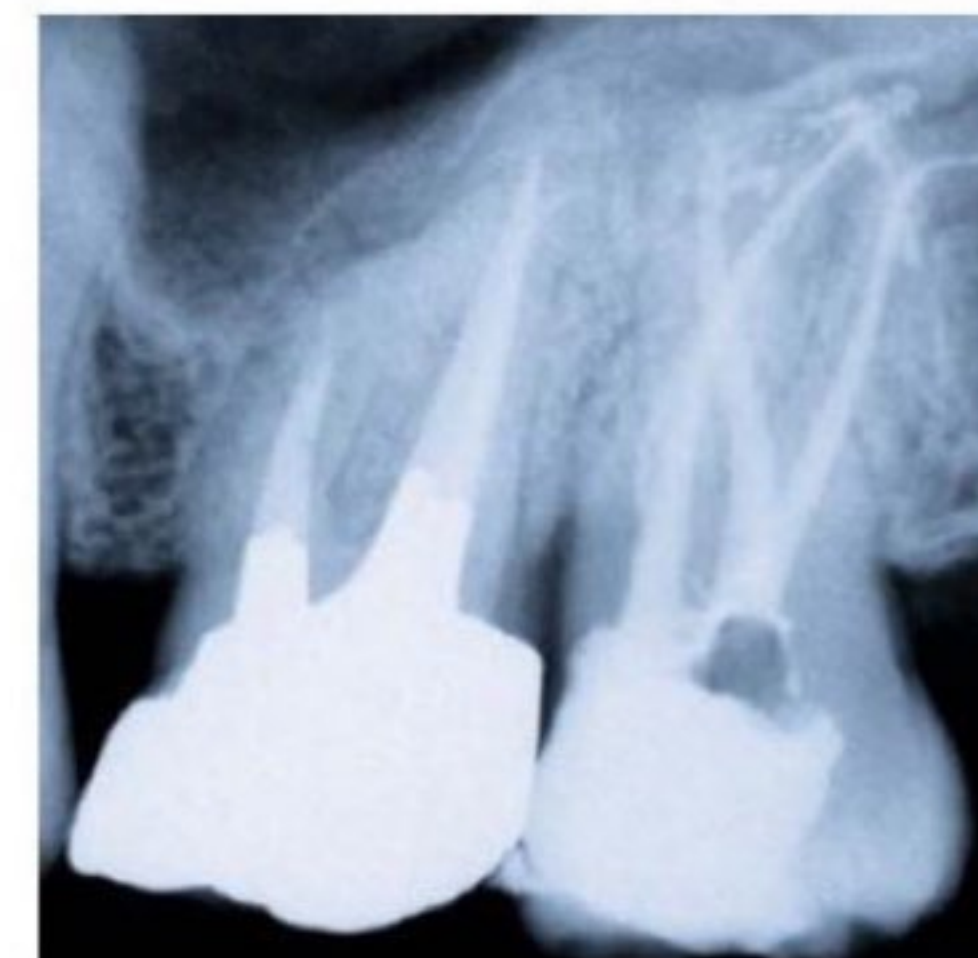


Figure 6. Complete root canal treatment

### **Will the Tooth Need Any Special Care or Additional Treatment after Endodontic Treatment?**

Patient should not chew or bite on the treated tooth until the patient has had a tooth restored by the dentist. The non-restored tooth is susceptible to fracture, so patient should visit the dentist for a full restoration as soon as possible not more than one month. Most endodontically treated teeth last as long as other natural teeth. In a few cases, a tooth that has undergone endodontic treatment does not heal or the pain continues. Occasionally, the tooth may become painful or diseased months or even years after successful treatment. Often when this occurs, re-treating the endodontic procedure can save.

### **Can All Teeth be Treated Endodontically?**

Most of the teeth can be treated endodontically. But sometimes when root canals are not accessible, root is severely fractured, tooth cannot be restored or tooth doesn't have sufficient bone support, it becomes difficult to treat the tooth endodontically. However, advances in endodontics are making it possible to save the teeth that even a few years ago would have been lost. Newer researches, techniques and materials have helped us to perform the endodontic therapy in better way with more efficiency. Since introduction of rotary instruments and other technologies reduce the treatment time, the concept of single visit is gaining popularity nowadays. It has been shown that success of endodontic therapy depends on the quality of root canal treatment and not the number of visits. In the modern world, single visit endodontics is becoming quite popular.

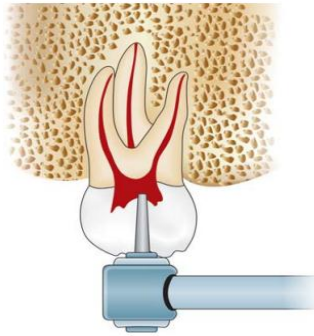
# ENDODONTICS

## Lecture 3

### Access Opening Preparation

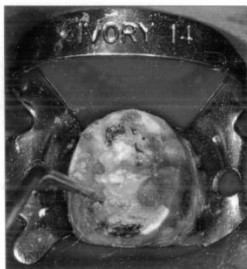#### Guidelines for access cavity preparation:

- 1) Study the preoperative radiograph: It gives information about the size, shape, number and curvature of the root canals and roots. One should check the depth of preparation by aligning the bur and handpiece against the radiograph.

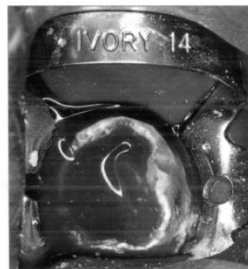

Preoperative radiograph can help to note the position and depth of pulp chamber

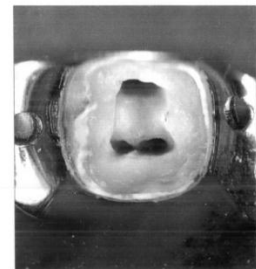
- 2) Excavate all the carious lesions: No caries should be left in the tooth, because microorganisms of the carious lesion may be introduced inside the canal and infection might occur.
- 3) Replace any defective filling: The defective filling should be replaced before beginning the access opening because it will not ensure proper seal of the tooth.
- 4) Remove unsupported tooth structure: Any weak tooth structure might fracture that causes loss of the seal of the tooth and the reference point which changes the length of the tooth.



2.40 Gross caries



2.41 Carious exposure with hyperaemic pulp



2.42 Pulp extirpated and canals prepared

### **Burs used for access cavity preparation**

Access opening burs: they are round burs with 16mm bur shank (3mm longer than standard burs).



Access refining burs: these are coarse flame-shaped, tapered round and diamonds for refining the walls of access cavity preparation



### **Procedure of Access Opening for Anterior Teeth:**

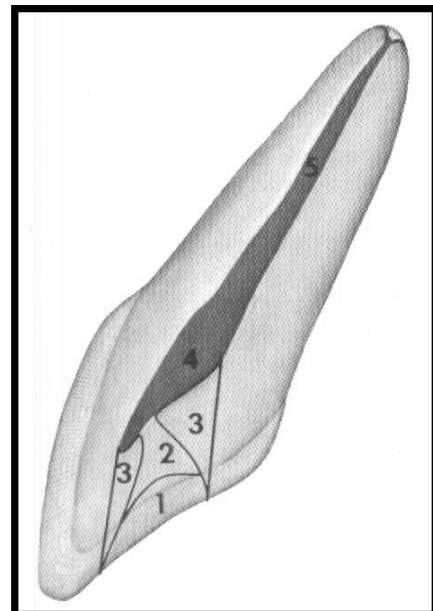
1) Entrance is always gained through the lingual surface of all anterior teeth. The initial penetration is prepared in the exact center of the tooth above the cingulum (in the center of the middle third).

2) The initial entry in the enamel is done by a round bur no. 4 operated at a right angle to the long axis of the tooth. The guide for enamel penetration is that only the head of the round bur no. 4 should enter the tooth.

The direction of the bur is changed to be parallel to the long axis of the tooth, and drill until the entrance to the pulp chamber. We can know that we reached the pulp chamber when we feel a fall in the resistance to the bur, i.e. the bur falls into a space which is the pulp.

3) Remove the roof of the pulp chamber by working from inside the chamber towards the outside of the chamber (pulling motion).

4) Lingual shoulder is removed by moving the bur from inside towards the outside to give a continuous smooth flaring preparation. Lingual shoulder is a convexity inside the pulp chamber.



- 5) Finishing and funneling with a fissure bur. The final shape funnels down to the orifice of the canal and flare outwards.
- 6) Extirpate the pulp by introducing an instrument called the barbed broach in the root canal and by outward movement the barbed broach will catch the pulp and remove it from the root canal.
- 7) Irrigation of the pulp chamber.

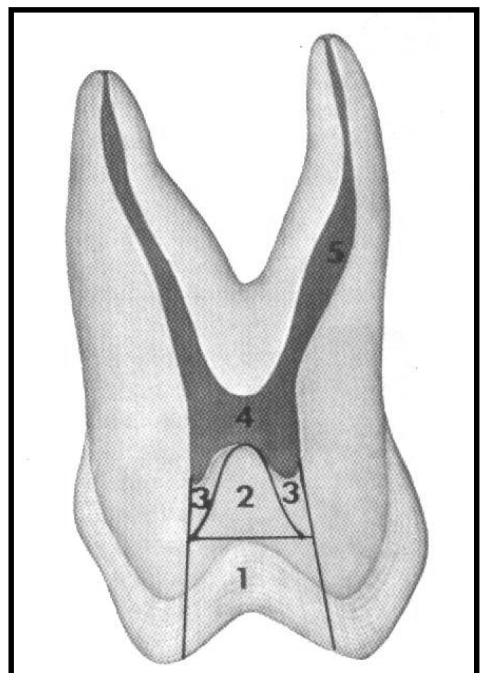
The pulp horns should be eliminated with a round bur no. 2 used laterally and incisally, because if they remain, remnants of necrotic tissue would cause discoloration to the anterior teeth.

**Procedure of Access Opening for Premolars:**

- 1) Access is always gained through occlusal surface of all posterior teeth at the center of the central groove. Initial penetration is made parallel to the long axis of the tooth into the exact center of the central groove.
- 2) A round bur no. 2 or 4 is used to open into the pulp chamber. The bur will be felt to drop if the pulp is reached.
- 4) We extend into the cavity bucco-lingually by removing the roof of the pulp chamber, working from inside the cavity to the outside (pulling motion).
- 5) Finishing the cavity walls is done with a fissure bur.

The final access opening would be ovoid in shape buccolingually which reflects the anatomy of the pulp chamber and position of the buccal and lingual canal orifices.

- \* The pulp chamber of the lower premolars is buccally located rather than lingually so we start access opening and push more buccally.
- \* Access for upper premolars: There are 2 canals, the buccal canal is approached palatally, and the palatal canal buccally.
- \* Floor of the pulp chamber should not be reached.

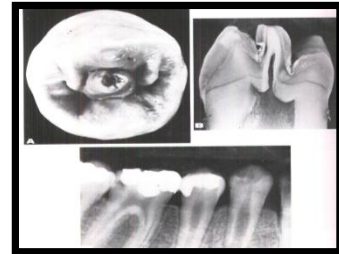




### **Anomalies of pulp cavities:**

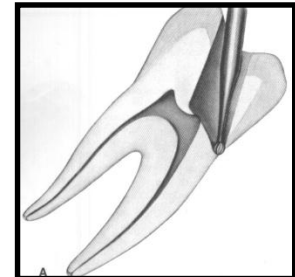
We have certain anomalies which interfere with root canal treatment. ex: calcification or complete obliteration of root canal, open apices, etc ...

- 1- Dentinogenesis imperfecta: There is a small pulp chamber with root canal obstruction.
- 2- Hyperparathyroidism: There is a calcified pulp chamber and loss of lamina dura.
- 3- Hypofunction of pituitary gland: There is a retarded eruption of the teeth and the apices of the root will be opened.
- 4- Dentinal dysplasia: There is an obliteration of the pulp chamber and the root formation is defected.
- 5- Shell teeth: The pulp chamber is quite big with short root.
- 6- Dense invagination: There is an improper shape of root canal.

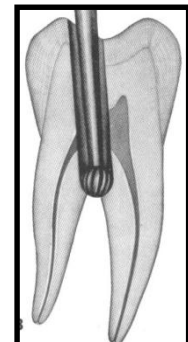


### **Errors in Access Opening:**

- 1- **Perforation**: It is common when drilling is continued apically or laterally after we reach the pulp chamber. It is mostly seen in:
  - a) Old patients. It is due to pulp recession.
  - b) Teeth restored by crowns, inlays or big restorations. It is difficult to know the long axis of the tooth so it is better to remove the restoration and work.
  - d) Tilted teeth.
  - e) Failure to complete a convenient extension.

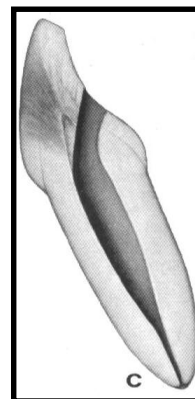


- 2- **Cutting more apically**: It will lead to flattening of the floor of the pulp chamber and this will weaken the tooth structure which will cause:
  - a) Losing the funneling shape of the canal orifice.
  - b) Perforation into the furca.
  - c) Gouging: Going laterally in the access opening, so the wall of the cavity will not continue with the wall of the root canal.

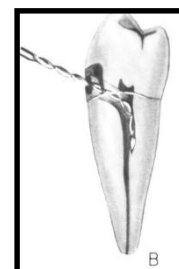


3- **Narrow access opening.** This will cause incomplete pulp extirpation and instrumentation through the pulp chamber or pulp horn. This is identified by:

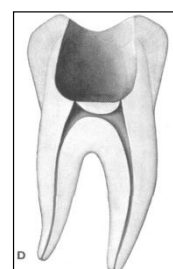
- a) Severe bleeding.
- b) Change of the colour of the floor dentin, to dark blue.
- c) Anatomical landmarks of the floor of pulp chamber, which are convex floor and presence of grooves connecting the canal orifices, are not seen clearly.
- d) If a probe is placed in the pulp chamber and pulled against the walls and it catches in the pulp chamber then there is still roof of the pulp chamber, therefore indicating presence of remnants of pulp tissue.



4) **Entrance through labial surface.** This is sometimes performed due to severe crowding or caries in labial surface, or proximal surface if the adjacent tooth is missing. This type of access opening causes incomplete pulp extirpation.



5) **Over extended access opening preparation.** This access opening causes undermining and weakening of the enamel walls.

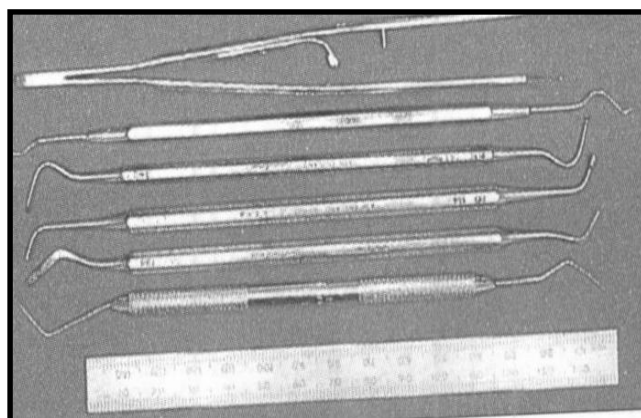


## **Endodontic Instruments:**

There are many instruments used in the different phases of endodontic treatment and they are as follows:


### **General Instruments**

- 1) Endodontic explorer: A double end instrument, one end is straight used to locate the root canal orifices after the removal of the pulp chamber, and the other end is L-shaped which aids in detecting the unremoved parts of the tooth

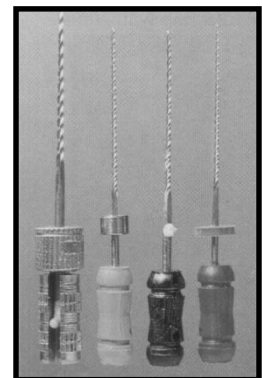


as the roof of pulp chamber.

- 2) Plastic instruments: It has two ends; the first is used to carry temporary filling material. The opposite end is used as a plugger to condense cement and base materials in the root canal.
- 3) Endodontic excavator: It is larger than a spoon excavator, used to allow excavation of the contents of the pulp chamber. It is also used in curettage of periapical lesions in surgical endodontics (apicectomy).
- 4) Endodontic locking pliers (tweezer): It has a lock that allows materials to be held without continuous finger pressure; also it has a groove which facilitates holding gutta percha and absorbing points.
- 5) Endodontic ruler: It is a metal ruler made of 0.5mm divisions. It is a convenient instrument to measure reamers, files and gutta percha.
- 6) Endodontic syringe: It is used to carry irrigating solution into the root canal. The tip of the instrument is flat to prevent penetration of the needle to the small canals; also it has a groove in its tip to permit the irrigation which might be under pressure to flow coronally rather than forcing it to the apical foramen causing post-operative pain.
- 7) Instrument organizer (endodontic kit): It is used for arrangement of reamers and files according to the size and length. The organizer provides holes for the files to be placed vertically in a sponge which is saturated with disinfectant to maintain its sterility.



- 8) Transfer sponge: It is sponge saturated with disinfectant solution. The reamers and files can be placed in it after being used.
- 9) Instrument stopper (rubber stopper): It is used to mark the length of the tooth on reamers and files; it should be perpendicular to the long axis of the reamer. It may be made of rubber or metal.



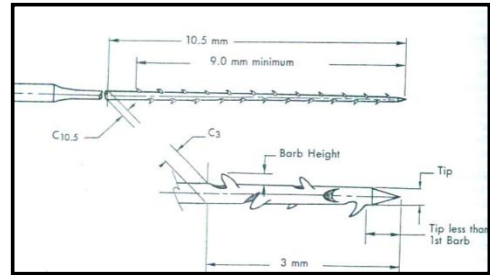
### **Intracanal Instruments:**

These instruments are used inside the root canal

## 1) Barbed broach.

This instrument is used inside the canal. It is a short handled instrument with a shaft having projections directed obliquely towards the handle. It is made of stainless steel, and used for pulp (vital pulp) extirpation, and removal of necrotic tooth debris inside the canal. It can be used to remove

cotton and paper points from the canal. It is used in straight parts of the canal and inserted freely (by using the suitable size) to the 2/3 of the pulp canal; otherwise, fracture of the instrument may occur.



### Technique of pulp extirpation (Healey, 1984)

Penetrate the barbed broach along the canal wall towards the apex



As it reaches to the apical constriction, move it into the center of mass of pulp tissue




Rotate the broach several times in a watch winding manner to entrap the pulp which is then withdrawn from the canal


## 2) K-Reamers and K-files.

These instruments are made of stainless steel, because it is more flexible than carbon steel and don't corrode, but nowadays, a super flexible material which is nickel-titanium is used. Reamers and files are manufactured by twisting a square bar to produce flutes but they differ in the number of flutes.


(a) Reamers are mostly used in reaming action and are less effective in filing action. Reamer = 0.5-1 flute/mm.



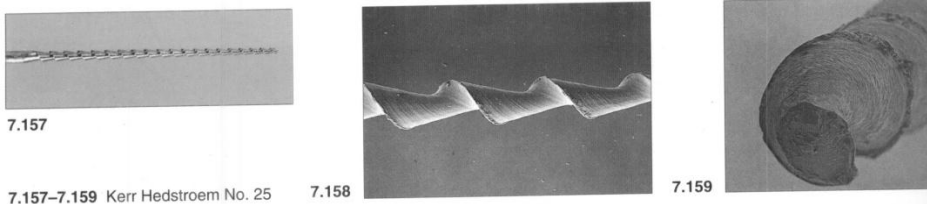
b) Files are less flexible than reamers. It is mostly used in filing action but can be used in reaming action. K file = 1.5-2.25 flute/mm,



(c) K flex file: It is a diamond cross section bar. It is more flexible and has sharper blades with non-cutting tip (blind tip).



(d) Hedstrom files: They are machined instrument that are made of stainless steel bar which are triangular in shape with very sharp edges. They are very active in just pulling action while K files are effective in both pulling and pushing action. It can not be used in rotation movement.




### Differences between reamers and files

Reamer	File
1- More flexible.	Less flexible.
2- Less no. of cutting flutes	More no. of cutting flutes
3- Used mainly in reaming action.	Used mainly in filing action.
4- Less effective in filing action because less no. of flutes.	Rotation Can be used in reaming action.
5- cutting motion is rotation and retraction	Push pull
6- Cross section is Triangular	Square
7. Round preparation shape	Ovoid

**Note:** Triangular cross-sectioned files show superior cutting and increased flexibility than the file or reamers with square blank

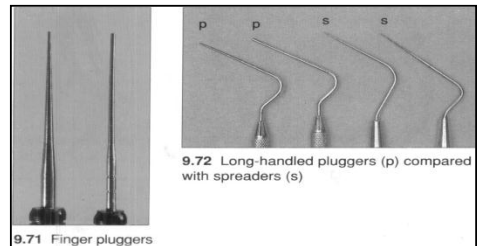
### **3) Spreader.**

It is a long, tapered and pointed end instrument, which is used to compress gutta percha into the apex and periphery of the prepared canal and also towards the irregularity of canals leaving a space for insertion of auxiliary root canal filling material cones. There is also a finger spread and long handled which is smaller and shorter to be used in posterior teeth.



### **4) Plugger**

It is a long and blunt flat tip blade instrument. It is necessary for vertical condensation technique and also plugging of gutta-percha at the termination of all other obturation condensation techniques. There are 2 types of pluggers, the long handled type and finger type.

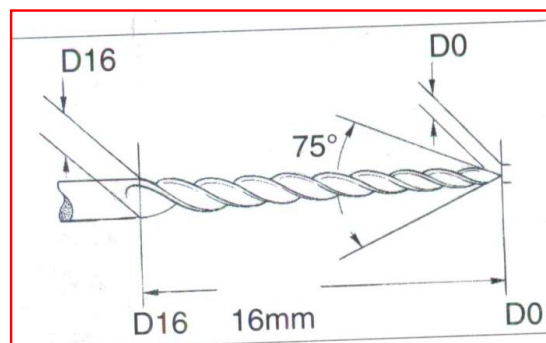


## **Standardization of Intracanal Instruments:**

Each instrument has a number which refers to the size of its tip. The reamer of size 30 means that  $D_0 = 0.3\text{mm}$ , while size 70 reamer means that  $D_0 = 0.7\text{mm}$ .

$$D_{16} = D_0 + 0.32 \text{ mm}$$

So in size 50 reamer, the tip ( $D_0$ ) is 0.5 mm while  $D_{16}$  is 0.82 mm. The distance between  $D_0$  and  $D_{16}$  is 16mm, but the total length differs from short to medium to long for anterior teeth, and the shorter ones for posterior teeth.

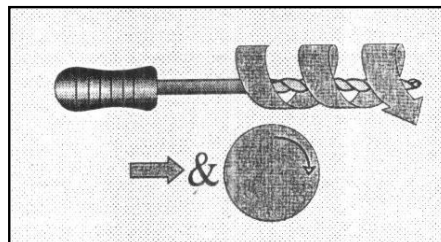


All intracanal instruments are color coded and each color represents a size. Pink= 6, Gray= 8, Purple= 10, White= 15, Yellow= 20, Red= 25, Blue= 30, Green=

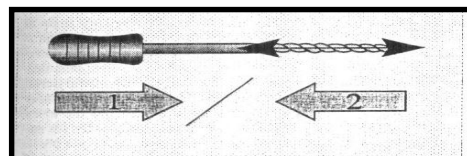
35, Black= 40, then the colour returns to White= 45, and so on to Blue= 60 and then the instruments increase by 10 as Green=70, Black=80, and so onto size 140.

### **Modes of action of Intracanal Instruments:**

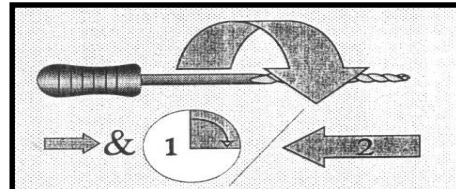
- 1) **Reaming action:** It is a repeated clockwise rotation of the instrument which will shave the canal walls and give a cross sectional preparation approximately round. Reamers are usually more effective for this function.



- 2) **Filing action:** It is a push-pull action without rotation which has a great efficiency with files than reamers. The cross sectional appearance of the prepared root canal is irregular with general oval configuration, so the canal must be filled with gutta percha.



- 3) **Quarter-turn filing:** This action is a combination of reaming and filing action. The instrument is inserted in the root with a quarter turn rotation ( $90^\circ$ ) then moved with dragging motion to produce an oval cross section. K-file and reamer can be used.



- 4) **Circumferential filing:** in this action, filing or quarter turn filing action is used with emphasis placed on the out stroke, so the file is dragged along different sides of the canal wall with each withdrawal. The resultant canal has a wide orifice with greater taper.

# ENDODONTICS

## Lecture 4



### The Rubber Dam and Its Applications

The rubber dam is a disposable aid in endodontic treatment for the following reasons:

- 1- It prevent accidental swallowing or aspiration of the small, easily dropped endodontic instruments.
- 2- It prevents intra canal irrigants from entering to the mouth because most of them are of unpleasant taste.
- 3- It helps to maintain a dry field of operation by eliminating salivary contamination.
- 4- It eliminates soft tissue interference by retracting the check & tongue.
- 5- It enhances better concentration of the dentist by showing only the tooth to be treated.

### Rubber Dam Materials

It comes in a variety of thickness, colors & sizes.

#### A) Thickness

- (i) Medium – weight: It is indicated in general all around in the mouth.
- (ii) Thin – weight: This thickness is indicated in lower anterior teeth & partially erupted posterior teeth.
- (iii) Heavy – weight: It has the advantage of providing great adaptation around the teeth & does not tear easily but it exerts much force on the lips & cheek

#### B) Color

- (i) Light. It provides better illumination of the field
- (ii) Dark. It provides a sharp contrast between the tooth & the dark background.

C) Size. The rubber dam comes in precut sheets of different dimensions.:



## Rubber Dam Frame

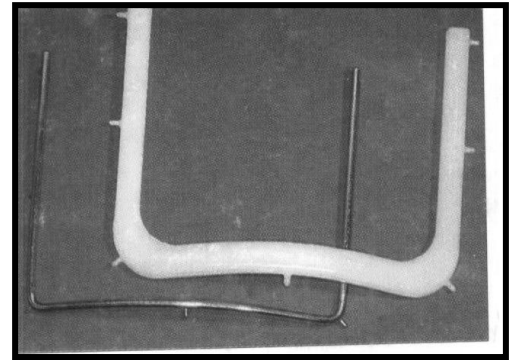
The purpose of rubber dam frame is to hold the rubber dam in a manner to:

- 1) Provide lip & cheek retraction.
- 2) Provide unobstructed access to the tooth to be treated.

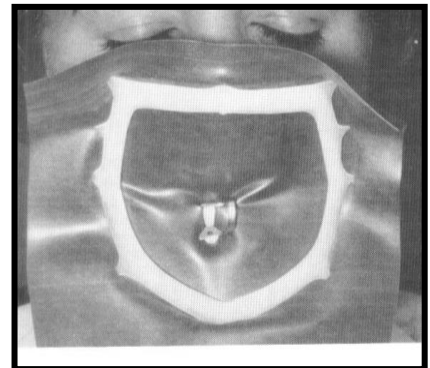
### Types

**1- Type A.** This is called **Young's frame**. It is U- shaped, and made of metal. It might interfere with the X- ray causing obscuring of important structure in the radiograph.

**2- Type B.** This is called **Starvisi frame**. It is a U- shaped frame, and made from radiolucent plastic & nylon materials. It is regarded as a suitable substitute for Young's frame.



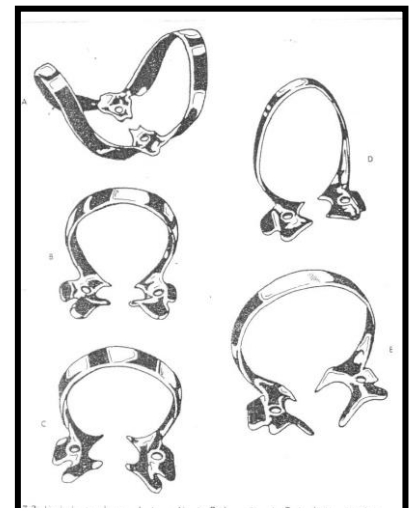
**3- Type C.** This is called **Nygaard – Ostby frame**. It is made from radiolucent plastic & nylon materials & can be left inside the patient's mouth while taking a radiograph without obstruction in the radiograph.



### Rubber Dam Clamps


The R.D. clamp is used to grasp the tooth needed to be endodontically treated and secure the rubber dam material and frame in place. There are many types of R.D. clamps, and each one of them is placed in a different tooth or region.

Type of Clamp	Used for
Ivory No. 9	Incisors and bicuspid
Ivory No. 1	Bicuspid
Ivory No. 26	Molars
Ivory No. 0	Incisors and cuspids Multiple isolation
Ivory No. 14A	Molars (partially erupted, badly broken-down, when other clamps fail)



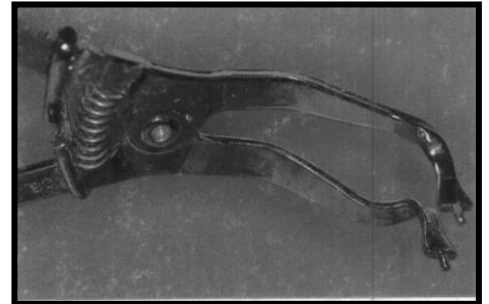
## Rubber Dam Puncture

It is an instrument used to create a hole in rubber dam. The hole should be clear without any tags or tears. The size of the hole punched or created depends on the tooth to be isolated. The puncture provides this hole to give maximum adaptation of the rubber dam around the tooth.



## Clamp Holder

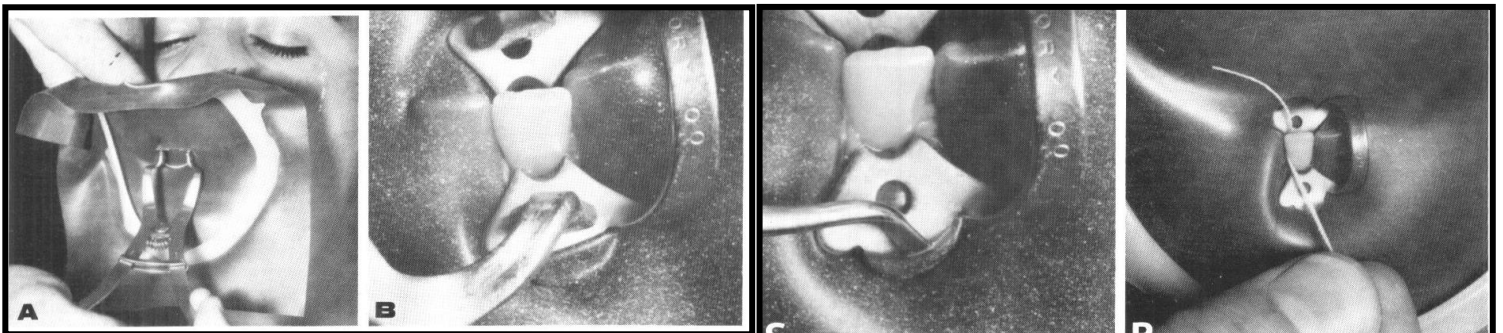
Sometimes it's called a forceps. This holder or forceps is used to place the clamp on the tooth by grasping the R.D. clamp from 2 lateral holes and widening the clamp to fit on the tooth.



## Methods of Applying The Rubber Dam

### Method 1: Application of the clamp & rubber dam together

- Select the suitable clamp to be used.
- Insert the wing in the hole after stretching the rubber dam on the frame with the forceps.
- Apply the clamp on the tooth.
- Release the wing from the dam.
- Restretch the rubber dam on the frame tightly to provide a good retraction to lips & cheek.
- Swab the isolated tooth & the adjacent dam with a suitable disinfectant .



### Advantages

- 1- Easy & fast.
- 2- It doesn't require the aid of assistance.
- 3- If the clamp snaps during placement, it's held by the dam.

### Disadvantage

- 1- It doesn't permit direct visualization of the tooth & soft tissues during placement.

### Method 2 – Application of clamp & then dam.

- Select the suitable clamp to be used.

- Place the clamp on the tooth.
- Stretch the dam on the frame.
- Draw the dam over the clamp.

#### Advantages

- 1-It allows unobstructed visualization of the tooth & surrounding tissues during clamp placement.
- 2- Its most efficient method of dam placement if there's difficulty in securing the clamp.

#### Disadvantages

- 1- Tearing of the dam.
- 2- Dislodgment of clamp during rubber dam drawing.

#### **Method 3 – Application of dam & then the clamp.**

- Select the suitable clamp to be used.
- Stretch the dam on frame.
- Apply the dam on the tooth.
- While retracting the dam to expose the tooth & the adjacent gingiva, place the clamp on the tooth.

#### Advantages

- There's little tendency to dislodgement of the clamp during placement.
- It provides direct visualization of the tooth & adjacent gingiva.

#### Disadvantage

- It needs help of assistance especially in post. teeth as the mandibular molars.

# ENDODONTICS

## Lecture 5



### Radiography in Endodontics:

There are many applications of radiographs in endodontics including:

- 1) Aid in the diagnosis and localization of hard tissue alteration of the tooth (sclerosis and resorption) and periradicular structures.
- 2) Determine the number, location, size, shape and direction of roots and root canals.
- 3) Estimate and confirm the length of root canals prior to instrumentation.
- 4) Determine the relative position of structures in facial or lingual dimensions.
- 5) Confirm the position and adaptation of the filling points.
- 6) Assess the outcome of root canal treatment

### Working length determination of Teeth:

Determination of an accurate working length is one of the most critical steps of endodontic therapy. The cleaning, shaping and obturation of the root canal system cannot be accomplished accurately unless working length is determined precisely. According to endodontic glossary working length is defined as “the distance from a coronal reference point to a point at which canal preparation and obturation should terminate”.

### **Objective of the working length**

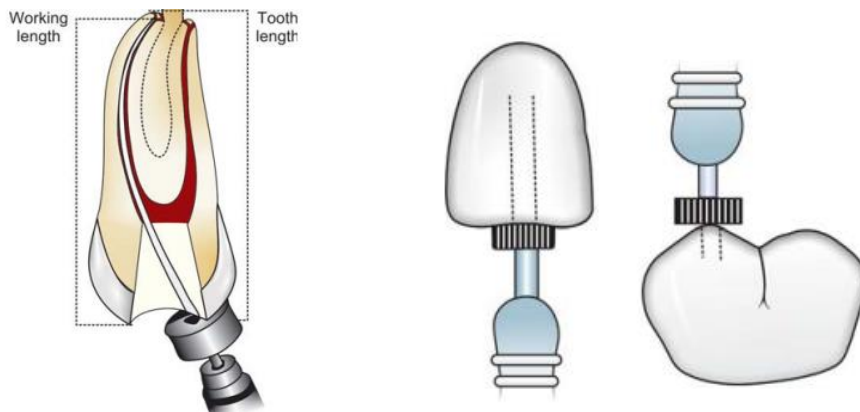
To establish the length of the tooth at which the canal preparation and subsequent obturation are to be completed. The apical end of the root canal is the CDJ, which is usually 0.5-1mm short of the radiographic apex. Sometimes the apical foramen is laterally positioned so it would be more than 1 mm from the radiographic apex.

	Maxillary	Mandibular
Central incisor	22.5	20.7
Lateral incisor	22.0	21.1
Canine	26.5	25.6
First premolar	20.6	21.6
Second premolar	21.5	22.3
First molar	20.8	21.0
Second molar	20.0	19.8

*From Black<sup>6</sup>*

**Reference point:** It is the site on the incisal edge or occlusal surface from which measurements are made. Usually it's the highest point on the incisal edge in anterior teeth & the tip of the cusp in posterior teeth. It should be:

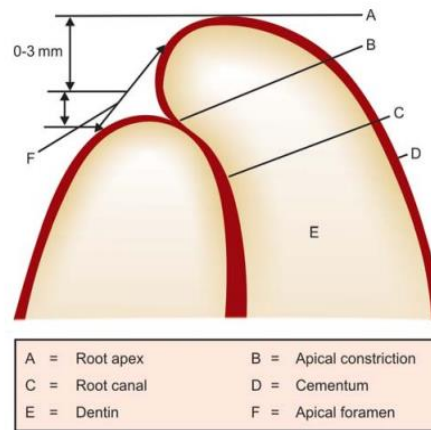
- 1) Stable
- 2) Easily visualized during preparation
- 3) Not changing during or between appointment.



Before we discuss various methods of determination of working length, we need to understand the anatomic consideration regarding it.

1. Anatomic apex is “tip or end of root determined morphologically”.
2. Radiographic apex is “tip or end of root determined radiographically”.
3. Apical foramen is main apical opening of the root canal which may be located away from anatomic or radiographic apex.
4. Apical constriction (minor apical diameter) is apical portion of root canal having narrowest diameter. It is usually 0.5 -1 mm short of apical foramen. The minor diameter widens apically to foramen, i.e. major diameter.

5. Cementodentinal junction is the region where cementum and dentin are united, the point at which cemental surface terminates at or near the apex of tooth. It is not always necessary that CDJ always coincide with apical constriction. Location of CDJ ranges from 0.5 - 3 mm short of anatomic apex



### **Consequences of over-extended working length**

- Perforation through apical construction
- Over instrumentation
- Overfilling of root canal
- Increased incidence of postoperative pain
- Prolonged healing period
- Lower success rate due to incomplete regeneration of cementum, periodontal ligament and alveolar bone.

### **Consequences of working short of actual working length**

- Incomplete cleaning and instrumentation of the canal
- Persistent discomfort due to presence of pulpal remnants
- Underfilling of the root canal
- Incomplete apical seal
- Apical leakage which supports existence of viable bacteria, this further leads to poor healing and periradicular lesion.

# DIFFERENT METHODS OF WORKING

## LENGTH DETERMINATION

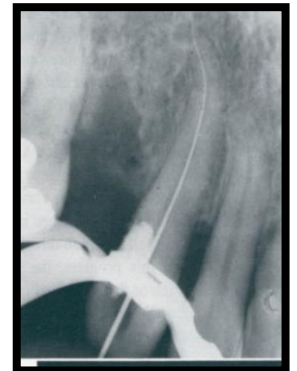
Various methods for determining working length include using average root lengths from anatomic studies, preoperative radiographs, tactile sensation, etc. Other common methods include use of paper point, working length radiograph, electronic apex locators or any combination of the above.

### 1. RADIOGRAPHIC METHOD OF WORKING LENGTH DETERMINATION

---

#### Procedure of Working Length determination

- 1- Examine preoperative radiograph & estimate the length of the tooth.
- 2- Know the average length of each tooth.
- 3- Place the file selected to be the correct initial width into the canal with it's rubber stopper set at the estimated working length.
- 4- Radiograph the tooth to verify the position of the instrument.
- 5- Readjust the file length according to the radiograph result.



Results are either fit, too long, or too short.

#### Notes:

- \* Bisecting technique in x-ray can't measure the exact length of the tooth. The parallel technique is more accurate
- \*The radiographs should be repeated in the following stages of treatment to check the working length.
- \* Initial size: It is the first instrument used to fit the working length & has slight resistance.
- \* If the radiograph results are too long e.g. 3mm. long, here we have to subtract 4 mm. & take another radiograph.
- \* If the radiograph results are too short e.g. 3mm. short, here we have to add 2mm. & then take another radiograph.

**When two superimposed canals are present (for example buccal and palatal canals of maxillary premolar, mesial canals of mandibular molar)**

one should take following steps:

- a. Take two individual radiographs with instrument placed in each canal.
- b. Take radiograph at different angulations, usually 20° to 40° at horizontal angulation.
- c. Insert two different instrument, e.g. K file in one canal, H file/ reamer in other canal and take radiograph at different angulations.
- d. Apply **SLOB** rule, that is expose tooth from mesial or distal horizontal angle, canal which moves to **S**ame direction, is **L**ingual where as canal which moves to **O**pposite direction is **B**uccal.

## **2. ELECTRONIC APEX LOCATORS**

---

Radiographs are often misinterpreted because of difficulty in distinguishing the radicular anatomy and pathosis from normal structures. Electronic apex locators (EAL) are used for determining working length as an adjunct to radiography. They are basically used to locate the apical constriction or cementodentinal junction or the apical foramen, and not the radiographic apex.





# ENDODONTICS

## Lecture 5

### Radiography in Endodontics:

There are many applications of radiographs in endodontics including:

- 1) Aid in the diagnosis and localization of hard tissue alteration of the tooth (sclerosis and resorption) and periradicular structures.
- 2) Determine the number, location, size, shape and direction of roots and root canals.
- 3) Estimate and confirm the length of root canals prior to instrumentation.
- 4) Determine the relative position of structures in facial or lingual dimensions.
- 5) Confirm the position and adaptation of the filling points.
- 6) Assess the outcome of root canal treatment

### Working length determination of Teeth:

Determination of an accurate working length is one of the most critical steps of endodontic therapy. The cleaning, shaping and obturation of the root canal system cannot be accomplished accurately unless working length is determined precisely. According to endodontic glossary working length is defined as “the distance from a coronal reference point to a point at which canal preparation and obturation should terminate”.

### **Objective of the working length**

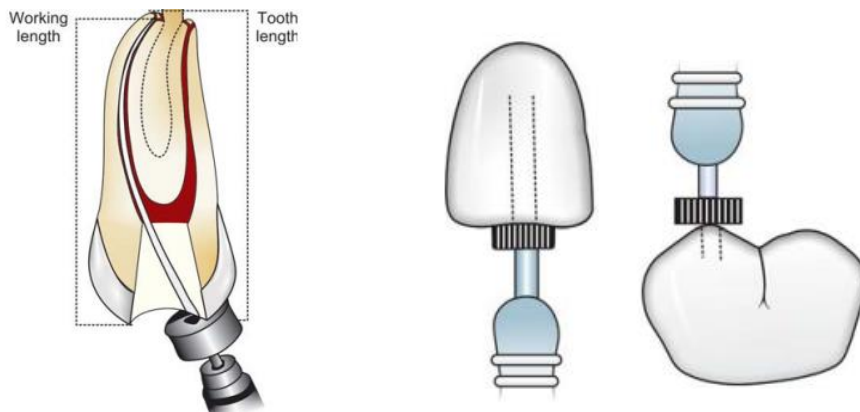
To establish the length of the tooth at which the canal preparation and subsequent obturation are to be completed. The apical end of the root canal is the CDJ, which is usually 0.5-1mm short of the radiographic apex. Sometimes the apical foramen is laterally positioned so it would be more than 1 mm from the radiographic apex.

	Maxillary	Mandibular
Central incisor	22.5	20.7
Lateral incisor	22.0	21.1
Canine	26.5	25.6
First premolar	20.6	21.6
Second premolar	21.5	22.3
First molar	20.8	21.0
Second molar	20.0	19.8

*From Black<sup>6</sup>*

**Reference point:** It is the site on the incisal edge or occlusal surface from which measurements are made. Usually it's the highest point on the incisal edge in anterior teeth & the tip of the cusp in posterior teeth. It should be:

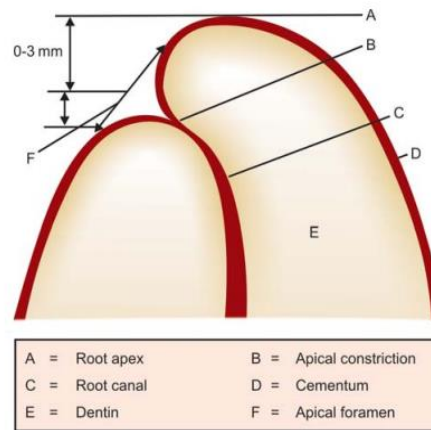
- 1) Stable
- 2) Easily visualized during preparation
- 3) Not changing during or between appointment.



Before we discuss various methods of determination of working length, we need to understand the anatomic consideration regarding it.

1. Anatomic apex is “tip or end of root determined morphologically”.
2. Radiographic apex is “tip or end of root determined radiographically”.
3. Apical foramen is main apical opening of the root canal which may be located away from anatomic or radiographic apex.
4. Apical constriction (minor apical diameter) is apical portion of root canal having narrowest diameter. It is usually 0.5 -1 mm short of apical foramen. The minor diameter widens apically to foramen, i.e. major diameter.

5. Cementodentinal junction is the region where cementum and dentin are united, the point at which cemental surface terminates at or near the apex of tooth. It is not always necessary that CDJ always coincide with apical constriction. Location of CDJ ranges from 0.5 - 3 mm short of anatomic apex



### **Consequences of over-extended working length**

- Perforation through apical construction
- Over instrumentation
- Overfilling of root canal
- Increased incidence of postoperative pain
- Prolonged healing period
- Lower success rate due to incomplete regeneration of cementum, periodontal ligament and alveolar bone.

### **Consequences of working short of actual working length**

- Incomplete cleaning and instrumentation of the canal
- Persistent discomfort due to presence of pulpal remnants
- Underfilling of the root canal
- Incomplete apical seal
- Apical leakage which supports existence of viable bacteria, this further leads to poor healing and periradicular lesion.

# DIFFERENT METHODS OF WORKING

## LENGTH DETERMINATION

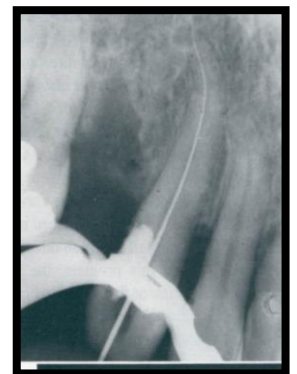
Various methods for determining working length include using average root lengths from anatomic studies, preoperative radiographs, tactile sensation, etc. Other common methods include use of paper point, working length radiograph, electronic apex locators or any combination of the above.

### 1. RADIOGRAPHIC METHOD OF WORKING LENGTH DETERMINATION

---

#### Procedure of Working Length determination

- 1- Examine preoperative radiograph & estimate the length of the tooth.
- 2- Know the average length of each tooth.
- 3- Place the file selected to be the correct initial width into the canal with it's rubber stopper set at the estimated working length.
- 4- Radiograph the tooth to verify the position of the instrument.
- 5- Readjust the file length according to the radiograph result.



Results are either fit, too long, or too short.

#### Notes:

- \* Bisecting technique in x-ray can't measure the exact length of the tooth. The parallel technique is more accurate
- \*The radiographs should be repeated in the following stages of treatment to check the working length.
- \* Initial size: It is the first instrument used to fit the working length & has slight resistance.
- \* If the radiograph results are too long e.g. 3mm. long, here we have to subtract 4 mm. & take another radiograph.
- \* If the radiograph results are too short e.g. 3mm. short, here we have to add 2mm. & then take another radiograph.

**When two superimposed canals are present (for example buccal and palatal canals of maxillary premolar, mesial canals of mandibular molar)**


one should take following steps:

- a. Take two individual radiographs with instrument placed in each canal.
- b. Take radiograph at different angulations, usually 20° to 40° at horizontal angulation.
- c. Insert two different instrument, e.g. K file in one canal, H file/ reamer in other canal and take radiograph at different angulations.
- d. Apply **SLOB** rule, that is expose tooth from mesial or distal horizontal angle, canal which moves to **S**ame direction, is **L**ingual where as canal which moves to **O**pposite direction is **B**uccal.

## **2. ELECTRONIC APEX LOCATORS**

---

Radiographs are often misinterpreted because of difficulty in distinguishing the radicular anatomy and pathosis from normal structures. Electronic apex locators (EAL) are used for determining working length as an adjunct to radiography. They are basically used to locate the apical constriction or cementodentinal junction or the apical foramen, and not the radiographic apex.



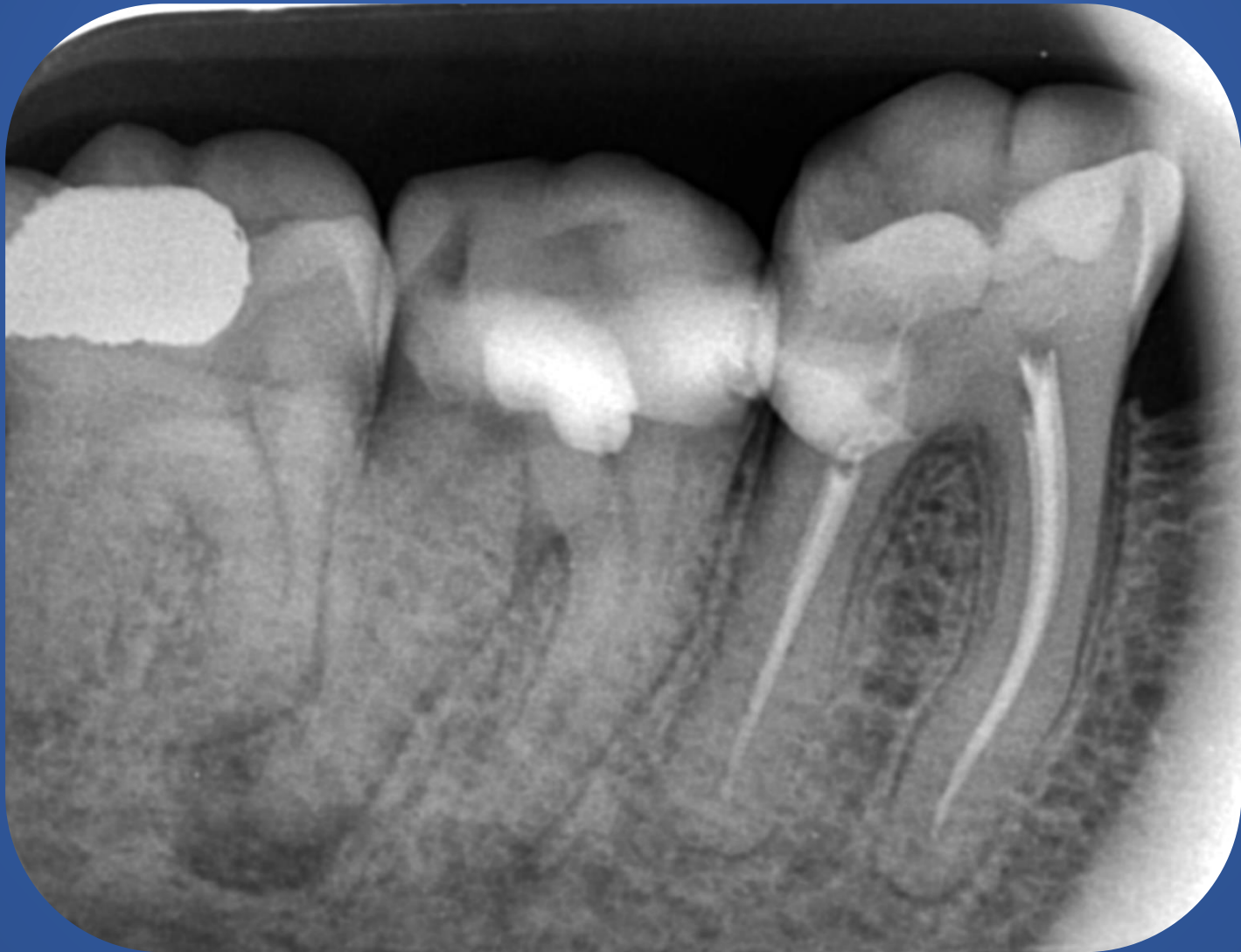# Cleaning and Shaping of Root Canal



# The outcomes of this lecture

- Understand the objectives of endodontic treatment.
- Recognise the difference between cleaning and shaping of root canal.
- Acknowledge the mechanical and biological objectives of successful root canal therapy
- Know the basic principles of mechanical root canal instrumentation

The major biologic aim of endodontic therapy is to eliminate apical periodontitis by disinfection and sealing of root canal systems.





Endodontic treatment mainly consists of three steps:

1. Cleaning and shaping of the root canal system.
2. Disinfection of the canal system.
3. Obturation and 3D closure and seal of the complete canal space.

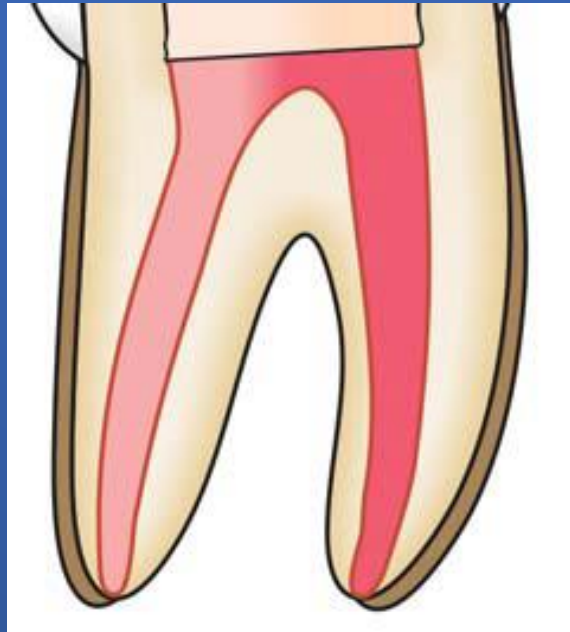
Cleaning and shaping is one of the most important step in the root canal therapy for obtaining success in the root canal treatment.

## Cleaning

It comprises the removal of all potentially pathogenic contents from the root canal system including the necrotic pulp tissue, dentine debris and microbes.

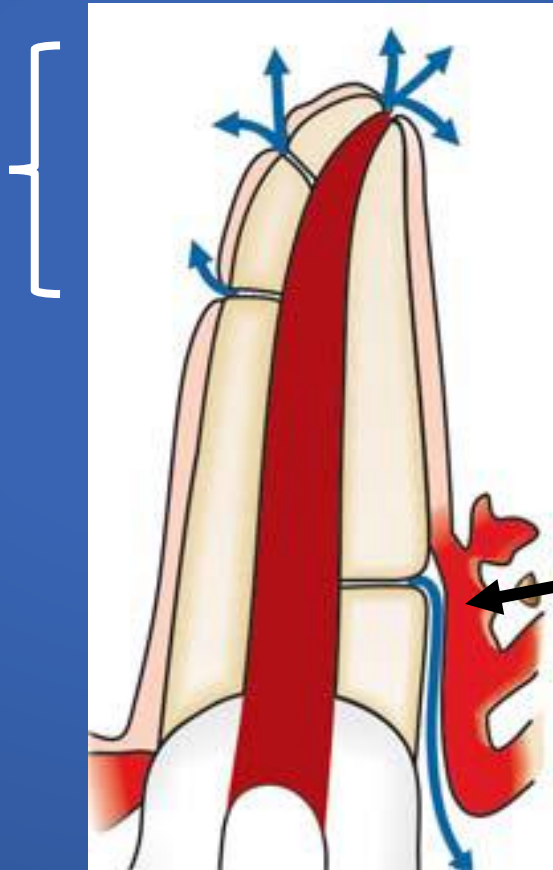
## Shaping

The establishment of a specifically shaped cavity which maintain the original shape and taper of the canal and allow three-dimensional progressive access into the apical part to permit the final obturation instruments and materials to fit easily.



For the success of endodontic treatment the contents of the root canal must be completely removed, to prevent any communication from the root canal system and periodontal space that may act as a portal of exit and can lead to formation of periodontal lesions of endodontic origin.

Apical region contains most of the lateral canals that connect the canal into the surrounding periodontium

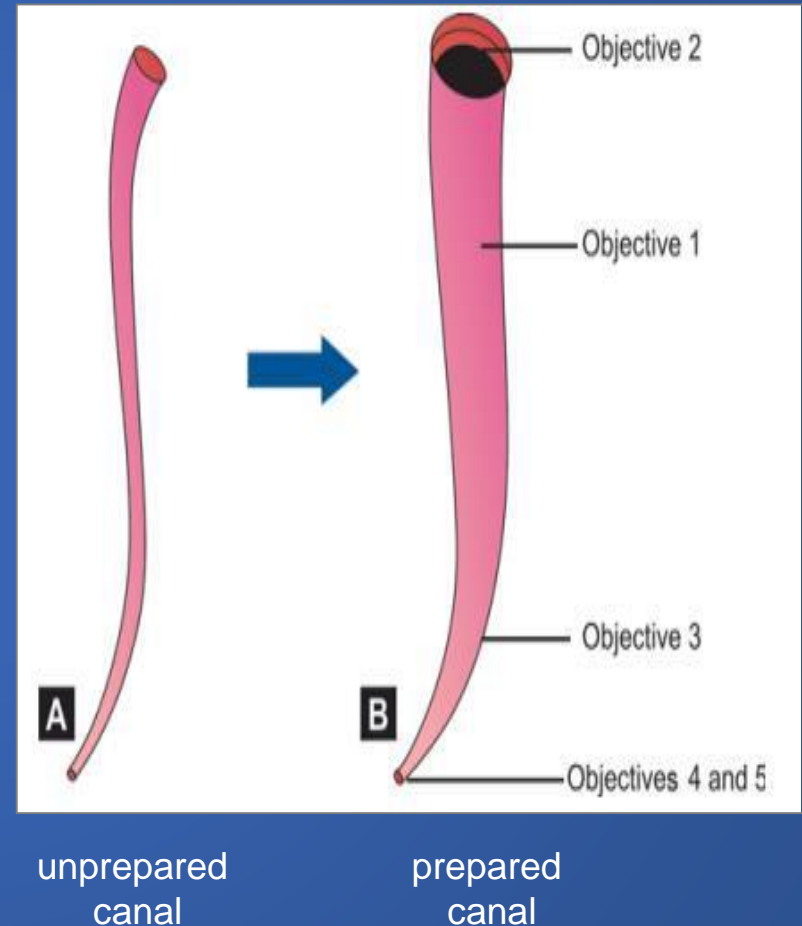


Communication route between the periodontal pocket and the root canal

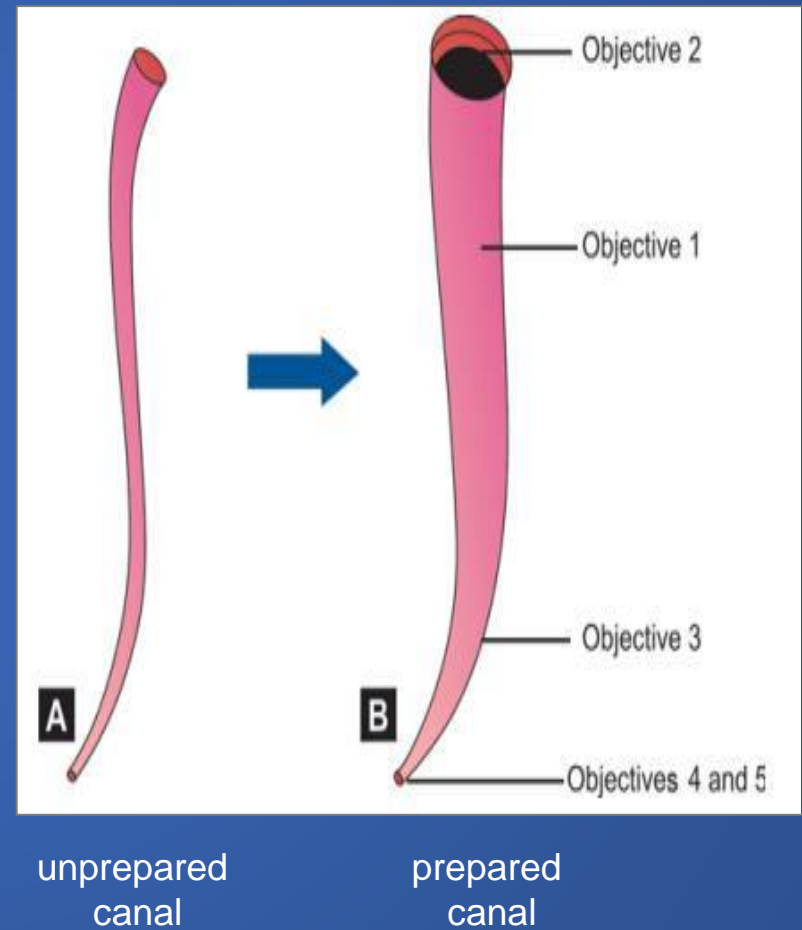
Schilder in early 1960s described **5 mechanical** and **4 biological** objectives for successful root canal therapy.

## Mechanical Objectives

1. The root canal preparation should develop a continuously tapering cone. This shape mimics the natural canal shape.
2. Making the preparation in multiple planes which introduces the concept of “flow”. This objective preserves the natural curve of the canal.
3. Making the canal narrower apically and widest coronally. To create a continuous tapers up to apical third which creates the resistance form to hold gutta-percha in the canal.



4. Avoid transportation of the foramen. There should be gentle enlargement of the foramen while maintaining its position.
5. Keep the apical opening as small as possible. Since over-lapping of the foramen contributes to number of iatrogenic problems. Doubling the file size apically increases the surface area of foramen for four folds ( $\pi r^2$ ).



The **Biological Objectives** are:

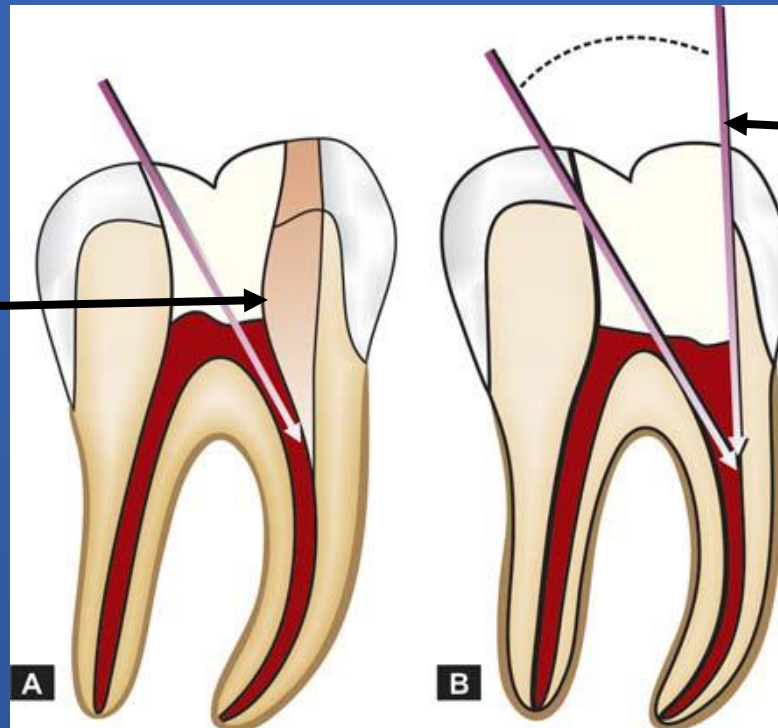
- 1- Confinement of instrumentation within the root canals only.
- 2- Ensure not to force necrotic or instrumentation debris beyond the apical foramen.
- 3- Optimum debridement of the root canal space.
- 4- Creation of sufficient space for intra-canal medicaments.

## Basic principles in root canal instrumentation

1- Before starting the endodontic treatment, proper diagnosis and evaluation of the tooth has to be performed to ensure that the tooth has a favourable treatment prognosis.

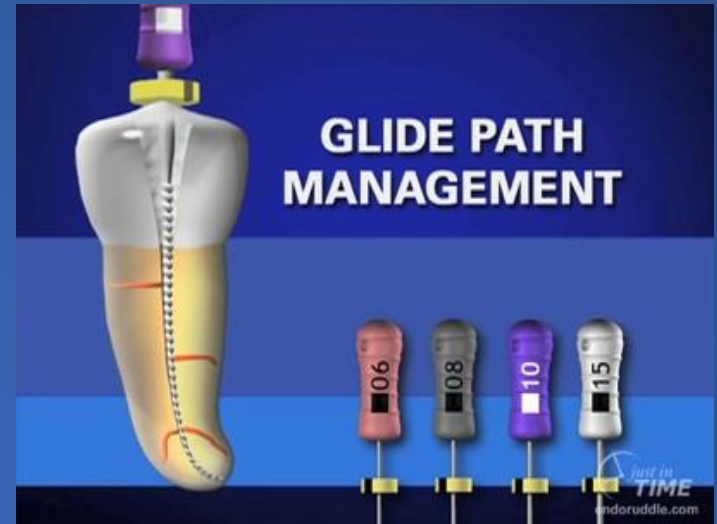2- During preparation of the access cavity, a straight line access from the coronal to the apical regions of the canal must be obtained. This can be performed by removing the overlying dentine to ensure flaring and smooth internal walls of the cavity with straight line access to the root.

This dentine shoulder should be removed to straighten the canal access

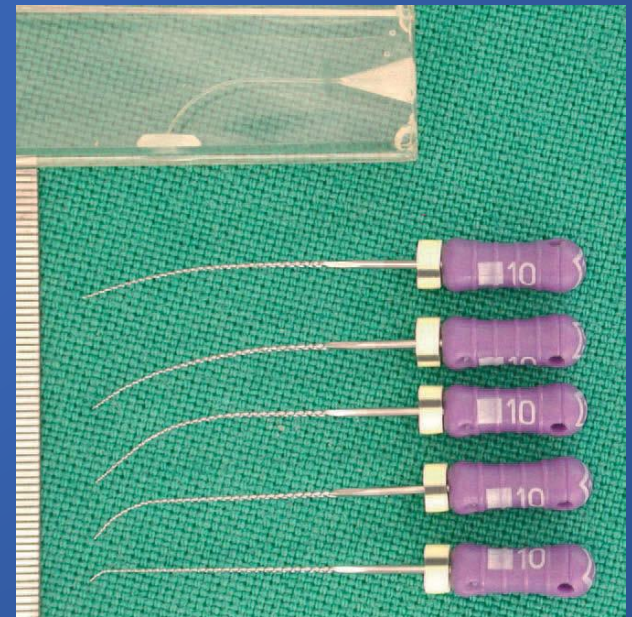


Straight access of the canal

3- Ensure glide path of the canal and apical patency before starting canal preparation. This can be performed by passing a small size K-file (usually a size #8 or #10) beyond the apex. The glide path file can help to ensure complete opening of the canal and facilitate working length estimation



4- Precurved instrument: In case of a curved canal, the instrument should be precurved to estimate the curvature of the canal. This is true only in case of stainless steel instrument, but nickel titanium instrument is flexible and cannot be curved.



Various precurved, stainless steel glide-path file. Compare the curves in the instruments to the ones in a plastic training block

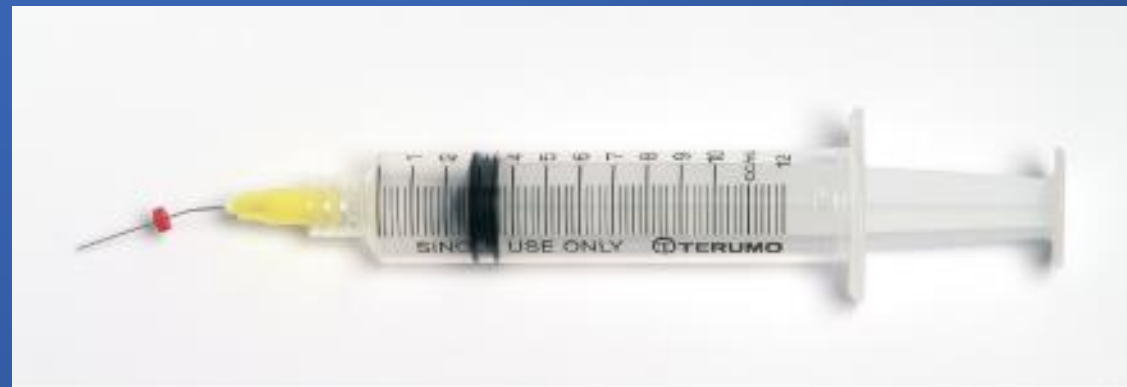

5- The use of intracanal irrigation solutions that serve many advantages:


- Dissolving and flushing out of the debris from the root canal,
- Lubrication for the cutting motion of the files within the canal,
- Antimicrobial activities.

The most popular intra-canal irrigation solution is Sodium hypochlorite (NaOCl) 2.5-5.25%.

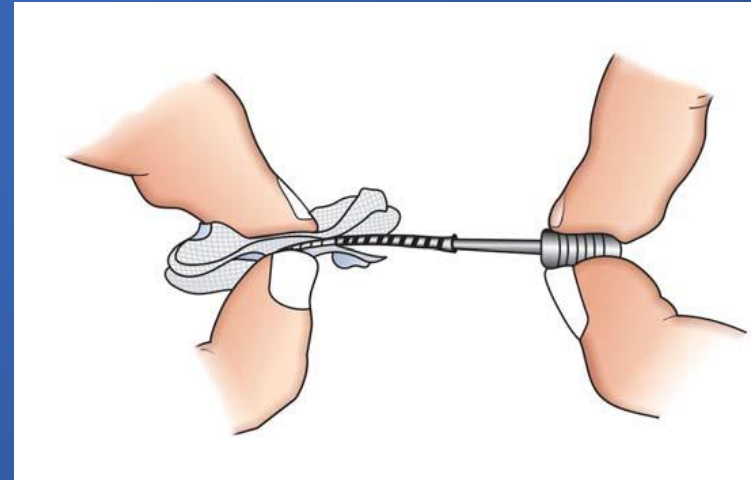
The irrigation solution can be delivered inside the canal by using hypodermic syringe.



6- Instrument examination: each instrument should be examined each time before insertion inside the root canal to verify the presence of any sign of fatigue, stress or damage, so any instrument showing such a sign should be discarded.



7- After each insertion and removal of the file, its flutes should be cleaned regularly, to ensure efficient cutting action of the file and prevent debris accumulation, canal blockage or extrusion of debris beyond the apical foramen.



8- Never force the instrument in the canal. Forcing or continuing to rotate an instrument while its bind to the canal wall may break the instrument.

9- Use of instruments in sequential order. Root canal preparation is done gradually by using successively larger files (never skip any size of instrument) e.g. size 20 followed by size 25 then 30 and so on, but not size 20 then size 30.



10- Over preparation and too aggressive over enlargement of the curved canals should be avoided.

11- Creation of an apical stop should be maintained during instrumentation procedures by maintaining the apical size as clean and small as possible. Over enlarging of the apical foramen should be avoided because it destroy the apical stop and cause apical extrusion of the irrigation and obturation material and cause failure of endodontic treatment.

# Manual or Hand instrumentation techniques

**Standardized Technique**

**Step-Back Technique**

**Step-down Technique**

**Balanced Force Technique**

**Crown Down Technique**