

Oral Surgery

Infection Control in Surgical Practice

Dr. Ali Mohammed

Communicable Pathogenic Organisms

Health care professionals must learn and practice protocols that limit the spread of contagions in the patient care setting. This is especially true for dentists performing surgery for two reasons: First, to perform surgery, the dentist typically violates an epithelial surface, the most important barrier against infection. Second, during most oral surgical procedures, the dentist, assistants, and equipment become contaminated with the patient's blood and saliva.

Therefore; it is necessary to know the sources of pathogenic organisms in the maxillofacial region which include: upper respiratory tract bacteria, maxillofacial skin bacteria, hepatitis, human immunodeficiency (HIV) viruses & Mycobacterium tuberculosis.

Aseptic Technique

Terminology

Sepsis is the breakdown of living tissue by the action of microorganisms and is usually accompanied by inflammation.

Medical asepsis is the attempt to keep patients, health care staff, and objects as free as possible of agents that cause infection.

Surgical asepsis is the attempt to prevent microbes from gaining access to surgically created wounds.

Antiseptics are substances applied to living tissues that can prevent the multiplication of organisms capable of causing infection.

Disinfectants are substances applied to inanimate objects that can prevent the multiplication of organisms capable of causing infection.

Sterility is the freedom from viable forms of microorganisms (bacteria, bacterial endospores, viruses ...etc).

Sanitization is the reduction of the number of viable microorganisms to levels judged safe by public health standards. Sanitization should not be confused with sterilization.

Decontamination is similar to sanitization, except that it is not connected with public health standards.

Techniques of Instrument Sterilization

Chemical and physical agents are the two principal means of reducing the number of microbes on a surface. Antiseptics, disinfectants, and ethylene oxide gas are the major chemical means of killing microorganisms on surfaces. Heat, irradiation, and mechanical dislodgment are the primary physical means of eliminating viable organisms

Any means of instrument sterilization to be used in office-based dental and surgical care must be reliable, practical, and safe for the instruments. The three methods generally available for instrument sterilization are dry heat, moist heat, and ethylene oxide gas.

Dry Heat

Dry heat is a method of sterilization that can be provided in most dental offices because the necessary equipment is no more complicated than a thermostatically controlled oven and a timer. Dry heat is most commonly used to sterilize glassware and bulky items that can withstand heat but are susceptible to rust. The success of sterilization depends not only on attaining a certain temperature but also on maintaining the temperature for a sufficient time. Therefore, the following three factors must be considered when using dry heat: **(1) warmup time for the oven and the materials to be sterilized, (2) heat conductivity of the materials, and (3) air flow throughout the oven and through the objects being sterilized.** In addition, time for the sterilized equipment to cool after heating must be taken into consideration. The time necessary for dry heat sterilization limits its practicality in the ambulatory setting because it lengthens the turnover time and forces the dentist to have many duplicate instruments. The advantages of dry heat are the relative ease of use and the unlikelihood of damaging heat-resistant instruments. The disadvantages are the time required to achieve sterilization and the potential damage to heat-sensitive equipment.

Moist Heat

Moist heat sterilization is more efficient than dry heat sterilization because it is effective at much lower temperatures and requires less time. The reason for this is based on several physical principles. First, water boiling at 100°C takes less time to kill organisms than does dry heat at the same temperature because water is better than air at transferring heat. Second, it takes approximately seven times as much heat to convert boiling water to steam as it takes to cause the same amount of room temperature water to boil. When steam comes into contact with an object, the steam condenses and almost instantly releases that stored heat energy, which quickly denatures vital cell proteins. Saturated steam placed under pressure (autoclaving) is even more efficient than non-pressurized steam. This is because increasing pressure in a container of steam increases the boiling point of water so that the new steam entering a closed container gradually becomes hotter.

The container usually used for providing steam under pressure is known as an autoclave as shown in the figure below.



The autoclave works by creating steam and then, through a series of valves, increases the pressure so that the steam becomes super-heated. Instruments placed into an autoclave should be packaged to allow the free flow of steam around the instruments, such as by placing them in sterilization pouches or wrapping them in cotton cloth. Simply placing instruments in boiling water or free-flowing steam results in disinfection rather than sterilization because at the temperature of 100°C, many spores and certain viruses survive. The advantages of sterilization with moist

heat are its effectiveness, speed, and the relative availability of office-proportioned autoclaving equipment. Disadvantages include the tendency of moist heat to dull and rust instruments and the cost of autoclaves.

Guidelines for Dry Heat and Steam Sterilization	
Temperature	Duration of Treatment or Exposure ^a
Dry Heat	
121°C (250°F)	6–12 h
140°C (285°F)	3 h
150°C (300°F)	2.5 h
160°C (320°F)	2 h
170°C (340°F)	1 h
Steam	
116°C (240°F)	60 min
118°C (245°F)	36 min
121°C (250°F)	24 min
125°C (257°F)	16 min
132°C (270°F)	4 min
138°C (280°F)	1.5 min

Comparison of Dry Heat Sterilization vs. Moist Heat Sterilization Techniques		
	Dry Heat	Moist Heat
Principal antimicrobial effect	Oxidizes cell proteins	Denatures cell proteins
Time necessary to achieve sterilization	Long	Short
Equipment complexity and cost	Low	High
Tendency to dull or rust instruments	Low	High
Availability of equipment sized for office use	Good	Good

Sterilization with Gas

Certain gases exert a lethal action on bacteria by destroying enzymes and other vital biochemical structures. Of the several gases available for sterilization, ethylene oxide is the most commonly used. Ethylene oxide is a highly flammable gas, so it is mixed with carbon dioxide or nitrogen to make it safer to use. Ethylene oxide is a gas at room temperature and can readily diffuse through porous materials such as plastic and rubber. At 50°C ethylene oxide is effective for killing all organisms, including spores, within 3 hours. However, because it is highly toxic to animal tissue, equipment exposed to ethylene oxide must be aerated for 8 to 12 hours at 50°C to 60°C or at ambient temperatures for 4 to 7 days. The advantages of ethylene oxide for sterilization are its effectiveness for sterilizing porous materials, large equipment, and materials sensitive to heat or moisture. The disadvantages are the need for special equipment and the length of sterilization and aeration time necessary to reduce tissue toxicity.

Techniques of Instruments Disinfection

Many dental instruments cannot withstand the temperatures required for heat sterilization. Therefore, if sterilization with gas is not available and absolute sterility is not required, chemical disinfection can be performed.

Substances acceptable for disinfecting dental instruments for surgery include glutaraldehyde, iodophors, chlorine compounds, and formaldehyde; glutaraldehyde-containing compounds are the most commonly used.

Alcohols are not suitable for general dental disinfection because they evaporate too rapidly; however, they can be used to disinfect local anesthetic cartridges. Quaternary ammonium compounds are not recommended for dentistry because they are not effective against the hepatitis B virus and become inactivated by soap and anionic agents.

Certain procedures must be followed to ensure maximal disinfection, regardless of which disinfectant solution is used:

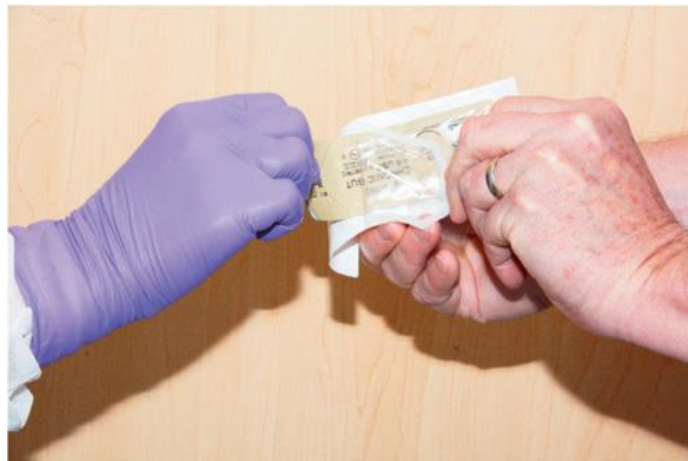1. The agent must be properly reformulated and discarded periodically, as specified by the manufacturer.

2. Instruments must remain in contact with the solution for the designated period, and no new contaminated instruments should be added to the solution during that time.
3. All instruments must be washed free of blood or other visible material before being placed in the solution.
4. The instruments must be rinsed free of chemicals and used within a short time.

Maintenance of Sterility

- The use of disposable materials

Materials and drugs used during oral and maxillofacial surgery—such as sutures, local anesthetics, scalpel blades, and syringes with needles—are sterilized by the manufacturer with a variety of techniques, including use of gases, autoclaving, filtration, and irradiation. To maintain sterility, only the dentist must properly remove the material or drug from its container. Most surgical supplies are double wrapped. The outer wrapper is designed to be handled in a nonsterile fashion and usually is sealed in a manner that allows an ungowned and gloved individual to unwrap it and transfer the material still wrapped in a sterile inner wrapper. The ungloved individual may allow the surgical material to drop onto a sterile part of the surgical field or allow an individual gloved in a sterile fashion to remove the wrapped material in a sterile manner



Method of sterily transferring double-wrapped sterile supplies from clean individual (ungloved hands) to sterily gowned individual (gloved hands). The package is designed to be peeled open from one end without touching the sterile interior of the package.

- Surgical Field Maintenance

during oral-maxillofacial surgery, the goal is to prevent any organisms from the surgical staff or other patients from entering the patient's wound. Once instruments are sterilized or disinfected, they should be set up for use during surgery in a manner that limits the likelihood of contamination by organisms foreign to the patient's maxillofacial flora. A flat tray should be used, and two layers of sterile towels or waterproof paper should be placed on it. Then, the clinician or assistant should lay the instrument pack on the platform and open out the edges in a sterile fashion. Anything placed on the platform should be sterile or disinfected. Care should be taken not to allow excessive moisture to get on the towels or paper; if the towels become saturated, they can allow bacteria from the unsterile undersurface to wick up to the sterile instruments.

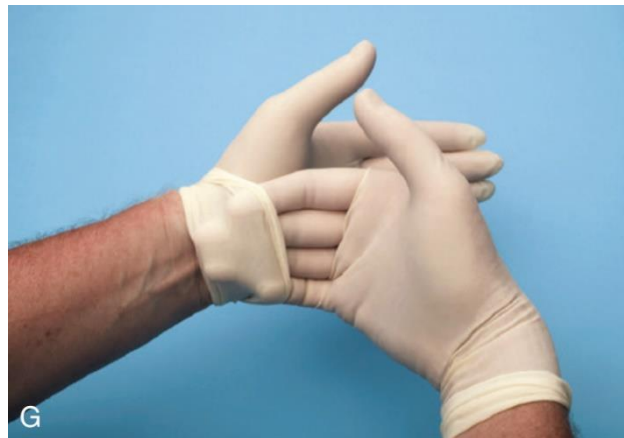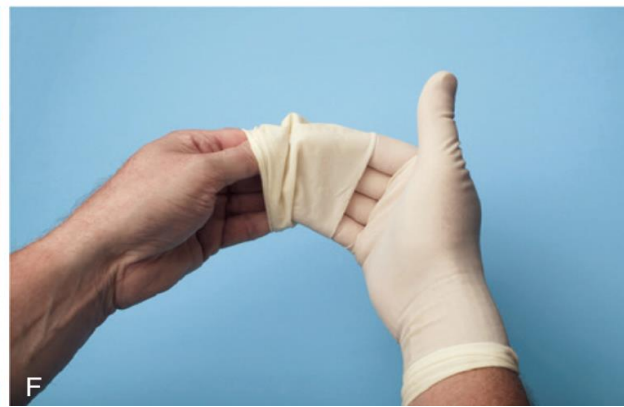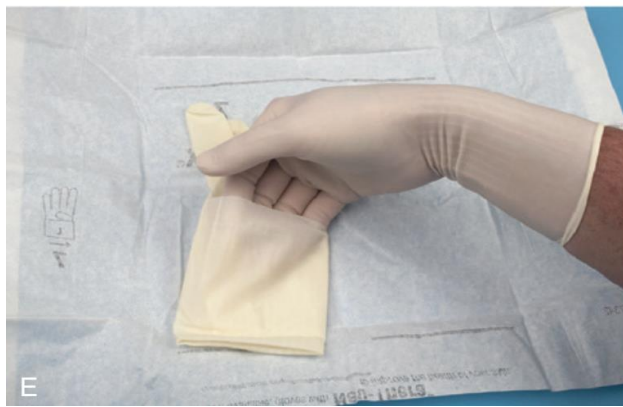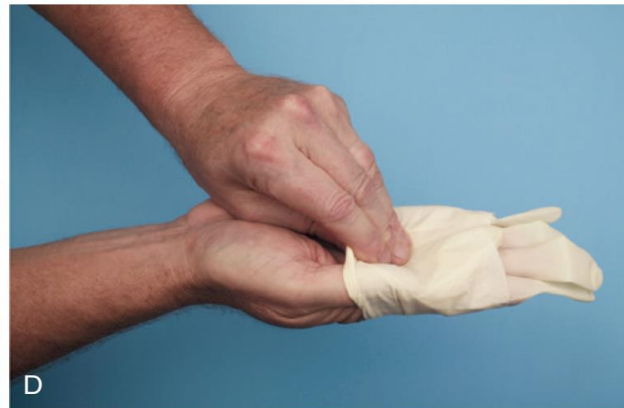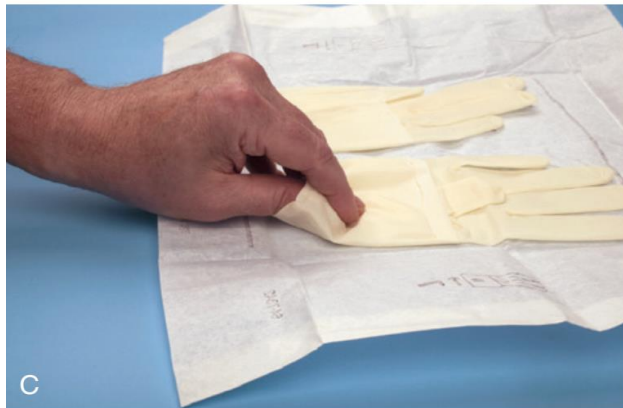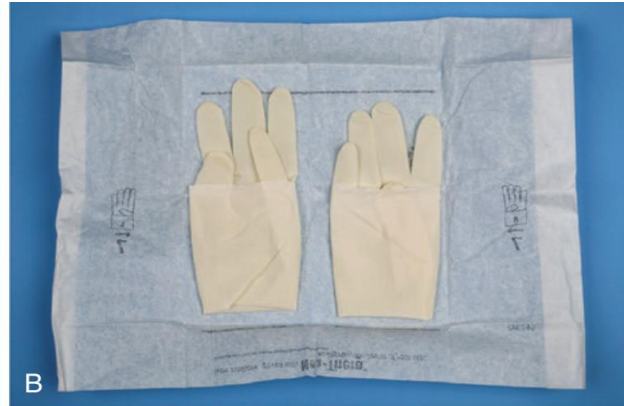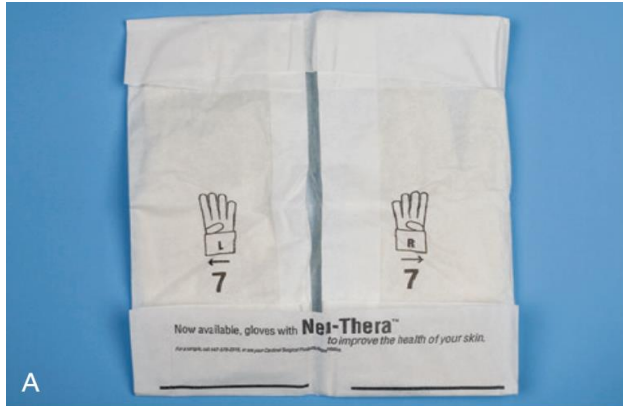- Operatory Disinfection

This can be achieved by two basic methods:

- ✓ The first is to wipe all surfaces with a hospital-grade disinfectant solution.
- ✓ The second is to cover surfaces with protective shields that are changed between each patient.

Fortunately, many chemical disinfectants, including chlorine compounds and glutaraldehyde, can prevent transfer of the hepatitis viruses when used on surfaces in certain concentrations (0.2% for chlorine, 2% for glutaraldehyde). Headrests, tray tables, hosing and lines, controls for the chair, and light handles can be covered with commercially available, single-use, disposable covers; the rest of the dental chair can be quickly sprayed with a disinfectant. Countertops usually come into contact with patients only indirectly, so counters should be periodically disinfected, especially before surgical procedures.

The dentist should put on sterile gloves when performing oral surgery as shown in the figure below.



Oral Surgery

3rd Grade
Dr. Ali Mohammed

Medical Emergencies During Dental Treatment

Patients with medical conditions sometimes require modifications of their perioperative care when oral surgery is planned. This lecture discusses those considerations for the major categories of health problems.

Cardiovascular Problems

1. Ischemic Heart Diseases.

❖ Angina Pectoris:

It is a progressive narrowing or spasm (or both) of one or more of the coronary arteries. narrowing of myocardial arteries is one of the most common health problems that dentists encounter. This condition occurs primarily in men older than age 40 years and is also prevalent in postmenopausal women.

This condition leads to a mismatch between myocardial oxygen demand and the ability of the coronary arteries to supply oxygen carrying blood. Myocardial oxygen demand can be increased, for example, by exertion or anxiety, the attack occurs because there is insufficient oxygen supply that meet the demand by the myocardium.

Signs & Symptoms:

- a) Heavy pressure or squeezing sensation in the patient's substernal region that can radiate into the left shoulder and arm and even into the mandibular region.
- b) Intense sense of being unable to breathe adequately.
- c) Nausea.
- d) Sweating.
- e) Bradycardia.

Once the decision is made to perform elective oral surgery, the patient with a history of angina should be prepared for surgery, and the patient's myocardial oxygen demand should be lowered or prevented from rising. The increased oxygen demand during oral surgery is primarily the result of patient anxiety; thus, an anxiety-reduction protocol should be used as mentioned below.

General Anxiety-Reduction Protocol

Before Appointment

- Hypnotic agent to promote sleep on night before surgery (optional)
- Sedative agent to decrease anxiety on morning of surgery (optional)
- Morning appointment and schedule so that reception room time is minimized

During Appointment

Nonpharmacologic Means of Anxiety Control

- Frequent verbal reassurances
- Distracting conversation
- No surprises (clinician warns patient before doing anything that could cause anxiety)
- No unnecessary noise
- Surgical instruments out of patient's sight
- Relaxing background music

Pharmacologic Means of Anxiety Control

- Local anesthetics of sufficient intensity and duration
- Nitrous oxide
- Intravenous anxiolytics.

Management of patient with history of Angina Pectoris:

1. Consult the patient's physician.
2. Use an anxiety-reduction protocol.
3. Have nitroglycerin tablets (sublingual) or spray readily available. Use nitroglycerin premedication, if indicated.
4. Ensure profound local anesthesia (best reducer of anxiety) before starting surgery.
5. Consider the use of nitrous oxide sedation.
6. Monitor vital signs closely.
7. Consider possible limitation of amount of epinephrine used (0.04 mg maximum)(4ml of LA with 1:100,000 epinephrine).
8. Maintain verbal contact with patient throughout the procedure to monitor status.

❖ Myocardial Infarction (MI):

MI occurs when ischemia (resulting from an oxygen demand-supply mismatch) is not relieved and causes myocardial cellular dysfunction and death.

MI usually occurs when an area of coronary artery narrowing has a clot form that blocks all or most blood flow. The infarcted area of myocardium becomes nonfunctional and eventually necrotic and is surrounded by an area of usually reversibly ischemic myocardium that is prone to serve as a nidus for dysrhythmias.

In general, it is recommended that elective major surgical procedures be deferred until at least 6 months after an infarction.

Management of Patient with a History of Myocardial Infarction

1. Consult the patient's primary care physician.
2. Check with the physician if invasive dental care is needed before 6 months since the myocardial infarction.
3. Check whether the patient is using anticoagulants (including aspirin).
4. Use an anxiety-reduction protocol.
5. Have nitroglycerin available; use it prophylactically if the physician advises.
6. Administer supplemental oxygen (optional).
7. Provide profound local anesthesia.
8. Consider nitrous oxide administration.
9. Monitor vital signs, and maintain verbal contact with the patient.
10. Consider possible limitation of epinephrine use to 0.04 mg.
11. Consider referral to an oral-maxillofacial surgeon.

2. Cerebrovascular Accident (Stroke)

Patients who have had a cerebrovascular accident (CVA) are always susceptible to further neurovascular accidents. These patients are often prescribed anticoagulants or antiplatelet medication depending on the cause of the CVA; if they are hypertensive, they are given blood pressure-lowering agents. CVAs are typically a result of an embolus from a history of atrial fibrillation, a thrombus due to a hypercoagulable state, or stenotic vessels.

In the case of a patient having an embolic or thrombotic stroke, the patient is likely taking an anticoagulant as opposed to an ischemic stroke secondary to stenotic vessels, in which case the patient would be taking an antiplatelet medication. If such a patient requires surgery, clearance by the patient's physician is desirable, as is a delay until significant hypertensive tendencies have been controlled. The patient's baseline neurologic status should be assessed and documented preoperatively.

The patient should be treated by a nonpharmacologic anxiety reduction protocol and have vital signs carefully monitored during surgery. If pharmacologic sedation is necessary, low concentrations of nitrous oxide can be used. Techniques to manage patients taking anticoagulants are discussed later in this lecture.

3. Congestive Heart Failure (Hypertrophic Cardiomyopathy)

CHF (HCM) occurs when a diseased myocardium is unable to deliver the cardiac output demanded by the body or when excessive demands are placed on a normal myocardium.

The heart begins to have an increased end-diastolic volume that, in the case of the normal myocardium, increases contractility through the Frank-Starling mechanism (FOR YOUR INFORMATION (FYI) The Frank-Starling mechanism is an intrinsic cardiac autoregulatory mechanism that represents the relationship between stroke volume and end-diastolic volume. The law states that the stroke volume of the heart increases in response to an increase in the volume of blood in the ventricles before contraction (the end-diastolic volume), when all other factors remain constant. As a larger volume of blood flows into the ventricle, the blood stretches cardiac muscle, leading to an increase in the force of contraction. This mechanism ensures that stroke volume changes in proportion to the change in end-diastolic volume). However, as the normal or diseased myocardium further dilates, it becomes a less efficient pump, causing blood to back up into the pulmonary, hepatic, and mesenteric vascular beds. This eventually leads to pulmonary edema, hepatic dysfunction, and compromised intestinal nutrient absorption. The lowered cardiac output causes generalized weakness, and impaired renal clearance of excess fluid leads to vascular overload.

Sings & Symptoms:

- a) Orthopnea: shortness of breath in supine position.
- b) Paroxysmal nocturnal dyspnea: similar to orthopnea. The patient has respiratory difficulty 1 or 2 hours after lying down.
- c) Lower extremity edema: which usually appears as a swelling of the foot, the ankle, or both, is caused by an increase in interstitial fluid. The edema is detected by pressing a finger into the swollen area for a few seconds; and the indentation in the soft tissue is left after the finger is removed.
- d) Weight gain.
- e) Dyspnea on exertion.

Management of the Patient with Congestive Heart Failure

1. Defer treatment until heart function has been medically improved and the patient's physician believes treatment is possible.
2. Use an anxiety-reduction protocol.
3. Consider possible administration of supplemental oxygen.
4. Avoid using the supine position.
5. Consider referral to an oral-maxillofacial surgeon.



Pulmonary Problems

1. Asthma

True asthma involves the episodic narrowing of inflamed small airways, which produces wheezing and dyspnea as a result of chemical, infectious, immunologic, or emotional stimulation or a combination of these. Patients with asthma should be questioned about precipitating factors, frequency and severity of attacks, medications used, and response to medications. The severity of attacks can often be gauged by the need for emergency room visits and hospital admissions.

Management of the Patient with Asthma

1. Defer dental treatment until the asthma is well controlled and the patient has no signs of a respiratory tract infection.
2. Listen to the chest with a stethoscope to detect any wheezing before major oral surgical procedures or sedation.
3. Use an anxiety-reduction protocol, including nitrous oxide, but avoid the use of respiratory depressants.
4. Consult the patient's physician about possible preoperative use of cromolyn sodium.
5. If the patient is or has been chronically taking corticosteroids, provide prophylaxis for adrenal insufficiency.
6. Keep a bronchodilator-containing inhaler easily accessible.
7. Avoid the use of NSAIDs in susceptible patients.

FYI: - Cromolyn is a synthetic compound that is used to prevent some allergic reactions. It is traditionally described as a mast cell stabilizer and is commonly marketed as the sodium salt sodium cromoglicate or cromolyn sodium. This drug prevents the release of inflammatory chemicals such as histamine from mast cells. It is available in multiple forms such as nasal spray, nebulizer solution for aerosol administration to treat asthma.

2. Chronic Obstructive Pulmonary Disease (COPD)

In the past, the terms emphysema and bronchitis were used to describe clinical manifestations of COPD, but COPD has been recognized to be a spectrum of pathologic pulmonary problems. It is usually caused by long-term exposure to pulmonary irritants such as tobacco smoke that cause metaplasia of pulmonary airway tissue. Airways are inflamed and disrupted, lost their elastic properties, and become obstructed because

of mucosal edema, excessive secretions, and bronchospasm, producing the clinical manifestations of COPD.

Sings & Symptoms:

1. dyspnea during mild to moderate exertion.
2. chronic cough that produces large amounts of thick secretions.
3. frequent respiratory tract infections.
4. barrel shaped chests.
5. they may purse their lips to breathe.
6. Have audible wheezing during breathing.
7. Patients may develop associated pulmonary hypertension and eventual right-sided heart failure.

Management of Patient With COPD

1. Defer treatment until lung function has improved and treatment is possible.
2. Listen to the chest bilaterally with stethoscope to determine adequacy of breath sounds.
3. Use an anxiety-reduction protocol, but avoid the use of respiratory depressants.
4. If the patient requires chronic oxygen supplementation, continue at the prescribed flow rate. If the patient does not require supplemental oxygen therapy, consult his/her physician before administering oxygen.
5. If the patient chronically receives corticosteroid therapy, manage the patient for adrenal insufficiency.
6. Avoid placing the patient in the supine position until you are confident that the patient can tolerate it.
7. Keep a bronchodilator-containing inhaler accessible.
8. Closely monitor respiratory rate and heart rate.
9. Schedule afternoon appointments to allow for clearance of secretions.

Renal Problems

1. Renal Failure

Patients with chronic renal failure require periodic renal dialysis. Elective oral surgery is best undertaken the day after a dialysis treatment has been performed. This allows the heparin used during dialysis to disappear and the patient to be in the best physiologic status with respect to intravascular volume and metabolic byproducts.

Management of Patient with Renal Insufficiency and Patient Receiving Hemodialysis

1. Avoid the use of drugs that depend on renal metabolism or excretion. Modify the dose if such drugs are necessary. Do not use an atrioventricular shunt for giving drugs or for taking blood specimens.
2. Avoid the use of nephrotoxic drugs such as nonsteroidal anti-inflammatory drugs.
3. Defer dental care until the day after dialysis has been given.
4. Consult the patient's physician about the use of prophylactic antibiotics.
5. Monitor blood pressure and heart rate.
6. Look for signs of secondary hyperparathyroidism.
7. Consider screening for hepatitis B virus before dental treatment. Take the necessary precautions if unable to screen for hepatitis.

2. Renal Transplantation and Transplantation of Other Organs

The patient requiring surgery after renal or other major organ transplantation is usually receiving a variety of drugs to preserve the function of the transplanted tissue. These patients receive corticosteroids and may need supplemental corticosteroids in the perioperative period.

Most of these patients also receive immunosuppressive agents that may cause otherwise self-limiting infections to become severe.

Therefore, a more aggressive use of antibiotics and early hospitalization for infections are warranted. The patient's primary care physician should be consulted about the need for prophylactic antibiotics. Cyclosporine A, an immunosuppressive drug administered after organ transplantation, may cause gingival hyperplasia. The dentist performing oral surgery should recognize this so as not to wrongly attribute gingival hyperplasia entirely to hygiene problems. Patients who have received renal transplants occasionally have problems with severe hypertension.

Management of Patient with Renal Transplant

1. Defer treatment until the patient's primary care physician or transplant surgeon clears the patient for dental care.
2. Avoid the use of nephrotoxic drugs.
3. Consider the use of supplemental corticosteroids.
4. Monitor blood pressure.
5. Consider screening for hepatitis B virus before dental care. take necessary precautions if unable to screen for hepatitis.
6. Watch for presence of cyclosporine-A-induced gingival hyperplasia. emphasize the importance of oral hygiene.
7. Consider use of prophylactic antibiotics, particularly in patients taking immunosuppressive agents.

3. Hypertension

According to the American Heart Association hypertension is a chronic elevation of blood pressure. when blood pressure consistently ranges from 130-139 systolic or 80-89 mm Hg diastolic, as illustrated in the table below:

Blood Pressure Categories



BLOOD PRESSURE CATEGORY	SYSTOLIC mm Hg (upper number)		DIASTOLIC mm Hg (lower number)
NORMAL	LESS THAN 120	and	LESS THAN 80
ELEVATED	120-129	and	LESS THAN 80
HIGH BLOOD PRESSURE (HYPERTENSION) STAGE 1	130-139	or	80-89
HIGH BLOOD PRESSURE (HYPERTENSION) STAGE 2	140 OR HIGHER	or	90 OR HIGHER
HYPERTENSIVE CRISIS (consult your doctor immediately)	HIGHER THAN 180	and/or	HIGHER THAN 120

Management of Patient with Hypertension

Mild to Moderate Hypertension (Systolic >140 mm Hg; Diastolic >90 mm Hg)

1. Recommend that the patient seek the primary care physician's guidance for medical therapy of hypertension. It is not necessary to defer needed dental care.
2. Monitor the patient's blood pressure at each visit and whenever administration of epinephrine-containing local anesthetic surpasses 0.04 mg during a single visit.
3. Use an anxiety-reduction protocol.
4. Avoid rapid posture changes in patients taking drugs that cause vasodilation.
5. Avoid administration of sodium-containing intravenous solutions.

Severe Hypertension (Systolic >200 mm Hg; Diastolic >110 mm Hg)

1. Defer elective dental treatment until the hypertension is better controlled.

2. Consider referral to an oral-maxillofacial surgeon for emergent problems.



Hepatic Disorders

The patient with severe liver damage resulting from infectious disease, ethanol abuse, or vascular or biliary congestion requires special consideration before oral surgery is performed. An alteration of dose or avoidance of drugs that require hepatic metabolism may be necessary. The production of nearly all coagulation factors, therefore obtaining an international normalized ratio [INR] which is in a healthy person is typically between 0.8 and 1.2, prothrombin time [PT] (normally 11-13.5 sec.) or partial thromboplastin time [PTT] (normally 25-35 sec.) may be useful before surgery in patients with more severe liver disease who are undergoing surgery with the potential for heavy blood loss. Portal hypertension caused by liver disease may also cause hypersplenism and the sequestering of platelets, causing a relative thrombocytopenia. Thrombopoietin is also produced in the liver, and decreased production of thrombopoietin may result in a true thrombocytopenia. Finding a prolonged bleeding time or low platelet count reveals this problem. Patients with severe liver dysfunction may require hospitalization for dental surgery because their decreased ability to metabolize the nitrogen in swallowed blood may cause encephalopathy. Finally, unless documented otherwise, a patient with liver disease of unknown origin should be presumed to carry the hepatitis virus.

FYI: - Encephalopathy is a general term used to describe a disease that affects the function or structure of the brain. It can have many different causes, including infections, liver failure, kidney failure, lack of oxygen or blood flow to the brain, and exposure to toxins. Symptoms of encephalopathy can vary depending on the underlying cause and may

include confusion, memory loss, personality changes, seizures, and loss of consciousness.



Endocrine Disorders

1. Diabetes Mellitus

Diabetes mellitus is caused by an underproduction of insulin, a resistance of insulin receptors in end organs to the effects of insulin, or both. Diabetes is commonly divided into insulin-dependent (type 1) and non-insulin-dependent (type 2) diabetes.

Type 1 diabetes usually begins during childhood or adolescence. The major problem in this form of diabetes is an underproduction of insulin, which results in the inability of the patient to use glucose properly.

Patients with type 2 diabetes usually produce insulin but in insufficient amounts because of decreased insulin activity, insulin receptor resistance, or both. This form of diabetes typically begins in adulthood, is exacerbated by obesity, and does not usually require insulin therapy. Hypoglycemia should be avoided in patients undergoing oral surgery since it can lead to coma while hyperglycemia rarely lead to ketoacidosis in patient with type 2 diabetes, therefore, any Signs of hypoglycemia—hypotension, hunger, drowsiness, nausea, diaphoresis, tachycardia, or mood change—occur, an oral or IV supply of glucose should be administered.

Persons with well-controlled diabetes are no more susceptible to infections than are persons without diabetes, but they have more difficulty containing infections. This is caused by altered leukocyte function or by other factors that affect the ability of the body to control an infection. Difficulty in containing infections is more significant in persons with poorly controlled diabetes. Therefore, elective oral surgery should be deferred in patients with poorly controlled diabetes until control is accomplished.

Insulin-Dependent (Type 1) Diabetes

1. Defer surgery until the diabetes is well controlled; consult the patient's physician.
2. Schedule an early-morning appointment; avoid lengthy appointments.
3. Use an anxiety-reduction protocol, but avoid deep sedation techniques in outpatients.
4. Monitor pulse, respiration, and blood pressure before, during, and after surgery.
5. Maintain verbal contact with the patient during surgery.
6. If the patient must not eat or drink before oral surgery and will have difficulty eating after surgery, instruct him or her not to take the usual dose of regular insulin; start intravenous administration of a 5% dextrose in water drip at 150 mL/h.
7. If allowed, have the patient eat a normal breakfast before surgery and take the usual dose of regular insulin.
8. Advise patients not to resume normal insulin doses until they are able to return to usual level of caloric intake and activity level.
9. Consult the physician if any questions concerning modification of the insulin regimen arises.
10. Watch for signs of hypoglycemia.
11. Treat infections aggressively.

Non-Insulin-Dependent (Type 2) Diabetes

1. Defer surgery until the diabetes is well controlled.
2. Schedule an early-morning appointment; avoid lengthy appointments.
3. Use an anxiety-reduction protocol.
4. Monitor pulse, respiration, and blood pressure before, during, and after surgery.
5. Maintain verbal contact with the patient during surgery.

6. If the patient must not eat or drink before oral surgery and will have difficulty eating after surgery, instruct him or her to skip any oral hypoglycemic medications that day.
7. If the patient can eat before and after surgery, instruct him or her to eat a normal breakfast and to take the usual dose of hypoglycemic agent.
8. Watch for signs of hypoglycemia.
9. Treat infections aggressively.

2. Adrenal Insufficiency

Diseases of the adrenal cortex may cause adrenal insufficiency. Symptoms of primary adrenal insufficiency include weakness, weight loss, fatigue, and hyperpigmentation of skin and mucous membranes. However, the most common cause of adrenal insufficiency is chronic therapeutic corticosteroid administration (secondary adrenal insufficiency).

Often, patients who regularly take corticosteroids have moon facies (moon-shaped face), buffalo (back) humps, and thin, translucent skin. Their inability to increase endogenous corticosteroid levels in response to physiologic stress may cause them to become hypotensive, syncopal, nauseated, and feverish during complex, prolonged surgery, which is consistent with an adrenal crisis.

Management of Patient With Adrenal Suppression Who Requires Major Oral Surgery

If the patient is currently taking corticosteroids:

1. Use an anxiety-reduction protocol.
2. Monitor pulse and blood pressure before, during, and after surgery.
3. Instruct the patient to double the usual daily dose on the day before, day of, and day after surgery.

4. On the second postsurgical day, advise the patient to return to a usual steroid dose.

If the patient is not currently taking steroids but has received at least 20 mg of hydrocortisone (cortisol or equivalent) for more than 2 weeks within the past year:

1. Use an anxiety-reduction protocol.
2. Monitor pulse and blood pressure before, during, and after surgery.
3. Instruct the patient to take 60 mg of hydrocortisone (or equivalent) the day before and the morning of surgery (or the dentist should administer 60 mg of hydrocortisone or equivalent intramuscularly or intravenously before complex surgery).
4. On the first 2 postsurgical days, the dose should be dropped to 40 mg and dropped to 20 mg for 3 days thereafter. The clinician can cease administration of supplemental steroids 6 days after surgery.

ORAL SURGERY

Lec:1

د. علي محمد

ORAL AND MAXILLOFACIAL SURGERY

Is one of the dental specialties dealing with management of diseases, injuries and defects of human jaws and associated structures. Oral surgery forms the connecting link between medical and dental specialties.

Diagnosis in surgery:-

Oral diagnosis is the art of using the scientific knowledge to identify the oral diseases and also to distinguish one disease from another.

The diagnostic process classically involves the following steps:-

- 1- History taking.
- 2- Clinical examination.
- 3- Investigation.
- 4- Provisional diagnosis.
- 5- Definitive diagnosis and treatment plan.

In oral surgery practice, clinician is often faced with the diagnosis of the following conditions:-

- 1- Dental and facial pain.
- 2- Swelling (lump, mass).
- 3- Ulcers;
- 4- Injuries (dental, facial bones).
- 5- Temporomandibular joint problems.
- 6- Medically compromised patient.
- 7- Facial deformity.

History taking:-

The art of taking an accurate case history is probably the most important

single step in the diagnosis of medical or surgical condition. History taking should be systematic, using special set or sequences. During history taking the clinician or the dental surgeon listen to the patient's story or talks and list the symptoms in order of severity or importance. By patient's words.

Symptoms:-

Means a subjective problem that the patient describes e.g. pain, parasthesia.

Signs:-

Means (objective) an abnormal presentation detectable by the clinician, e.g. swelling, ulcer.

So detection of signs and symptoms of a disease may aid in diagnosis of that disease.

Objectives of taking history:-

- 1- To provide the dentist with information that may be necessary for making diagnosis.
- 2- To establish a good or positive professional relationship with the patient which affect cooperation and confidence.
- 3- To provide dentist with information concerning patient's past and present medical, dental and personal history.
- 4- To provide information about patient's systemic health which may greatly affect the treatment plan and prognosis and diseases that could be transmitted to the dentist, his staff or other patients.
- 5- It serves as a legal document.

How you take history:-

During history taking the dentist should encourage his patient to describe his symptoms in his own words, interrupting his story only to explain a point or stop a useless talk.

A clear and concise summary of patient's complaints should be recorded in

the case sheet. The symptoms should be recorded or being listed in order of its importance (e.g. pain, swelling, bleeding).

During taking the history give your patient your whole attention and never take shortcuts.

You have to avoid speed in taking the history, so you have to give the patient a suitable time to give all information, because hurry in taking history may lead to many pitfalls that affect the accuracy or completeness.

You have to avoid the leading questions (e.g. does the pain comes on taking hot or cold?) it's better to ask him what is or what are the things that brings pain to you? Or anything hurt you?

During taking history don't depend on the patient diagnosis or the diagnosis of a previous doctor, so you have to ask the patient to describe his complaining-only-to establish your diagnosis process.

Components of the patient history:-

The case history may include commonly the following sections or components:-

- 1- Biographic data (personal history).
- 2- Chief complaint (C.C).
- 3- History of the chief complaint (history of the present illness) H.P.I.
- 4- Past dental history.
- 5- Medical history and systems review.
- 6- Family history.

Biographic data:-

This includes the full name of the patient, age, sex, address and telephone number and occupation. Those information may aid or contribute to the diagnosis since some medical problems have a tendency to occur in a particular age group, sex or race. The patient occupation maybe associated with a particular disease or may influence the type of therapy.

Chief complaints (C.C):-

The chief complaint is usually the reason for the patient's visit. The chief complaint(s) is best stated in the patient's own words in a brief summary of the problems (e.g. pain, swelling, ulcer, paraesthesia, numbness, clicking, halitosis, bleeding, trismus). If the patient complaining of several symptoms in which case they should be listed, but with the major complaint first.

History of the present illness (H.P.I):-

This part of the story must be gone into complete details and get the patient to **tell** the story in his fashion, never ask the patient leading questions and you have **to see** if the patient in a condition able to give you a history which is reliable and his statement can be relied upon.

It's best to start by asking the patient about:-

- I- Duration (record the length of the complaint).
- 2- Onset (date of onset, manner of onset).
- 3- Precipitating/predisposing factors, (e.g. hot, cold, sweet).
- 4- Characteristic, and this includes:-
 - a) Nature e.g. (continuous, intermittent, stabbing).
 - b) Severity e.g. (mild, severe, very severe).
 - c) Location.
 - d) Radiation (feeling of pain in site other than that of causative lesion, called referred pain).
 - e) Temperature features.
 - f) Aggravating- factors.
 - g) Relieving factors.
 - h) Associated constitutional symptoms and signs.
- 5- Course and progress.
- 6- Therapy:-
 - a) Type of therapy and dose.

- b) Provider.
- c) Effect of therapy.
- d) Date of therapy.

7- Other information.

So if a patient comes with a chief complaint (pain) very detailed history of the pain should be taken and particular attention paid to the following points:-

- a) **The duration of pain:** Whether any incident which might have played some part in the etiology of the pain precede its onset (e.g. a blow on the jaw, dental treatment), duration record the length of the pain.
- b) **Site of the pain:** The patient should be asked to point to the place where the pain is felt, using his finger.
- c) **Any radiation of the pain:** If the pain radiates, the patient should be asked to demonstrate its course with the tip of his finger. On other occasions pain maybe felt in a site other than of the causative lesion or remote from the diseased area and this type called "referred pain", e.g. pain of pericoronitis radiates to the ear.
- d) **The precise characteristic of the pain:** the pain maybe described as sharp, severe, dull, throbbing, excruciating, lancinating, mild, continuous, intermitted, all these objectives can be applied to the pain in different pathological process which may help you in the diagnosis. (In acute pulpitis, the pains is sharp and severe, in acute dental abscess the pain is dull, throbbing and severe and the tooth tender, in acute maxillary sinusitis the pain is dull, throbbing and continuous).
- e) **Timing of pain:** Some pains are characteristically worse at particular time in the day e.g. pulpal pain often wakens the patient at night and tend to keep him awake, in-acute periodontitis the pain is worse at meal time.
- f) **Any factors which precipitate the pain:** Pulpal pain is often

precipitated by thermal and osmotic stimuli (hot, cold, sweet). Periodontal pain often precipitated by biting and chewing.

- g) **factors or Any drugs which relieve pain:** This will give you an idea about the nature and duration of severity of the pain.
- h) **The presence of other symptoms:** Like when patient says that, “the pain started two days ago, then a swelling appeared after that” or “discharging sinus appeared” or “a discharge of pus” or he/she says: “pain, swelling then Parasthesia of the lower lip” ...etc.
- i) **The patient also may be asked about relevant past medical history** which may assist you in the diagnosis of the pain like patient with facial pain of vascular origin like migraine, or chronic psychosomatic origin or angina (angina pectoris) pain. In addition to that the patient asked about his opinion of the cause of the pain.

Another example of complaint is:-

Patient presented with a "lump or mass":-.

The oral surgeon must be ascertained by asking some questions: -

- 1- How long the swelling has been present.
- 2- Whether it is getting larger or smaller or fluctuated in size.
- 3- What are the symptoms of the lump: The lump maybe painful or not. If the lump is associated with Parasthesia or numbness of the lower lip for example.
- 4- Whether there is any possible cause for the swelling e.g. trauma, injuries, or systemic illness known to the patient.
- 5- What made the patient notice the lump? By feeling or because it is painful or someone else noticed it and told him.

Past dental history (P.D.H):-

The past dental history includes:-

- 1- The frequency of previous visits (e.g. previous extractions or oral surgical procedures).
- 2- Any difficulties or complications (e.g. excessive bleeding or fainting).
- 3- Determination of the availability of past dental or oral radiographs. In other words, it is important to ask the patient about any type of dental or oral treatment received before, and if there is any complications or unsatisfaction arise and his impression about the type of treatment.

Medical history and systems review (M.H):-

The patient's medical history includes review, the past and the present illness or diseases because:-

- 1- These information (M.H) may aid in the diagnosis of various conditions occurring or has oral manifestation that are related to specific systemic disease (e.g. aids, leukemia).
- 2- The presence of many diseases may lead or need modification for the treatment plan, and affect the manner in which therapy is provided.
- 3- Drugs used in treatment of some systemic diseases can also have effects on the mouth (have oral manifestation), or dictate some modification to the dental or surgical treatment (e.g. anticoagulant drugs, chemotherapy).

The past medical history includes:-

- 1- Previous serious illness or diseases.
- 2- Childhood diseases.
- 3- Hospitalization.
- 4- Operations.
- 5- Injuries to the head and neck.
- 6- Allergy to drugs or general allergy.
- 7- Listing of medication taken in the last six months.

Some examples of serious illness:-

- ♦ Heart attack or diseases (e.g. myocardial infarction, angina pectoris).

- ◆ Stroke (cerebrovascular accident C.V.A).
- ◆ Hypertension.
- ◆ Heart failure.
- ◆ Bleeding disorders.
- ◆ Diabetes.
- ◆ Rheumatic fever or disease.
- ◆ Hospitalizations may indicate past disease and how it was treated.
- ◆ Aids (acquired immune-deficiency syndrome).
- ◆ Viral hepatitis.
- ◆ Neoplasm and the method of treatment (surgical, cytotoxic drugs) especially if the growth in the head and neck region **or** previous radiation (radiotherapy).
- ◆ Allergic reaction to drugs.

Review of the systems: Is that part of medical history covering each major system of the body. Review of systems lead to concentration on the signs and symptoms related to that system disorders, which dictate us to more investigations or referring of the patient for medical evaluation and preparation. The review of systems includes:-

Cardio vascular system, respiratory system, central nervous system, genitourinary system, musculoskeletal system, endocrine system, ears, eye, vital signs (blood pressure, pulse, temperature, respiratory rate).

Components of medical history

Any patient come to you should be asked certain concise questions that aid you to have medical history, and this includes:

1. If he is currently receiving any medical care or under supervision of any clinician.
- 2 . Whether he has been hospitalized and Why?
- 3 . If you have any serious illness remembered by the patient?
- 4 . If you have any surgical operation before?

5 . If your patient takes any type of drugs before in the past or present time?

Family History: (F. H.)

Details of (F.H.) may reveal valuable information about diseases that are occurring in families (e.g. Tuberculosis, Hemophilia, Psychiatric or neurotic disorders, Breast cancer) Congenital Anomalies such as lip clefts or palate clefts.

Clinical Examination

Careful history taking should be followed by a thorough and systematic clinical examination.

Diagnostic instruments include:

- 1.Dental Mirror.
- 2.Dental Prone.
- 3.Tweezer.

The clinical examination in Oral Surgery should be systematic and should be always includes the vital signs like Body Temperature, Pulse Rate, Blood Pressure, respiratory rate, also should have always Comparative Observations of both sides of the body and the oral cavity.

Clinical Examination includes:

- 1 . Extra oral Examination.
- 2 . Intra oral Examination:

In extra oral examination we consider the general evaluation e.g. Observation the patient Posture, Gait, Facial Form, Nutrition Status, Speech, Body movement, Skin, Hair, Vital Signs. In addition to that we examine the area of the head and the neck thoroughly and this includes:

- Examination of the Temporomandibular Joint.
- Lymph Nodes.
- Salivary Glands.
- Bones of the Skull.

-Sinuses (Maxillary Sinus)

-Ear, Eye & Perioral Tissues.

-Neck examined for enlarged Thyroid Gland, Lymph Nodes of the neck, & swelling.

Methods of Clinical Examination:

In Clinical practice, examination of patient involves FOUR ROUTINE PROCEDURES

1. INSPECTION.

2. PALPATION.

3. PERCUSSION.

4. AUSCULTATION.

•**INSPECTION (VISUAL)** :- At the start of every examination you must begin by Looking at patient as a whole before looking at the region in question for signs that may provide clue for a Diagnosis any changes in the color, or asymmetry of the face and sclera of the eyes, any growth, ulceration, Scar, Defect, Loss of tissue should be inspected by your eye.

PALPATION:- Next use your fingertips to feel for tender spots , Lump , Fluctuant Swelling , & Mobile teeth . Palpation gives information about texture, Dimension, consistency, Temperature & Functional Events

.

PROBING: - Is the palpation with an instrument & is one of the most important diagnostic techniques used in Dentistry. The teeth are probed for caries with the dental probe & periodontal probe is used to measure the periodontal sulcus depth. Lacrimal probe used for examination of parotid & submandibular salivary gland ducts. Fistulous tracts can be probed with Gutta Percha points to determine the origin of the Fistula.

PERCUSSION: - Is the technique of striking the tissue with fingers or an instrument (e.g. Handle of the mirror). The examiner listens to the resulting sounds & observes the response of the patient. Extra orally, percussion is often used to detect tenderness in the frontal and maxillary sinuses by tapping the finger tips against a finger placed over the sinuses. Intra orally, percussion is used to evaluate the teeth by tapping the teeth with mirror handle; this technique may induce pain in the area of inflammation from periodontal diseases or periapical abscess.

AUSCULTATION- Is the act or process of listening for sounds within the body.
e.g. Auscultation to the clicking in the Temporomandibular Joint (T.M.J.) by the use of stethoscope. Auscultation technique is rarely used in Dentistry.

Extra oral Examination

Objectives: -

1. To evaluate any general abnormalities & in particular those of the head & neck region.

2. To look for signs & symptoms of the patient that could influence diagnosis & treatment. This examination includes: -

*General examination of the patient including his Posture, Gait, Facial Form, Nutritional, Status, Habits, Speech, Skin, Hair, nail, & all exposed parts of the body.

*Examination of head include T.M.J., Lymph Nodes (Submandibular, Sub mental, etc.), Salivary gland Parotid & Submandibular gland etc.), Bones of skull, Sinuses (Maxillary Sinus), ear, eyes, & peri oral tissues.

Examination of neck include Thyroid gland, Lymph Nodes (Cervical node anterior & posterior) & other midline structures & muscle (The neck should be inspected for midline or lateral swelling, scar, or any inflammatory lesions palpated for Thyroid enlargement or Cervical lymph node enlargement.

The T.M.J, palpated for any clicking or pain, & asking the patient to open and close the mouth to see if there is any limitation of opening (Trismus), or deviation of occlusion.

The eyes should be examined for Exophthalmos or proptosis, pallor of Conjunctiva may indicate Anemia. Sclera of the eye should be also examined; Yellow discoloration may indicate Hepatitis or Obstructive Jaundice (Liver Diseases).

Intraoral Examination: -

Objectives

- 1.To detect soft tissue abnormalities.
- 2.To evaluate the status of teeth and other hard tissues.

Intraoral examination consists of evaluation of the following areas in systematic ways: Lips, Labial & Buccal Mucosa, Muco-buccal folds, floor of the mouth, Tongue, Hard & Soft Palate, Oropharynx, Muscle of mastication (Lateral & Medial muscles), Teeth, Gingiva, Orifice of the ducts of the Parotid and Sub mandibular Glands.

intra oral examination should begin with the observation of the mouth for extent or deviation. The extent of the opening its averaging between 35 – 55 mm and usually described in terms of the of the width of the patient's fingers e.g. 3 or 4 fingers opening, then we look for the oral Hygiene weather is good, fair poor, or very poor.

We use the mouth mirror to reflect or retract the cheek & the lips with good light, to evaluate the condition of the vestibules, floor of the mouth, ventral surface of the tongue avoid any overlooking of these hidden areas, also the opening of the salivary glands ducts examined for enlargement, redness, & discharge.

The ventral, lateral, dorsal, aspects of the tongue should be examined for the presence or absence of papillae, fissuring, ulceration, growth, indurations, limitation in extraction, & lateral movement.

Hard & soft tissue examined for swelling, ulcers, sinuses, & perforation.

Mucosal changes may be observed in association with Leukoplakia, Tobacco irritation, Pigmentation.

The gingiva examined for the slipping, the color & the size of interdentially papillae, any cause of food impaction, the presence of calculus, sinuses or retained roots, pocket etc...

Teeth Examination:

The presence, absence, appearance, mobility, retained roots, retained deciduous teeth, Malposed teeth, mobility of teeth classified as nil, marked or gross Attrition (Exposed dentin), Exposed roots, Carious Lesions, Vitality test (hot & cold application, Pulp tester, etc...). The teeth might be percussed or probed with our instrument to see any tenderness or sensitivity of the teeth. Any edentulous area should be dried with a piece of cotton and examined for the presence of retained roots or discharging sinuses. Occlusion should be examined in closed and rest position the presence of open bite, type of occlusion (Neutro occlusion class I, or disto occlusion class II, or mesio occlusion class III).

Investigations

Sometime the clinician determines that additional tests are needed to clarify some aspects of the diagnosis such tests include radiographic examination, Biopsy (Histological Study), Cytology, Aspiration, Clinical Laboratory studies.

***Radiographic examination:**

Is one of the special methods of examination which mostly used in the Oral Surgery. It provides information about hard & soft tissues that are hidden for eye which aid in diagnosis & to evaluate the progress of the disease. For example, Peri apical, occlusal, & extra oral views like lateral oblique of the Mandible radiograph. CT scan, MRI

•VITALITY TEST: -

1. Hot application (e.g. Hot instrument)
2. Cold application (e.g. Ethyl Chloride Application)
3. Electrical pulp Tester. Used to check the vitality or response of teeth.

BIOPSY:-

Small pieces of tissue taken from the lesion submitted to microscopical examination (Histopathology examination). Biopsy could be incisional or Excisional, Exfoliate

Cytology. It is used to confirm the diagnosis of the lesion.

•ASPIRATION: -

the withdrawal of fluid from the lesion may aid in diagnosis. For example, aspiration of pus indicates an inflammatory process like abscess or in infected cyst. Aspiration of yellow fluid may indicate cystic lesion, aspiration of blood may indicate Vascular lesion like Hemangioma, etc.... Aspiration is one of the methods used to aspirate fluid from swelling for evaluation the nature of that swelling which may assist in Diagnosis.

•LABORATORY TEST: - LIKE

1. bacteriological examination.
2. Hematological examination
3. Urine analysis (GUE)
4. Blood Chemistry & Serological examination.
5. Culture & sensitivity test.

All these tests or any one of these tests might be ordered to aid as in confirming our Diagnosis.

So, collection of all information taken from the history & clinical examination & accessory information (Special tests) must be evaluated, analyzed to reach the final Diagnosis.

•PATIENT RECORD (MEDICAL) RECORD: -

It consists of: -

1. Case sheet.
2. All radiographs.
3. All investigation papers.
4. Referring papers.

Objectives & Benefits: -

1. It assist in Diagnosis of the diseases.
2. For follow up & future checking.
3. For statistical analysis.
4. For studies & educations.
5. For Medico legal purposes.

Oral Surgery

Elevators:-

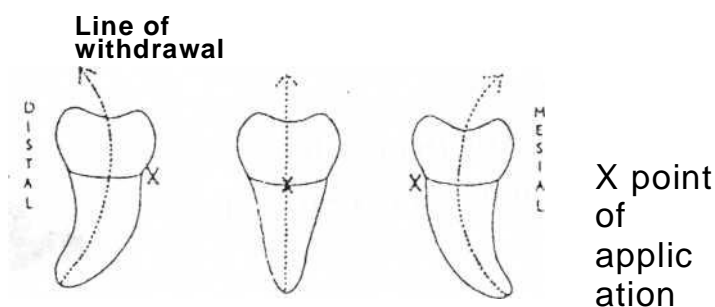
Are exo-levers, instrument designed to elevate or luxate the teeth or roots from their bony socket in close or surgical method of extraction to force a tooth or root along the line of withdrawal.

Line of withdrawal:-

Is the path along which the tooth or root will move out of its socket when minimal force is applied to it, and this line is primarily determined by root pattern (long axis of the tooth).

Point of application:-

Is the site on the root at which force must be applied to effect delivery, it is determined by the line- of withdrawal. We have buccal point of application, distal point of application, and mesial point of application.



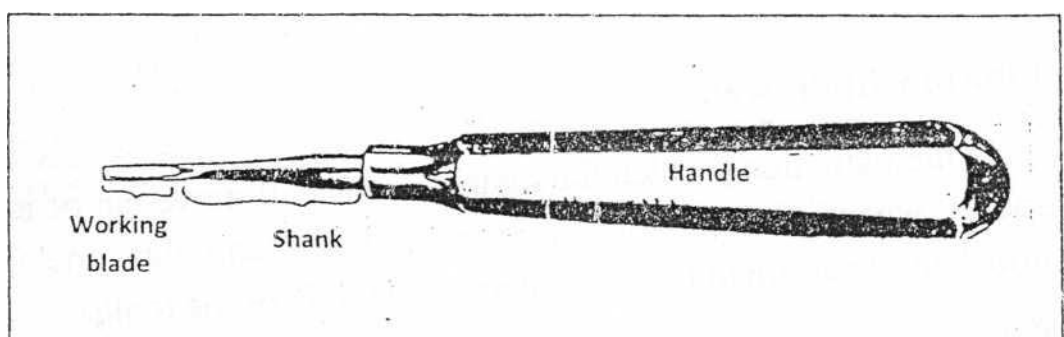
Parts of elevators:-

All elevators have the following parts:-

I-Handle: This maybe a continuation of shank or at right angle to it.

II- Shank.

III- Blade: This part engages the crown or root and transmit force to the tooth, bone or both. The working side of the blade is either concave or flat.



Mechanical principles of uses of elevators:-

The work principles as applied to the use of elevators maybe that of:-

- 1- Lever principle.
- 2- Wedge principle.
- 3- Wheel and axle principle.
- 4- Combination of these principles.

Clinical uses of elevators:-

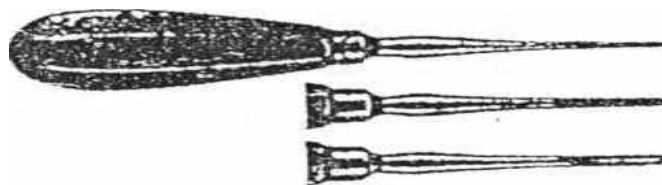
- 1- Elevators are used to luxate and remove teeth which cannot be engaged or grasped by the beaks of forceps (e.g. impacted teeth, malposed teeth), also badly carious teeth, teeth with heavy filling.
- 2- To remove old roots and fractured roots and sectioned roots.
- 3- To loosen teeth prior to use of forceps.
- 4- To split teeth which have had grooves cut in them, as in separation of roots.
- 5- To remove small amounts of bone to create point of . application for the beaks of forceps, or removal of interseptal bone.
- 6- Any tooth resisting normal extraction force by extracting forceps.

Elevators commonly used:-

There are so many elevators available but few are widely used because of their efficiency.

1-straight elevator:-

Elevator in which the blade, shank, and the handle are straight. The working blade or end is blind and round, there are many types and sizes of straight elevators,



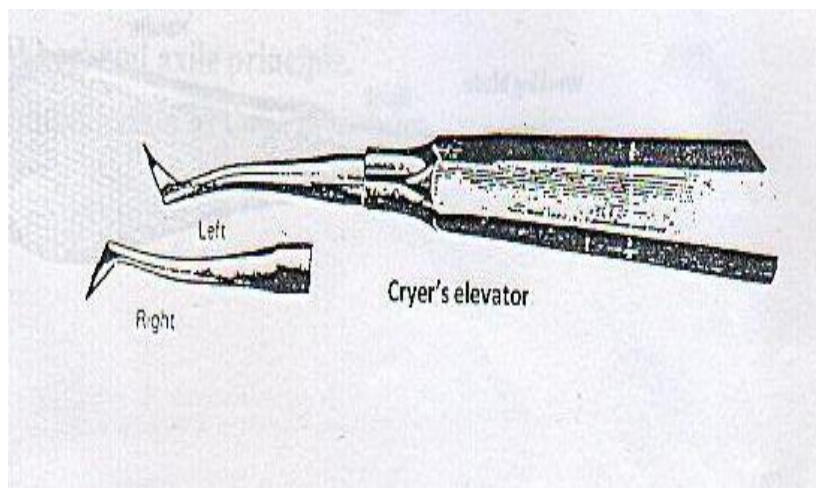
2-Coupland's chisel (elevator):-

It is similar to straight elevator but the working end is sharp and straight cut, used for chiselling of bone to create point of application or to split of teeth. It's of different sizes, size 1, size 2, size 3. Depending on the width of the working end.



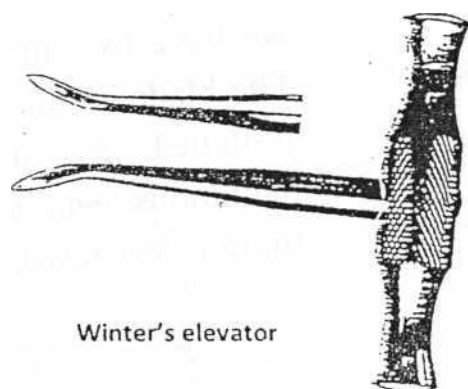
3-Cryer's elevators:-

In this type the working blades are sharp, pointed and triangular in shape just like a claw, forming an angle with the shank of the elevators. These are pair instrument mesial and distal (right & left) designed to fit the root surface on mesial and distal surface. It's mostly used for removal of retained root of the lower molar and for elevation for impacted teeth after surgical exposure of the bifurcation of the tooth.



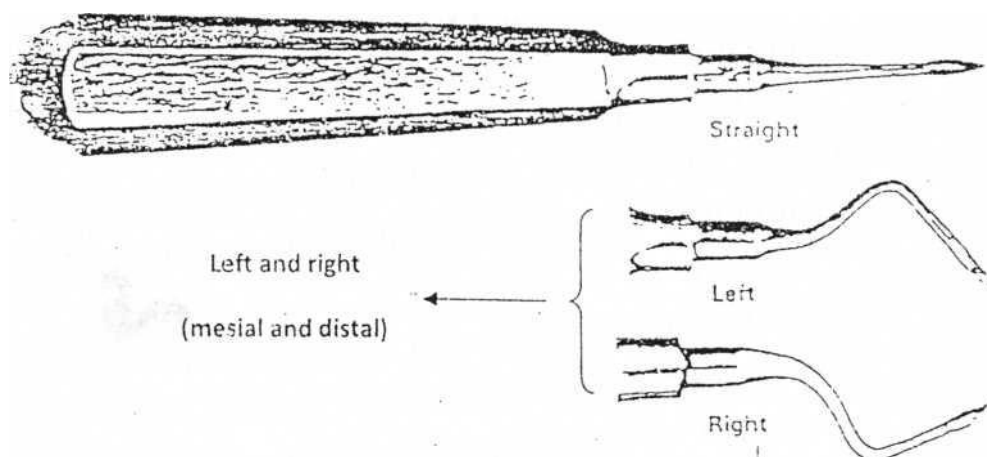
4- Winter's elevator:-

In which the working end is the same that of Cryer's elevator but the handle is in right angle to the shank so it is called winter's (T-bar) cross-bar handle elevator. Winter's elevators are very powerful and great force maybe applied or generated (sufficient to fracture the mandible) so the use of this elevator should be with great care to avoid fracture of the jaw.



5- Apexo elevators:-

The working blade is long, the margins are sharp, we have 3 Apexo, 2 angled and 1 straight (mesial, distal, straight). The blade forming an angle with the shank, this elevator is used mainly for removal of apical fragments of root deeply present in the socket of the lower jaw especially morals. We push it between the socket and the root to loosen the fractured tip and remove it from the socket.



6-War-wick James elevators:-

It is a light duty elevator. It's like Cryer's elevator, also we have two angled (mesial and distal) and one straight. The blade is short and the end is rounded and the handle is flattened, it's used for extraction of retained roots, deciduous teeth, anterior lower teeth extraction, and where there is less resistance area. e.g. extraction of upper wisdom tooth.



Guiding principles for use of elevators:-

The following rules should be observed when using elevators in general:-

- 1- Never use an adjacent tooth as a fulcrum, unless that tooth to be extracted itself in the same visit, and the fulcrum should always be bony one (alveolar bone).
- 2- An elevator should always be supported to avoid slippage and injury to the patient.
- 3- Avoid the use of excessive force if the tooth/root is resist luxation, by gentle rotation, then stop, look for the obstruction for elevation and deal with it.
- 4- The direction of force should be such that the roots are not directed toward major structures such as the maxillary antrum.
- 5- An elevator should never be used "blindly" in the socket
- 6- If an application point is not present, then this should be created by careful removal of bone.
- 7- Elevators should always be sterile and sharp.
- 8-- The sharp edges of the working blades are placed between the alveolus and the root surface and gently rotated apically along the long axis of the elevator to luxate or displacing the tooth or root.

Complications of use of elevators:-

Although elevators are very useful instrument for facilitating extraction of teeth, but misuse or miss-judgement may lead to some complications, part of it may be serious:-

1- Injury to the soft tissues, like injury to the tongue, floor of the mouth, soft and hard palate, caused by slipping of elevator during its use

2- Wrong application of force or excessive force may lead to fracture of jaw especially the lower jaw at the angle of the mandible, also excessive force may lead to crushing of the alveolar bone and fragmentation

3- Fracture of maxillary tuberosity especially in extraction of upper third molars.

4- Uncontrolled force may lead to displacement of roots into maxillary sinus, infratemporal fossa, buccal soft tissue, submandibular space or inferior dental canal.

5- Use of elevator in periapical area of abscessed tooth may cause spread of infection to the surrounding tissue.

6- Tip of instrument (working blade) may be fractured and remain in the socket causing postoperative infection or delay healing, so always check the tip of instrument after use.

So most problems with elevators arise from:-

- a) Miss-judgement of amount of force exerted.
- b) Improper positioning of the elevators.

“Neurophysiology”

Review of the nervous system and impulse generation:-

The basic structural unit of the nervous system is the **neuron** (fig: 1) which is able to transmit messages between the central nervous system and all parts of the body, it consists of three parts: cell body axon and dendrites. The dendrites which end in the free nerve endings respond to stimulation produced in the tissue they lie, provoking an impulse that is transmitted centrally along the axon. The axon which is the single nerve fiber, is a cable like structure composed of neural cytoplasm and covered by thin sheath which is the nerve membrane; in some nerves an insulating lipid rich layer of myelin covers this membrane. Current theories stated that nerve excitability and conduction are both attributable to changes developing within the nerve membrane.

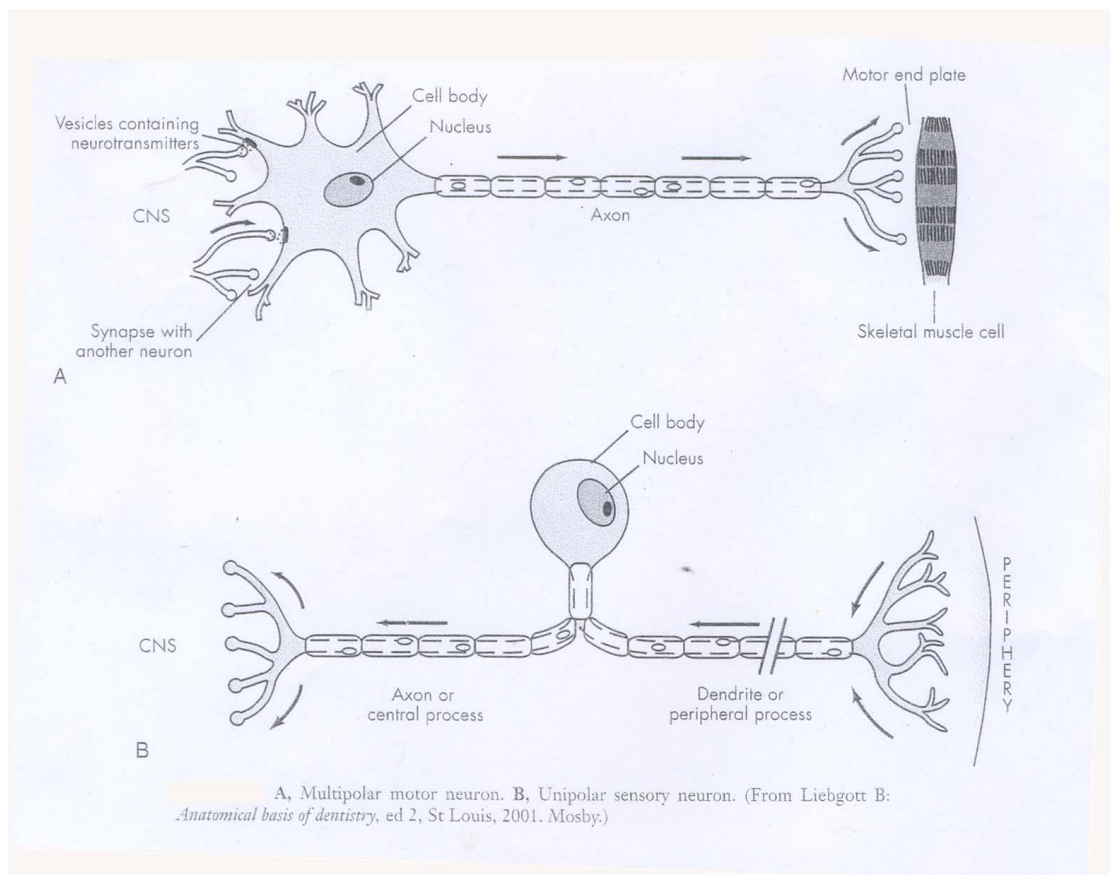


Fig. 1 A. motor neuron.

B. sensory neuron.

Nerve membrane:-

The nerve membrane consists of two layers of lipid molecules (phospholipids) and associated proteins, lipids and carbohydrates. All biologic membranes are organized to (1) block the diffusion of water soluble molecules. (2) be selectively permeable to certain molecules via specialized channels and (3) transduce information by protein receptors responsive to chemical or physical stimulation. Since the nerve membrane exhibits selective permeability, therefore significant differences exist for ions between the intracellular and the extracellular concentrations. Accordingly high concentration of K inside while high concentration of Na and Cl outside the nerve membrane.

In some nerves an insulating lipid rich layer of myelin covers this membrane (fig: 2). the outer most layer of myelin consists of the schwann cell cytoplasm and its nucleus. A gap between two adjoining schwann cells and their myelin spirals called node of ranvier, at these nodes the nerve membrane is exposed directly to the extracellular medium.

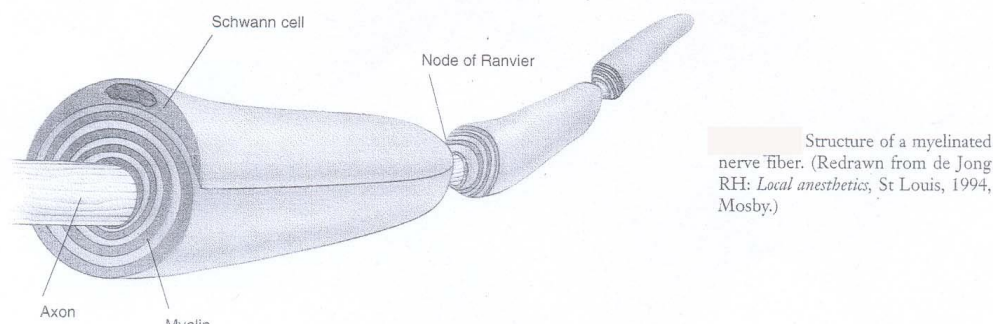


Fig. 2 the structure of a myelinated nerve fiber.

Impulse generation:-

The function of a nerve is to carry messages from one part of the body to another. These messages in the form of electrical action potentials are called impulses. Impulses are initiated by chemical, thermal, mechanical or electrical stimuli.

Resting state:-

(fig3 step1) In the resting state the nerve membrane possess a negative resting potential (-70mv) that comes from different concentrations of ions on either side of the membrane (due to the selective permeability property).

Depolarization:-

(Fig 3 step 2) when a stimulus excites a nerve this will lead to an increase in permeability of the membrane to Na ions, the rapid influx of Na ions to the interior of the nerve will cause depolarization of the nerve membrane from the resting level to its firing threshold of approximately (-50) to (-60) mv. The firing threshold is actually the magnitude of the decrease in the negative membrane potential that is required to initiate an action potential (impulse). When firing threshold is reached, permeability of the membrane to sodium increases dramatically and at the end of depolarization the electrical potential of the nerve is reversed, an electrical potential of + 40 mv exists. This process takes 0.3 millisecond.

Repolarization:-

The action potential is terminated when the membrane repolarizes (fig 3 step 3) and this is achieved by increase permeability to K ions, resulting in the efflux of K ions (movement to the outside) leading to membrane repolarization and return to its resting potential (-70mv). This process takes 0.7 milliseconds.

The movement of Na ions to the inside of the nerve during depolarization and the subsequent movement of K ions out of the nerve during repolarization are passive process (not requiring energy) since each ion moves along its concentration gradient. After repolarization when the nerve returns to its resting state a slight excess of Na ions exists within the nerve cell and a slight excess of potassium exists extracellular, accordingly a period of metabolic activity begins called sodium pump leading to the movement of Na to the outside as well as movement of K to the inside, this pumping mechanism require energy that is coming from oxidative metabolism of adenosine triphosphate (ATP).

Accordingly action potential could be defined as a transient membrane depolarization that results from a brief increase in the permeability of the membrane to sodium and also from delayed increase in the permeability to potassium.

Once an impulse has been initiated it moves along the surface of the axon to the CNS.

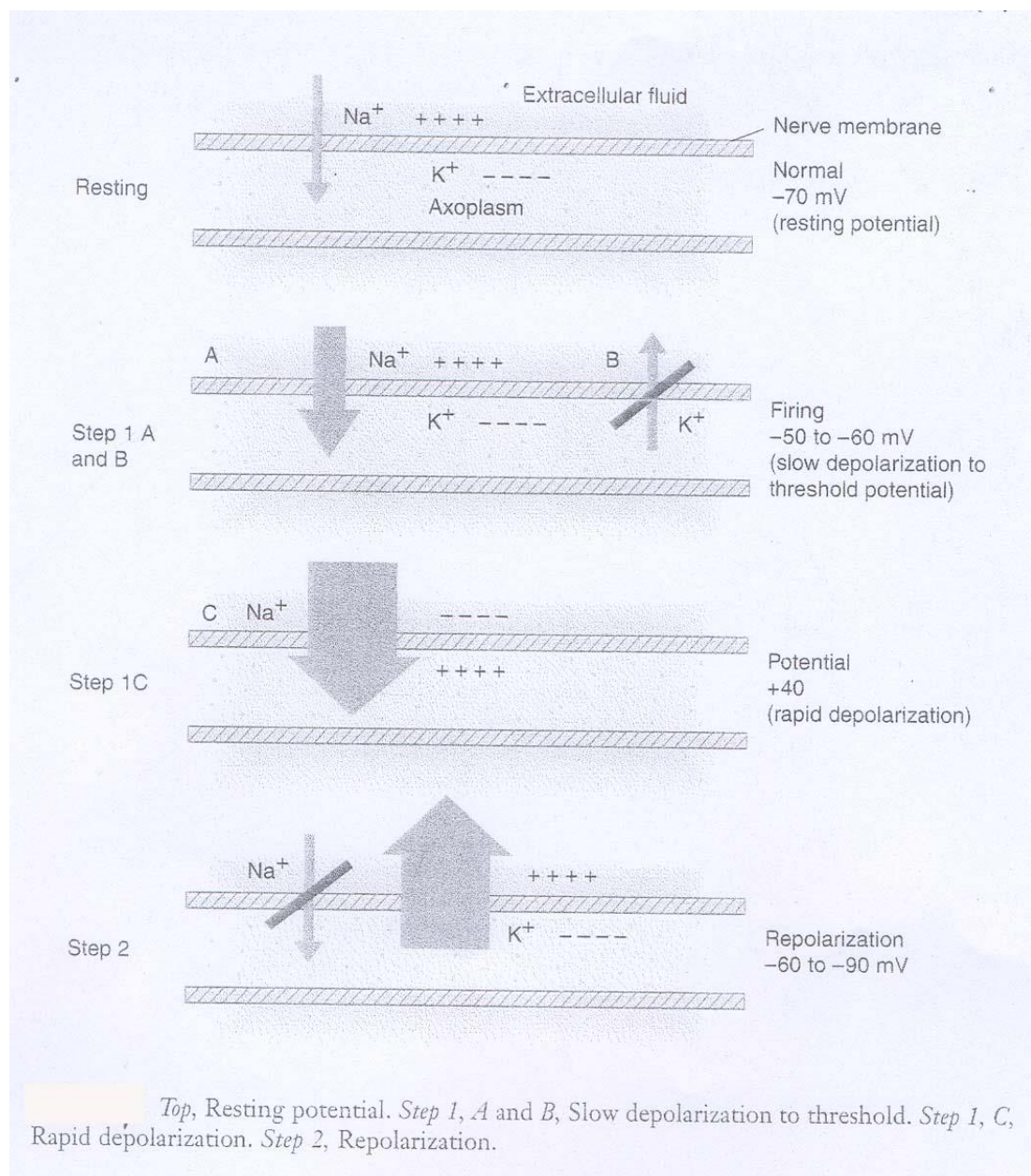


Fig.3 Steps of the action potential.

Note:-

A peripheral nerve is composed of hundreds to thousands of tightly packed axons (fig: 4) these axons are covered by several layers of fibrous and elastic tissues in which blood vessels and lymphatics course throughout these layers.

Individual nerve fibers (axons) are covered with perineurium and separated from each other by the endoneurium. The perineurium then binds these nerve fibers together into bundles called fascicule.

The inner most layer of perineurium is the perilemma which represent the main barrier to diffusion of local anesthetic into a nerve. The whole fasciculi are contained within a loose connective tissue called the epineurium which represent 30% to 75% of the total cross section of a nerve.

Local anesthetics are readily able to diffuse through this tissue because of its loose consistency. Nutrient blood vessels and lymphatics traverse the epineurium. These vessels absorb local anesthetic molecules thus removing them from the nerve.

Induction of local anesthesia

Following the administration of a L.A into a tissue near a nerve, molecules of the L.A will move from one site to another according to their concentration gradient so it will move from site of deposition toward the nerve (this process termed diffusion).

Fasciculi that are located near the surface of the nerve are termed **mantle bundles** (fig 4) they are first ones reached by the local anesthetic and they are exposed to a higher concentration of it. These bundles will be blocked completely shortly after the injection of a local anesthetic.

Fasciculi that are located near the center of the nerve are called **core bundles** these bundles are contacted by a local anesthetic only after a much delay and by a lower anesthetic concentration because of the greater distance that the solution must move and the greater number of the barriers it must cross.

As the local anesthetic diffuses into the nerve it becomes increasingly diluted by tissue fluids and is absorbed by capillaries and lymphatics, thus the core fibers are exposed to a decreased concentration of local anesthetic a fact that may explain the clinical situation of inadequate pulpal anesthesia developing in the presence of subjective symptoms of adequate soft tissue anesthesia. Complete block of all nerve fibers in a peripheral nerve requires an adequate volume as well as an adequate concentration of the local anesthetic be deposited.

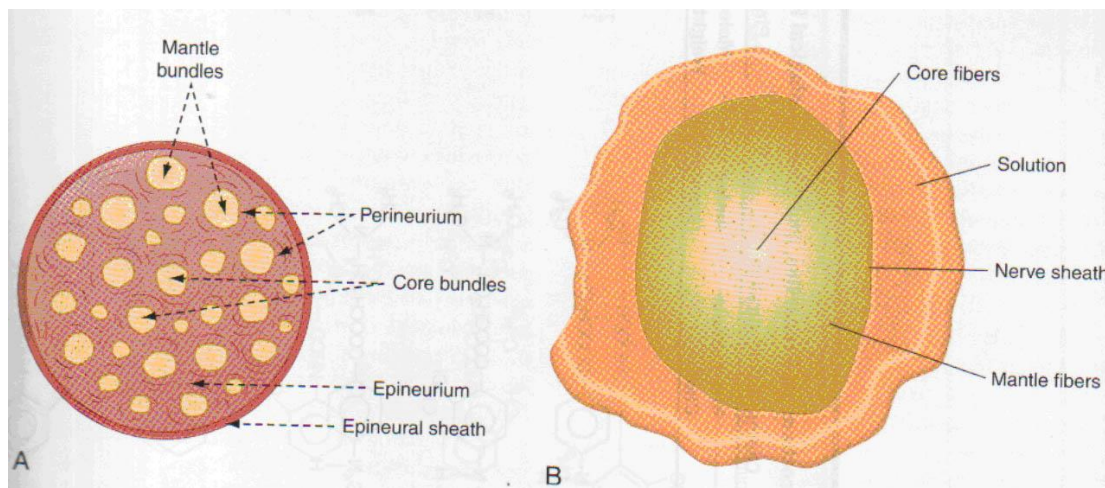


Fig. 4 Cross section of a peripheral nerve.

Classification of nerve fibers:

The fibers of peripheral nerves are classified according to the basis of electrophysiological and morphological differences:

Type A fibers: largest fibers further divided into four groups:-

- 1) A- alpha (α): responsible for motor action & muscle proprioception.
- 2) A-beta (β): responsible for motor action & muscle proprioception.
- 3) A-gamma (γ): responsible for motor action & muscle proprioception.
- 4) A- delta (δ): responsible for fast sharp pain, temperatures, touch, & pressure

Type B fibers: preganglionic responsible for sympathetic activity.

Type C fibers: unmyelinated, the most numerous in the peripheral nervous system. It is responsible for conduction of dull or burning pain.

Noxious stimuli are transmitted to the CNS by way of **A δ & C** fibers. The lightly myelinated A δ fibers are responsible for conduction of sharp, bright pain while unmyelinated C fibers conduct dull or burning pain.

“Mechanism of action of local anesthesia”

The concept behind the action of LA is that it prevents both the **generation** and the **conduction** of a nerve impulse thereby they act like a roadblock between the source of impulse (as a surgical incision in soft tissue) and the brain.

Many theories have been suggested to explain the mechanism of action of LA, in general, the nerve membrane is the site at which LA agents exert their pharmacological actions, the most popular theories are:

1. Membrane expansion theory: this theory states that anesthetic molecules diffuse through the nerve membrane producing a general disturbance of the bulk membrane structure, expanding some critical regions in the nerve membrane and decrease the permeability to sodium ions (decreased diameter of sodium channels), thus inhibiting both conduction and nerve excitation.

2. Specific receptor theory: this is most favored theory today, it proposes that local anesthetics act by binding to specific receptors in the sodium channel (protein channel) in the nerve membrane, the action of the drug is direct, not mediated by some changes in the general properties of the cell membrane. Once the local anesthetic has gained access to these receptors permeability to Na ions is decreased or eliminated and nerve conduction is interrupted.

“Factors Affecting the Local Anesthetic Action”

1. PH value

It is well known that the pH of a local anesthetic solution (as well as the pH of the tissue into which it is injected) greatly influences its action. Acidification of tissue decreases local anesthetic effectiveness. Inadequate anesthesia results when local anesthetics are injected into inflamed or infected areas. The inflammatory process produces acidic products: The pH of normal tissue is 7.4; the pH of an inflamed area is 5 to 6.

Local anesthetics containing epinephrine or other vasopressors are acidified by the manufacturer to inhibit oxidation of the vasopressor. The pH of solutions without epinephrine is about 6.5; epinephrine-containing solutions have a pH of about 3.5. Clinically, this lower pH is more likely to produce a burning sensation on injection, as well as a slightly slower onset of anesthesia.

Elevating the pH (alkalization) of a local anesthetic solution speeds its onset of action, increases its clinical effectiveness and makes its injection more comfortable.

Despite potentially wide pH variation in extracellular fluids, the pH at the interior of a nerve remains stable. Normal functioning of a nerve, therefore, is affected very little by changes in the extracellular environment. However, the ability of a local anesthetic to block nerve impulses is profoundly altered by changes in extracellular pH.

2. Lipid solubility

Increased lipid solubility of local anesthetics permits the anesthetic to penetrate the nerve membrane more easily. Local anesthetics with greater lipid solubility produce more effective conduction blockage at lower concentrations than less lipid soluble solutions

3. Protein binding

The degree of protein binding of the anesthetic molecule is responsible for the duration of local anesthetic activity. Local anesthetic possessing a great degree of protein binding appears to attach more securely to the protein sites and to possess a longer duration of clinical activity.

Longer-acting local anesthetics (e.g. bupivacaine) are more firmly bound in the nerve membrane (increased protein binding) than are shorter-acting drugs (e.g. lidocaine) and therefore are released more slowly from receptor sites in the sodium channels.

4. Vasodilator activity

The local anesthetic solution with greater vasodilator activity will increase blood flow to the area; this will lead to rapid removal of anesthetic molecules from the injection site, decreasing anesthetic potency and duration.

5. Vascularity of the injection site

The duration is increased in areas of decreased vascularity.

6. Presence or absence of vasoactive substance

The addition of a vasopressor into local anesthetic solution decreases the tissue perfusion thus increasing the duration of action.

As the local anesthetic is removed from the nerve, the function of the nerve returns rapidly at first, but then it gradually slows. Compared with the onset of the nerve block, which is rapid.

Oral Surgery (Local Anesthesia)

Lec.: 1

“Introduction to Local Anesthesia”

Many dental procedures, such as tooth extraction, are both painful and prolonged and should be performed without pain by using a local anesthesia.

Local anesthesia has been defined as “loss of sensation in a circumscribed area of the body caused by inhibition of the conduction process in the peripheral nerves”.

An important feature of local anesthesia is that it produces this loss of sensation without inducing loss of consciousness. In this one major area, local anesthesia differs dramatically from general anesthesia.

Many methods are used to induce local anesthesia. However, only those methods or substances that induce a transient and completely reversible state of anesthesia have application in clinical practice.

Brief history:

Local anesthesia as it is known today began when a German chemist (Albert Niemann-1860) successfully isolated the active principle of coca leaf, he named it **cocaine**. In 1898 professor Heinrich Braun introduced **procaine** as the first derivative of cocaine which is known as the first synthetic local anesthetic drug. In 1940 the first modern local anesthetic agent was introduced and known as **Lidocaine** (trade name Xylocaine). It relieves pain during the dental surgeries and produces the desired anesthetic effect for several hours.

Terminology:

Pain: According to the World Health Organization (WHO) pain is defined as an *“unpleasant sensation that occurs from imminent tissue damage”*. From a physiological perspective, pain is a warning system. During dental treatment, patients will experience pain as something unpleasant.

Analgesia: loss of pain.

Anesthesia: loss of sensation (loss of pain and touch sensation).

- In dentistry, local anesthesia is used to permit the performance of surgery or other painful procedures with no pain.

Paresthesia: altered sensation (tingling), such as when a local anesthesia is starting to work or its effect is wearing off. Or when a damaged nerve is regenerated.

The effect of local anesthetics on nerve fiber has been shown to be dependent on:

- 1- The duration of exposure of local anesthesia
- 2- Concentration
- 3- Volume of the solution

Relative analgesia: is a sedation technique in which the patient remains conscious but mental relaxation is induced by inhalation of a mixture of nitrous oxide and oxygen.

Pain threshold:-a point at which the patient feels discomfort when exposed to painful stimuli.

The patient who feels minimal discomfort from painful stimuli is having a high pain threshold

Many factors influence this response such as fear, apprehension and fatigue, all of which lower the pain threshold.

Premedication:-is the use of drugs to reduce a patient's apprehension prior to operative treatment.

Sedation techniques: involve the administration of a sedative to reduce anxiety in the conscious patient, usually, given by I.V route.

Properties (requirements) desirable for ideal local anesthetic:

1. It should not be irritant to the tissue to which it is applied.
2. It should not cause any permanent alteration of nerve structure.
3. Its systemic toxicity should be low.
4. The time of onset of anesthesia should be as short as possible.
5. The duration of action must be long enough to permit completion of the procedure.
6. It should be relatively free from producing allergic reactions.
7. It should be stable in solution and should readily undergo biotransformation in the body.
8. It should be sterile.

Of paramount importance is systemic toxicity, because all injectable and most topical local anesthetics are eventually absorbed from their site of administration into the cardiovascular system.

Several of the more potent injectable local anesthetics (e.g., procaine, mepivacaine) prove to be relatively ineffective when applied topically to mucous membrane. To be effective as topical anesthetics, these drugs must be applied in concentrations that prove to be locally irritant to tissues, while increasing the risk of systemic toxicity.

Lidocaine, on the other hand, is effective anesthetic when administered by injection or topical application in clinically acceptable concentrations.

Clinical duration of action does vary considerably among drugs and also among different preparations of the same drug, as well as by the type of injection administered (e.g., nerve block vs. supraperiosteal). The duration of anesthesia necessary to complete a procedure is a major consideration in the selection of a local anesthetic.

Uses or indications of local anesthesia

Local anesthesia is indicated in almost all the dental procedures, it is used to render the teeth, the supporting tissues and associated structures insensitive to painful stimuli.

A. Diagnostic:

Administration of LA can be a useful way of finding the source of patient's pain. An example of this is the pain of pulpitis which can be very difficult for both the patient and the dentist to isolate because of its tendency to be referred to other parts of the mouth or face, so LA can differentiate between maxillary and mandibular sources, and even between individual upper teeth provided they are not immediately adjacent.

Another example is a patient with myofacial pain who is convinced that an upper tooth is causing the problem, LA may help this patient and the surgeon in this situation to eliminate the tooth as the cause of pain and may thus avoid unnecessary treatment.

B. Therapeutic:

LA can constitute part of a treatment for painful conditions, for example, the use of block technique to eliminate the pain of dry socket. Blocks of the inferior alveolar nerve, mental nerve or infraorbital nerve can also be used for the treatment of trigeminal neuralgia when pain breakthrough.

C. Preoperative:

The provision of pain-free operation is by far the most common use of LA providing an effective and safe method for almost all outpatient dentoalveolar surgical procedures. It can in conjunction with sedation techniques allows more difficult procedures to be carried out without the additional risks of general anesthesia and this is particularly of value in patients with significant cardiovascular or airway diseases.

D. Adjunct to General Anesthesia:

LA is also given to patients undergoing oral and maxillofacial surgery under general anesthesia this serves the following purposes:

1. It reduces the depth of general anesthesia needed.
2. It reduces the arrhythmia during surgery when significant stimulation is taking place, for example when a tooth is being elevated.
3. It provides local hemostasis to the operative site.
4. Provides immediate postoperative analgesia.

E. Postoperative

After surgery with either local or general anesthesia the continuous effect of the anesthesia is the most beneficial way of reducing patient's discomfort, it helps to reduce or even eliminate the need for a stronger systemic analgesic.

Contraindications of local anesthesia

These can be divided into two groups:

1- Absolute contraindications:

A. History of allergy to local anesthetic agent

Local anesthetic agents belong to the same chemical group should not be used. However, LA agents in the different chemical group can be used. For example, if the patient gives a history of allergy to an ester local anesthetic agent, an amide LA agent should be used.

B. History of allergy to other constituents of the local anesthetic solution

When the patient has a history of allergy to any of the constituents of the LA solution, it should be avoided, a different type of solution should be used.

2- Relative contraindications:

A. Uncooperative patient such as mentally retarded patient.

B. Presence of acute inflammation or suppurative infection at the site of injection, to avoid the spread of infection (with the passages of the needle) from the abscess area to the deeper tissue.

C. Patient with a significant medical disease such as cardiovascular disease, hepatic dysfunction, renal dysfunction, clinical hyperthyroidism, etc.

D. Major surgical procedures (needs to be done under general anesthesia).

Advantages of local anesthesia

1. Less expensive than general anesthesia (GA).
2. No special preparation of the patient is needed as in GA.
3. No complicated apparatus is needed.
4. Less complication rate than GA.
5. The patient remains awake with no need for aftercare.
6. Can be used if GA is contraindicated (the patient is unfit for GA).
7. Anesthetist and other additional trained personnel are not required.
8. The technique is not difficult to master.

Oral Surgery

Lecture: 3

“Pharmacology of Local Anesthesia”

Constituents of local anesthetic solution (Local anesthetic cartridge):

1. **local anesthetic agent** (esters or amides type)
2. **Vasoconstrictor agent.** (will be discussed later)
3. **Reducing agent:** vasoconstrictors in local anesthetic solution are unstable and may oxidize, especially on prolonged exposure to sunlight. This will lead to brown discoloration of the solution and this is an indication that the solution should be discarded. In an attempt to overcome this problem a small quantity of sodium bisulphite, which compete for the available oxygen, is included in the solution. Since this substance is more readily oxidized than adrenaline or nor adrenaline, it protects their stability.
4. **Preservative:** the sterility of local anesthetic solution is maintained by the inclusion of a small amount of preservative. Some preservatives such as methyl paraben have been shown to produce allergic reaction in sensitized subjects.
5. **Fungicide:** in the past some solutions tended to become cloudy due to the proliferation of minute fungi, now a small quantity of thymole is added to serve as a fungicide and prevent this occurrence.
6. **Vehicle:** the anesthetic agent and the additives mentioned above are dissolved in modified ringer’s solution. This isotonic vehicle minimizes discomfort during injection.
7. **Distilled Water** it is used as diluting substance to provide the volume of solution in the dental cartridge.

“Local anesthetic agents”

Local anesthetics are drugs which upon topical application or local injection cause a reversible loss of sensory perception, especially of pain in a restricted area of the body; it provide pain control during dental therapy and interrupt the propagation of impulse preventing it from reaching the brain.

These drugs are listed by their percentage (%) concentration. The number of (mg) of an agent contained in the cartridge can be calculated by multiplying the percentage (%) concentration by the number of (ml) in the cartridge. Thus, a cartridge containing 1.8 ml of 2% local anesthetic solution contains 36 mg of the local anesthetic agent (2% mean that for each ml there is 20 mg, if the cartilage contains 1.8 ml then $1.8 \times 20 = 36$ mg of the local anesthetic agent in a single cartilage).

Classification of local anesthetics

The local anesthetic agents can be classified in various ways

1 – on the basis of occurrence in nature

- Natural (e.g. cocaine)
- Synthetic (e.g. lignocaine)

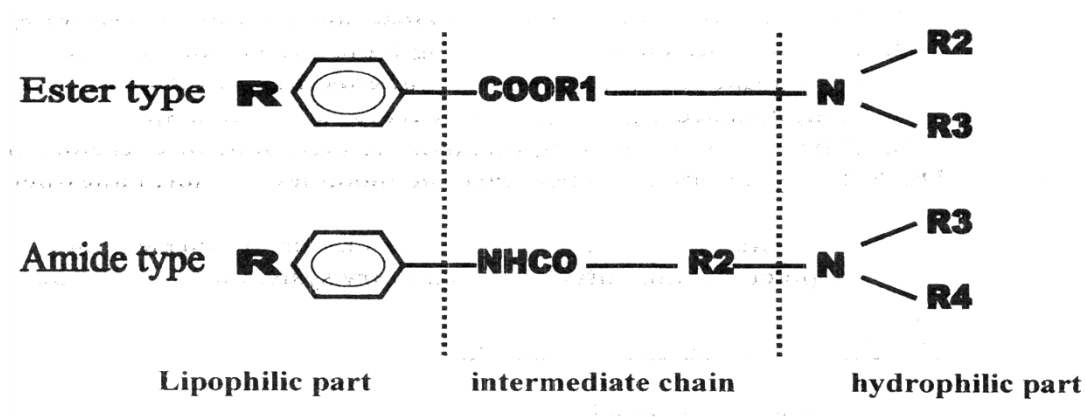
2 – on the basis of duration of action

- Short-acting (e.g. Articaine, lidocaine)
- Long-acting (e.g. bupivacaine)

3 – on the basis of chemical structure

- Ester (e.g. Procaine, Cocaine, Benzocaine)
- Amide (e.g. Lidocaine, Prilocaine, Articaine)

Local anesthetics are classified as either esters or amides according to their chemical linkages the chemical structure is shown below:



The lipophilic part is the largest portion of the molecule, which is aromatic in structure, while the hydrophilic part is an amino derivative of ethyl alcohol or acetic acid. The chemical structure is completed by an intermediate hydrocarbon chain containing either an ester or an amide linkage. All local anesthetics are amphipathic that is they possess both lipophilic and hydrophilic characteristics generally at opposite ends of the molecule.

Notes:-

1. local anesthetics without a hydrophilic part are not suited for injection but are good topical anesthetics (ex: benzocaine)
2. Ester linked local anesthetic (ex: procaine) are readily hydrolyzed in aqueous solution, while amide linked types (ex: lidocaine) are relatively resistant to hydrolysis.
3. A greater percentage of an amide linked drug is excreted unchanged in the urine than of an ester linked drug.

Pharmacokinetic of local anesthetics:-

Distribution:-

Once absorbed into the blood, local anesthetics are distributed throughout the body to all tissues. The blood level of local anesthetic is influenced by the following factors:-

1. Rate at which the drug is absorbed into the cardiovascular system.
 2. Rate of distribution of the drug from the vascular compartment to the tissue (more rapid in healthy patients than in those who are medically compromised e.g.; congestive heart failure patients).
 3. Elimination of the drug through the metabolic or excretory pathways.
- The last two factors act to decrease the blood level of local anesthetic.

Note:-

All local anesthetics are readily cross the blood brain barrier, they also readily cross the placenta and enter the circulatory system of the developing fetus.

Metabolism (biotransformation):-

A. Ester local anesthetics:-

Ester local anesthetics are hydrolyzed in the **plasma** by the enzyme **pseudo cholinesterase**. Procaine undergoes hydrolysis to para amino benzoic acid which is excreted unchanged in the urine. Allergic reactions that occur in response to ester drugs are usually not related to the parent compound (e.g.; procaine) but rather to para amino benzoic acid which is a major metabolic product of ester local anesthetics. Peoples having atypical form of pseudo cholinesterase get inability to hydrolyze ester local anesthetics and other chemically related drugs thus get prolongation of higher blood levels of the local anesthetic and an increased potential for toxicity.

B. amide local anesthetics:-

The metabolism of the amide local anesthetics is more complex than that of the esters; the primary site of biotransformation of amide drugs is the **liver**. The metabolic products of certain local anesthetics are capable of producing significant clinical activity if permitted to accumulate in the blood (due to renal or cardiac failure and during periods of prolonged drug administration). A clinical example is the production of methemoglobinemia in patients receiving large doses of Prilocaine or Articaine these drugs cannot produce methemoglobinemia but their metabolic products induce the formation of methemoglobin which is responsible for methemoglobinemia another example is the sedative effect occasionally observed following lidocaine administration. Lidocaine does not produce sedation but some of its metabolic products are currently thought to be responsible for this clinical action.

Excretion:

The **kidneys** are the primary organ of excretion for both the local anesthetics and its metabolites. A percentage of a given dose of local anesthetic drug will be excreted unchanged in the urine and this varies according to the drug. Esters appear in only very small concentration as a parent in the urine; this is because they are hydrolyzed almost completely in the plasma. Amides are usually present in the urine as the parent compound in a greater percentage than are esters, because of their more complex

process of metabolism of anesthetic compound or its metabolites from the blood, resulting in slightly elevated blood levels and an increased potential for toxicity. This may occur with either the esters or the amides drugs. Thus patients with a significant renal disease may represent a relative contraindication to the administration of local anesthetics.

- **Common local anesthetic agents**

Lignocaine (Lidocaine, Xylocaine)

Lignocaine: is the most commonly used local anesthetic agent in dentistry, it is the first non-ester type of local anesthetic agent to be used in dentistry, it is stable as it can be stored for a long time at room temperature, it withstands boiling and autoclaving and it is compatible with all types of vasoconstrictors.

- Classification: Amide.
- Metabolism: in the liver.
- Excretion: Via the kidneys. Less than 10% unchanged.
- Vasodilating Properties: Considerably less than those of procaine; however, greater than those of mepivacaine.
- The onset of Action: Rapid (3 to 5 minutes).
- Effective Dental Concentration: 2%.
- Anesthetic Half-Life: (90 minutes).
- Topical Anesthetic Action: Yes (with a concentration of 5% or 10%).
- Availability in dentistry: dental cartridge of 2% lidocaine with or without epinephrine

Maximum Recommended Dose:

The maximum recommended dose of lidocaine with epinephrine (1:100,000) is (**7 mg/kg**). While (**4.5 mg/kg**) is the maximum dose of lidocaine without epinephrine. In all the cases, not to exceed an absolute maximum dose of (**500 mg**).

- Lidocaine replaced procaine (Novocain) as the drug of choice for pain control. Compared with procaine, lidocaine possesses a significantly

more rapid onset of action, produces more profound anesthesia, has a longer duration of action and has greater potency.

- Allergy to amide local anesthetics is extremely rare; although possible, this is a major clinical advantage of lidocaine and all amides over ester-type local anesthetics.

❖ Selection of local anesthetic agent is based on:

1. Duration of action
2. Need for control of post-operative pain
3. Physical and mental status of the patient
4. Concomitant medications

❖ An approximate duration for completing the surgical procedure should be taken into account. Based on duration, the action of the local anesthetic agent can be grouped as:

1. Ultrashort-acting agents: where the duration of action is less than 30 minutes: e.g. 2 % lidocaine without vasoconstrictor.
2. Short-acting agents: where the duration of action is 30 to 90 minutes: e.g. 2% lidocaine with vasoconstrictor.
3. Medium-acting agents: where the duration of action is 90 to 180 minutes: e.g. 4 % prilocaine with vasoconstrictor.
4. Long-acting agents: where the duration of action is 180 minutes or longer: e.g. 0.5% of bupivacaine.

❖ Most of the oral surgical procedures result in varying amount of post-operative pain. The local anesthetic agent serves as additional medication that sometimes eliminates the need for postoperative analgesia.

❖ Any co-existing medical condition such as hypertension, diabetes should be considered, a patient with a history of allergy to a specific local anesthetic agent should be considered. The mental status of the patient has to be evaluated, small children and the mentally retarded patients may traumatize their lip, tongue or cheeks due to the effect of local anesthesia.



	The ester type	The amide type
1	Procaine	Lidocaine
2	Chloroprocaine	Prilocaine
3	Propoxycaine	Articaine **
4	Butacaine	Bupivacaine
5	Cocaine	Dibucaine
6	Benzocaine	Etidocaine
7	Hexylcaine	Mepivacaine
8	Piperocaine	
9	Tetracaine	

****Note:** articaine contains both ester and amide linkages in its chemical structure, but is considered as an amide local anesthetic agent.

“Vasoconstrictor”

Vasoconstrictors are drugs that constrict blood vessels thereby control tissue perfusion. They are added to the local anesthetic solutions to oppose the vasodilatation actions of the local anesthetic agent.

After injection of the local anesthetic, blood vessels dilate in the area, resulting in an increased blood flow to the site. This increase in perfusion leads to the following reactions:

1. Increased rate of absorption of the local anesthetic into the cardiovascular system, which in turn removes it from the injection site.
2. Increased plasma level of the local anesthetic, with an increased risk of local anesthetic toxicity.
3. Decreased duration of action and decreased depth of anesthesia because it diffuses away from the injection site more rapidly.
4. Increased bleeding at the site of injection due to increased perfusion.

The advantages of additions of vasoconstrictors to the local anesthetic solution are:

1. Vasoconstrictors decrease blood flow (perfusion) to the site of the injection.
2. The absorption rate of the local anesthetics into the cardiovascular system is reduced, resulting in lower anesthetic plasma levels.
3. Decrease the risk of systemic toxicity (lower the local anesthetic plasma levels).
4. Increase the duration of action of local anesthetics (higher volumes of the local anesthetic agent remain in and around the nerve for longer periods).
5. Decrease bleeding at the site of injection, especially useful when increase bleeding is anticipated (e.g. during a surgical procedure).

Dilution of vasoconstrictors:

The dilution of the vasoconstrictor is commonly referred to as ratio (1 to 1000, and is written as 1:1000). This 1:1000 means that there is 1 gm (1000 mg) of the drug contained in 1000 ml of solution.

Types of the vasoconstrictors:

1- Epinephrine (adrenaline) :-

Sources: it is either synthetic or obtained from adrenal medulla of animals.

Mode of action:-

It acts directly on both alpha α & beta β receptors

Systemic action:

a- Cardiovascular system

It causes increased systolic & diastolic B.P.

It causes increased heart rate & strength of contraction.

It causes increased stroke volume & cardiac output.

It causes increased myocardial O₂ consumption.

On blood vessel it causes vasoconstriction & so frequently used alone as a vasoconstrictor for hemostasis during surgical procedures.

B-Respiratory system:-

Epinephrine is a potent dilator of the smooth muscle of the bronchiole; it is the drug of choice for management of acute asthma.

C- Central nervous system (CNS)

In the usual therapeutic dosage epinephrine is not a potent CNS stimulant. CNS stimulation occurs when an excessive dosage is given.

Availability in dentistry

Epinephrine is the most potent & widely used vasoconstrictor in dentistry. It is available in 1:50 000, 1:80 000, 1:100 000, 1:200 000 dilution.

Maximum dosage:

a- for pain control

The least concentrated solution that produces effective pain control should be used.

For normal healthy patient:

The max. dose is **0.2 mg** per appointment & this means:

10 ml of a 1:50 000 dilution (5 cartridge).

20 ml of a 1:100 000 dilution (11 cartridge).

40 ml of a 1:200 000 dilution (22 cartridge).

For patient with clinically significant cardiovascular disease:

The max. dose **0.04 mg** per appointment, that means:

2 ml of a 1:50 000 (1 cartridge).

4 ml of a 1:100 000 (2 cartridge).

8 ml of a 1:200 000 (4 cartridge).

b- For hemostasis:-

Epinephrine containing LA solution is used via infiltration into the site of operation to prevent or minimize bleeding during surgical procedures.

For normal healthy patient the 1:50 000 dilution of epinephrine is more effective in hemostasis than less concentrated 1:100 000, or 1:200 000.

For patient with cardiovascular dis. The dilution of 1:100 000 is considered the best.

2- Norepinephrine (noradrenalin)

Sources: either synthetic or obtained from adrenal medulla of animals.

Mode of action:

The mode of action is almost exclusively on alpha receptors. It also stimulates beta (β) receptors in the heart. Norepinephrine is one fourth (25%) as potent as epinephrine.

Systemic action:

a - Cardiovascular system (C.V.S)

It causes increased systolic B.P.

It causes decreased heart rate.

It causes no changes or slightly decreased cardiac output.

It causes increased stroke volume.

It causes increased peripheral resistance on the blood vessel through alpha receptor stimulation, it produces constriction of cutaneous blood vessels & this will lead to increased peripheral resistance.

b- Respiratory system

Norepinephrine does not relax smooth muscle as do epinephrine & it is not clinically effective in the management of bronchospasm.

c-- CNS

In the usual therapeutic dosage norepinephrine is not potent CNS stimulant. CNS stimulating action predominates when an excessive dosage is given.

Availability in dentistry:

Sometimes, norepinephrine is used with LA as vasoconstrictor in a 1: 30 000 dilution.

Maximum doses:

Nor epinephrine should be used for pain control only but not for hemostasis. For normal healthy patient:

0.34 mg per appointment, that mean 10 ml of a 1:30 000

For patient with clinically significant cardiovascular disease:

0.14 mg per appointment, that means 4 ml of a 1:30 000.

Levonordefrin (Neo-cobefrin):

It is synthetic substance.

It acts through direct alpha receptor stimulation with some B beta activity. It produces less cardiac & CNS stimulation than epinephrine does. It is mainly used with mepivacaine in a 1:20 000 dilution. The max. dose for all patients should be 1 mg per appointment that mean 20 ml of a 1:20 000 dilution (11 cartridge).

Felypressin (octapressin):

Sources: it is the analogue of the antidiuretic hormone vasopressin .it is a non-sympathomimetic drug & it is categorized as vasoconstrictor.

Mode of action:

It acts as direct stimulant of vascular smooth muscle. Its action appears to be more pronounced on the venous than the arteriolar microcirculation.

Systemic action:

Heart: no direct effects

Blood vessel: In high doses. Felypressin -induced constriction of cutaneous blood vessel & may produce facial pallor.

CNS: no effect

Uterus: it has both antidiuretic & oxytocin actions, the latter contraindicating its uses in pregnant patient.

Clinical application:

It is used as vasoconstrictor to decrease the absorption as well as to increase the duration of the anesthesia, it is not recommended for use when hemostasis is required because of their predominant effect on the venous rather than the arterial circulation. Availability in dentistry:

It is used in a dilution of 0.03 iu/ml with 3% prilocaine (it means international unit). Max. dose is 0.27 IU, that means: 9ml of 0.03 iu/ml.

Selection of a vasoconstrictor

The selection of an appropriate vasoconstrictor is based on the following factors:

1. Length of the surgical procedure: The duration of plain anesthesia only lasts for few minutes; the addition of adrenaline will prolong the duration.
 2. The requirement of hemostasis: Some of the vasoconstrictors are effective in minimizing the blood loss during the surgical procedure as adrenaline, while Felypressin is of minimal value in achieving hemostasis.
 3. The requirement of postoperative pain control: Adding vasoconstrictor will prolong the pain-free status.
 4. Physical status of the patient and medication used: The benefit and risks of including a vasoconstrictor in a local anesthetic solution in patients who are medically compromised must be weighed against benefits and risks of using plain anesthesia.
- ❖ For the following group of patients, the use of local anesthetic agents with vasoconstrictor is contraindicated:
- A. Patients with a significant cardiovascular disease such as ischemic heart disease, hypertension or cerebral strokes.
 - B. Patients with thyrotoxicosis.
 - C. Patients receiving monoamine-oxidase inhibitors or tricyclic antidepressant.

Calculation of the dose of local anesthetics in dentistry (Using lidocaine as an example)

As any other drug, LA has a maximum safe dose. The dose is calculated in mg. per kg. of body weight (mg/kg body weight) .

The amount of LA agent (e.g. lidocaine) that is present in the cartridge is written on the cartridge by its percent concentration.

The number of milligram of the agent in the cartridge therefore can be calculated by.:

multiplying the percent conc., (ex 2% - $2\text{gm}/100\text{ml}=2000\text{ mg}/100\text{ ml}=20\text{ mg/ml}$) .

Thus 1.8 ml. cartridge of 2% lidocaine contains 36 mg lidocaine. (1.8×20)

Example:-

The maximum safe dose of lidocaine is 4.5 mg/kg body weight per appointment .this means that maximum dose of 2% lidocaine (without epinephrine)that could be given to a 70 kg patient about 300 mg. per appointment ($4.5 \times 70 = 315\text{ mg}$).

To calculate the max number of cartridge:

2% means $2\text{ gm.}/100\text{ ml} = 2000\text{ mg}/100\text{ ml} = 20\text{ mg/ml}$

$20\text{ mg/ml} \times 1.8 = 36\text{ mg}$ lidocaine inside a single cartridge.

$300\text{ mg} / 36\text{ mg} = 8$ cartridges.

This calculation is considering that the local anesthesia is plain (without a vasoconstrictor).

We should remember that the max. dose of the vasoconstrictor is 0.2 mg per appointment for adult healthy patient. And 0.04 mg per appointment for patient with clinically significant cardiovascular disease & should be considered when calculating the max number of cartridge that are allowed to be given to the patient per appointment & according to the type & concentration of the vasoconstrictor.

Oral Surgery

“Surgical anatomy in local anesthesia”

Trigeminal nerve:-

The management of pain in dentistry requires a thorough knowledge of the fifth cranial nerve (fig:1). The right and left trigeminal nerves provide, among other functions, the overwhelming majority of sensory innervation from the teeth, and soft tissues of the oral cavity. The trigeminal nerve is also the largest cranial nerve. It is composed of a small motor and considerably larger sensory root. The motor root supplies the muscles of mastication and other muscles in the region. The three branches of the sensory root supply the skin of the entire face and the mucous membrane of the cranial viscera and oral cavity, except for the pharynx and the base of the tongue.

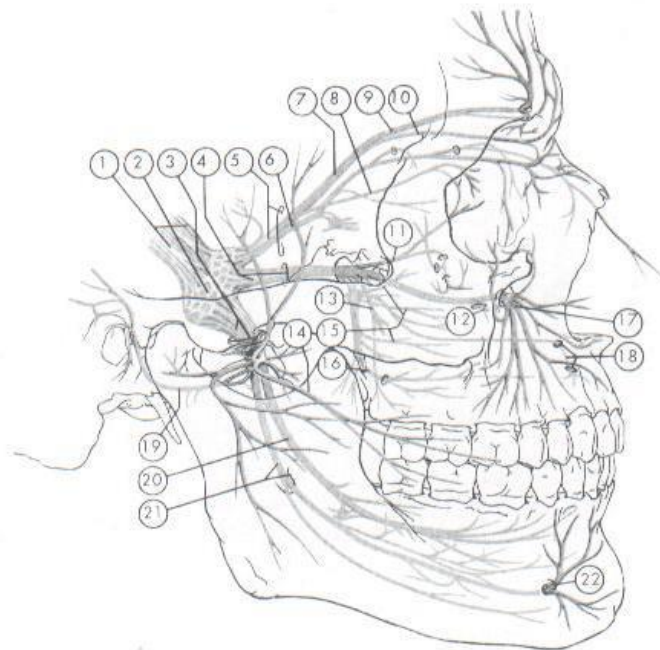


Fig. 12-1 Distribution of the trigeminal nerve. 1, The branches are as follows: 2, gasserian ganglion; 3, mandibular nerve and foramen ovale; 4, maxillary nerve and foramen rotundum; 5, ophthalmic nerve and superior orbital fissure; 6, nasociliary nerve; 7, frontal nerve; 8, lacrimal nerve; 9, supraorbital nerve; 10, supratrochlear nerve; 11, zygomatic nerve; 12, anterior superior alveolar branches; 13, posterior superior alveolar branches; 14, buccal nerve; 15, posterior nasal branches; 16, greater palatine nerve; 17, infraorbital nerve; 18, nasopalatine nerve; 19, auriculotemporal nerve; 20, lingual nerve; 21, inferior alveolar nerve; 22, mental nerve. (From Haglund J, Evers H: Local anaesthesia in dentistry, ed 2, Södertälje, Sweden, 1975, Astra Läkemedel.)

Fig 1. Trigeminal nerve

An understanding of the management of pain in dentistry requires a thorough knowledge of the fifth (V) cranial nerve. The right and left trigeminal nerves provide the majority of sensory innervation from teeth, bone, and soft tissues of the oral cavity. The trigeminal nerve is the largest of the twelve cranial nerves. It is composed of a small motor root and a larger sensory root.

The three sensory divisions of the trigeminal nerve are:

1. **The ophthalmic division (V1)** exits the skull through the superior orbital fissure into the orbit. It is the first branch of the trigeminal nerve, purely sensory and is the smallest of the three divisions.
2. **The maxillary division (V2)** exits the skull through the foramen rotundum into the upper portion of the pterygopalatine fossa. It is intermediate in size between ophthalmic and mandibular divisions. It is purely sensory in function.
3. **The mandibular division (V3)** exits the skull, along with the motor root, through the foramen ovale. Just after leaving the skull, the motor root unites with the sensory root of the mandibular division to form a single nerve trunk that enters the infratemporal fossa.

Maxillary Division (V2)

Once outside the cranium, the maxillary nerve crosses the uppermost part of the pterygopalatine fossa. It then enters the orbit through the inferior orbital fissure occupying the infraorbital groove and becomes the infraorbital nerve, which courses anteriorly into the infraorbital canal. The following is a summary of maxillary division innervation:

1. **Skin** (middle portion of the face, lower eyelid, side of the nose and upper lip).
2. **Mucous membrane** (nasopharynx, maxillary sinus, soft palate, tonsil and hard palate).
3. **Maxillary teeth and periodontal tissues**

Branches originating within the pterygopalatine fossa

The nasopalatine nerve enters the incisive canal, through which it passes into the oral cavity via the incisive foramen, located in the midline of the palate about 1 cm posterior to the maxillary central incisors. The right and left nasopalatine nerves emerge together through this foramen and provide sensation to the palatal mucosa in the region of the premaxilla.

The greater palatine nerve descends through the pterygopalatine canal, emerging on the hard palate through the greater palatine foramen (which is usually located about 1 cm toward the palatal midline, just distal to the second molar). The nerve courses anteriorly between the mucoperiosteum and the osseous hard palate, supplying sensory innervation to the palatal soft tissues and bone as far anterior as the first premolar, where it communicates with terminal fibers of the nasopalatine nerve.

The posterior superior alveolar (PSA) nerve descends from the main trunk of the maxillary division in the pterygopalatine fossa. Commonly there are two PSA branches, but on occasion, a single trunk arises. When two trunks are present, one remains external to the bone, continuing downward on the posterior surface of the maxilla to provide sensory innervation to the buccal gingiva in the maxillary molar region. Whereas the other branch enters into the maxilla through the PSA canal to travel down the posterior wall of the maxillary sinus, providing sensory innervation to the mucous membrane of the sinus. Continuing downward, this second branch of the PSA nerve provides sensory innervation to the alveoli, periodontal ligaments, and pulpal tissues of the maxillary third, second, and first molars (with the exception [in 28% of patients] of the mesiobuccal root of the first molar).

Branches originating within the infraorbital canal

Within the infraorbital canal, the maxillary division (V2) gives off two branches of significance in dentistry: the middle superior and anterior superior alveolar nerves.

The middle superior alveolar (MSA) nerve provides sensory innervation to the two maxillary premolars and, perhaps, to the mesiobuccal root of the first molar and periodontal tissues, buccal soft tissue, and bone in the premolar region. Traditionally it has been stated that the MSA nerve is absent in 30% to 54% of individuals. In its absence, its usual innervations are provided by either the posterior superior alveolar (PSA) or the anterior superior alveolar (ASA) nerve; most frequently the latter.

The ASA nerve, a relatively large branch, descending within the anterior wall of the maxillary sinus, it provides pulpal innervation to the central and lateral incisors and the canine, and sensory innervation to the periodontal tissues, buccal bone, and mucous membranes of these teeth.

Summary

The following is a summary of the branches of the maxillary division (only those of special significance in dental pain control):

1. Branches originating within the pterygopalatine fossa
 - a. Nasopalatine nerve
 - b. Greater palatine nerve
 - c. Posterior superior alveolar nerve
2. Branches originating within the infraorbital canal
 - a. Middle superior alveolar nerve
 - b. Anterior superior alveolar nerve

Mandibular Division (V3)

The mandibular division is the largest branch of the trigeminal nerve. It is a mixed nerve with two roots: a large sensory root and a smaller motor root. The two roots emerge from the cranium separately through the foramen ovale, the motor root lying medial to the sensory. They unite just outside the skull and form the main trunk of the third division. This trunk remains undivided for only 2 to 3 mm before it splits into a small anterior and a large posterior division. The areas innervated by V3 are included in the following outline:

Sensory root:

1. Skin of the temporal region, auricle, external auditory meatus, cheek, lower lip, and the lower part of the face (chin region).
2. Mucous membrane of the cheek and the tongue (anterior two thirds).
3. Mandibular teeth and periodontal tissues.
4. Bone of the mandible.
5. Temporomandibular joint.
6. Parotid gland.

Motor root: Motor fibers of the trigeminal nerve supply the following muscles:

1. Masticatory muscles
 - a. Masseter
 - b. Temporalis
 - c. Medial Pterygoid
 - d. Lateral Pterygoid
2. Mylohyoid
3. Anterior belly of the digastric
4. Tensor tympani
5. Tensor veli palatine

Branches from the Undivided Nerve

The main undivided nerve trunk gives off two branches during its 2- to 3-mm course. These are the nervus spinosus (a meningeal branch of the mandibular nerve) and the medial pterygoid nerve. The medial pterygoid nerve is a motor nerve to the medial pterygoid muscle. It gives off small branches that are a motor to the tensor veli palatini and the tensor tympani.

Branches from the Anterior Division

Branches from the anterior division of V3 provide motor innervation to the muscles of mastication and sensory innervation to the mucous membrane of the cheek and the buccal mucous membrane of the mandibular molars. The anterior division is significantly smaller than the posterior.

Branches:

1. Deep temporal nerve (to the temporalis muscle).
2. Masseter nerve (to the masseter muscle).
3. Lateral pterygoid nerve (to the lateral pterygoid muscle).
4. The long buccal nerve (also known as the buccal nerve).

The long buccal nerve emerges under the anterior border of the masseter muscle, continuing in an anterolateral direction. At the level of the occlusal plane of the mandibular third or second molar, it crosses in front of the anterior border of the ramus and enters the cheek through the buccinator muscle. Sensory fibers are distributed to the skin of the cheek. Other fibers pass into the retromolar triangle, providing sensory innervation to the buccal gingiva of the mandibular molars and the mucobuccal fold in that region. The long buccal nerve does not innervate the buccinator muscle; the facial nerve does.

Branches of the Posterior Division

The posterior division of V3 is primarily sensory with a small motor component.

1. Auriculotemporal nerve.
2. Lingual nerve.
3. Inferior alveolar nerve.
4. Mylohyoid nerve.

The lingual nerve runs anterior and medial to the inferior alveolar nerve. It then continues downward and forward, deep to the pterygomandibular raphe to reach the side of the base of the tongue slightly below and behind the mandibular third molar. Here it lies just below the mucous membrane. It then proceeds anteriorly

looping downward and medial to the submandibular (Wharton's) duct to the deep surface of the sublingual gland, where it breaks up into its terminal branches.

The lingual nerve is the sensory tract to:

1. The anterior two-thirds of the tongue. It provides both general sensation and gustation (taste) for this region. The nerve supplies fibers for general sensation, whereas the chorda tympani (a branch of the facial nerve) supplies fibers for taste.
2. The mucous membranes of the floor of the mouth.
3. The gingiva on the lingual side of the mandible.

❖ The lingual nerve is the nerve most commonly associated with cases of paresthesia (prolonged or permanent sensory nerve damage).

The inferior alveolar nerve is the largest branch of the mandibular division. It enters the mandibular canal through the mandibular foramen. Throughout its path, it is accompanied by the inferior alveolar artery and vein. The nerve, artery, and vein travel anteriorly in the mandibular canal as far forward as the mental foramen, where the nerve divides into its terminal branches: the incisive and mental nerves. Once the inferior alveolar nerve enters the mandibular canal, the dental plexus serves the mandibular posterior teeth, entering through their apices and providing pulpal innervation.

The incisive nerve remains within the mandibular canal and forms a nerve plexus that innervates the pulpal tissues of the mandibular second premolar (in most instances), first premolar, canine, and incisors via the dental branches.

The mental nerve exits the canal through the mental foramen and divides into three branches that innervate the skin of the chin and the skin and mucous membrane of the lower lip.

❖ Bifid inferior alveolar nerves and mandibular canals have been observed radiographically in about 0.95% of people. The bifid mandibular canal is clinically significant in that it increases the difficulty of achieving adequate anesthesia in the mandible through conventional techniques.

The mylohyoid nerve branches from the inferior alveolar nerve before entry of the latter into the mandibular canal. It supplies the mylohyoid muscle. It also may provide sensory innervation to the mandibular incisors and molars in some persons (usually the mesial root of the mandibular first molar).

Osteology:

In addition to the neuroanatomy of pain control in dentistry, one should be aware of the relationship of these nerves to the osseous and soft tissues through which they course.

Maxilla:

- ❖ The maxilla has a series of eminences that correspond to the roots of the maxillary teeth. The most prominent usually is found over the canine tooth and is often referred to as the canine eminence. Superior to the canine fossa (located just distal to the canine eminence) is the infraorbital foramen.
- ❖ Bone in the region of the maxillary teeth is more porous than mandible leading to a significantly greater incidence of clinically adequate anesthesia.
- ❖ The palatal processes of the maxilla form the anterior three-fourths of the hard palate. While the horizontal plate of the palatine bone forms the posterior fourth. Along its lateral border, at the junction with the alveolar process, is a groove through which the greater palatine nerve passes from the greater palatine foramen.
- ❖ In the midline in the anterior region is the funnel-shaped opening of the incisive foramen, through which the nasopalatine nerves emerge.
- ❖ A fine suture line extends laterally from the incisive foramen to the canine teeth. The area anterior to this suture is termed the premaxilla.

Mandible:

- The buccal cortical plate of the mandible is sufficiently dense to preclude effective infiltration of anesthesia. The bone in the anterior region (incisors) is usually less dense than that over the posterior teeth, permitting infiltration anesthesia to be employed. Bone along the lingual surface of the mandible usually is dense.
- In the region of the second premolar, midway between the upper and lower borders of the body lies the mental foramen.
- Sometimes lingual foramina are located in the posterior (molar) region. Some of which may contain sensory fibers from the mylohyoid nerve that innervate portions of mandibular molars.
- The mandibular foramen, located about two-thirds the distance from the anterior border of the ramus to its posterior border. The height of mandibular foramen varies greatly, ranging from 1 to 19 mm above the level of the occlusal plane.

- A prominent ridge, the Lingula, lies on the anterior margin of the foramen. The Lingula serves as an attachment for the sphenomandibular ligament.
- The anterior border of the coronoid process is concave, the coronoid notch. The coronoid notch represents a landmark for determining the height of needle penetration in the inferior alveolar nerve block technique.
- When cutting horizontally at the level of the mandibular foramen, the ramus of the mandible can be seen to be thicker in its anterior region than it is posteriorly. This is of clinical importance during the inferior alveolar nerve block. The thickness of soft tissues between needle penetration and the osseous tissues of the ramus at the level of the mandibular foramen averages about 20 to 25 mm.

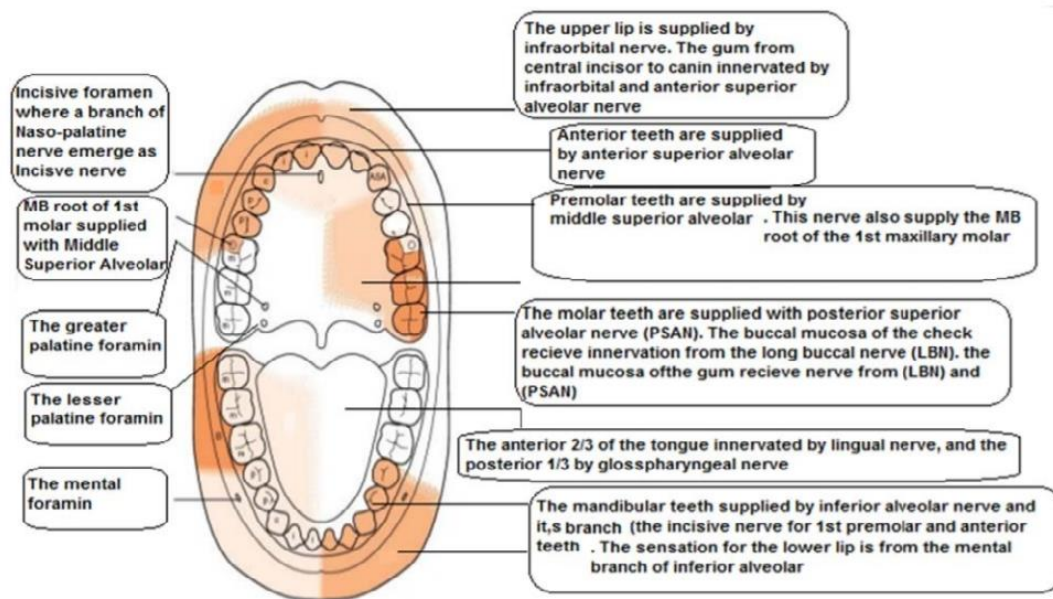
The dental plexus

The actual innervation of individual roots of all teeth, bone, and periodontal structures in both the maxilla and the mandible derives from terminal branches of larger nerves in the region. These nerve networks are termed the dental plexus.

The superior dental plexus is composed of smaller nerve fibers from the three superior alveolar nerves (ASA, MSA and PSA nerves) and in the mandible, from the inferior alveolar nerve. Three types of nerves emerge from these plexuses (each is accompanied along its pathway by a corresponding artery):

1. **Dental nerves:** enter a tooth through the apical foramen. Pulpal innervation of all teeth is derived from dental nerves.
2. **Interdental branches:** travel through the entire height of the interdental septum (between teeth), providing sensory innervation to the periodontal ligaments of adjacent teeth enter the gingiva to innervate the interdental papillae and the buccal gingiva.
3. **Interradicular branches:** traverse the entire height of the interradicular septum (between roots of the same tooth), providing sensory innervation to the periodontal ligaments of adjacent roots. They terminate in the periodontal ligament (PDL) at the root furcations.

Summary for sensory dental innervations



Summary for sensory dental innervations. The middle superior alveolar nerve is present in 28% of anatomically dissected cadavers, in the remaining 72% this nerve can not be recognized and the premolars are mostly supplied by posterior superior alveolar nerve.

INSTRUMENTS FOR BASIC ORAL SURGERY

These lectures will introduce the basic and main instruments required to perform routine oral surgical procedures ,these instruments are used for many purposes including both soft and hard tissues (e.g./ Bone , dental procedures):-

The main instruments include the followings:-

- 1- Instruments to incise the tissues .
- 2- Instruments for elevating mucoperiosteum.
- 3- Instruments for controlling haemorrhage .
- 4- Instruments to grasp tissues.
- 5- Instruments for removing bone includes:-
 - a. Ronger forceps(bone cutter, bone nibbler)
 - b. Chisel and mallet.
 - c. Bone file.
 - d. Burs and hand piece.
 - e. Instruments to remove soft tissues from bony defects
- 6-Instruments for suturing mucosa:
 - a. Needle holder.
 - b. Needle.
 - c. Suture material.
 - d. Scissors.
- 7- Instruments for retraction of soft tissues.
8. Instruments for irrigation and for providing suction.

1-Instruments to incise tissues:

These instruments used to do incision in the soft tissues and this procedure needs scalpel and scalpel handle, the most commonly used handle is number 3 and number 7 . The tip of the scalpel handle is prepared to receive a variety of different scalpel blades that can be inserted into a slotted receiver, the most commonly used scalpel blade for intra oral incisions is number 15 , its relatively small and can be used to make incision around teeth and through mucoperiosteum.

Another scalpel used to make incisions on the skin extra orally is number 10..

Other commonly used blades for intra oral surgery are number 11 and 12.


Blade no. 11 mostly used for making stab incision such as for incising abscess , its

pointed triangular in shape , the hooked no. 12 blade is useful for mucogingival procedures especially in the posterior area of the oral cavity , for example maxillary tuberosity or posterior aspects of the upper molar region on the buccal or lingual aspects.

Scalpel handle no.3



Dental scalpel blades:



2-Instruments for mucoperiosteum elevation

After an incision is made through the mucoperiosteum (mucosa +sub mucosa+ periosteum=mucoperiosteum)

The mucosa and periosteum should be reflected from the underlying bone with periosteal elevator . The instrument that is mostly used in our department is Howarth periosteal

elevator, this instrument has a sharp pointed end and a broad flat round end .

The broad flat round end is inserted into the incision beneath the cut edge of the periosteum to elevate or strip it off the bone , and the sharp end of the elevator used for detachment of muscle insertion or sometimes to complete the incision done by the blade if there is some resistance for the elevation by the flap, many types and sizes of the periosteal elevators are available like Mitchell trimmer

Mitchell trimmer is useful in separating through the fibres from around the crown of the unerupted teeth and the neck of erupted teeth.

The periosteal elevator can be used to reflect soft tissues by push stroke in which the broad end of the instrument slides underneath the flap separating through the periosteum from the underlying bone and sometimes periosteal elevators are used by a pull stroke or scrap stroke in special locations.

Howarth periosteal elevator:



Mitchell trimmer:



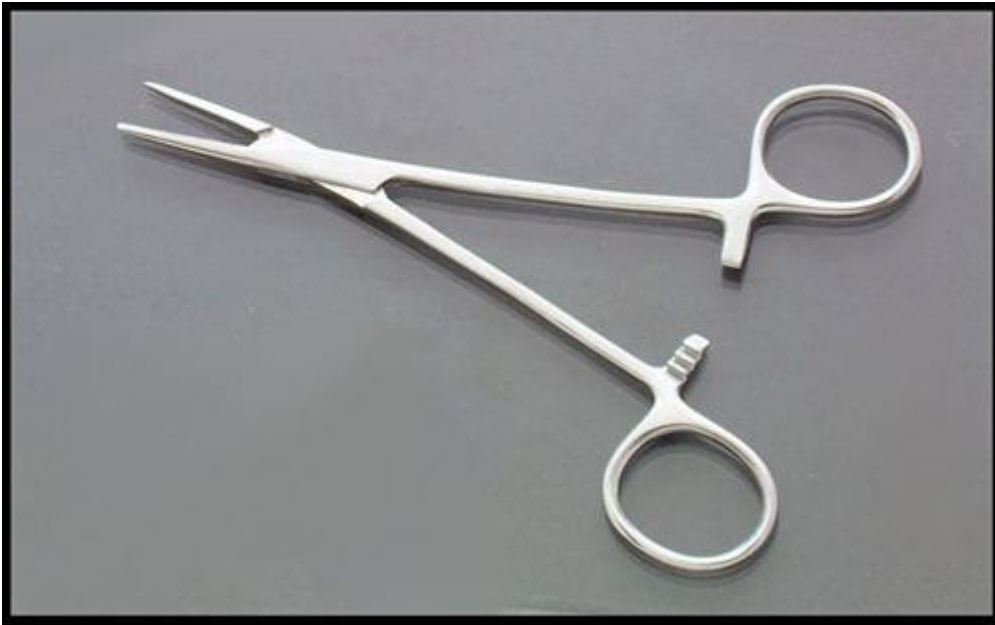3-Instruments for controlling haemorrhage:

When incision is made through the tissues , small vessels may be cut leading to bleeding , to control this bleeding we have instruments Which aid in the stoppage of bleeding called haemostat or artery forceps , this comes in a variety of shapes and sizes , it's a delicate instrument which may have straight or curved beaks , this

instrument has a locking device assisting in the clamping of the blood vessels

In addition to its use as an instrument for controlling bleeding its used in oral surgery to evacuate pus from abscesses by inserting the haemostat inside the abscess after an incision is made , also haemostat may be useful in grasping tissues from the tooth socket and pick up small root tips , pieces of calculus, fragments of amalgam or any other small particles that have been dropped in the mouth or wound area.

Haemostat:



4-Instruments used to grasp tissues:

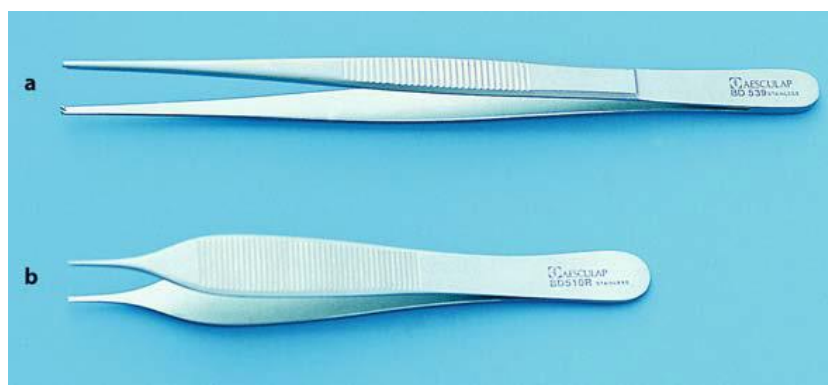Here we have :

A-Toothed -tissue forceps.

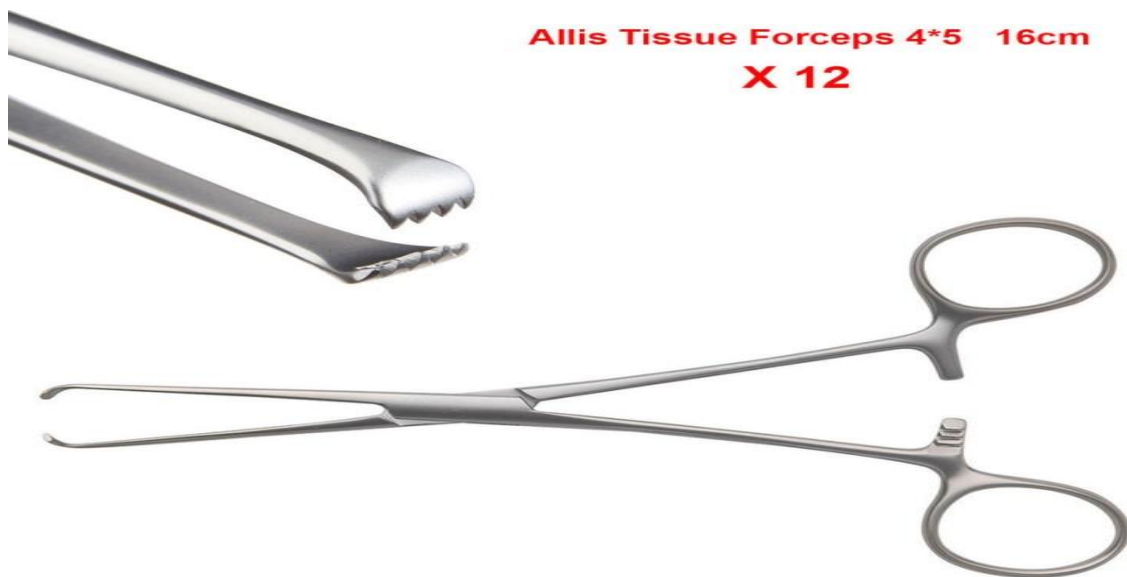B- Allis tissue forceps.

These instruments used to hold and stabilize flap during suturing to assist in passing needle through the mucoperiosteal flap , also these instruments, used to hold tissues or grasping tissues in some types of surgical procedures .e.g.\ Taking biopsy.

It should be used gently to prevent crushing of the tissues especially in the case of Allis tissue forceps



Allis tissue forceps:



5-Instruments for removing bone includes:

A-rounger forceps (bone cutter , bone nibbler)

B-chisel and mallet.

C-surgical burs and hand piece.

D-bone file.

E-instruments used to remove soft tissues from bony defects

sometimes we need to remove bone to gain access into a lesion like intra-bony cystic lesion, or bony biopsy or to correct an existing bony defect or abnormal bony exostosis or even sometimes to remove a retained root or a sharp bony projection ..etc.

So we have many tools and instruments to perform such a duty. the use of any one of these instruments depends on the case and preference of the operator, so we have many modalities to perform bone removal.

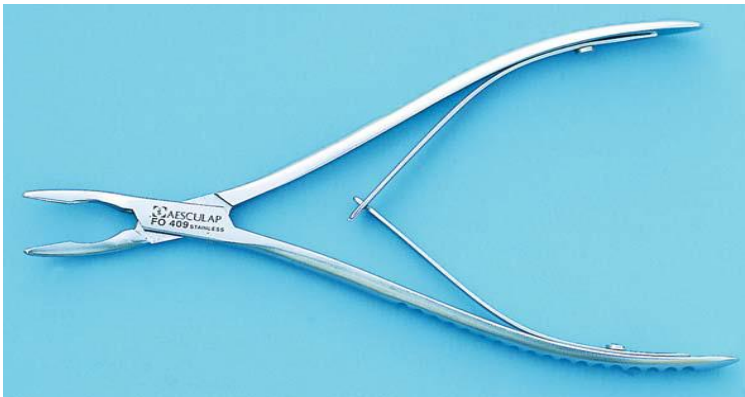A- Bone rounger:

It's also called (bone nibbler) or (bone cutter) it's used to cut bone quickly and efficiently this instrument has sharp blades that are squeezed together by the handles cutting or pinching through the bone , it also has a leaf spring or spring loaded handles to control the opening of the blades, some of these are side cutting others are end

cutting.

End cutting types are used to cut bone in less accessible areas like inside the tooth socket , these instruments are very useful for trimming of sharp bony projections or removing of a thin plate of compact bone during saucerization of bone cavity.

Bone Cutter (rounger forceps):



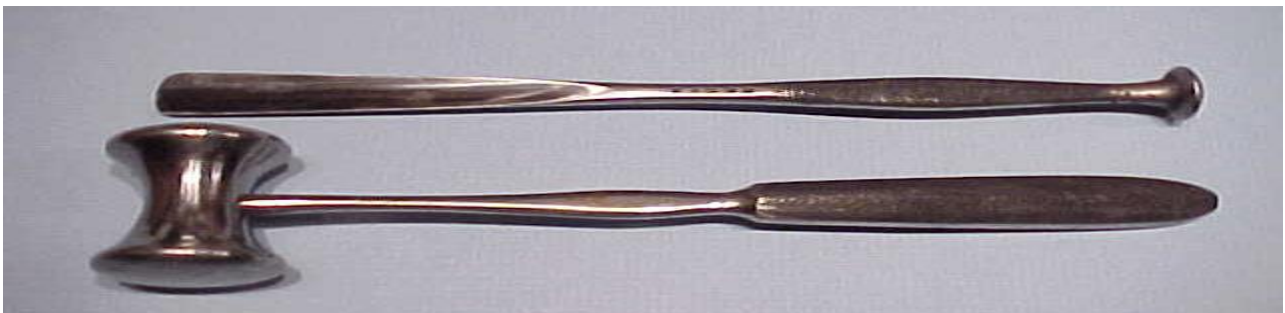
B-Chisel and mallet:

This is another method for removing bone especially when large piece of bone need to be removed ,we have many sizes and lengths of chisels ..chisel have a sharp monobeveled working end used to cut bone , bibevelede called ***osteotome*** , may be used for splitting bone or teeth.

cutting of bone by chisel need to be used by applying force and by the use of mallet,. A mallet with a nylon cover or facing will exert less shock to the patient, also its less noisy ..

Removal of bone using chisel and mallet mostly done under general anaesthesia.

Chisel & Mallet:



C- Surgical burs and hand piece:

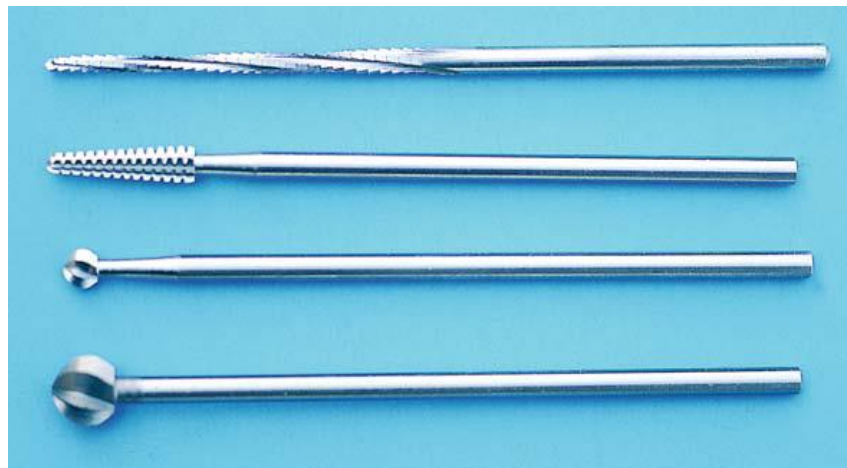It's a useful method and commonly used to remove bone by rotary means (hand piece) under local anaesthesia, burs are either used to remove bone or to cut a window in the bone , it's also useful in dividing teeth , we have dental steel burs and tungsten carbide burs carbide burs cut bone more efficiently than steel burs, these burs are-either-round or fissure burs...

* large diameter bone burs may be used for removal of wide area of bone or for smoothening of the margins of bony defect, in most cases the use of either size 6 or 8 bone burs will enable the production of deep narrow slots in the bone ,burs can be used with angle or straight hand piece which should have an accepted speed and torque to remove bone efficiently and should always be used with irrigation by distilled water or saline to prevent damage to the bone by heat generation during cutting.

*when large amount of bone need to be removed , large bur that resembles an acrylic bur is used .

High speed turbine which is used in restorative dentistry must not be used because the air exhausted into the wound may produce tissue emphysema.

Dental surgical burs:



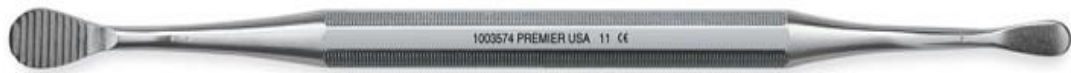D- Bone file:

This instrument is used for smoothening of bone before suturing of the flap , it's usually double ended instrument with a small and large ends , the working end of the bone file have grooves or slots to work in a ***pull stroke*** only, bone file is not used to remove bone

its used only for final smoothening ..

Notice that its used in a pull stroke one direction only , if pushing movement is used it will lead to crushing of bone and this should be avoided.

Bone file :



E-Instruments to remove soft tissues from bony defects:

It is called Curette : it's just like excavator , angled , double ended ,of different sizes,the working end is like a spoon, round -oval in shape, its mostly used to remove soft tissues from a bony cavity like :periapical granuloma or cystic lesion from the bone, it also may be used to remove foreign bodies or small pieces or spicules from the bony socket.

Curette:



ORAL SURGERY 3rd grade

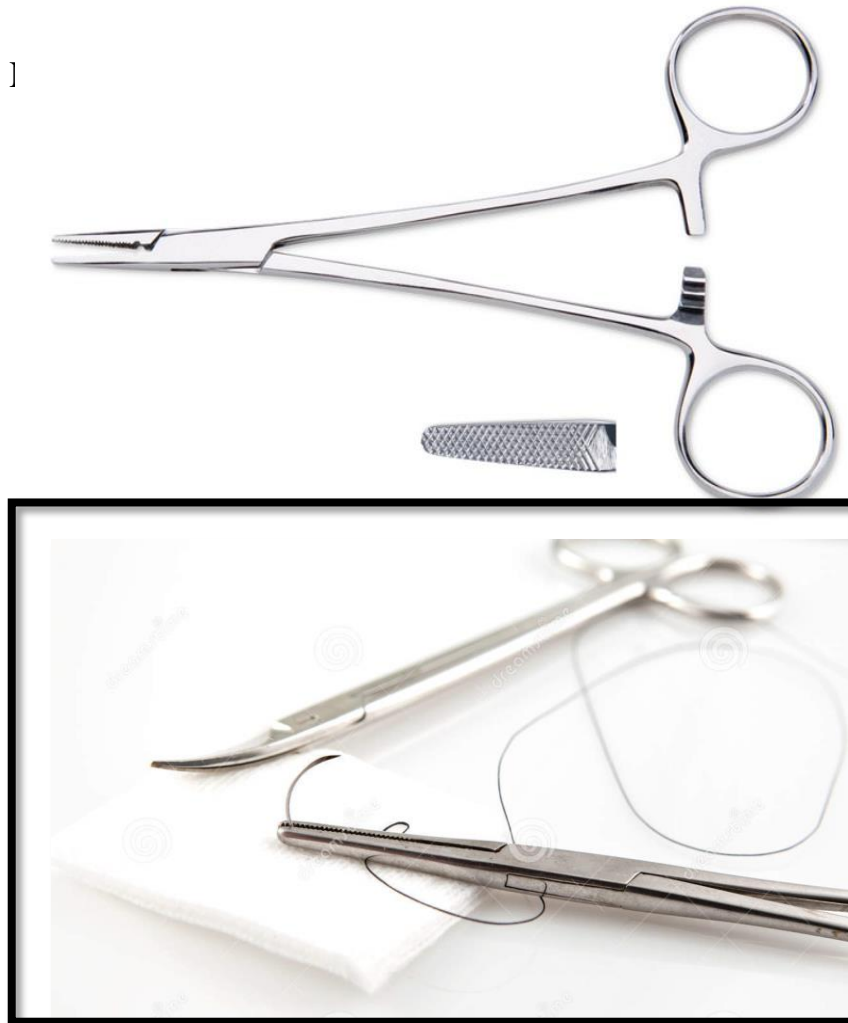INSTRUMENTS FOR BASIC ORAL SURGERY II

6-Instruments for suturing:

At the end of the procedure the mucoperiosteal flap must be returned back to its original place or position by sutures, the instruments used to do any suturing may include the followings:

A-Needle holder

the needle holder is an instrument with a locking handle device the handle is long and the beaks are short ,stout for intraoral suturing, a 15 cm handle length needle holder is often recommended the beaks of the needle holder are shorter and stronger than the beaks of the haemostat, the inner surface of the beaks is crosshatched to provide good surface for grasping of the needle and to prevent its rotation or movement during suturing while in haemostat the inner surface has parallel grooves which differentiates it from the needle holder, so haemostat should not be used for suturing but preserved for its original work to control bleeding during surgery.



B-Needles:

Most sutures come fused to needles in a pre-sterilized package, suture needles differ according to the shape of their cross section and their length, there are generally two types:

1-cutting needle, have a triangular cross section

2-taper point, which are round or oval in cross section.

According to the shape of the needles, straight needles are only used where tissues or areas of surgery are easily accessible and therefore they are not used in oral cavity because of the limitation of space in oral cavity, so curved needles are mostly used of a length of 21-25 mm or 3/8 or 1/2 (half circle) and this design allows the needle to pass through the limited area of suturing easily, the cutting needle(triangular cross section) also called traumatic needle but it has a good advantage of being able to enter the tissues easily during suturing specially in tout areas like mucoperiosteum of the hard palate(keratinized mucosa) or skin where the tissue is difficult to penetrate the tapered needle is generally used for closing muscle or fascia that are easily penetrated.

C-Suture material:

many types of suture materials are available and could be classified by size , resorb ability ,and whether or not they are monofilament or poly filament .Sutures are made of wide variety of materials and come in several sizes, each designed for a particular purpose

1-size

Sutures are available in various sizes that range from one zero (1/0) to (1 1/0)eleven zero, increasing number of zeros means decreasing the suture diameter, the most size used in oral and maxillofacial surgery is size 3/0 and 4/0 ,the size of the suture usually expressed on the package e.g. 3/0 ,4/0, 2/0....the size 3/0 used most commonly in suturing oral mucosa, which is enough to prevent tearing of the oral mucosa and strong to withstand the tension placed on them intraorally.

2.Resorbability:


Sutures may be resorbable or non-resorbable, resorbable sutures are made of materials that the body is capable of easily breaking them down, like catgut sutures and this is used for suturing deep structures like muscles, fascia, so these sutures does not require removal, while non resorbable sutures like black silk sutures ,nylon, stainless steel, those need removal of the suture postoperatively..

For the resorbable sutures we have two types. Plain gut and chromic gut ,the plain gut is subjected to rapid resorption or digestion by the proteolytic enzymes produced by the inflammatory cells ,while the chromic catgut is treated with special chromic salts ,to provide resistance for the proteolytic enzymes.

D-Scissors:-

the final instrument necessary for placing sutures are suture scissors ,the suture scissor usually have long handles, short cutting edge or beaks because main purpose is to cut suture during suturing or on the removal of sutures postoperatively, other types of scissors used in oral surgery are called soft tissue scissors or operating scissors: these scissors are used for cutting of tissues and for dissection or undermining of tissues during surgery , we mainly have two types of operating scissors..

1-small,sharp,delicate ones used for fine work



2-blunt nosed scissors: used for undermining soft tissues as well as for

Blunt tissue scissors



notice that these operating scissors should not be used for cutting sutures or other material because these materials make them blunt ,and it became less effective for cutting tissues.

7-instruments for retraction of soft tissues:


These instruments may be held by the surgeon or his assistant to help the surgeon to have a clear field or area during his work so that it will provide accessibility to the working field and in addition to that it will help in the protection of surrounding tissues from trauma or injury during surgery

There are many types and varieties of retractors ,that have been designed to retract the cheek ,tongue ,lips and mucoperiosteal flaps ,so we have ..

A-Cheek retractor:

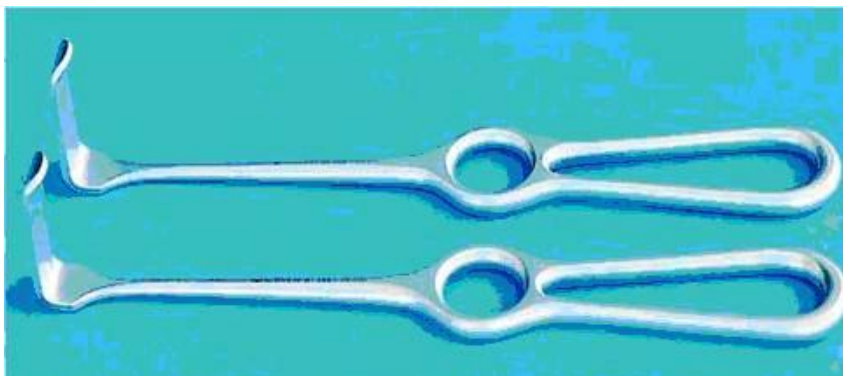
from its name its used to retract the cheek ,the most popular one is the *kilner retractor*, its double ended with different sizes and widths ,and it's held against or at the angle of the mouth ,to retract the cheek away from the operative area .

cheek retractors



B-Mucoperiosteal flap retractor:

it is used to retract the flap away from the operative area ,to provide good vision for the surgeon and to help protect the flap from trauma ,it should be held against the bone and not on the flap ,there are many retractors of different shapes and designs especially made for flap retraction and even *periosteal elevator (Howarth 's)* may be used as a retractor for the flap ..




There is also special retractors for the tongue but usually the mouth mirror is the most common instrument used for tongue retraction and lip retraction



8-instrument for irrigation and suction

A-instrument for suction:

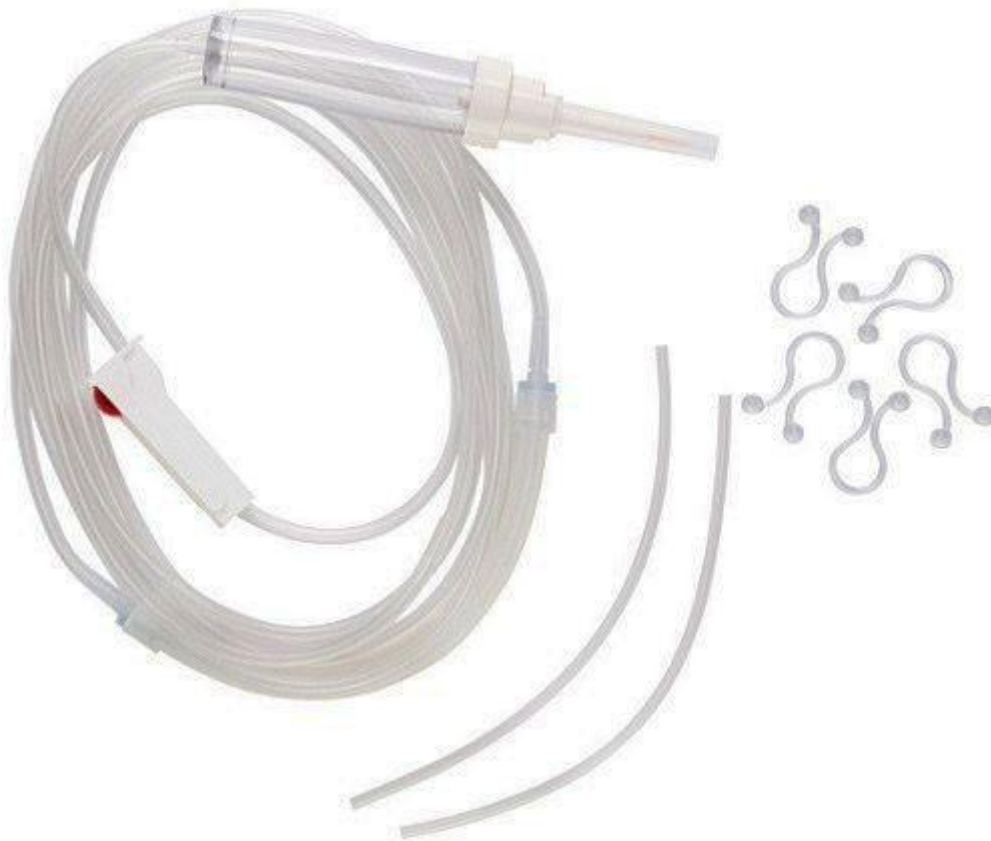
These instruments used to provide good visualization of the operative field by aspirating the blood, saliva and the irrigating solution (e.g. saline, distilled water) used during operation. In oral surgery a fine metal suction tips on vacuum pressure most used to perform such duty. The use of suction also is very important and must be used when we are working under general anaesthesia to prevent the possibility of aspiration of blood and other fluids by the patient.



B-Instruments for irrigation:

When we use hand piece and bur to remove bone its necessary to use irrigating solutions like normal saline to cool the bur and prevent bone damage by the heat generated during cutting of bone ,also irrigation will clean the area of surgery from small debris and chips during the surgical procedure and after finishing before suturing the area ,large plastic syringe with blunt 18 gauge needle is used for irrigation purposes ,the needle should be blunt and smooth so that no damage to the vital organs or soft tissues can occur ,the needle also preferable to be angled to have good and efficient direction of the irrigation fluid .

Irrigation set:



Oral Surgery

Lecture: 6

“Basic Techniques of Dental Local Anesthesia”

A variety of techniques used in administration and deposition of local anesthesia:

1. Topical anesthesia
2. Infiltration anesthesia
3. Field block anesthesia
4. Regional block anesthesia

Selection of the technique depends on the area and the type of the surgery. In general, the infiltration anesthesia is used for the maxilla and the anterior portion of the mandible, while nerve block is indicated for the posterior portion of the mandible.

“Topical or Surface Anesthesia”

Small terminal nerves in the surface area of the intact mucosa or the skin (superficial nerve ending) up to the depth of about 2 mm are anesthetized by application of topical anesthetic agent directly to the area.

This method is commonly used to:

1. Obtain anesthesia of mucosa prior to injection, making the insertion of the needle less painful.
2. Prior to carrying out incision and drainage of abscesses.
3. Prior to suture removal.

Examples of topical anesthesia's preparation:

Lidocaine Spray: The active ingredient is 10% or 15% lidocaine hydrochloride in a water base, which have rapid onset (1 minute), and the duration of anesthesia is approximately 10 minutes.

Ointments: containing 5 % lidocaine hydrochloride, it takes 3 – 4 minutes to produce surface anesthesia.

Ethyl chloride spray: when sprayed on to either skin or mucosa, quickly produces anesthesia by refrigeration. This technique is of limited value but it is occasionally used to produce surface anesthesia prior to the incision of fluctuant abscesses.

“Infiltration Anesthesia”

In this method, the anesthetic solution deposited near the terminal fibers of any nerve. It will infiltrate through the tissue to reach the nerve fibers and thus produce anesthesia of the localized area served by them.

The maxilla has thin labial / buccal cortical plate, shows sites of porosity, which aid in the absorption of the local anesthetic solution. These factors, therefore, make the maxilla more favorable for infiltration anesthesia. The mandibular bone is generally dense and has thicker cortical plates than the maxilla, particularly in the posterior region, so only the anterior part of the mandible presents sufficient porosity, which is favorable for the infiltration.

Advantages:

1. Easy and simple injection
2. Very high success rate
3. Good control of bleeding

Disadvantage: its action is limited to a small area; hence, a considerable amount of solution has to be injected with multiple penetrations when large field is to be anesthetized.

Technique: the recommended gauge of the needle is 25-30 and the recommended length is 25 mm. the bevel of the needle should be facing the bone. The needle is inserted in the middle of the area to be operated and the point of the needle insertion is at an angle of 45 degrees to the long axis of the tooth to be anesthetized. The depth of penetration is beneath the mucous membrane into the connective tissue. This technique may require more than one needle insertions depending on the extent of the area to be anesthetized, care should be taken to avoid injury to the tissue in the following ways:

1. Avoid injecting the solution too rapidly.
2. Avoid injecting too large volume of the local anesthetic solution.
3. Avoid injecting too superficially.

These situations will result in injury to the tissue in the form of pain at the time of injection, or persistent post – injection pain.

Types of infiltration anesthesia

Based on deposition site, this technique includes:

1. **Sub-mucous injection:** the solution deposited just beneath the mucous membrane; the solution diffuses through the interstitial tissue and reaches the terminal fibers of the nerve in the area of deposition. This technique is unlikely to produce anesthesia of the dental pulp it is often employed to anesthetize the long buccal nerve prior to the extraction of mandibular molars or for soft tissue surgery.

2. **Supra-periosteal injection:** in some sites, such as maxilla, the outer cortical plate of alveolar bone is thin and perforated by tiny vascular canals. In these areas when the anesthetic solution is deposited outside the periosteum. It will infiltrate through the periosteum, cortical plate and medullary bone to the nerve fibers. By this means, anesthesia of the dental pulp can be obtained by injecting near the tooth apex. The supra-periosteal injection is the technique most frequently used in dentistry.
3. **Sub-periosteal injection:** the solution is deposited between the periosteum and the cortical plate. This technique is painful since the periosteum is firmly attached to the cortical plate.

"Field Block"

Local anesthetic is deposited near the larger terminal nerve branches so the anesthetized area will be circumscribed. Incision (or treatment) is then made into an area away from the site of injection of the anesthetic. Maxillary injections administered above the apex of the tooth to be treated are properly termed field blocks (although common usage identifies them as infiltration).

"Regional block anesthesia"

In this technique, the anesthetic solution deposited near the main nerve trunk, usually at a distance from the site of the surgical procedure and this will lead to blocking all impulses and produce anesthesia of the area supplied by that nerve. Example: by placing the anesthetic solution in the pterygomandibular space, near the mandibular foramen, regional block anesthesia over the whole distribution of the inferior alveolar nerve on that side is obtained.

Local anesthesia in the maxilla

Anesthesia for the upper molar teeth

The pulps of the upper molars with the exception of the mesiobuccal root of the first molar are innervated by the posterior superior alveolar nerve. This nerve is also responsible for innervations of the alveolar bone, buccal gingiva in the molar region and the mucoperiosteum attached to them. Infiltration technique as follows:

1. Hold the syringe at an angle of 45 degrees with the long axis of the tooth to be anesthetized, with the bevel of the needle facing the bone.
2. Insert the needle into the mucobuccal fold over the target tooth.
3. Advance the needle for few millimeters.
4. Inject slowly, slowly withdraw the syringe and cover the needle.
5. Wait for 2-3 minutes, check for the sign and symptoms of anesthesia, and start the procedure.

Posterior superior alveolar nerve block

The local anesthetic solution is deposited close to the posterior superior alveolar nerve after it leaves its bony canal.

Technique:

1. partially open the patient's mouth
2. retract the patient's cheek with your finger
3. insert the needle into the height of the mucobuccal fold opposite to the distal surface of the maxillary second molar
4. advance the needle in upward, inward and backward direction.
5. deposit 1-2 ml of the anesthetic solution

One of the disadvantages of this technique is the possibility of damaging the pterygoid venous plexus and the risk of hematoma formation.

Anesthesia of the upper premolar teeth:

The mesiobuccal root of the upper first molar, both premolars, and buccal supporting tissue and mucoperiosteum related to them are innervated via the middle superior alveolar nerve. Infiltration technique is usually employed to anesthetize these structures.

Anesthesia of the upper anterior teeth:

The upper canine, central and lateral incisors, labial supporting tissue and mucoperiosteum related to them are innervated via anterior superior alveolar nerve. Infiltration technique is usually employed to anesthetize these structures.

Anesthesia of the palatal tissue

Anesthesia of the posterior portion of the palate could be achieved by infiltration technique (the solution is deposited in the palatal tissue about half way between the midline and the gingival margin of the target tooth at an angle of 45 to the bony surface), or by using greater palatine nerve block (the solution is deposited near the greater palatine foramen, located just distal to the maxillary second molar about 1 cm toward the midline).

Local infiltration of the palate will anesthetize the palatal soft and hard tissues. Anesthesia of the anterior portion of the palate could be achieved by infiltration technique, just next to the target tooth, or by nasopalatine nerve block, where the solution is deposited near the incisive foramen (located in the midline of the palate about 1 cm posterior to the maxillary central incisors).

- ❖ The palatal mucoperiosteum is firm in consistency and is closely adapted to the bone, making the injection of the local anesthetic solution performed under great pressure. This may be minimized by inserting the needle with the bevel facing the bone. If the bevel faces away from bone, the sharp point of the needle would contact the periosteum, tearing it and leading to a more painful (subperiosteal) injection. Post-injection discomfort is considerably greater with subperiosteal than with suprapariosteal injections.

- ❖ The palatal injection is painful, so it is advisable to inform the patient prior to injection. When the needle touches the bone, gently, withdraw the needle by 1 mm (to avoid painful subperiosteal injection) and deposit about 0.25 – 0.5 ml of the solution in the area to be anesthetized, withdraw the needle slowly.

The infra-orbital nerve block injection:

This technique is rarely used since the infiltration techniques are so effective in the maxilla, however, it may be of value if numerous extractions or extensive surgery are to be undertaken in the maxillary incisor and canine regions. It may also be employed for anesthetizing an anterior tooth where the use of infiltration technique is precluded by the presence of infection at the site of injection.

The solution deposited at the orifice of the infra-orbital foramen passes along the canal. The ASA, MSA and the infraorbital nerve with its terminal branches will be anesthetized. The technique is performed Intra-orally. The infraorbital foramen site is palpated, the upper lip is reflected and the tip of a long needle is inserted into the height of the mucobuccal fold over the first molar with the bevel facing the bone. The needle is advanced in line with the long axis of this tooth to a depth of 1.5 – 2 cm then 1 ml of anesthetic solution is given which is enough in most instances. The extra-oral approach is rarely used and involve direct injection through the skin to the foramen.

Maxillary nerve block

The maxillary nerve and all its branches will be anesthetized. These blocks are used for achieving anesthesia of half of the maxilla in extensive surgery. This technique could be used for diagnostic or therapeutic purposes such as trigeminal neuralgia of the maxillary division of the fifth cranial nerve.

Local anesthesia in the mandible

Anesthesia of the lower anterior teeth

The lower anterior teeth are supplied by the terminal branch of the inferior alveolar nerve (incisive nerve). Fortunately, the labial alveolar plate in this region is thinner and more porous than elsewhere in the mandible and because of that, the infiltration technique could be used in this area. This is achieved by deposition of about 1 ml of the solution in the labial sulcus adjacent to the target tooth to anesthetize the pulp and labial supporting tissues.

Anesthesia of the lower premolars and molars

To extract the lower premolar and molars we should anesthetize the inferior alveolar nerve (supply the pulp of these teeth with their periodontium and the bony socket), the lingual nerve (supply the lingual soft tissue adjacent to them) and the long buccal nerve (supply the buccal soft tissue).

- ❖ In children, multiple vascular canals perforate the thin labial/buccal alveolar plate. For this reason, infiltration techniques are highly effective in producing anesthesia of upper and lower deciduous teeth. Care should be taken to avoid the misjudging the length of the roots and inserting the needle too deeply into the tissue.

Inferior alveolar nerve block

The IAN, along with its terminal branches (incisive and mental nerves) are anesthetized by this technique (anesthesia of the pulp of all mandibular teeth in the same side of injection, the skin of the chin and the skin and mucosa of the lower lip). This is achieved by the deposition of the solution around the mandibular foramen in the pterygomandibular space.

Boundaries of the pterygomandibular space

This space is bounded anteriorly by the pterygomandibular raphe and the fibers of superior constrictor and buccinators muscles that are inserted into it. The posterior boundary is formed by the parotid gland. The ramus of the mandible forms the lateral wall while the medial pterygoid muscle forms the medial wall. The lateral pterygoid muscle forms the roof of the space.

The inferior alveolar nerve block technique

The success of this technique is entirely dependent upon the accurate deposition of the solution; this technique will anesthetize the inferior alveolar nerve and its terminal branches.

Technique: the patient is seated in the chair and the headrest adjusted so that his mandibular occlusal plane is horizontal when the mouth is open. The dentist should stand in front of the patient for the right side nerve block and behind the patient for the left. The mouth should be opened widely, the thumb of the free hand should rest on the coronoid notch and the pterygomandibular raphe should then be identified (thick soft tissue band originated from the pterygoid hamulus and inserted on the lingual aspect of the mandible in the third molar region).

The syringe should be introduced from the lower premolar teeth of the other side parallel to and 0.5-1 cm above the lower occlusal plane such that the needle penetrates laterally to the pterygomandibular raphe. The long dental needle should be advanced about 2-2.5 cm until the bone is touched lightly, the needle should then be withdrawn a millimeter or two, the local anesthetic should then be deposited slowly using most of the cartridge's solution.

The local anesthesia is deposited to the inferior alveolar nerve as it enters the mandibular foramen on the medial aspect of the ramus. The lingual nerve, which lies anteromedial to the inferior alveolar nerve is anesthetized by slowly withdrawing the syringe until approximately half the needle's length remains within the tissue, deposit few drops of the solution. The onset of the anesthesia is checked by a change of sensation in the lower lip and the tongue when compared with the other side and absence of pain during the procedure.

Long buccal nerve block

The long buccal nerve provides sensory innervations to the buccal soft tissue adjacent to the mandibular molar teeth, vestibular mucosa and mucosa of the retromolar fossa. A long buccal nerve block is achieved by means of a sub-mucous injection in which the solution is deposited (few drops) just posterior and buccal to the last molar tooth in the arch (between the external and the internal oblique ridge). Infiltration technique for the long buccal nerve is achieved by deposition of the solution in the muco-buccal fold adjacent to the target tooth.

The mental nerve block

This block will anesthetize the pulp and periodontal membrane of the lower incisors, canine, first premolar and sometimes the second premolar (incisive nerve), labial mucous membrane anterior to the mental foramen and the skin of the chin and the skin and mucosa of the lower lip (mental nerve). In dentate patient, the mental foramen lies below and between apices of the lower premolar teeth, approximately halfway between the cervical margin of the teeth and the lower border of the mandible. The solution is deposited at or near the foramen (about 1 ml). In edentulous patients, the foramen may lie near the crest of the ridge because of bone resorption.

Mandibular nerve block

The entire mandibular branch of the trigeminal nerve is anesthetized. The mandibular nerve could be blocked by

1. Intra-oral approach as in Gow-Gates mandibular nerve block and Akinosi (closed mouth) mandibular nerve block.
2. Extra-oral mandibular nerve block.

Gow-Gates mandibular nerve block

This technique is indicated when the conventional inferior alveolar nerve block is unsuccessful.

Akinosi (closed mouth) mandibular nerve block

It is indicated when there is limited mandibular opening and inability to visualize the landmarks for the inferior alveolar nerve block.

Extra-oral mandibular nerve block

This technique is indicated when there is an acute infection at the site of injection for the subdivisions of the mandibular nerve, when there is need to anesthetize the entire mandibular nerve and its branches with one single penetration and minimum amount of local anesthetic solution, and for diagnostic and therapeutic purposes as in trigeminal neuralgia.

“Supplementary Injections”

Sometimes these will produce local anesthesia where all other methods fail:

1. **Intra-ligamentary (periodontal) injection:** the local anesthetic solution is deposited into the periodontal ligament, using small amount of local anesthetic solution usually 0.2 ml delivered via a specifically designed system which comprises of high-pressure syringes and ultrafine needles. This technique can also be carried out by the conventional syringes; however, care should be exercised to avoid shattering of the glass cartridges. The single rooted tooth should be injected on the mesial and the distal sides while the multirooted teeth are injected over each root.
2. **Intrapulpal anesthesia:** put a cotton ball soaked in a local anesthetic solution in the cavity, wait for a minute and then a needle is inserted firmly directly into the pulp chamber or to the root canal.
3. **Intraosseous injection:** In this rarely used method, the local anesthetic solution is deposited directly into the cancellous bone adjacent to the tooth to be anesthetized. An incision is made in the mucosa and the periosteum, a small opening is made in the outer cortical layer of the bone. The needle is inserted into the opening created, and approximately 0.5–1 ml of solution is slowly injected under pressure. Anesthesia by the intraosseous method will not be of very long duration, possibly between 10 -20 minutes.

Speed of injection

Rapid injection of the solution may cause tissue distension and discomfort or actual cellular damage and pain when sensation returns, also the risk of toxic reactions is greater if a quantity of anesthetic solution is injected rapidly, a slow rate of injection is thus essential. In general, the ideal rate of injection is 1 mL/min.

Testing for anesthesia

Altered sensation in itself does not guarantee that anesthesia has been achieved, prior to extraction under local anesthesia a dental probe may be pushed into the gingival crevice on both the labio-buccal and the lingual surface of the tooth. The patient should be told that pressure might be felt and asked to state if sharpness is noted, the presence of sharpness is an indication of a further injection.

The end of Lecture 6

Oral Surgery

Lecture: 7

“Complications of local anesthesia”

The widespread use of local anesthesia in dental practice is in itself attributed to both the effectiveness and safety of the method. Nevertheless, complications occasionally occur and it is essential that the dental surgeon should know how to minimize its incidence.

The complications associated with the administration of local anesthesia classified into local and systemic.

Local complications of the local anesthesia:

1. Pain on injection
2. Burning on injection
3. Failure to obtain anesthesia
4. Persistent anesthesia
5. Needle breakage
6. Facial nerve paralysis
7. Trismus
8. Soft tissue injury
9. Hematoma
10. Infection

1. Pain on injection: Pain on injection increases patient anxiety and may lead to sudden unexpected movement, increasing the risk of needle breakage.

Causes:

- 1) Careless injection technique.
- 2) Rapid deposition of the solution may cause tissue damage and pain.
- 3) Low PH of the solution could irritate the tissue.
- 4) The temperature of the solution: a warmer solution is more comfortable for the patient than the cold one.
- 5) Aggressive insertion of the needle can tear the soft tissue, blood vessel, nerve and periosteum, causing more pain.

Prevention of the pain during injection could be achieved by avoiding the causes.

2. Burning on injection: A burning sensation occurring during injection of local anesthesia is common.

Causes:

- 1) Low PH of the solution.
- 2) Rapid injection of local anesthesia, especially in the denser more adherent tissues of the palate.
- 3) Contamination of the local anesthetic cartridge that can result when they are stored in alcohol or other sterilizing solutions (diffusion of these solutions into the cartridge).

Management: Because most instances of burning on injection are transient and do not lead to prolonged tissue involvement no treatment is indicated.

3. Failure to obtain anesthesia: Although the incidence of this difficulty tends to decrease as the experience of the operator increases it is still probably the most common problem seen during the use of local anesthesia. The problem is most common with block anesthesia, especially in the lower jaw.

Causes:

- 1) **Poor technique:** it is the most common cause of insufficient anesthesia in inferior alveolar nerve block and common mistakes are:

- Injection of anesthesia too soon on the anterior ascending ramus.
- Giving the solution inferior to the mandibular foramen.

- 2) **Anatomical causes:**

- Accessory nerve supply
- Abnormal course of the nerve
- Variation in the foramen location
- Sometimes the tooth is innervated by more than one nerve

- 3) **Pathological causes:**

- Trismus (limited mouth opening): in these cases, it is difficult to use the conventional technique of inferior nerve block.
- Infection and inflammation: if the pulp is inflamed the low PH may cause lack of effective anesthesia in that area. The inflammation makes the nerve more sensitive to pain; minimal stimulation can cause pain perception. In those patients, to obtain proper anesthesia more solution has to be injected, for example, by combining a block, infiltration and supplemental Intraligamentary injections.

- 4) Psychological causes: Fear and anxiety can cause failure in local anesthesia, to enable successful anesthesia relaxation of the patient is sometimes needed. The use of a sedative like benzodiazepine may be helpful.

4. Persistent anesthesia or Paraesthesia, which can be defined as altered sensation beyond the expected duration of anesthesia or it is the prolonged loss of sensation. It is common in dental practice.

When anesthesia persists for days, weeks, or months, there is an increased potential for self-inflicted injury, biting, thermal or chemical trauma which can occur without the patient awareness.

Causes:

- 1) Trauma to any nerve during injection may lead to paresthesia. Patients report the sensation of an electric shock throughout the distribution of the involved nerve.
- 2) Injection of local anesthetic solution contaminated by a neurotoxic substance such as alcohol near a nerve.
- 3) Hemorrhage and infection in close proximity to a nerve may lead to transient paresthesia, due to pressure on the nerve, which resolves when the cause is removed.

Prevention: Strict adherence to injection protocol and proper care and handling of dental cartridges help to minimize the risk of paresthesia

Management: Most paresthesia resolves within approximately 8 weeks without treatment. Reassure the patient that the condition is transient with strict follow up. If the damage to the nerve is severe, the paresthesia will be permanent.

5. Needle breakage: Breakage and retention of needles within the tissue have become an extremely rare occurrence because of the introduction of disposable needles. However, reports of needle breakage still appear.

Causes:

- 1) The primary cause of needle breakage is weakening of the dental needle by bending it before its insertion into the patient's mouth.
- 2) The sudden unexpected movement of the patient.
- 3) Smaller needles (such as gauge 30) are far more likely to break than larger needles (such as gauge 25).
- 4) Re-use of the needle (repeated injection cause fatigue of the needle structure and increases the risk of needle breakage).

5) Incorrect use of the needle:

- Aggressive insertion of the needle into the tissue.
- A sudden change in the direction inside the tissue.
- Too deep penetration as the needle goes up to its hub inside the tissue and might fracture at this point. The hub is considered the most common point of needle fracture.

6) Needles may be defective in manufacture.

Prevention:

- The dentist should check the needles before using them. If there is any suspicion of inadequate product quality a new one should be used.
- Use larger gauge and long needle for techniques needing penetration of significant depths of soft tissue, gauge 25 is appropriate for an inferior alveolar nerve block.
- Do not redirect a needle once it is inserted into the tissue.

Management:

- Stay calm and try to localize broken part in the tissue.
- Tell the patient what has happened and try to relax and comfort him.
- Stabilize the patient's jaws in order that the needle stays in place, if the patient moves his jaw the tension from the muscle of the masticatory system help the needle to penetrate the tissues.
- If a portion of the needle is visible, grasp it firmly with a hemostat and remove it.
- If you cannot remove the broken part by yourself, refer the patient to an oral and maxillofacial surgeon.

6. Facial nerve paralysis: Paralysis of the facial muscles on one side is an uncommon complication of the inferior alveolar nerve block and may be either partial or complete depending upon which branches of the nerve are affected.

Cause: This complication arises if the tip of the needle is inserted too far back and behind the ascending ramus. The solution is then deposited in the substance of the parotid gland, where it anesthetizes the branches of facial nerve causing paralysis of the muscle they supply. Since a fascial sheath envelops the parotid gland there is also a failure in anesthesia of the inferior alveolar nerve.

Clinically the patient will immediately complain of transient paralysis of the muscles of the chin, lower lip, upper lip, eyelid (inability to close the eye) and inability to raise the eyebrow of the affected side.

Management:

- Reassure the patient of the transient nature of the event, it will last for a few hours and will resolve without residual effect.
- Advise the patient to use an eye patch until the motor function returns.
- If contact lenses are worn, they should be removed until the muscular movement returns.

7. Trismus: Trismus defined as a prolonged spasm of the jaw muscles by which the normal opening of the mouth is restricted (locked jaw).

Causes:

- 1) Trauma to the muscles due to the injection of local anesthetics which is the most common etiological factor in Trismus.
- 2) Muscles irritation by local anesthetic solution contaminated by alcohol.
- 3) Hematoma in or around the muscles, the blood is slowly resorbed over approximately 2 weeks.
- 4) Infection after injection can also cause trismus.
- 5) Excessive volume of local anesthetic solution deposited into a restricted area produce distention of tissues which may lead to post-injection trismus and this is more common after multiple missed inferior alveolar nerve block.

Prevention:

- Use sharp, sterile, disposable needle.
- Practice atraumatic insertion and injection technique.
- Avoid repeated injections and multiple insertions into the same area, by getting a good knowledge of anatomy and proper technique.
- Use the minimum effective volume of local anesthetic solution.

Management:

- Heat therapy, which consists of applying hot and moist towels to the affected area for approximately 20 min every hour or using warm saline rinse; a teaspoon of salt is added to a glass of warm water.
- Use analgesic and muscle relaxant.
- The patient is advised to initiate physiotherapy consisting of opening and closing the mouth as well as lateral excursions of the mandible, chewing gum is another means of providing lateral movement of the temporomandibular joint.

8. Soft tissue injury: The soft tissue anesthesia lasts longer than pulpal anesthesia. Trauma to the anesthetized soft tissue can lead to swelling, pain and even infection.

Causes: Self-inflicted trauma to the lips and tongue frequently occurs when the patient bites or chews these tissues while still anesthetized. Trauma occurs most frequently in younger children and in mentally retarded patients.

Prevention:

- The local anesthetic of appropriate duration should be selected.
- A cotton roll can be placed between the lip and the teeth if they are still anesthetized.
- Warn the patient against drinking hot fluid, and biting the lips or tongue.

Management: Management is symptomatic:

- 1) Analgesics for pain.
- 2) Antibiotic if necessary.
- 3) Warm saline rinses to aid in decreasing any swelling present.
- 4) Use any lubricant to cover the lip lesion and minimize the irritation.

9. Hematoma: Hematoma is a localized mass of extravasated blood that may become clinically noticeable following injection. It is caused by penetration of the blood vessel with the needle during injection. The patient will notice the development of swelling and discoloration (bruise). Intraorally the blood vessels most commonly associated with hematoma are:

- the pterygoid venous plexus
- the posterior superior alveolar vessels
- the inferior alveolar vessels in the pterygomandibular space
- the mental vessels
- the infraorbital vessels

Prevention:

- 1) Learn anatomical landmarks and injection technique.
- 2) Avoid relocating the needle to different sites inside the tissue.

Management:

- If it is visible immediately following injection, apply direct pressure if possible. Once bleeding has stopped, inform the patient of what was happened and reevaluate the possibilities of continuing the treatment. Instruct the patient to avoid application of heat over the area, prescribe analgesic and antibiotic if necessary.

- If it is invisible like in case of pterygomandibular space hematoma, the patient will come in the 2nd or 3rd day complaining of trismus, in this case, treat the case as trismus.

10. Infection: Infection after local anesthesia has become rare since the introduction of sterile disposable needles.

Causes:

- Contamination of the needle by touching the mucous membrane in the oral cavity before the administration of local anesthesia.
- Improper technique in the handling of the local anesthetic equipment.
- Injecting the solution into an area of infection, which might transport bacteria into adjacent healthy tissues (spreading the infection).

Prevention:

- 1) Use sterile disposable needles.
- 2) Proper handling of the needle to avoid its contact with nonsterile surfaces.
- 3) Use cartridge only once and store it in their original container, covered at all times.

Management: If an infection does occur the patient will complain of pain and trismus, immediate treatment consists of those procedures used to manage trismus. A course of antibiotic should be prescribed to the patient for 7 days.

Summary: to give efficient local anesthesia, you should gather the following three elements:

- Thorough anatomical knowledge
- Mastering a good technique
- Sterile handling of the dental syringe assembly

Systemic Complications of Local Anesthesia

- 1. Fainting (vasovagal attack)**
- 2. Hypersensitivity or allergy to local anesthesia**
- 3. Overdosage and toxicity**
- 4. Drug interaction**

1.Fainting (Vasovagal Attack)

It is the most common systemic complication that occurs with local anesthesia in the dental office. It refers to a sudden transient loss of consciousness usually secondary to cerebral ischemia. The cerebral ischemia is secondary to vasodilatation or an increase in peripheral vascular bed, with a corresponding drop in blood pressure.

The collapse in the dental chair may occur suddenly and may not be accompanied by loss of consciousness, in most instances, these episodes are vasovagal attack and spontaneous recovery is usual. The patient often complains of feeling dizzy, weak, and nauseated, the skin is pale, cold and slow pulse is noticed.

Predisposing Factors or Triggering Stimulus

The predisposing factors for this condition may be divided into two groups:

1) Psychogenic factors:

- Anxiety
- Emotional stress
- Pain of sudden and unexpected nature
- The sight of blood, surgical or other dental instrument such as a local anesthetic syringe, an injection needle, etc.

2) Non-psychogenic factors:

- Sitting in an upright position or standing for a prolonged period, it leads to pooling of the blood in the periphery, thereby decreasing cerebral blood flow.
- Hunger or starvation, which leads to a decrease in cerebral blood glucose level.
- Poor physical condition.
- Hot, humid and crowded environment.

Mechanism of Vasovagal Syncope

Regardless of the trigger, the mechanism of syncope is similar. The brainstem is activated directly or indirectly by the triggering stimulus, resulting in simultaneous enhancement of parasympathetic nervous system (vagal) tone and withdrawal of sympathetic nervous system tone.

This results in the following responses:

- 1) The cardioinhibitory response, characterized by a drop-in heart rate and in contractility leading to a decrease in cardiac output that is significant enough to result in a loss of consciousness.
- 2) Vasodepressor response: dilation of the blood vessels as a result of the withdrawal of sympathetic nervous system tone. The blood will pool in the dilated peripheral vessels, at the same time, the blood flow to the brain is reduced.

Prevention

The prevention is directed toward the elimination of the cause; good preoperative assessment, the patient should be asked to take a light meal prior to the dental appointment, proper injection technique, use of sedation for the relief of anxiety, etc.

Management

The first aid treatment should be started at once, the head of the patient should be lowered, the legs elevated, tight belt and collar should be loosened, and respiration is stimulated. Spontaneous recovery is usual and it is often possible to complete the treatment at the same visit.

If signs of recovery are not apparent within 30 – 40 seconds, the collapse probably is not a vasovagal attack, the airway must be maintained, oxygen administered and, in this case, a medical emergency team should be asked immediately for help.

Cardiopulmonary Resuscitation (CPR)

An emergency procedure that combines chest compressions with artificial ventilation in an effort to manually preserve intact brain function until further measures are taken to restore spontaneous blood circulation and breathing in a person who is in cardiac arrest. It is recommended in those who are unresponsive with no breathing or abnormal breathing.

CPR involves chest compressions for adults of about 5 cm deep and at a rate of at least 100 per minute with a universal compression to ventilation ratio of 30:2 is recommended for adults. The rescuer may also provide artificial ventilation by

either exhaling air into the subject's mouth (mouth-to-mouth resuscitation) or use a device that pushes air into the subject's lungs (mechanical ventilation).

2.Hypersensitivity or Allergy to Local Anesthesia

It is more commonly seen with ester type agent than amide type. Hypersensitivity reaction could be due to:

- local anesthetic agent
- vasoconstrictor
- additives like bisulfite which is used as a preservative

In general, hypersensitivity reaction to local anesthesia is very rare and represent less than 1 % of all complications of local anesthesia. True allergic response to local anesthesia may be localized or generalized and it may be immediate or delayed in onset, also the allergic reactions may vary from mild skin irritation or rashes to an anaphylactic reaction. Local reactions are seen more frequently than systemic and usually resolve without active treatment. If any degree of allergic reaction is observed, it is very important to determine the actual cause (allergen). Inadequate diagnosis and treatment can be life-threatening to the patient.

Clinical manifestations of allergy vary and include the following: fever, angioedema, urticaria, dermatitis, photosensitivity or anaphylaxis.

Prevention

Proper pre-anesthetic evaluation, which includes a proper personal history and the past dental history, particularly history of allergy to the local anesthetic agent, or history of allergy to any other drug.

Management

- Antihistamine injection
- Epinephrine 0.5 ml of 1:1000 IM (intramuscular)
- Administer O₂ if necessary.

Substitution of the local anesthetic agent

The local anesthetic agent can be substituted with another type of agent. If the reaction is in response to ester-type then an amide type such as lidocaine could be used.

Anaphylactic Shock

It is a rare, life-threatening hypersensitivity reaction to an antigen. It develops fast causing death within a few minutes. It is characterized by:

- 1) profound fall in the blood pressure
- 2) dyspnea and respiratory embarrassment
- 3) facial and laryngeal edema
- 4) loss of consciousness

Management of anaphylaxis

If you suspect the anaphylactic reaction, immediately seek medical help.

- Epinephrine is the most important medication; it is given as intramuscular injection working rapidly to make the blood vessels contract. it also relaxes the airway, helping the individual breathe easier and stop itching.
- Even if the patient responds to the epinephrine, it is vitally important to go to an emergency room immediately.
- Oxygen should be given to improve breathing.
- Intravascular (IV) fluid may be necessary to restore adequate blood pressure.
- Antihistamine should be given to contract the effect of histamine.
- If the patient stops breathing, start cardiopulmonary resuscitation (CPR) immediately until the patient begins to breathe again.

3.Overdosage and Toxicity

It is relatively rare, a toxicity reaction can occur when the concentration of local anesthesia in circulation increases too rapidly within a short period of time as in injecting too rapidly into the highly vascular area or when giving IV injection. The toxic effect is primarily directed to the central nervous system (CNS) and cardiovascular system (CVS). The dose necessary to induce toxicity varies among patients and is influenced by numerous factors which are:

- The patient general health, age and weight: in patients with dysfunction of the liver and kidneys, there is an increased level of local anesthetic in the bloodstream.
- Rapidity of injection.
- Rout of administration.
- Amount of local anesthesia administered.

Signs and symptoms: restlessness, agitation, convulsion along with increased blood pressure, heart rate and respiratory rate. There are two types of drugs that can exhibit toxic reactions in dental practice local anesthetic agent and the vasoconstrictor.

Prevention: The best method to avoid toxic reactions is by:

- 1) Use the smallest possible volume and lowest effective concentration.
- 2) The local anesthetic solution should be injected slowly.
- 3) Avoid intravascular administration by the use of aspirating syringe.

Management

- Stop the dental procedure.
- Position the patient supine with legs elevated.
- Reassurance of the patient.
- Administer O₂, IV anticonvulsant and monitor vital signs.
- Allow the patient to recover and then discharge.
- If the patient fails to recover then transfer him to the hospital.

Factors adding to the increased risk of local anesthetic overdose in younger patients

- 1) Treatment plan where all four quadrants are treated with local anesthetic in one visit.
- 2) Use of plain local anesthetic.
- 3) Exceeding the maximum dosage based on patient's body weight.

4. Drug Interaction

In some patients, the administration of two drugs will counteract each other, while in others, potentiation occurs. In patients using a tricyclic antidepressant, variable degrees of potentiation of blood pressure response to adrenaline will occur even to small doses; therefore, precautions should be taken during the use of these vasoconstrictors with the patient taking a tricyclic antidepressant.

The practitioners can minimize the risk of interaction by using an aspirating syringe, which reduces the likelihood of the local anesthetic being administered directly into a blood vessel.

Last Lecture

Oral surgery

Complications of exodontia

Complications can arise during the procedure of extraction or may manifest themselves sometime following the extraction, so we have immediate complications and post-operative one.

All these complications arise from error in judgment, misuse of instruments, exertion of extensive force or from anatomic causes or factors.

By careful diagnosis and planning of the procedures many complications can be avoided but some of these complications may occur even when utmost, care is exercised, so that the dentist or the oral surgeon should be qualified to deal with each complication successfully.

So, the possible complications are: -

1- Failure to secure anesthesia.

Failure to secure profound or good anesthesia may be due to:-

- a- Faulty technique, or Insufficient dosage of anesthesia.
- b- Expired anesthesia.
- c- The presence of acute infection.

2- Failure to remove the tooth with either forceps or elevator.

failure to remove the tooth after applying a reasonable amount of force without movement or yielding of the accused tooth need further clinical and radiological evaluation, because the tooth may be need surgical extraction.

3- Fracture (#) of: -

- A. Crowns and roots.
- B. Alveolar bone.
- C. Maxillary tuberosity.
- D. Adjacent or apposing tooth.
- E. Mandible.

a-Fracture of crowns and roots: -

The most common complication during tooth extraction is fracture of the tooth crown or roots.

The factors that may lead to fracture of crown or roots may be classified into three groups:

1. Factors related to the tooth itself.
2. Factors related to the bone investing that tooth.
3. Factors related to the operator (dentist).

1- factors related to the tooth itself

means that the tooth may be badly carious, or heavily filled, brittleness of the tooth due to age, or non-vitality, root canal filled tooth. Also peculiar root or crown formation like dilacerated tooth, geminated tooth, severely curved root, divergent roots, convergent roots, hyper-cementosis, accessory root and complex root shape, malposed tooth, insufficient space for the application of the extraction instrument, internal & external! resorption.

2-Factors related to the investing bone

means the surrounding bone might be excessively dense or sclerotic due to localized or systemic causes.

3-factors related to the operators

includes improper application of the beaks of the dental forceps or elevator on the tooth to be extracted; like the placement of the beaks of the dental forceps on the crown instead of the root or below the cemento-enamel junction, also the beaks are not parallel to the long axis of the tooth, also the use of wrong type of forceps.

Incorrect application of force during extraction by wrong direction in addition to that the use of twisting or rotational movement when not indicated like the use of twisting movement in extraction of upper 1st premolar or upper 1st and 2nd molar for example.

b- Alveolar bone fracture: -

Fracture of alveolar bone frequently occurs when extraction is difficult. The fractured bone may be removed with tooth to which it is firmly attached or it may be remain attached to the periosteum or it may be completely detached in the socket or wound.

It is a common complication that especially occurs on labial(buccal) area during extraction of upper canine and upper and lower molar teeth.

This complication might be due to: -

1. The alveolar bone is very thin.
2. Accidental inclusion of the alveolar bone within forceps blades
3. Configuration of the roots.
4. The shape of the alveolus.
5. Pathological or physiological changes in the bone itself like Ankylosis (bony connection between the tooth and bone), the presence of destruction in the alveolar bone due to the presence of discharging sinus.

c- Maxillary tuberosity fracture: -

Sometime the tuberosity is completely fractured when we try to remove maxillary 3rd or 2nd molar.

Fracture of maxillary tuberosity may lead to a wide opening into the antrum called Oro-antrum communication with irregular tearing in the covering soft tissue lead to profuse bleeding and post- operatively may lead to difficulties in the retention of upper denture.

This complication might occur if the molar tooth to be extracted is isolated and subjected to full force of bite leading to sclerosis of the surrounding bone, or due to downward extension of the maxillary sinus to the nearby edentulous alveolar bone or due to large abnormal size of the maxillary sinus extended to involve the tuberosity; in addition to that, the use of excessive force or wrong positioning of the elevator in the extraction of upper 3rd molars

d-Fracture of the adjacent and opposing tooth; -

Adjacent teeth occasionally may be damaged during extraction procedures, this may include loosening or dislocation or fracture of the adjacent teeth.

This misshapes occur mostly due to careless use of the dental forceps or elevator by wrongfully using the adjacent tooth as a fulcrum during the use of elevator or the application of the beaks of dental forceps, also fracture of the crown of adjacent tooth or fracture and dislodgment of its filling.

In addition to that opposing teeth may be chipped or fractured if the tooth being extracted yield suddenly to uncontrolled force of the forceps striking the opposing tooth leads to this complication.

e-Mandible fracture: -

This is a rare complication, but it might occur almost exclusively with the surgical removal of impacted lower third molar tooth.

A mandibular fracture is usually the result of the application of a force exceeding that needed to remove a tooth and often occurs during the use of dental elevators (winters elevator), but sometimes pathological or physiological changes may lead to weakened mandible like: -

1. Senile atrophy and osteoporosis of the bone.
2. Osteomyelitis e.g. osteoradionecrosis.
3. cystic lesion.
4. Impacted teeth.
5. Tumour, benign or malignant..

So, preoperative clinical and radiographic evaluation is very important to avoid such complication or preventing it.

4. Dislocation of the temporo-mandibular joint (T.M.J.): - Exertion of high amount of force during extraction of lower teeth especially posterior teeth may lead to dislocation of the condyle of the mandible and the patient becomes unable to close his/her mouth, especially in patient who had a history of recurrent dislocations in TMJ.

if this dislocation occur it should be reduced immediately by the operator by standing in front of the patient and his thumbs placed intra-orally on the external oblique ridge lateral to the molar teeth and other fingers outside the mouth under the lower border of the mandible, downward pressure with the thumbs and upward pressure with the other fingers may reduce the dislocation, if reduction is delayed it become difficult to reduce it because of muscle spasm and the patient may need general anesthesia to reduce the dislocation, also the patient may complain of traumatic arthritis of the TMJ. Post-operatively due to high pressure applied to the joint during extraction, so supporting the mandible during extraction prevents such complication.

5. Displacement of a root into the soft tissue and tissue spaces and the maxillary antrum: -

During extraction especially on use of elevator, a root or piece of root may be dislodged into the soft tissue through a very thin bony plate overlying the socket and disappear buccally or lingually into the soft tissue between periosteum and bone in the vestibule, but sometimes a root or even a tooth may be displaced into the tissue spaces surrounding the jaws e.g. a retained root in the lower molar teeth may be displaced into the sublingual or submandibular space or e.g. upper third molar may displaced into the infratemporal space.

So the extraction with high force without direct vision on the retained root may lead to such complications, also retained root may be displaced into the maxillary antrum during the extraction of upper molar or sometimes premolar teeth especially palatal root of upper molar teeth.

The presence of large antrum or the use of excessive force during extraction or due to pathological conditions like periapical pathology. All these factors may assist or predispose to such complication, so pre-operative radiograph and clinical evaluation may assist in the prevention of such complication.

6- Excessive bleeding after extraction: -

At the beginning one must understand that some slight oozing of blood for several hours following tooth extraction is considered normal. But sometime excessive or abnormal bleeding may occur following tooth extraction.

The causes of excessive bleeding may be due to:-

A. Local factors

The local causes which are the commonest causes for prolonged bleeding as in usual, due to gross tissue damage, when there is severe bone injury and tearing of the periosteum many vessels are opened also severe gingival lacerations, also damage to large arteries like inferior dental vessel or greater palatine vessels may lead to profuse bleeding, also the presence of Hemangioma (central) and other vascular abnormalities may lead to such complication. Also post-operative infection of the extraction wound causing erosion of the blood vessel leading to secondary haemorrhage, also the working in acutely inflamed area may assist in the prolonged bleeding.

B. systemic factors

For the systemic causes like systemic haematological disorders like thrombocytopenia, reduction in the clotting factors, anticoagulant drugs, hereditary blood disease like haemophilia, all these factors may lead to severe bleeding; so good history and clinical examination and blood investigation is very important and essential before any extraction especially if the patient gives you a history of bleeding on previous extractions or trauma.

7-damage to the surrounding soft tissues.

a. Damage to the gum or lip.

like laceration of the gum during extraction occurs if the gingival tissue not reflected before extraction so gum adhere to the tooth to be extracted from its socket should be carefully dissected before any further attempts to deliver the tooth are made, also the inclusion of the gum by forceps beaks or by blind application of the forceps may lead to crushing of the soft tissue, also the lower lip may be pressed or crushed between the handles of the forceps and the lower lip on extraction of upper teeth if sufficient care is not taken .

b. damage to the tongue and floor of the mouth

Also slipping of elevator during extraction may lead to damage or wounds in the floor of the oral cavity, there are many vital structures in the floor of the oral cavity which might be damage like [sublingual gland , submandibular duct, lingual nerve & tongue]. So the operator should always keep in his mind that supporting of elevator during extraction is very important.

C. Damage to nerves

occur mostly on surgical extraction of teeth rather than simple extraction but one must always be aware of the risk when operating in the region of the (inferior dental nerve, lingual nerve & mental nerve). Inferior alveolar nerve injury is an uncommon occurrence in extraction of erupted mandibular teeth. In rare cases third molar roots may *encircle the nerve* so that extraction of the tooth will cause nerve injury also currature or improper use of elevators to remove root apices may cause tearing or displace bone fragments so that will be impinging or pressing the nerve in the canal "inferior dental canal" result in *Paraesthesia or anesthesia* of half of lower lip.

The mental branch of the alveolar nerve also may be injured during surgical procedures in the premolar region. The lingual nerve may be damaged during exodontias of the lower molar teeth especially the lower wisdom tooth by trapping the lingual soft tissue in the forceps beaks or by direct trauma from misusing of elevator or by using surgical extraction to remove impacted wisdom tooth.

8-post -operative pain:

Post-operative pain and discomfort after extraction due to traumatized hard tissue may be from bruising of bone during instrumentation or from using burs for removal of bone also damage and rough handling of soft tissue during extraction is another cause for postoperative pain.

The most common cause for the moderate to severe continuous pain after extraction is related to a well-known cause called ***dry socket or acute localized alveolar Osteitis***. -The patient presented with continuous moderate to severe pain after 24-72 hours after extraction which may last for 7 to 10 days clinically the patient may presented with empty socket (there is no clot in the socket) , exposed bone or empty socket with some evidence of broken-down blood clot and food debris within it with intense bad odour. The aetiology of this condition is incompletely understood but many predisposing factors exist like infection, trauma, blood supply, site, smoking, sex, vasoconstrictors or systemic factors.

9-post- operative swelling:

After extensive surgical interference and exodontias some time may be associated with post-operative swelling, this swelling may be related to one or more of the following causes: (A-Oedema, B-Infection, C-Hematoma.)

a. Oedema:

oedema occurs after surgery as a result of tissue injury (*it is normal response*) when there is great damage to the tissue by using blunt instrument. And rough handling of tissue may Increase the chance of production large oedema.

So laceration of tissue during extraction, trauma to the bone or periosteum are some of the most common causes of oedema and in other words *post-operative swelling*, persistent post-extraction swelling or the development of swelling several days after surgery is usually due to infection.

b. infection

swelling due to infection can be distinguished from postoperative oedema by the increased skin temperature, greater redness of the overlying tissues, the usual presence of fever and sometime fluctuation is present due to presence of pus. The infection should be always considered a serious complication and need urgent management.

c. hematoma

means a collection of blood in the extra-vascular spaces of the tissues. It is rare complication following extraction of the teeth, but sometimes hematoma or ecchymosis (bruising) may develop postoperatively if haemostasis is not developed and persistent bleeding from either the socket or adjacent alveolar bone.

10-The creation of an oroantral communication.

On extraction of upper molar teeth and sometimes upper premolars a communication between the oral cavity and maxillary antrum may be created. This communication if not healed or closed after few days a chronic condition occurs called *Oro- antrum fistula*.

Close proximity of the maxillary cheek teeth to the maxillary antrum which are separated only by little amount of bone and sometime even the soft-tissue lining of the maxillary sinus, the presence of periapical infection, the antrum itself may be abnormal in size, misjudgement of the amount of force and its direction used in extraction or the presence of pathological lesions. all these factors may assist in the production of this complication.

to confirm the presence of this complication, the patient is asked to pinch or close the nostrils together and blow air **gently** into the nose, the operator may see blood bubbling, or shooting of air through the communication is heard or a piece of cotton on tweezer may be defected. The *presence of* this complication needs surgical correction by well-trained oral surgeon and surgical unit in which all instruments and qualified staff present.

11-Trismus:

Means inability to open the mouth, trismus is one of common complication following extraction of teeth especially the surgical removal of wisdom teeth.

Trismus may be caused by post-operative *oedema, hematoma, inflammation of the soft tissue*. *Trauma and arthritis* of the temporomandibular joint, it may be related to the use of *inferior dental block* local anesthesia so the management of the trismus depend on diagnosis of the cause of this complication

12-syncope(fainting): -

Collapse on the dental chair is a common complication during extraction. The patient may often complain of feeling dizzy, weak & nauseated, and the skin is seen to be pale, cold and sweating, these complains may be accompanied by loss of consciousness, and the patient if not noticed at the beginning of the fainting may shows episode of convulsion.

The primary pathophysiological component of this situation is *cerebral ischemia* secondary to an inability of the heart to supply the brain with an adequate volume of oxygenated blood. In the presence of anxiety, blood flow is increasingly directed toward the skeletal muscles at the expense of other organ systems such as the gastrointestinal tract, in the absence of muscular movement, the increased volume of blood in the skeletal muscle remains there, decreasing venous return to the heart and decreasing the volume of blood available to be pumped by the heart (uphill) to the brain.

A slight decreased in cerebral blood flow is evidenced by the signs and symptoms of vasodepressor syncope (i.e., light headedness, dizziness, tachycardia, palpitation) if this situation continues cerebral blood flow declines still further and the patient loses consciousness.

When the operator notices these signs and symptoms a first aids treatment should be started by lowering the head of the patient by putting him in supine position by lowering the back of the dental chair. Care should be taken to maintain the airway and you have to notice the condition of the patient. if consciousness is not returned within 1-2 minutes otherwise one should consider that something serious like *respiratory arrest* or *cardiac arrest* may happen and the patient need medical emergency.

Oral Surgery

Indication & contra-indication of extraction

Lec. 2

د. علي محمد

EXTRACTION OF TEETH (EXODONTIA):-

Extraction of teeth is the most important part of minor oral surgery and the most common procedures to general dental practitioner (dentist).

Definition: -

Exodontia is a painless removal of teeth from their bony alveolar socket with relatively minimal amount of trauma to the investing or surrounding tissues, so that the wound may heal without postoperative problems.

Basically, we have two methods of extraction:-

- 1- Intra-alveolar extraction (forceps extraction).
- 2- Trans-alveolar extraction (surgical extraction).

In forceps extraction which is enough for extraction in most of cases consist of removing the tooth or root by the use of forceps or elevators or both. While in trans-alveolar extraction we dissect the tooth or root from its bony attachment by rising a flap and removal of some of the bone surrounding the roots, which are then removed by the use of elevators and/or forceps.

INDICATIONS OF Extraction: -

There are many indications for tooth extraction, if conservative treatment has either failed or is not indicated, a tooth may have to be extracted. The reasons for extraction of teeth are based on the presence of local pathology, the feasibility of restorative procedure (function of the dentition as a whole and the patient's attitude and education). Although the modern dentistry tries and takes all measures to preserve and maintain teeth in the oral cavity, there are still a variety of general indications for removing teeth.

Indications of teeth extraction.

1- Severe caries: -

This is the most common reason to remove a tooth. Badly carious teeth that are beyond restoration should be removed.

Badly carious teeth result in deterioration of the oral hygiene resulted in bad oral hygiene and bad smell in addition to that sharp edges of the carious teeth leads to repeated trauma and ulceration to the mucosa and the tongue, in addition to pain during eating and drinking. Untreated teeth with caries may end with pulpitis, periapical pathology etc...

2- Severe periodontal disease: -

Severe and extensive periodontal disease is a common reason for tooth removal, in chronic periodontitis there is excessive bone loss and mobility in the tooth. As a rough guide, loss of about half of the normal alveolar bone or extension of pockets to the bifurcation of the roots of posterior teeth and hypermobility of the teeth means that extraction of the involved tooth is necessary.

Patient with advanced periodontitis may complain of mild to severe throbbing pain in case of development of Paradental abscess.

3- pulp pathology: -

For example acute pulpitis or chronic pulpitis, non-treatable pulpal lesion. if endodontic therapy wasn't possible or if the tooth isn't amenable for endodontic treatment, extraction is indicated.

4- Apical pathology:-

Periapical lesions like periapical abscess, periapical granuloma, cyst. If the teeth fail to respond to all conservative treatment to resolve apical pathology due to technical reasons or other causes such teeth are indicated for extraction.

5- Orthodontic reasons:-

During the course of orthodontic treatment, tooth or teeth maybe extracted for:-

- a) **Therapeutic extraction** e.g. extraction of upper first premolar for treatment of malposed upper canine and extraction of teeth to provide space for teeth alignment.
- b) **Malposed teeth:** teeth which erupted out of the line of arch are difficult to clean and not amenable for orthodontic treatment are indicated for extraction.

- c) **Preventive extraction**, means that during mixed dentition period (permanent and deciduous teeth), dental surgeon may extract few deciduous teeth to prevent malocclusion and all these extractions should be done after proper evaluation by specialist orthodontic.

6-Prosthetic considerations:-

Extraction of teeth is indicated for:-

- 1) Providing efficient dental prosthesis.
- 2) To provide better design for success of partial denture, few teeth maybe extracted.
- 3) Solitary tooth or non-strategic tooth to enable the patient to have complete denture e.g. full mouth clearance.

7- Impacted teeth.-

Retention of un erupted teeth beyond the normal time of eruption may sometimes be responsible for: -

- a) Vague facial pain.
- b) Periodontal problems of the adjoining teeth.
- c) Tempromandibular joint problems.
- d) Bony pathology e.g. cyst (dentigerous cyst), tumor, pathological fracture.
- e) May predispose to anterior teeth crowding
- f) Significant infection (pericoronitis) e.g., partially erupted third molar.

8-Supernumerary teeth

The teeth maybe impacted or malposed and such teeth may predispose to malocclusion, periodontal disturbances, facial pain, bony pathology (cyst), aesthetic problems and preventing the eruption of adjacent teeth.

9- Tooth in the line of fracture of the jaws:-

This tooth maybe extracted if:-

- a) It is a source of infection at the site of the fracture.
- b) The tooth itself is fractured.
- c) Interfere with fracture reduction.
- d) Interfere with healing of fracture.

10- Teeth in relation with pathological conditions:-

They are indicated for extraction if they are involved in:-

- a) Cyst formation.
- b) Neoplasm (tumour).
- c) Osteomyelitis (Infection of bone).
- d) Pyogenic granuloma

And the tooth interfere with complete surgical removal of the lesion the tooth should be extracted.

11-Retained roots

Retained roots may remain embedded in the bone without problems for a long period, but sometimes removal of such roots maybe necessary, for example, root maybe at the sub mucosal level producing recurrent ulceration under the denture, sometimes root fragments may be involved in initiation of bony lesions like osteomyelitis, cystic lesion or neoplasm, if such fragments are in close relation to the neurovascular bundle (e.g. inferior dental nerve of the mandible) the patient may complain of facial pain or numbness in the area supplied by that nerve. As a general rule, very small fragments maybe left alone and that patient should be kept under periodic observation, and all other root fragments are indicated for removal.

12- prior to irradiation :-(before radiotherapy)

Irradiation is one of the methods of treating oral carcinomas and teeth which cannot be kept in a sound condition should be removed before irradiation, trauma (extraction) with superadded infection will lead to development of osteoradionecrosis of the jaw bone which is unpleasant complication and difficult to be treated.

13-Focal sepsis:-

Sometimes teeth or a tooth may appear sound clinically, but on radiographic examination the tooth may appear to be considered as a foci of infection (teeth associated with periapical pathology or periodontal problems), these teeth or tooth should be extracted in certain conditions e.g. heart surgery; heart valve replacement, kidney transplant, eye Surgery

14- Aesthetic:-

Poor aesthetic, severely stained (tetracycline, fluorosis) attrition or hypoplastic (hypoplasia) of enamel or dentine and they cannot be restored may be indicated for extraction.

Contra-indications of teeth extraction.

In general, the contra-indications are subdivided into;

- 1- Local contra-indications.
- 2- Systemic contra-indications.

Local contra-indications: - (L.C s)

There are several L.C s to extractions of indicated teeth:-

1- Acute and uncontrolled infection:-

Extraction in the presence of acute and uncontrolled infection may lead to spread of infection locally or systemically leading to many complications some of them are dangerous and life threatening (e.g. cavernous sinus thrombosis, mediastinitis, Ludwig's angina) and acute periapical abscess and facial abscess especially in medically compromised patient. In addition to that, limitation of mouth opening especially in lower wisdom tooth infection.

2- Previous radiotherapy:-

Previous therapeutic radiation in oral and maxillofacial region for treatment of cancer lead to fibrosis and decreased vascularity of the tissue or area of extraction and end with a condition in the bone called osteoradionecrosis

3- Teeth located within area of tumour: -

Especially in vascular lesion or malignant tumor should not be extracted because extraction may lead to dissemination of the tumor, unhealed socket and postoperative complications, for example, bleeding postoperatively and intraoperative.

Systemic contra-indications:-

Systemic contra-indications preclude extraction because the patient's systemic health is such that the ability to withstand the surgical work may be compromised. So extraction should be postponed until the severity of the problem has been resolved and maybe arranged after consultation with the physician to perform extraction safely without complications so caution is advised in the following conditions:-

1- Severe uncontrolled metabolic disease, e.g. uncontrolled diabetes, end-stage renal disease.

2- Uncontrolled leukaemia and lymphomas.

3- Severe uncontrolled cardiac disease, e.g. myocardial infarction, unstable angina pectoris, dysrhythmias.

4- Severe uncontrolled hypertension.

5- Pregnancy.

6- Bleeding disorder e.g. haemophilia, platelet disorder, patient on anticoagulants.

7- Patients who take a variety of medications e.g. patient on steroid and immunosuppressive drugs, cancer and chemotherapy.

8- Uncontrolled epilepsy.

Pre-extraction evaluation:-

P.E.E is very valuable and necessary for successful extraction practice. Hurry and inadequate P.E.E of the case may lead to many embarrassing intra-operative problem for the operator, in addition to the postoperative problems to the patient,

P.E.E include:-

1- Clinical preoperative evaluation.

2- Radiological evaluation

1-Clinical P.E.E also includes:-

a) General evaluation.

b) Local evaluation.

A -General evaluation includes:-

- General impression of the patient.
- History of general diseases, Nervousness and orientation
- General oral hygiene.
- Gingival inflammation, calculus, neglected mouth.

b- Local factors evaluation Includes:-

- Clinical examination of the accused tooth.
- Adjoining structures.
- Access to the tooth. This includes the mouth opening, location of the tooth (e.g. buccally malposed, in standing) may present difficulty in positioning the dental forceps for extraction, so you may remove such a tooth surgically.
- Tooth mobility: The mobility of the tooth to be extracted should be assessed preoperatively, greater than normal mobility is frequently seen with severe periodontal disease, but sometimes it maybe because of the underlying pathology like neoplasm
- **Condition of the tooth: - e.g.**
 - a) Carious destruction.
 - b) The presence of large restoration.
 - c) Presence or absence of the adjoining teeth.
 - d) Non-vital tooth.
 - e) State of the supporting tissue.
 - f) Shape, position, long axis and size of the crown.

g) Attrition.

Good P.E.E resulted from correction of data collected from history, clinical examination, radiographs and laboratory aids in addition to that P.E.E need good knowledge and experience in the basic sciences e.g. anatomy, physiology, pathology.

In general, P.E.E may help you in: -

- a) Determine the method of extraction and type of anaesthesia.
- b) Reduce the time spend for extraction.
- c) Reduce the intra and post-operative crisis and complications.

2- Radiological evaluation: -

Preoperative clinical assessment maybe supplemented some times by preoperative radiographs, and the positive indications for preoperative radiograph are:-

- 1) History of difficult or unsuccessful extraction.
- 2) Crown with extensive caries, large restorations, non-vital tooth when diagnosis is not certain and tooth is malposed.
- 3) A tooth which is abnormally resistant to forceps extraction.
- 4) If after clinical examination you decide to remove the tooth surgically.
- 5) Any tooth which is in close relation to important or vital structures like neurovascular canal, maxillary sinus, mental nerve, nasal cavity.
- 6) Attrition teeth in elderly patient (maybe associated with hypercementosis).
- 7) If a tooth is partially erupted or completely unerupted or retained root.
- 8) Any tooth which has been subjected to trauma,

fracture of the root and/or alveolar bone maybe

present.
- 9) An isolated maxillary molar especially if it is unopposed and over erupted. The bony support of such a tooth is often weakened by the presence of maxillary sinus and this may predispose to certain of oro-anrtal communication or fracture of the maxillary tuberosity.
- 10) Whenever, underlying bony pathology is suspected e.g. cystic lesion, tumor.

11) Any systemic condition which may predispose to dental or alveolar abnormality like: -

- a) Osteitis deformans (Paget's disease), in which the roots are hypercementosed and ankylosed leading to difficult extraction, infection of the socket.
- b) Cleido-cranial dysostosis, for pseudo-anodontia (multiple impactions, hooked roots occur, supernumerary teeth).
- c) Patient who have received therapeutic irradiation to the jaw which may have to predispose to osteoradionecrosis.
- d) Osteopetrosis (marble bone disease), which cause extraction very difficult and predispose to chronic osteomyelitis.

• **A good radiograph and careful interpretation may give or aid the operator to many factors that may cause difficult extraction, e.g.:-**

- 1- Abnormal number and shape of roots.
- 2- An unfavourable root pattern.
- 3- Caries extending to the root mass.
- 4- Fracture or resorption of the root.
- 5- Hypercementosis of roots.
- 6- Ankylosis (there is no space in periodontal ligament), and sclerosis of the bone.
- 7- Gemination (the development of two teeth from one bud).
- 8- Impaction.
- 9- Bony sclerosis and pathological lesions.

Also careful interpretation of the radiograph may also reveal or show the possibility of the following complications:-

- 1) Involvement of, and damage to inferior dental nerve and mental nerve e.g. on extraction of impacted lower third molar
- 2) The creation of oro-antral fistula or or-nasal communication.
- 3) The retention of intra-bony pathology e.g. cyst.
- 4) The displacement of root or tooth into maxillary sinus.
- 5) Fracture of maxillary tuberosity.

Oral surgery

TYPES OF DENTAL FORCEPS

THE FORCEPS FOR UPPER TEETH

1- The upper straight forceps:-

The blades, joint and handle are in one long straight line. We have two types, one with broad blades that is we call heavy blades and this is used for extraction of upper central incisors and upper canines, left and right.

The second type of straight forceps has narrow blades or we call it fine blades for extraction of upper lateral incisors (left and right) and upper anterior retained roots.

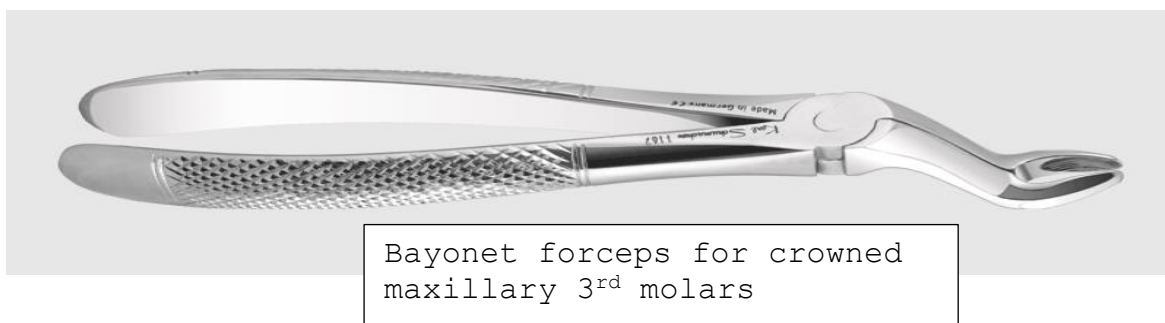
2- The upper premolar forceps:-

Here we have two bends in the design of the forceps, one where the beaks (blades) bend in relation to the joint of the forceps to apply the forceps parallel to long axis of premolar, the 2nd bend or curvature is of the handle to avoid injury to the lower lip and apposing teeth (mandibular). The upper premolars teeth has either one root or two roots (one buccal and one palatal), so there is no difference in the anatomy of the tooth root of the premolar on the buccal and palatal surface so the two blades of the premolars forceps are mirror image to each other.

3- The upper molar forceps (full crown upper molar forceps):-

Since upper molar teeth have three roots, two buccal and one palatal, the blade of palatal side is round to conform or fit on palatal root, while blades on buccal has pointed tip or projection so it can enter or fit the bifurcation between the two buccal roots (mesial and distal) on the buccal side of the tooth. So we have two forceps; one for the right molars and one for the left molars and these forceps also double bend for the same requirement as mentioned for premolar teeth.

The Bayonet forceps, the blades of the forceps are off set to the long axis of the handles, used for extraction of upper 3rd molars right and left. In addition, there is another bayonet with fine curved blades for extraction of upper posterior roots.



THE FORCEPS OF LOWER TEETH;-

Here we have the long axis of the blades is in right angle to the long axis of the handle so the blades can be applied apical to the cemento-enamel junction (on the root) of the tooth surface parallel to the long axis of the tooth and the handle not to cause injury to the upper lip. The forceps for the lower teeth are:-

1- Forceps for extraction of lower central and lateral incisors and canine:-

We have fine blades for extraction of the lower central and lateral incisors and lower anterior retained roots which have fine roots with flattened sides (mesiodistally) and heavy blades used for extraction of canines.

2- Premolar forceps:-

Because the bucco-lingual width of the crown in the premolar teeth is larger than that of lower incisors and canines we use forceps with heavy blades but partially away from each other when close to accommodate the crowns of these teeth without crushing for the crown.



Lower premolar tooth forceps



Lower molar tooth forceps

3- Full crown lower molar forceps: -

Since the lower molar teeth have two roots, one mesial and one distal root so the buccal and lingual blades of the forceps designed with projected tapered tip to fit the bifurcation of these teeth on the buccal and lingual sides, so the buccal and lingual blades are identical so the same forceps can be used on the right and left sides on opposite to that in upper molar teeth.

In addition to that we have two Bayonet forceps for lower 3rd molars; one for left side

and the other for right side.

Mechanical principles of extraction:-

The removal of teeth from the alveolar process employs the use of the following mechanical principles:-

I- Expansion of the bony socket:-

This is achieved by using the tooth itself as a dilating instrument, and this is the most important factor in forceps extraction, and this principle need:-

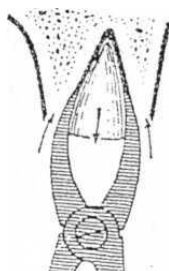
- 1- Sufficient tooth substance be present to be firmly grasped by the forceps.
- 2- The root pattern of the tooth in such that it is possible to dilate the socket to permit the complete dislocation of the tooth from its socket, e.g. dilacerated, divergent, converge roots.
- 3- Nature of the bone, elastic bone especially in young patients is maximal and decreased with age, older patients usually have denser, more highly calcified bone that is less likely to provide adequate expansion during extraction of the teeth.
- 4- Thickness of the bone. Thick bone expansion is less likely to occur by using normal force.

II- The use of a lever and fulcrum

This is used to force a tooth or root out of the socket along the path of least resistance and the principle is the basic factor governing the use of elevators to extract teeth or roots

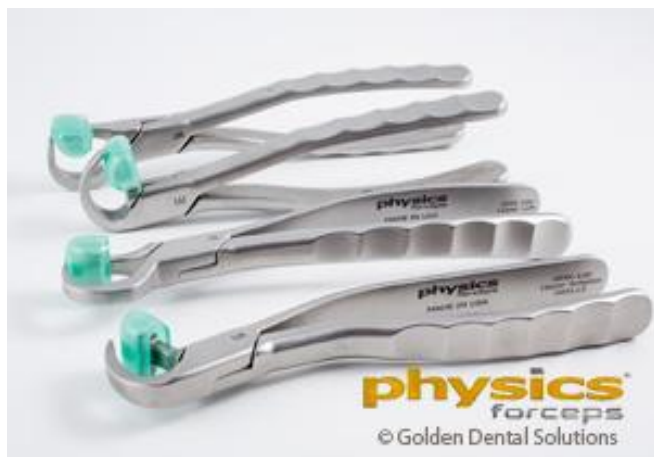III-The insertion of a wedge or wedges:-

Between the tooth-root and the bony socket wall, thus causing the tooth to rise in its socket and this explains why some conically rooted mandibular premolar and molars sometimes shoot out of their socket when forceps blades are applied to it.

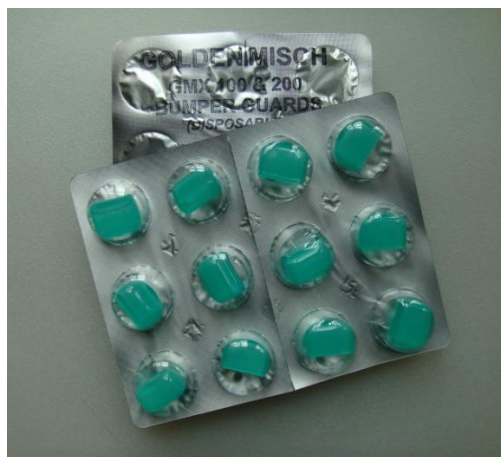

Physics forceps:

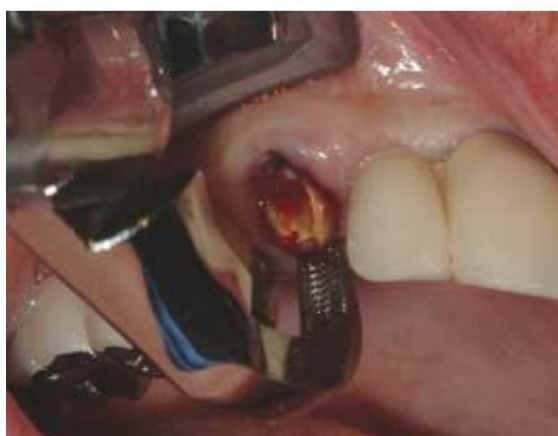The Physics Forceps uses first-class lever mechanics. One handle of the device is connected to a “bumper,” which acts as a fulcrum during the extraction and stabilizes the beak during wrist movements. The beak of the extractor is positioned most often on the lingual or palatal root of the tooth and into the gingival sulcus



Standard Physics forceps set.



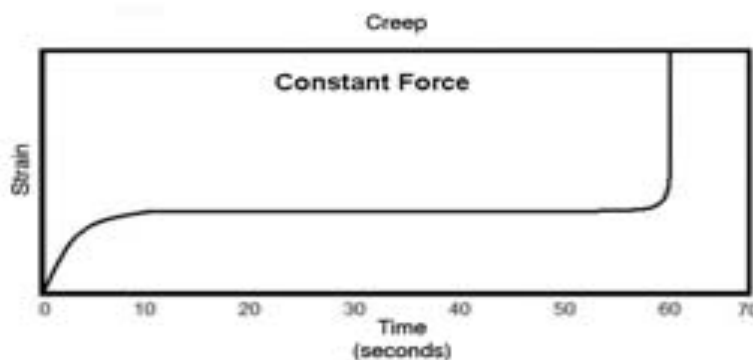
Bumper guards



The bumper is most often placed on the facial aspect of the dental alveolus, typically at the mucogingival junction. Unlike conventional forceps, only one point of contact is made on the tooth being extracted. No squeezing pressure is applied to the handles or to the tooth. Instead, the handles (once in position) are rotated as one unit for a few degrees, and then the action is stopped for approximately 1 minute. The torque force generated on the tooth, periodontal ligament, and bone is related to the length of the handle to the bumper (8 cm), divided by the distance from the bumper to the forceps beak (1 cm). As a result, a force on the handle connected to the bumper will increase the force on the tooth, periodontal ligament, and bone by 8 times. No force is required to be placed on the beak, which is only on the lingual aspect of the tooth root. Therefore, the tooth does not split, crush or fracture.

Moment of force in physics represents the magnitude of force applied to a rotational system at a distance from the axis of rotation. The principle of moment is derived from Archimedes' operating principles of the lever and is defined as $M=rF$, where "F" is the applied force and "r" is the distance from the applied force to the object. This is referred to as the moment arm. The length of the moment arm (or lever arm) is the key to the operation of the lever, pulley, and most other simple machines capable of generating mechanical advantage. This means that if the force applied to generate work cannot be increased, it is still possible to gain a greater amount of work by increasing the moment arm of the lever.

"Creep" is a phenomenon whereby a material continues to change shape over time under a constant load. In a tooth extraction, creep may occur in bone and the periodontal ligament. Reilly established the creep curve of bone, whereby under a constant load of 60 Mpa, the bone over time changes shape (strain) in 3 different stages



A creep curve demonstrates that a constant force applied to bone or a periodontal ligament results in initial changes in shape, with a prolonged period (horizontal line) necessary before the material fractures or releases (the vertical aspect of the line on the right at 60 seconds).

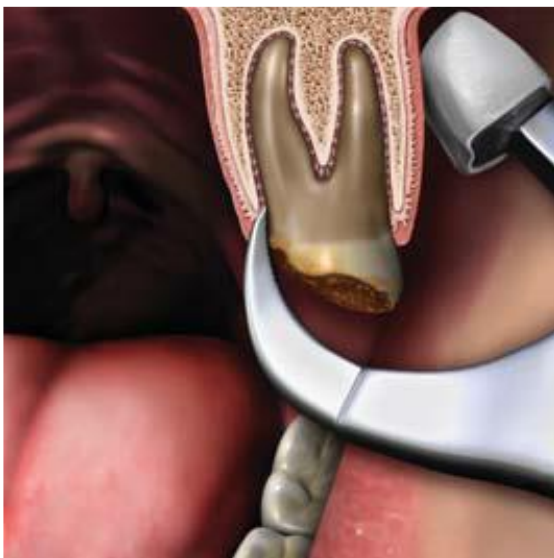The majority of bone changes occur within the first minute, whereby the strain of bone (the change of length divided by the original length) is modified. The higher the force that is applied, the greater the deformation of the bone. This process allows the tooth socket to expand and permits the tooth to exit the socket.

A secondary creep action occurs over time and allows the bone to further deform when the force is applied during a 1- to 5-minute period. The longer the time, the greater the

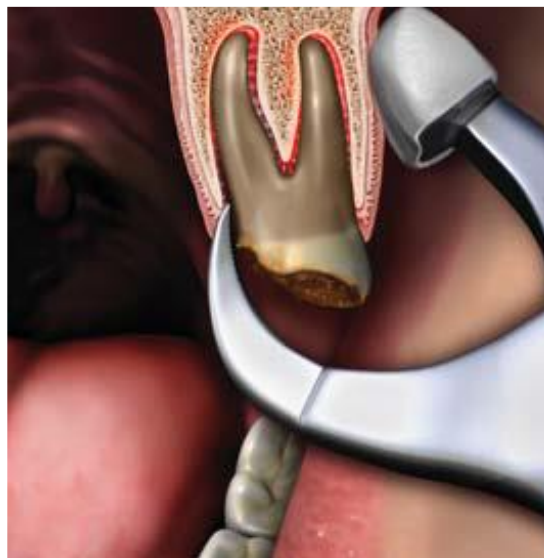deformation; however, it expresses only a 10% to 20% difference compared to the initial one-minute strain. Eventually, the third phase of the curve causes the bone to fracture if the load is applied over a long time frame, representing creep rupture. A similar phenomenon occurs in the periodontal complex.

Mechanical forces shift lateral force to a tooth, causing primary movement to the periodontal ligament and space. A greater force overtime causes a slight additional tooth movement. Therefore, the creep of the periodontal complex is similar to the creep of the bone, whereby the constant load weakens the periodontal ligament. Thus, a constant load on the tooth over time increases the tooth socket dimension and decreases the strength of the periodontal complex.

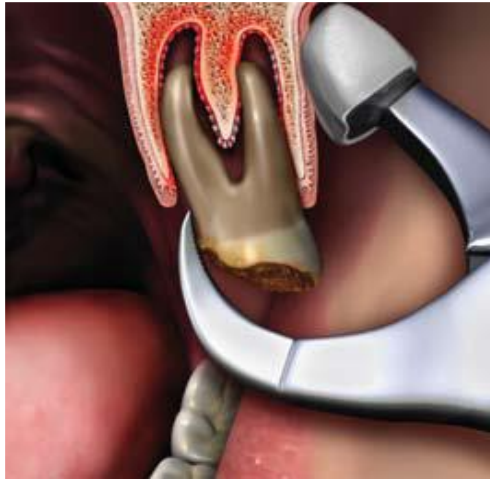Once creep has expanded and weakened the periodontal ligament and bone, the handle of the extraction device may be slowly rotated another few degrees for 10 to 30 seconds. This action contributes to the creep rupture of the ligament and usually elevates the tooth a few millimeters from the socket. At this point the tooth is loose and ready to be removed from the socket using any pincer-like device, i.e, pickups, extraction forceps, or hemostats.



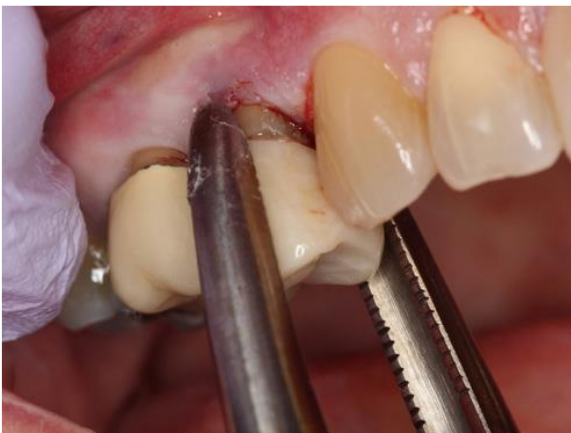The Physics Forceps is in position, and constant pressure is applied.



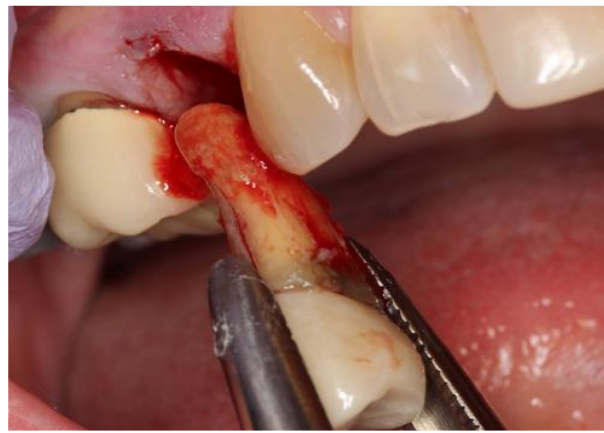Creep is expanding the bone and rupturing the periodontal ligament.



The tooth is rotated slightly and elevated from the socket.



The tooth was delivered from the socket with a pincer-type instrument as the Physics Forceps are not designed to remove the tooth all the way from the socket but simply to elevate the tooth or release the periodontal ligaments.



The tooth was easily removed from the socket.

The extraction of a tooth using the Physics Forceps is similar to the removal of a nail from wood using a hammer versus a pair of pliers (Figures below). The handle of the hammer is a lever, and the beaks of the hammer's claw fit under the head of a nail. The hammer's head acts as a fulcrum. A rotational force applied to the hammer handle magnifies the force by the length of the handle, and the nail is elevated from the wood. Unlike a nail in wood with parallel sides and friction along its full length, a tooth is tapered. After being elevated a few millimeters, the periodontal ligament fibers are broken and the tooth may then be easily removed without additional rotational force. This is important to note, since further rotational force on the tooth may fracture the

facial plate of bone.



A “traditional” dental forceps removes a tooth similar to how a pair of pliers removes a nail.

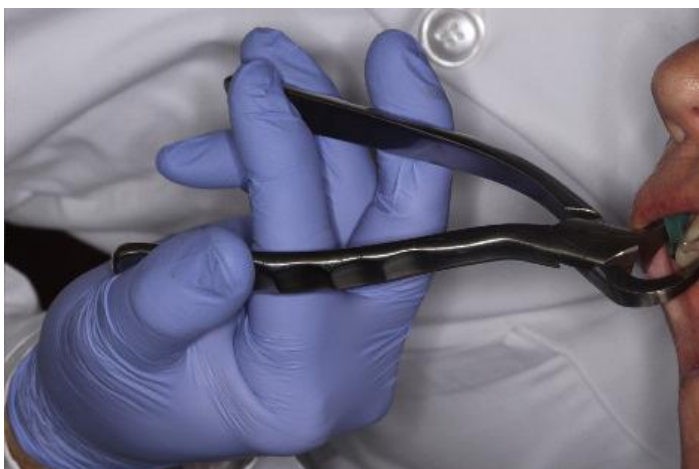

A claw hammer uses class I lever mechanics, with the handle one lever, the head of the hammer as the fulcrum, and the claw as the short lever applied to the nail. The Physics Forceps uses a similar action to remove a tooth.

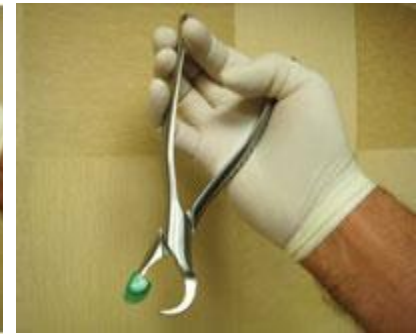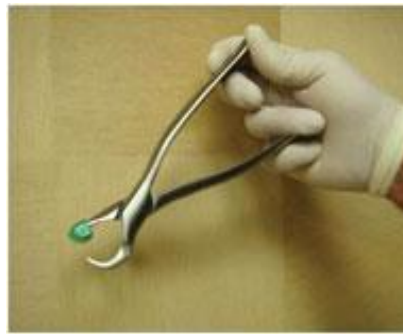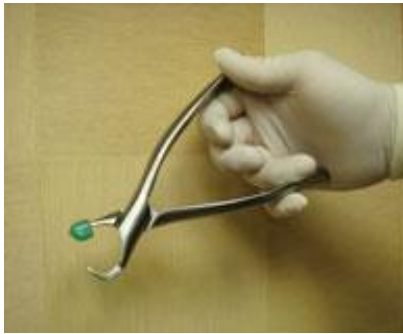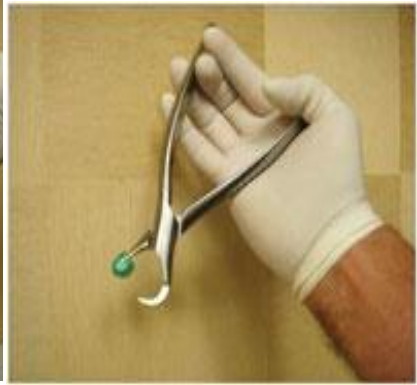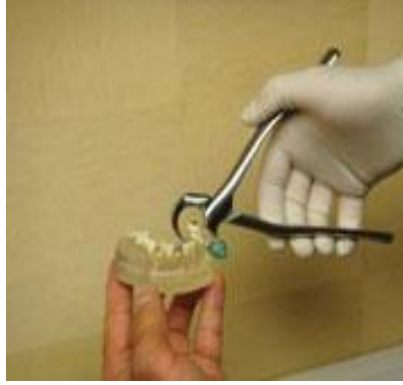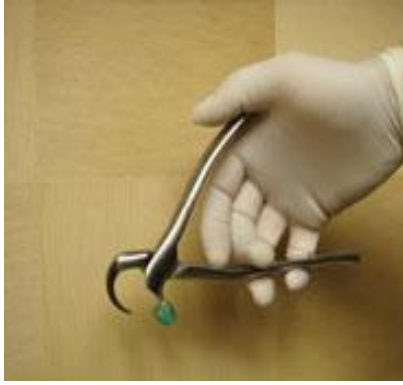Stress is the internal distribution of force per unit area that balances and reacts to external loads applied to a body. Stress can be broken down into its shear, tensile, and compressive components. Materials in general are weakest to shear forces and strongest to compressive loads. For example, bone is strongest to force in compression, 30% weaker to tension, and 65% weaker to shear forces (*Reilly DT., 1975*). When a rotating force is applied to the Physics forceps on a tooth, the stress to the tooth and the periodontal complex is a shear component of force. The force applied to the gums and bone by the bumper of the Physics Forceps is over a greater surface area and is a compressive force, thus bracing the buccal bone. This permits the lingual plate to expand more and protects the facial plate from fracture.

The instrument is uniquely designed to allow tension to be placed on the periodontal ligament and to achieve excellent leverage. This tension results in the physiologic release of an enzyme by the body that breaks down the periodontal ligament over a short period of time which is called hyaluronidase (hyaluronate

glycanohydrolase). This is an enzyme that catalyzes the hydrolysis of the interstitial barrier, hyaluronan (hyaluronic acid), which is the cement substance (extracellular matrix) of all human tissues (*KUMAR DM., 2015*). This process may take 20 seconds or up to 4 minutes depending on the tooth and surrounding bone structure of the patient. The clinician must be patient, as the technique will feel like nothing is happening since none of the usual operator movements are employed. With the breakdown of the periodontal ligament, the tooth will release or “pop” out of the socket in an upward and outward motion, mirroring the arch form of the head of the instrument. This innovative instrument allows tooth dislodgment with little or no pressure, simply utilizing leverage. The handles are never squeezed like a conventional forceps; rather they are held lightly in the hand, and the wrist is rotated to simply create tension on the palatal aspect of the root. There is no forearm, bicep, or shoulder pressure used. The handles simply allow the beak to engage the root structure without slipping off. During a short time of constant tension, the root will disengage or pop from the socket incisally and facially. Although the facial bone may expand slightly, the movement of the tooth out of the socket is not straight facial, but rather up and out of the socket. This allows for maintenance of the facial plate of bone, when the instrument is used correctly. One of the biggest misconceptions of this innovative technique is that it is a “forceps” as the names implies, when in fact it is a lingual elevator (*Kosinski T, Golden R., 2015*).



Atraumatic extraction with the Physics Forceps (Golden Dental Solutions). Using the proper hand position and hold are a must when utilizing the Physics Forceps technique.



Oral surgery

Technique of forceps extraction

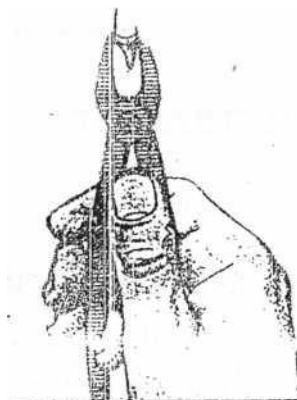
Regardless of the tooth to be extracted in the oral cavity, some common principles are applied to all dental extraction. The general steps in the closed-extraction (forceps extraction) procedure are: -

1- Soft tissue retraction: -

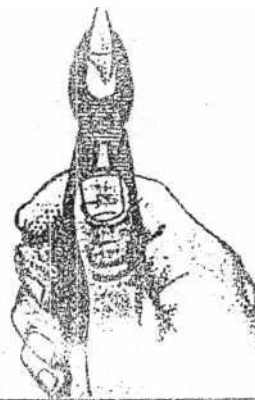Before starting the application of the dental forceps, the gingival tissue surrounding the tooth should be reflected with blunt probe or tweezers, the neck of the tooth freed labially and lingually as far as the bony alveolar margin, so that no laceration or tearing of the gingival occur on extraction. So, care should be exercised to avoid application of the beaks over the gingival tissue. Reflection of the gingival tissue allows the surgeon to ensure that profound anesthesia is secured before starting extraction. Also, gingival retraction allows the beaks of forceps to be positioned more apically without interference or impingement of the gingival tissue.

2- Handling of the forceps: -

The forceps should be grasped by the palm of the right hand and the thumb finger is placed below the joint. The little finger is placed inside the two handles of the forceps so that it can control the opening and closure of the handle and guide the forceps beaks on the root surface, and when the tooth is grasped the little finger is placed outside the handle.



Handling of dental forceps while closing and grasping the tooth

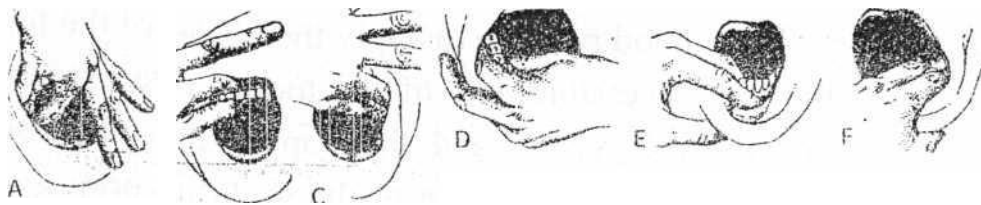


Handling of dental forceps while opening

3- Retraction and support (the use of the left hand):

When using the forceps and elevators to luxate and remove teeth. It's important that the surgeon's opposite hand play an active role in the procedure. For the right-handed operator (dentist), the left hand has a variety of functions:

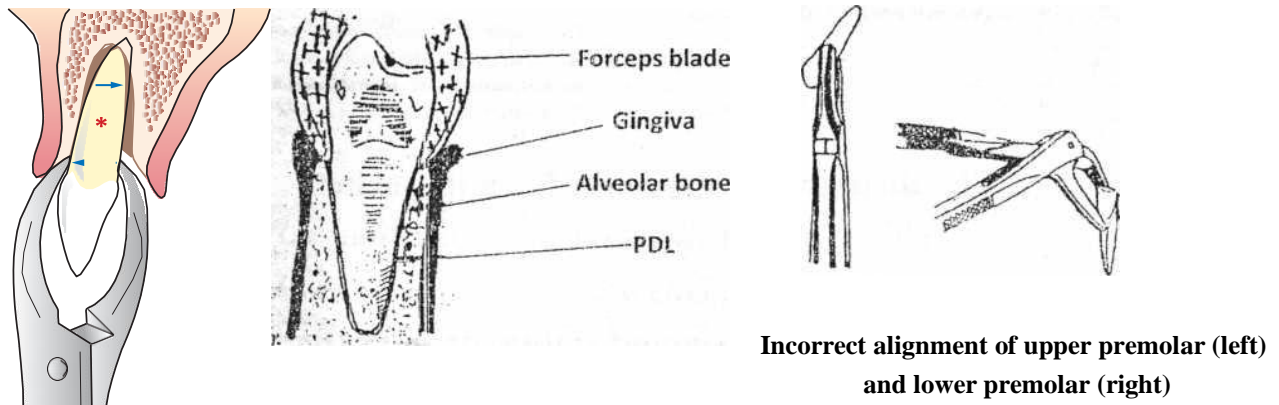
- a) It's used to reflect the soft tissues of the cheeks, lips and tongue to provide adequate visualization of the area of surgery.
- b) It helps to provide protection for the soft tissue structures and protect other teeth from forceps, if they release suddenly from the tooth socket.
- c) It helps to stabilize the patient's head during extraction process.
- d) The opposite hand plays an important role in supporting and stabilizing the lower jaw when mandibular teeth are being extracted to prevent injury and post-operative pain in the tempromandibular joint (T.M.J). And also, to prevent dislocation of the mandible during extraction especially when extraction is performed under general anesthesia
- e) The opposite hand supports the alveolar process and provide tactile information to the operator concerning the expansion of the alveolar process during luxation process.



Correct use of left hand during extraction of: A, Right maxillary premolars, B, Maxillary anterior teeth. C, Left maxillary premolars and molars. D, Right mandibular cheek teeth (N.B. The operator stands behind the patient when extracting these teeth) E, Mandibular anterior teeth. F. Left mandibular molars and premolars

4- The application of forceps blades to the tooth (tooth grasp):-

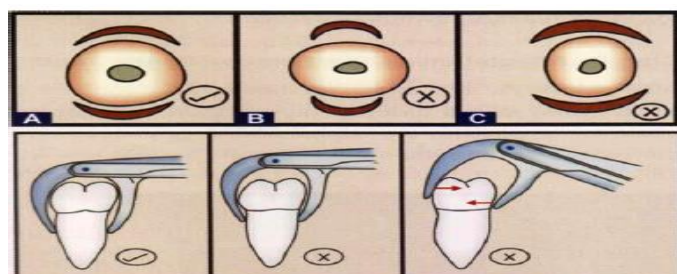
After you select the proper forceps for the extraction of particular tooth. The forceps blades are applied on both labial (buccal) and lingual (palatal) surface of the tooth, so that the blades are parallel to the long axis of the tooth to be extracted



The blades of the forceps are moved on the tooth surface apically and are allowed to move apically cutting through periodontal and gingival fibres to grasp the tooth-root surface below the cemento-enamel junction. The tooth to be extracted is grasped firmly, the blades are not allowed to slide on the surface of the root during extraction movement.

It's a good practice to apply the blades of the forceps to the less accessible side of the tooth to be extracted first under direct vision and then apply the other blade on opposite side. If one side of the tooth is carious, then the forceps blades applied to the carious side first and extraction movement should be started toward the carious side.

The surface of the beaks of the forceps should lie as close as possible to the surface of the tooth grasped tightly without slipping during extraction



5- The displacement of the tooth from its socket: -

This is performed by using the extraction movements.

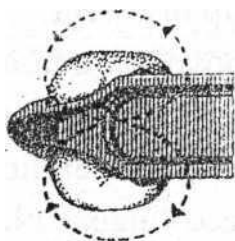
The extraction movements are: -

- a- Outward movement (labial or buccal)
- b- Inward movement (lingual or palatal)
- c- Rotatory movement (rotation movement).

The purpose of extraction movements is:

- 1-Cutting the tooth attachment.
- 2- Separating the tooth from the wall of the socket.
- 3- Dilatation of the bony wall of the socket utilizing the resiliency of the living bone.
- 4- The removal of the tooth from the socket.

When the blades applied to the root surface a firm grip of the root taken by the forceps and buccolingual and lingobuccal movements are made in that order. This pressure should be firm but not crushing, smooth and controlled not jerking. By this movements normally after few lateral movements the tooth is felt to be loosen and begin to rise out of the socket, when this loosening occurs, rotatory or figure 8 movement will help to delivery of the tooth



. Occlusal view of mandibular molar illustrating the figure 8 of movement

Rotatory movement:

Can be used as primary movement for extraction of teeth with conical straight roots such as the upper central incisors and lower second premolars, also rotatory movements are useful in completing the removal of teeth previously loosened by other means and this is called secondary rotatory movement.

The gross distortion and laceration of the buccal plate and mucosa are happened if excessive lateral movement is done. The final movement by which the tooth is removed from its socket should be always directed outwards, so reducing the trauma

to the opposing teeth and preventing slipping of the tooth in the mouth which may be swallowed or aspirated by the patient.

If the tooth does not yield (no movement) after applying a reasonable force, excessive force should not be used, stop and re-evaluate the case clinically and/or radiographically because the tooth may need surgical extraction.

Post-operative care of extraction wound: -

1- Examine the extracted tooth to be sure that there is no fracture in the roots (retained root), keeping in mind the anatomical variations in number of roots of each tooth, because some teeth have accessory roots.

2- Always examine the socket for any loose fragments of bone or roots (pieces of enamel), foreign materials (e.g. calculus, amalgam particles, or pathology (e.g. periapical granuloma, polyp) all these should be removed by using curette or suction tip or tweezers.

3- You have to remove or smooth any sharp bone or projections of inter-radicular bone, then apply suture if necessary, e.g. if there is laceration in the soft tissue.

4- The expanded bucco-lingual plate should be compressed or squeezed back to their original configuration or shape in order to reduce any distortion of the supporting tissue to re-establish the normal contour before extraction

5- Make sure that the socket is full of blood, (to form blood clot)

6- Place a properly shaped and size (2X2 Cm) gauze piece over the socket (and never put it into socket) in such a way that the patient closes his mouth and it is not visible to gain initial control of haemorrhage. It is important to place the gauze directly over the extraction site in the space occupied by the crown of the extracted tooth and not over the occlusal table of teeth to ensure that the pressure is correctly transmitted over the socket to achieve haemostasis.

Instructions to the patient:

1- Keep biting over the gauze for at least (0.5-1) hours and discharge after that but if haemostasis is not established, you can use another.

2- Do not spit during first $1/2$ hour and use minimal talking and avoid violent exercise or activity to assist the formation of a firm clot in the socket, so rest for the first few hours following extraction are recommended ,avoid insertion of the tongue tip inside the socket which lead to dislodgement of clot or disturb its formation

3- use only cold fluid and soft diet for the few postoperative hours and not take solid or hard food for the rest of the day, and chew on the opposite side of extraction.

4- in case of continuous bleeding. Place a sterile gauze in place over the wound and keep it in place for an hour, if bleeding not stopped contact your dentist.

5- always prescribe the proper analgesic and antibiotic if necessary (e.g. The presence of residual infection, diabetic patient, patient on immune-suppressive drugs, aids...etc.