

Lec [1]/The scalp

The scalp consists of five layers, the first three of which are bound together and move as a unit. To assist one in memorizing the names of the five layers of the scalp, use each letter of the word **SCALP** to represent the layer of the scalp.

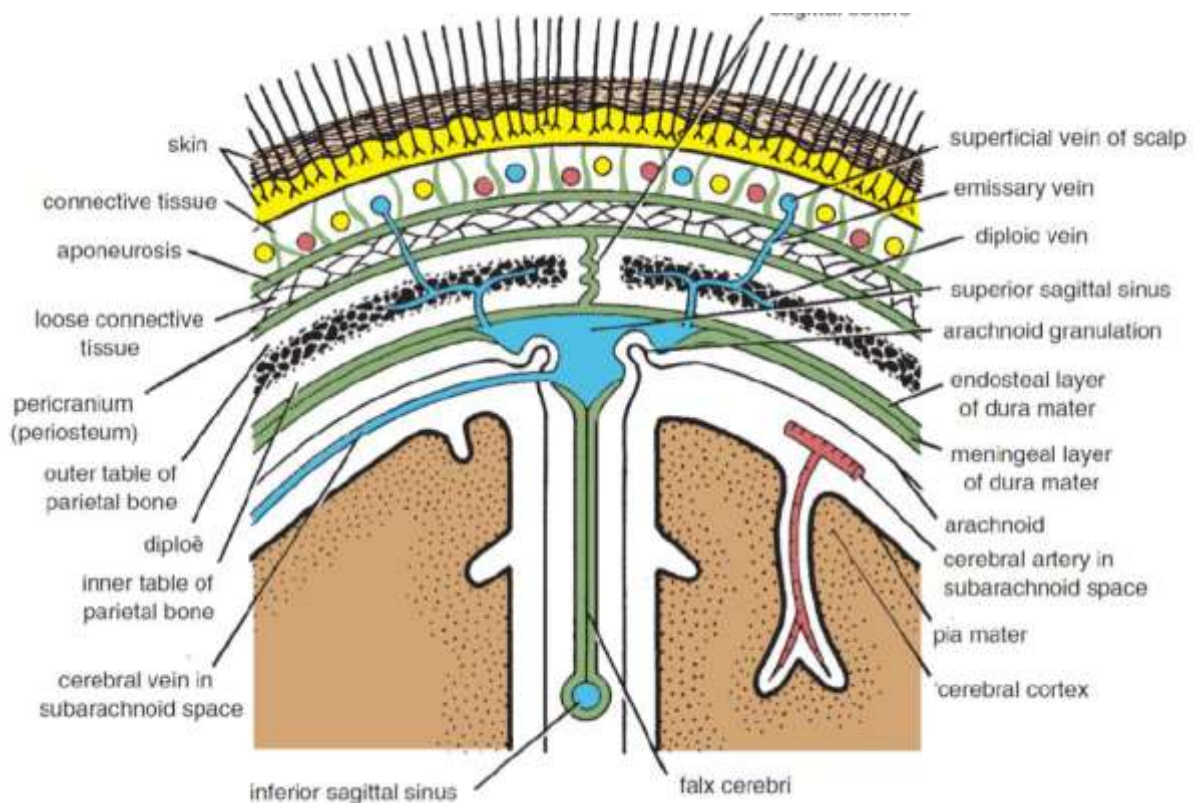
Skin; **C**onnective tissue; **A**poneurosis; **L**oose areolar tissue; and **P**ericranium.

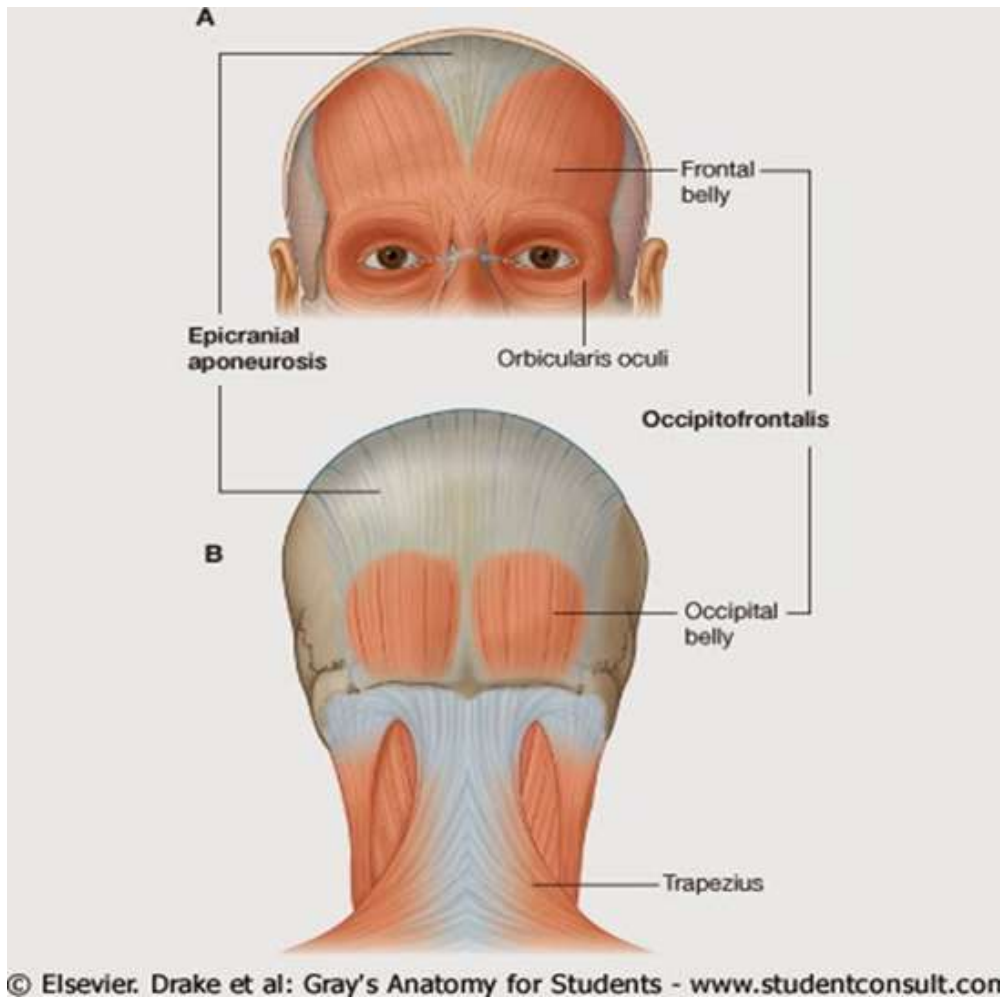
S/Skin:

1. thick , 2.hair bearing , 3.contains numerous sebaceous glands.

C/Connective tissue (subcutaneous tissue): which is 1.Fibrofatty tissue. 2.the fibrous septa uniting the skin to the underlying aponeurosis of the occipitofrontalis muscle. 3.Numerous arteries and veins are found in this layer. 4.The arteries are branches of the external and internal carotid arteries, and a free anastomosis takes place between them.

A/Aponeurosis (epicranial): which is 1.Thin 2. tendinous sheet 3.unites the occipital and frontal bellies of the occipitofrontalis muscle. 4.The lateral margins of the aponeurosis are attached to the temporal fascia. 5.It is limited in front and behind by the origins of the occipitofrontalis muscle, and it extends laterally as far as the attachment of the aponeurosis to the temporal fascia.





Muscles of the Scalp

Muscle	Origin	Insertion	Nerve Supply	Action
Muscle of Scalp				
Occipitofrontalis				
Occipital belly	Highest nuchal line of occipital bone	Epicranial aponeurosis	Facial nerve	Moves scalp on skull and raises eyebrows
Frontal belly	Skin and superficial fascia of eyebrows			

Occipitofrontalis:

when this muscle contracts, the first three layers of the scalp move forward or backward, the loose areolar tissue of the fourth layer of the scalp allowing the aponeurosis to move on the pericranium. The frontal bellies of the occipitofrontalis can raise the eyebrows in expressions of surprise or horror.

Nerve supply. By the facial nerve; the posterior auricular branch to occipitalis, and temporal branches to frontalis.

L/Loose areolar tissue (loose connective tissue) : which

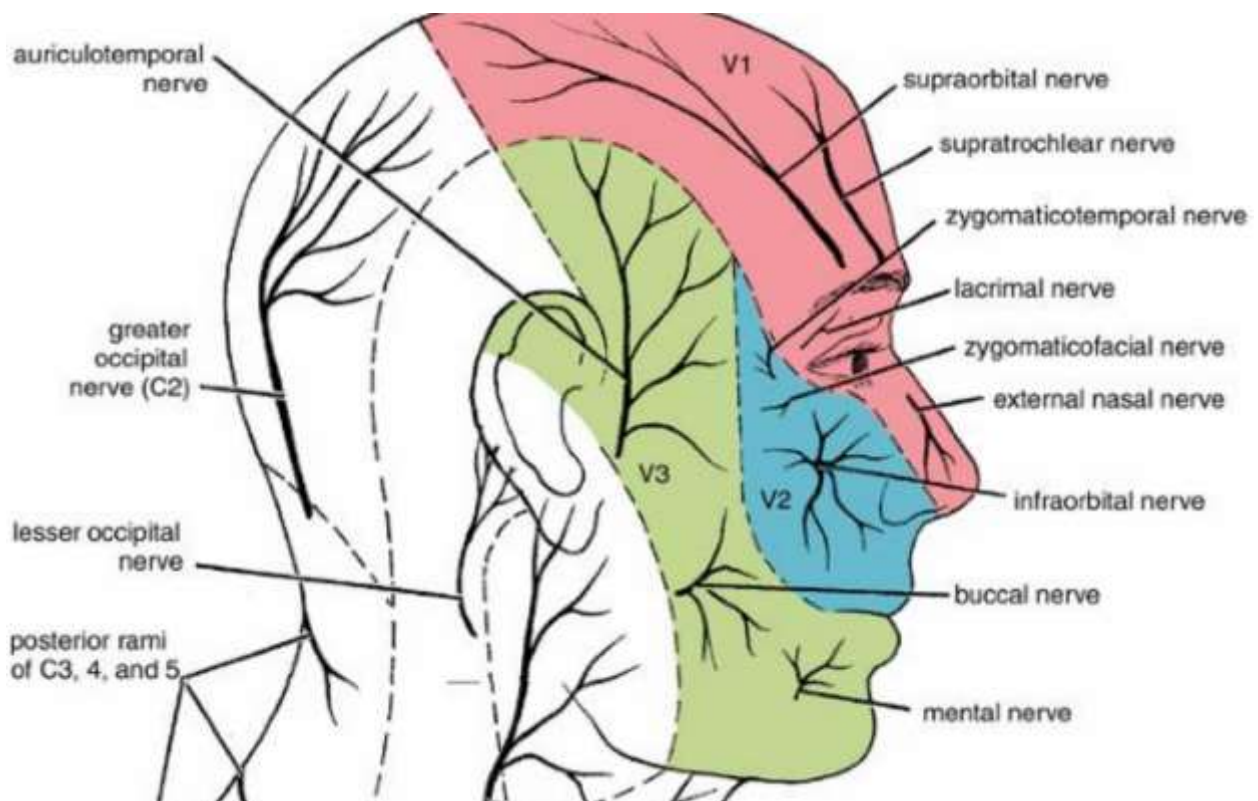
1. occupies the subaponeurotic space
2. loosely connects the epicranial aponeurosis to the periosteum of the skull (the pericranium).
3. It contains a few small arteries
4. it also contains some important emissary veins. The emissary veins are valveless and connect the superficial veins of the scalp with the diploic veins of the skull bones and with the intracranial venous sinuses.

P/Pericranium: which is

1. covering the outer surface of the skull bones.
2. at the sutures between individual skull bones, the periosteum on the outer surface of the bones becomes continuous with the periosteum on the inner surface of the skull bones

Sensory nerve supply of the scalp:

The main trunks of the sensory nerves lie in the superficial fascia. Moving laterally from the midline anteriorly, the following nerves are present:

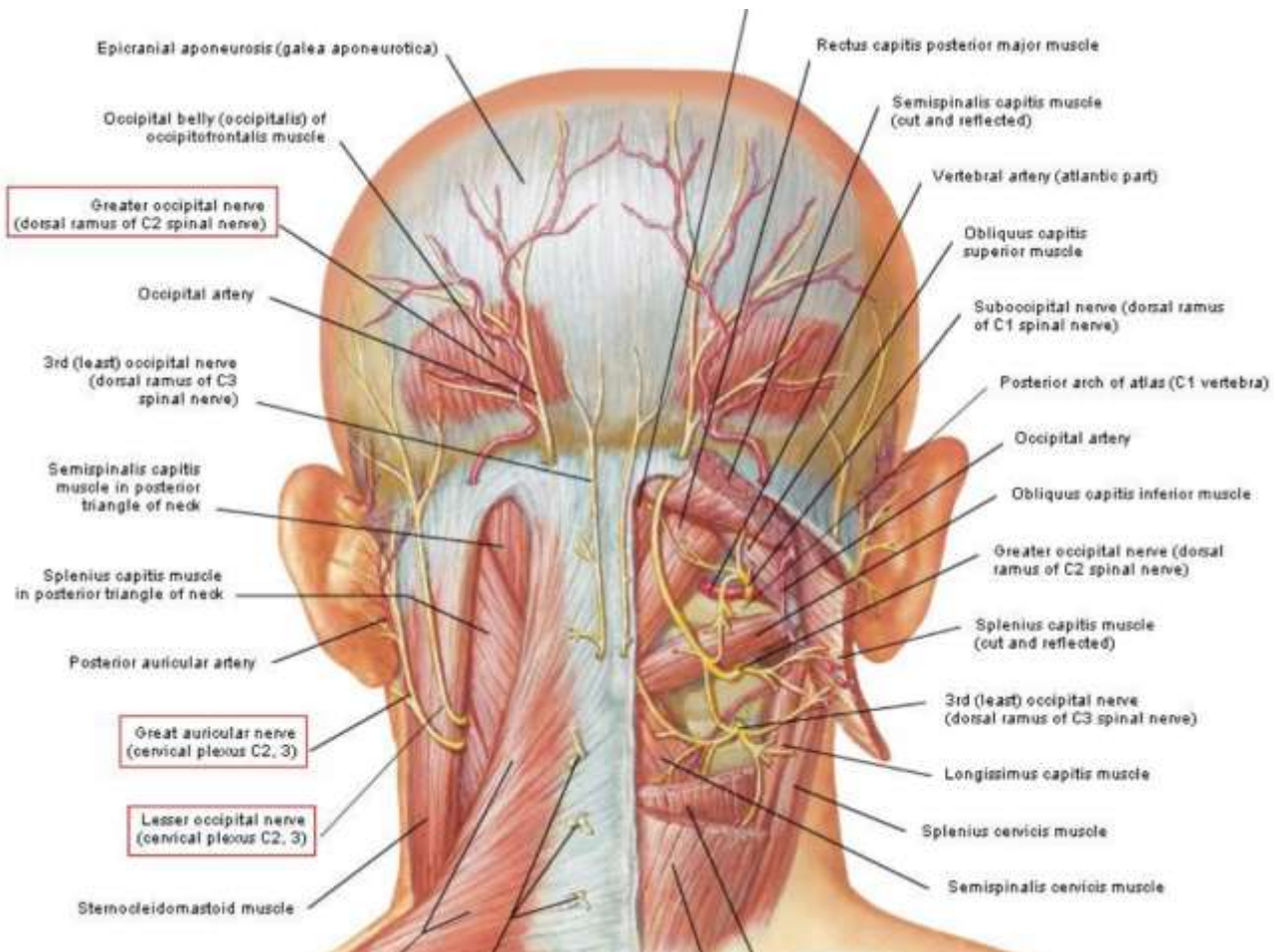


1/The supratrochlear nerve, branch of the ophthalmic division of the trigeminal nerve, winds around the superior orbital margin and supplies the scalp. It passes backward close to the median plane and reaches nearly as far as the vertex of the skull.

2/The supraorbital nerve, a branch of the ophthalmic division of the trigeminal nerve, winds around the superior orbital margin or passing through supraorbital notch (or foramen) and ascends over the forehead. It supplies the scalp as far backward as the vertex.

3/The zygomaticotemporal nerve, a branch of the maxillary division of the trigeminal nerve, supplies the scalp over the temple [small area] .

4/The auriculotemporal nerve, a branch of the mandibular division of the trigeminal nerve, ascends over the side of the head from in front of the auricle. Its terminal branches supply the skin over the temporal region.



5/The lesser occipital nerve, a branch of the cervical plexus(C2), supplies the scalp over the lateral part of the occipital region and the skin over the medial surface of the auricle.

6/The greater occipital nerve, a branch of the posterior ramus of the 2nd cervical nerve, ascends over the back of the scalp and supplies the skin as far forward as the vertex of the skull.

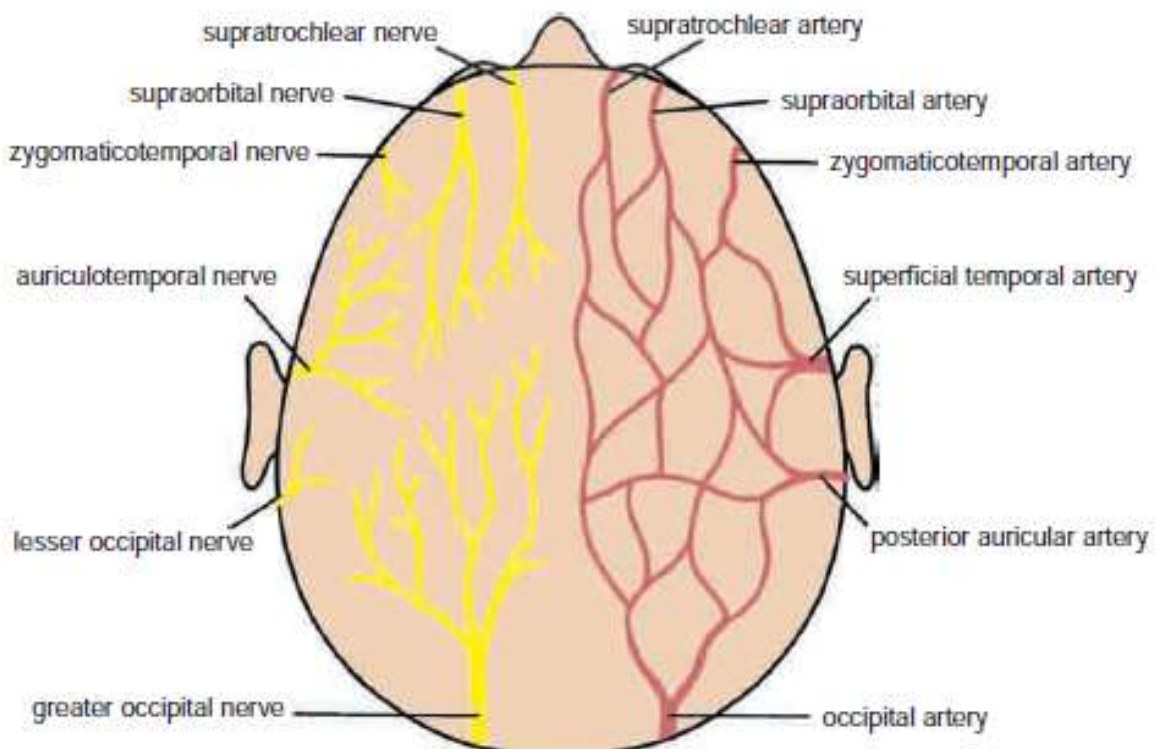
7/The third occipital nerve, a branch of the posterior ramus of the 3rd cervical nerve, ascends over the back of the neck close to the midline and its terminal branches supplies the small posterior area of the middle part of the scalp.

Arterial supply of the scalp:

The scalp has a rich supply of blood to nourish the hair follicles. These arteries are branches from external carotid artery (**occipital, posterior auricular and superficial temporal**), and from internal carotid artery (**zygomaticotemporal, supraorbital and supratrochlear**) branches of ophthalmic artery]. All these arteries anastomose very freely with each other

The arteries lie in the superficial fascia (connective tissue layer).

1/The **occipital artery** emerges from the apex of the posterior triangle and runs with the **greater occipital** nerve to supply the back of the scalp up to the vertex.



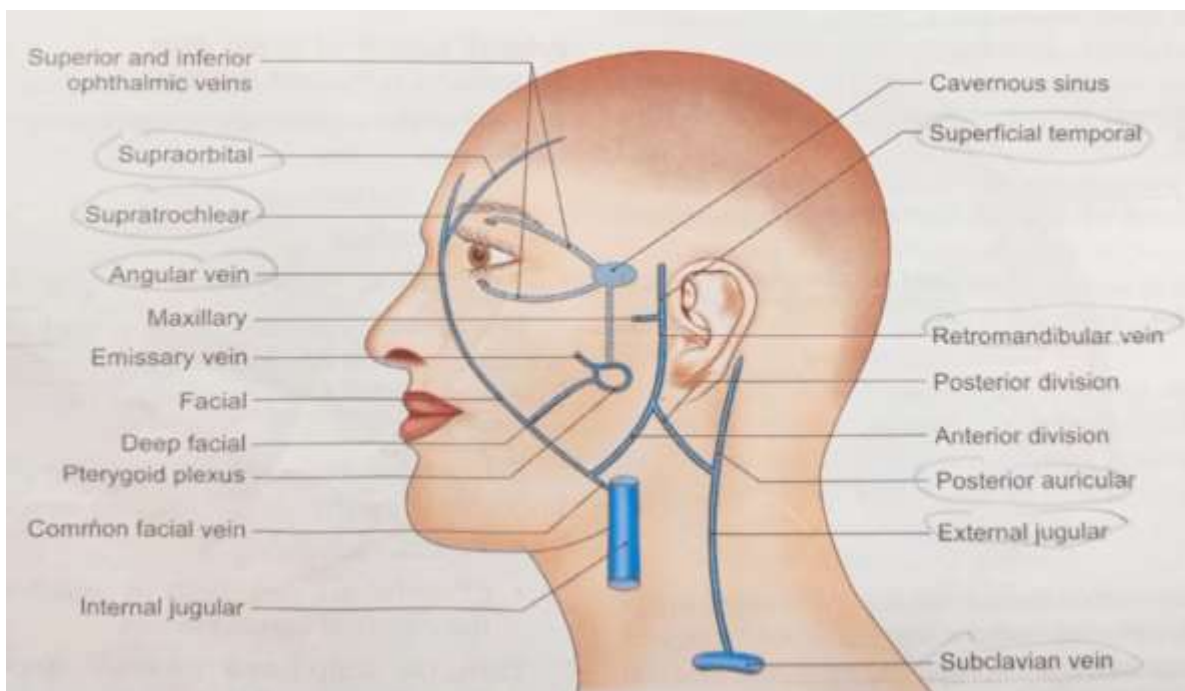
2/ The smaller **posterior auricular artery** runs with the **lesser occipital** nerve to supply the scalp above and behind the ear.

3/The **superficial temporal artery** is a terminal branch of the external carotid. Running up behind the temporomandibular joint and in front of the ear in accompany with **auriculo-temporal** nerve, it crosses the zygomatic arch, where its pulsation can be felt, and branches out widely into the skin that overlies the temporal fossa.

4/The **zygomaticotemporal, supraorbital** and **supratrochlear arteries** (from the ophthalmic) run with the corresponding nerves. The supraorbital is the larger and supplies the front of the scalp up to the vertex. Its anastomosis with the superficial temporal artery connects the internal and external carotid systems.

Venous drainage of the scalp:

The veins of the scalp run back with the arteries. The veins of the scalp freely anastomose with one another and are connected to the **diploic veins of the skull bones** and the **intracranial venous sinuses** by the valveless **emissary veins**.



1- The **supraorbital** and **supratrochlear** veins drain by the **angular vein** into the **facial vein**.

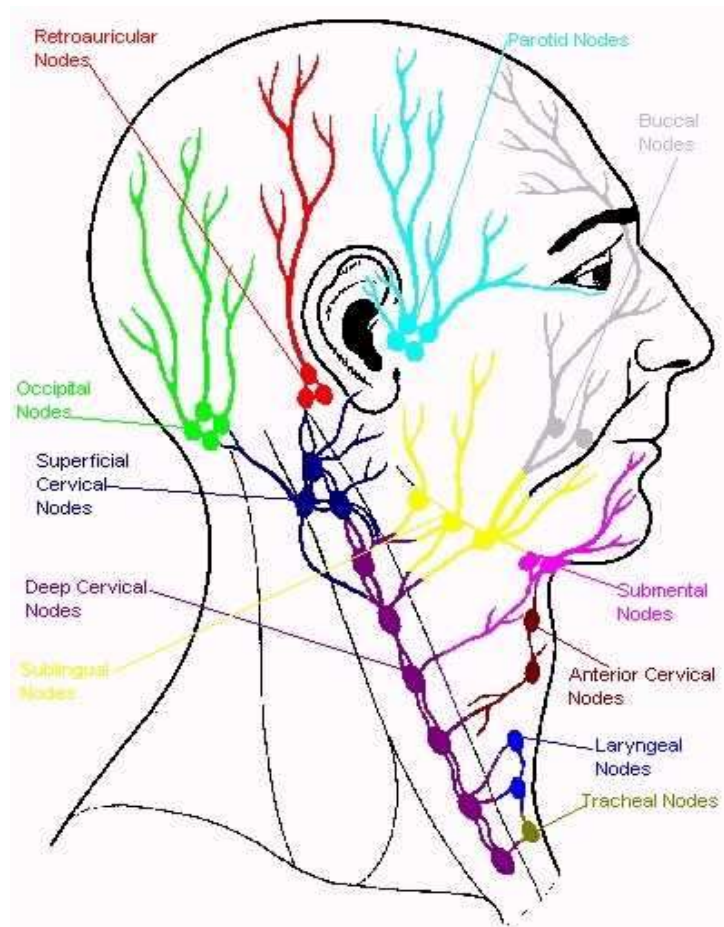
2- The **superficial temporal veins** unites with the **maxillary vein** in the substance of the parotid gland to form **the retromandibular vein**. Just below the parotid gland, retromandibular vein divided into anterior and posterior divisions.

3-The **posterior auricular vein** unites with the **posterior division** of the **retromandibular vein**, just below the parotid gland, to form the **external jugular vein**.

4-The **occipital vein** drains into the **suboccipital venous plexus**, which lies beneath the floor of the upper part of the posterior triangle; the plexus in turn drains into the **vertebral veins** or the **internal jugular vein**.

Lymph Drainage of the Scalp:

- 1- Lymph vessels in the anterior part of the scalp and forehead drain into the **submandibular lymph nodes**.
- 2- Drainage from the lateral part of the scalp above the ear is into the **superficial parotid (preauricular) nodes**.



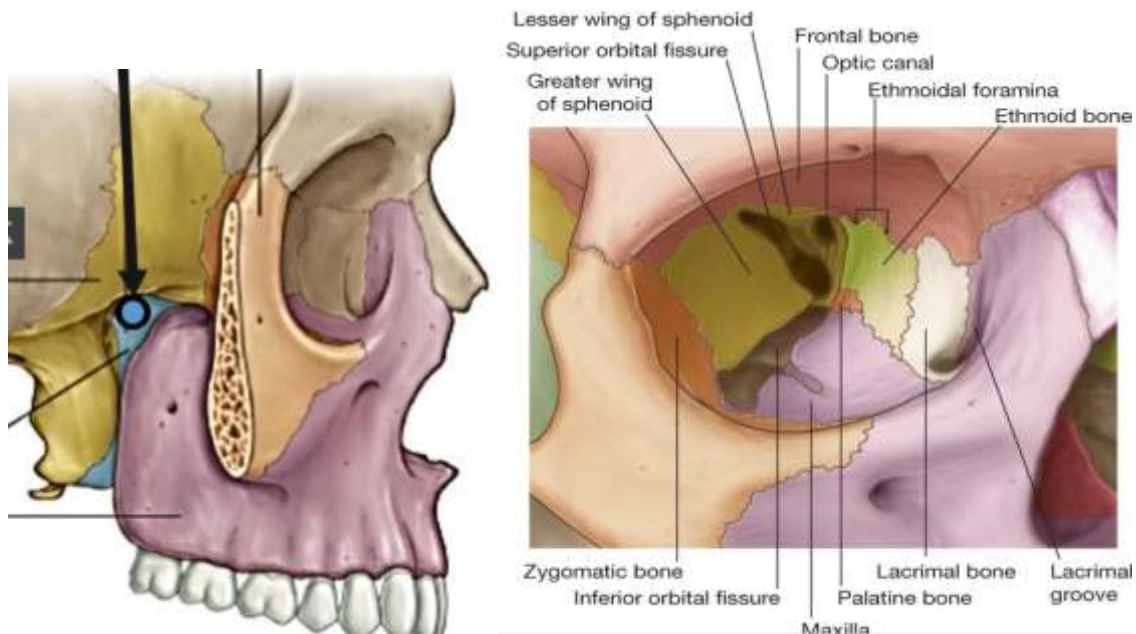
- 3- lymph vessels in the part of the scalp above and behind the ear drain into the **mastoid nodes**.
- 4- Vessels in the back of the scalp drain into the **occipital nodes**.

Clinical Significance of the Scalp Structure:

- 1- The skin of the scalp possesses numerous sebaceous glands, the ducts of which are prone to infection and damage by combs. For this reason, sebaceous cysts of the scalp are common.
- 2- Lacerations of the Scalp: Even a small laceration of the scalp can cause severe blood loss, because the arterial walls are attached to fibrous septa in the subcutaneous tissue and are unable to contract or retract to allow blood clotting to take place. Local pressure applied to the scalp is the only satisfactory method of stopping the bleeding .
- 3- Scalp Infections: Infections of the scalp tend to remain localized and are usually painful because of the abundant fibrous tissue in the subcutaneous layer. Occasionally, an infection of the scalp spreads by the emissary veins, which are valveless, to the skull bones, causing osteomyelitis. Infected blood in the diploic veins may travel by the emissary veins farther into the venous sinuses and produce venous sinus thrombosis.
- 4- Blood or pus may collect in the potential space beneath the epicranial aponeurosis. It tends to spread over the skull, being limited in front by the orbital margin, behind by the nuchal lines, and laterally by the temporal lines.
- 5- On the other hand, subperiosteal blood or pus is limited to one bone because of the attachment of the periosteum to the sutural ligaments.

Lec [6] Pterygopalatine fossa:

The pterygopalatine fossa is a small pyramidal space **inferior** to the **apex of the orbit** and **medial** to the **infratemporal fossa**, it is located between the **maxilla, sphenoid and palatine bones**, and communicates with other regions of the skull and facial skeleton via several **canals and foramina**.



Boundaries:

Anterior: Posterior wall of the maxilla.

Posterior: Pterygoid process below and greater wing of the sphenoid bone above.

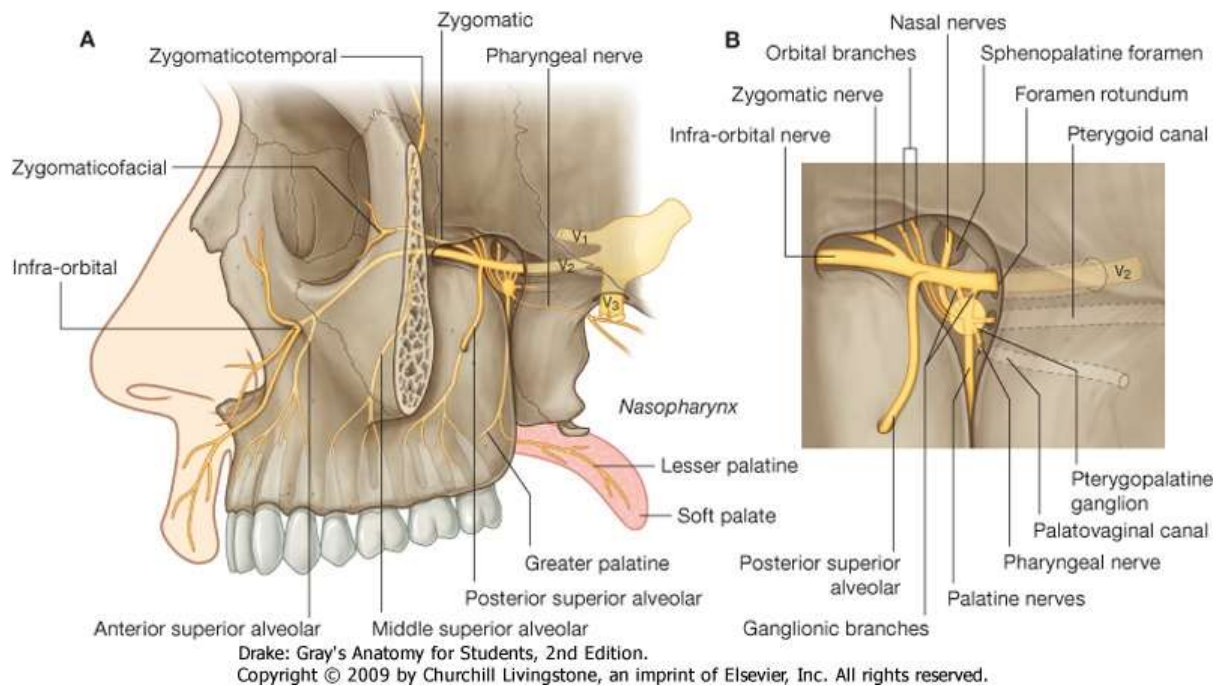
Superior: greater wing of sphenoid bone.

Inferior: the pyramidal process of the palatine bone. it articulates with the lateral pterygoid plate and maxilla and forming the narrow floor of the pterygopalatine fossa.

Medial: Perpendicular plate of the palatine bone

Lateral: Pterygomaxillary fissure

Contents: maxillary nerve and its branches, pterygopalatine ganglion and 3rd part of maxillary artery and accompanying veins.



Maxillary nerve:

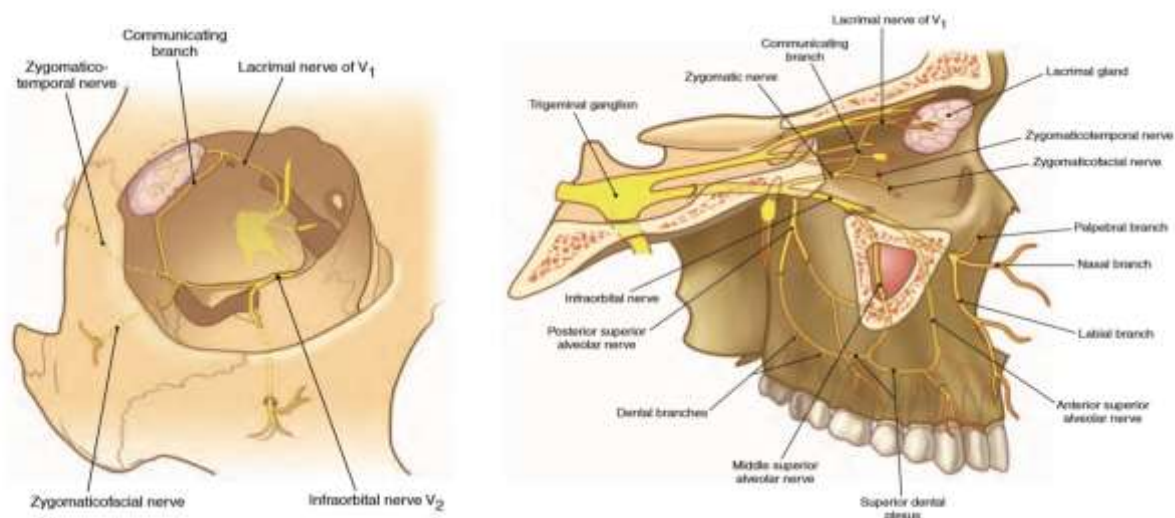
The second division of trigeminal nerve contains only sensory fibers. Functionally, it supplies the **maxillary teeth and their supporting structures**, the **hard and soft palate**, the **maxillary air sinus**, much of the **nasal cavity** and **skin overlying the middle part of the face**.

The maxillary nerve arises from the **trigeminal ganglion** in the **middle cranial fossa**. It passes forward in the **lateral wall of the cavernous sinus** and leaves the skull through the **foramen rotundum** and crosses the **upper part of pterygopalatine fossa** to enter the **orbit** through the **inferior orbital fissure**. It then continues as the **infraorbital nerve** in the **infraorbital groove, infraorbital canal** and it emerges on the face through the **infraorbital foramen**.

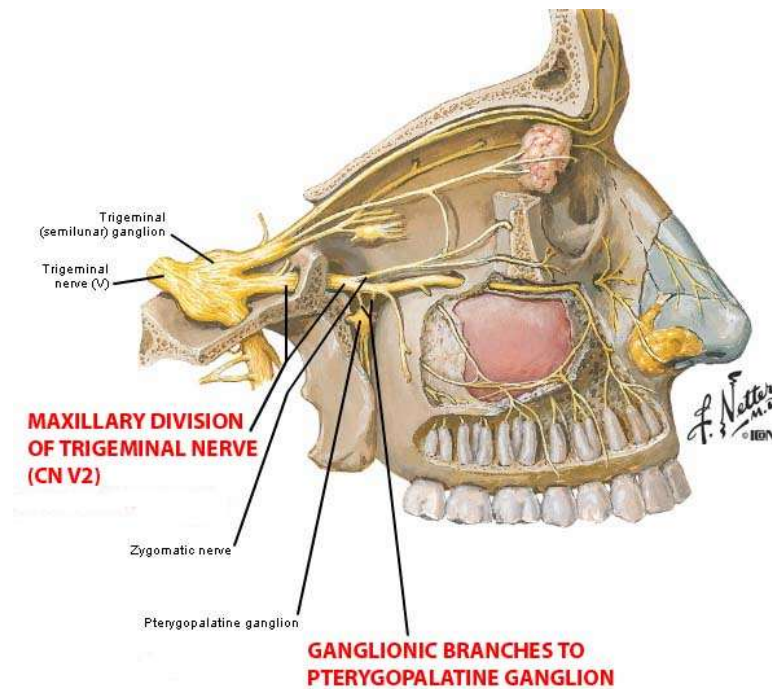
Direct branches of maxillary nerve(branches from the main maxillary nerve trunk):

1. **meningeal branch** [dural branch or middle meningeal nerve] to the middle cranial fossa, it arises within **middle cranial fossa**, runs with **middle meningeal artery**.

2. **Ganglionic branches**, which are two short nerves that connect **maxillary nerve** to the **pterygopalatine ganglion**.
3. **Zygomatic nerve** arises from the maxillary nerve in the **fossa** and runs through the **inferior orbital fissure** to enter the orbit along the **lateral wall**, then divides into the **zygomaticotemporal** and the **zygomaticofacial** nerves that supply the skin of the face. The **zygomaticotemporal** branch gives **autonomic fibers [communicating branch]** to the **lacrimal gland** via the **lacrimal nerve**.



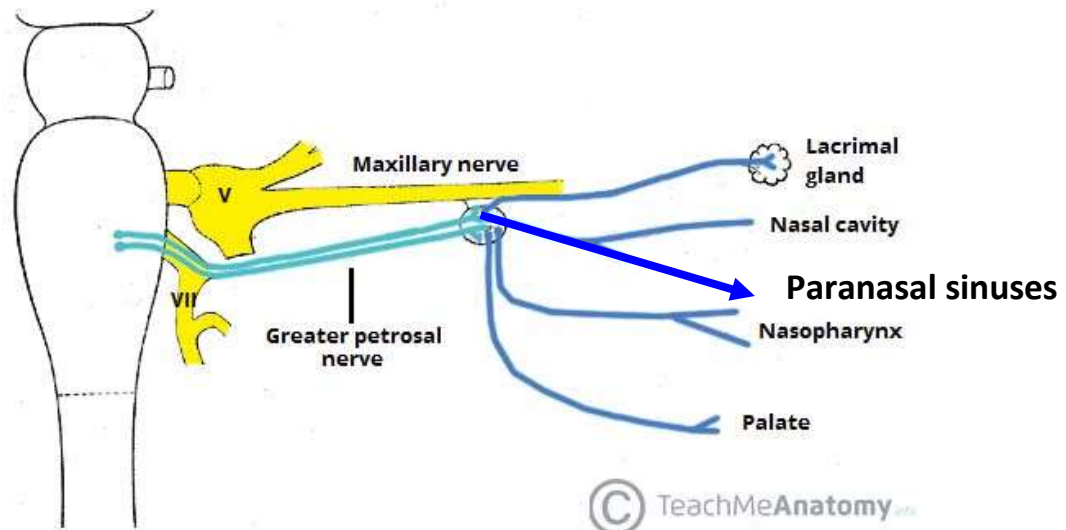
4. **Posterior superior alveolar nerve** is also given off in the fossa. It passes through the pterygomaxillary fissure on to the posterior wall of the maxilla (maxillary tuberosity), which supplies the maxillary sinus as well as the upper molar teeth and adjoining parts of the buccal gum.
5. **Infraorbital nerve** this can be regarded as terminal branch of maxillary nerve passing through inferior orbital fissure to become in the floor of the orbit running in the infraorbital groove and give here the middle superior alveolar nerve, and anterior superior alveolar in the infraorbital canal.



Pterygopalatine Ganglion

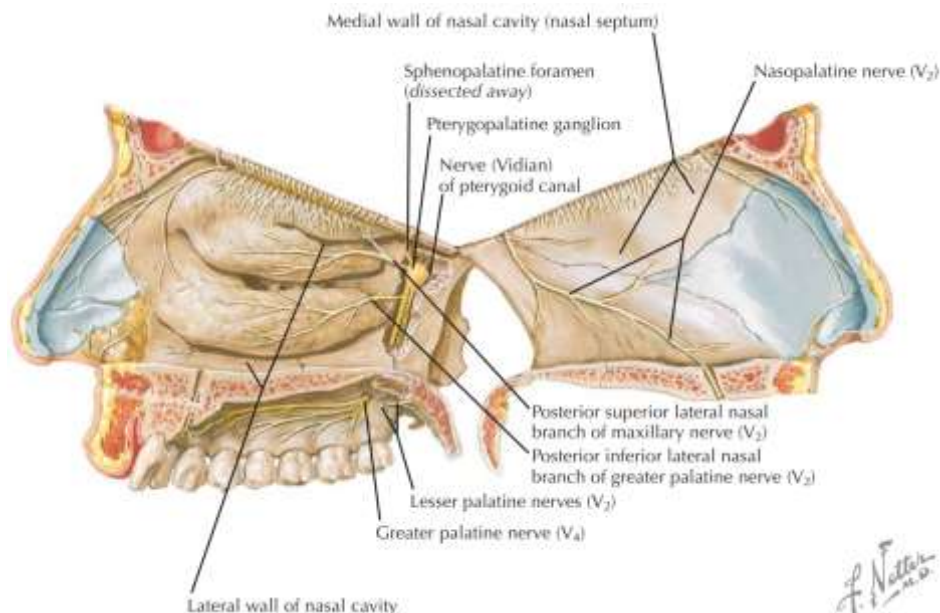
It is the **largest parasympathetic ganglion**. The ganglion lies immediately in front of the opening of the pterygoid canal and the nerve of that canal [Vidian nerve] runs straight into the back of the ganglion. This nerve is formed in the foramen lacerum by union of the **greater petrosal nerve**, containing mainly **parasympathetic secretomotor fibers**, [with **few taste fibers**] and the **deep petrosal nerve**. The former is a branch of the **facial nerve** and the latter is a branch from the **internal carotid sympathetic plexus**. The combined nerve passes forward in the **pterygoid canal** and joins the **ganglion**.

Postganglionic parasympathetic fibers leave the ganglion and distribute with branches of the maxillary nerve. These fibers are **secretomotor** in function, and provide **parasympathetic innervation** to the **1/lacrimal gland, and mucosal glands of the 2/palate, 3/nose 4 / paranasal sinuses and 5/nasopharynx**.



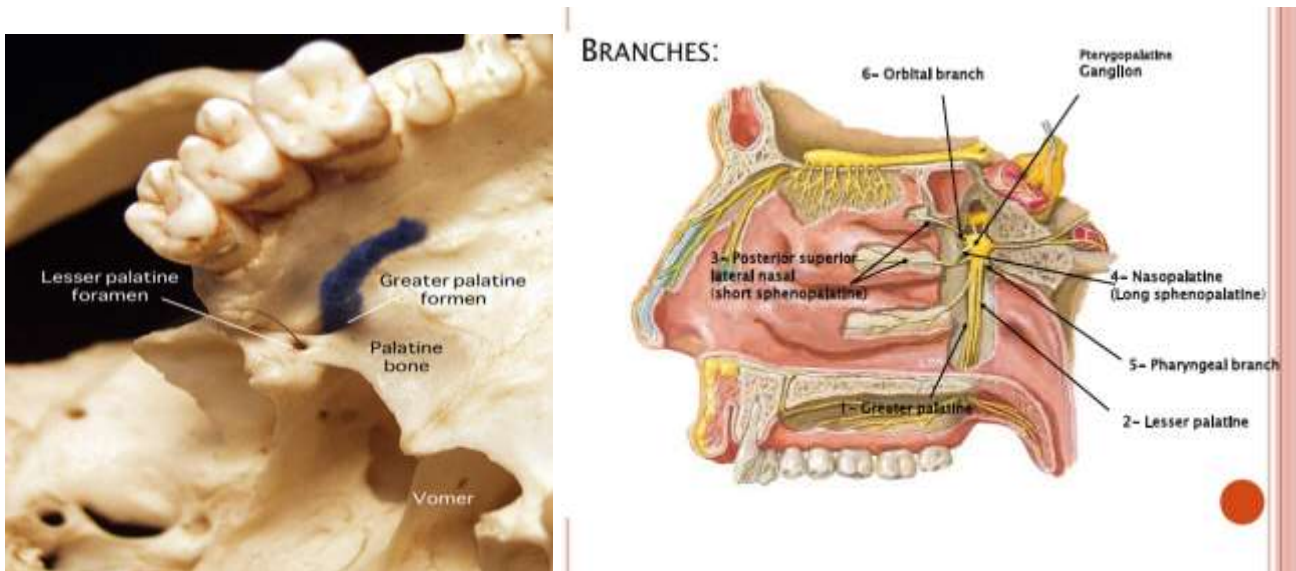
The fibers in the connections between the maxillary nerve and the ganglion are sensory and, like the sympathetic fibers in the deep petrosal nerve, they pass through the ganglion without relay. Every branch carries a mixture of all **three kinds of fibers: sensory, secretomotor and sympathetic.**

Indirect branches of maxillary nerve: which are distributed through the branches of pterygopalatine ganglion.



1/ posterior superior medial nasal nerves pass through the **sphenopalatine foramen**, cross the **roof of the nose**, and are distributed to the posterosuperior part of nasal **septum**. The largest of these is termed the **nasopalatine nerve** [long

sphenopalatine], where it travels anteroinferior to the incisive canal, supplying the septum and passes through the incisive canal to supply the gingiva and mucosa of the hard palate from central incisor to canine.



2/The posterior superior lateral nasal nerves [short sphenopalatine] pass through the **sphenopalatine foramen** and turn forward to supply the posterosuperior part of the lateral wall of the nose.

3/The greater palatine nerve passes down through the greater palatine canal. At the greater palatine foramen, it turns forward to supply the mucous membrane of the hard palate. As it descends it also supplies **the posteroinferior** part of the lateral wall of the nose and the **medial wall of the maxillary sinus** through its branch the **Posterior inferior lateral nasal**.

4/The lesser palatine nerves, two in number, pass down behind the greater palatine nerve and emerge through the **lesser palatine foramen**. They pass back to the **soft palate** and the **mucous membrane of the palatine tonsil**. They carry the only special sensory fibers transmitted in the **greater petrosal nerve**; these are **sensory (taste) fibers** that have their cell bodies in the **geniculate ganglion** of the **facial nerve**.

5/The pharyngeal nerve passes back through the **palatovaginal canal** and supplies the mucous membrane of the nasopharynx.

6/ Orbital branches enter the orbit via the **inferior orbital fissure** and supply **periosteum** of the orbital floor and the **mucous membrane of the sphenoidal and ethmoidal sinuses**.

Maxillary vessels: The 3rd part of **maxillary artery** passes through the **pterygomaxillary fissure**, enters the **pterygopalatine fossa** and gives off its branches.

Veins accompany the arteries and, passing through the fossa, emerge at the pterygomaxillary fissure to drain into the **pterygoid venous plexus**.

Communication and Openings: There are **seven openings** that connect the pterygopalatine fossa with the **orbit, nasal, oral cavities, middle cranial fossa, nasopharynx** and **infratemporal fossa**. The openings transmit blood vessels and nerves between these regions.

1/Pterygomaxillary Fissure: connects the infratemporal fossa with the pterygopalatine fossa. It transmits the posterior superior alveolar nerve and 3rd part of the maxillary artery.

2/Foramen Rotundum: connects the pterygopalatine fossa to the middle cranial fossa. It conducts a single structure, the maxillary nerve.

3/Pterygoid canal: runs from the middle cranial fossa [anterior wall of foramen lacerum]. It carries the nerve, artery and vein of the pterygoid canal.

4/Pharyngeal Canals [palatovaginal canal]: communicates with the nasopharynx. It carries the pharyngeal branches of the maxillary nerve, artery and vein.

These two canals, with the foramen rotundum, are the three openings in the posterior wall of the pterygopalatine fossa

5/Inferior Orbital Fissure: It is a space between the sphenoid and maxilla bones. communicates with the orbital cavity. It is transmitting the zygomatic branch of the maxillary nerve, the infraorbital nerve, artery and vein, the inferior ophthalmic vein

communicates with pterygoid Venous plexus through this fissure and the orbital branches from pterygoid ganglion.

6/Greater Palatine Canal: lies in the floor of the pterygopalatine fossa, and communicates with the oral cavity. Branching from the greater palatine canal are the lesser palatine canals. The greater palatine canal transmits the descending palatine artery and vein, the greater palatine nerve and the lesser palatine nerve.

7/Sphenopalatine Foramen: It connects the pterygopalatine fossa to the nasal cavity. It is formed by the sphenopalatine notch at the superior aspect of the perpendicular plate of the palatine bone [orbital process anteriorly and sphenoidal process posteriorly] and the body of the sphenoid superiorly.

The sphenopalatine foramen transmits the sphenopalatine artery and vein, as well as the nasopalatine nerve (a large branch of the pterygopalatine ganglion), with other branches mentioned above.

HUMAN ANATOMY

Brain

Lec. 2

Asis.Lec. Noor Ghazi

Nervous System

The nervous system is divided structurally into two main parts: the central nervous system, which consists of the brain and spinal cord, and the peripheral nervous system, which consists of 12 pairs of cranial nerves and 31 pairs of spinal nerves and their associated ganglia.

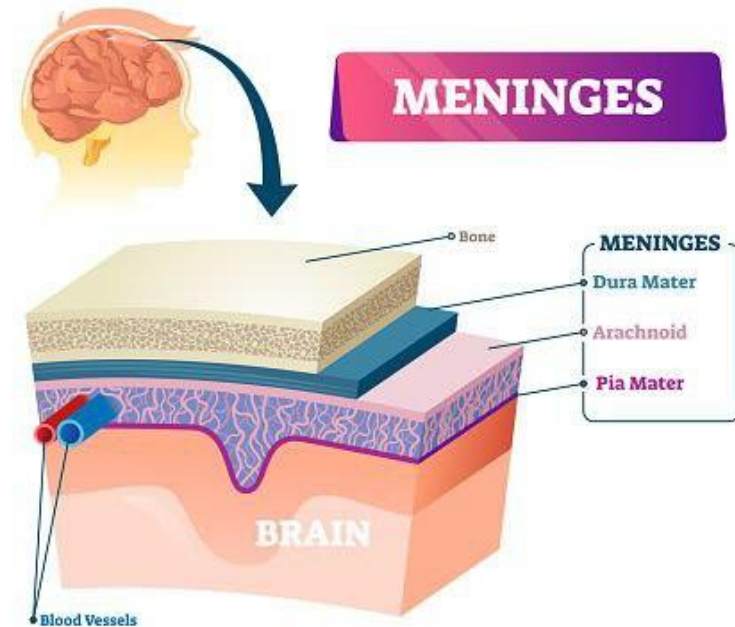
Functionally, the nervous system can be further divided into the somatic nervous system, which controls voluntary activities, and the autonomic nervous system, which controls involuntary activities.

Cranial Meninges

The brain and spinal cord are surrounded by three membranous connective tissue layers called the meninges. The cranial meninges protect the brain, form the supporting framework for blood vessels and venous sinuses, and enclose the subarachnoid space (a fluid-filled cavity), which is vital to the normal function of the brain.

The three layers include the following:

1. Dura mater: tough, thick external fibrous layer that is richly innervated by sensory nerve fibers. The cranial dura is distinguished from the spinal dura by its two layers. The outer endosteal layer is attached to the inner aspect of the cranium (no thing more than periostum); the inner meningeal layer is dura mater proper, its dense, strong, fibrous membrane covering the brain and continuous through foramen magnum with dura of spinal cord.



******The meningeal layer sends inward four septa that divide the cranial cavity into freely communicating spaces lodging the subdivisions of the brain.

The **function** of these septa is to restrict the rotatory displacement of the brain.

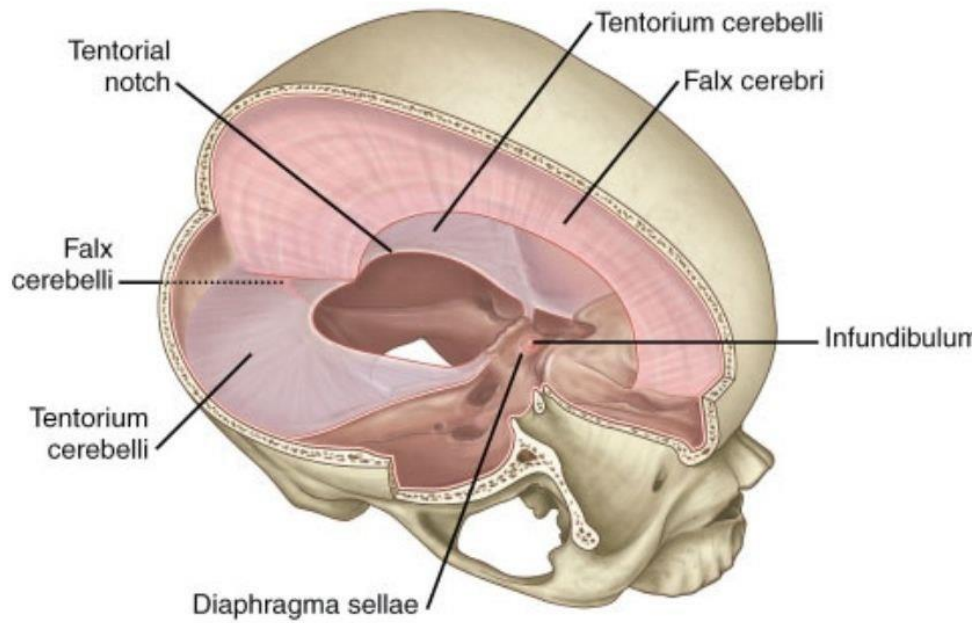
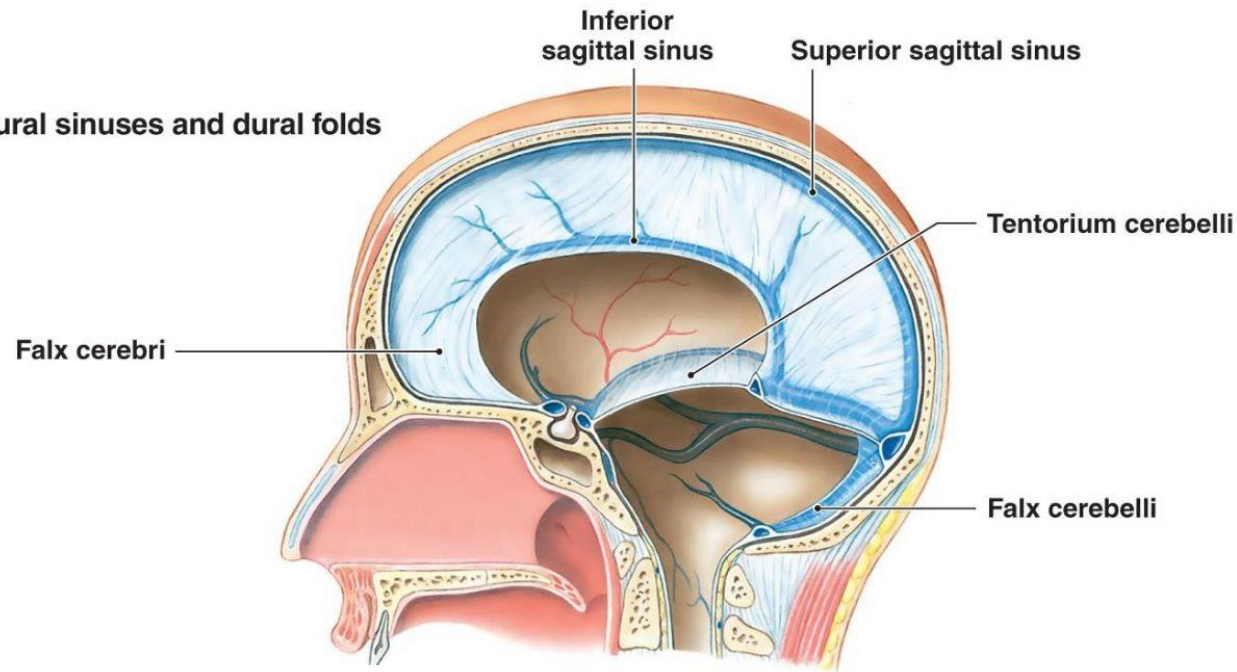
***The falx cerebri:** is a sickle-shaped fold of dura mater that lies in the midline between two cerebral hemispheres. Its narrow end in front is attached to the internal frontal crest and crista galli, while its broad posterior part blends in the midline with the upper surface of the tentorium cerebelli. The **superior sagittal sinus** runs in its upper fixed margin, the **inferior sagittal sinus** runs in its lower concave free margin, and the straight sinus runs along its attachment to the tentorium cerebelli.

***The tentorium cerebelli:** its crescent-shaped fold of dura mater that roofs over the posterior cranial fossa. It covers the upper surface of the cerebellum.

***The falx cerebelli:** is a small, sickle-shaped fold of dura matter that is attached to the internal occipital crest and projects forward between the two cerebellar hemispheres. Its posterior fixed margin contains the occipital sinus.

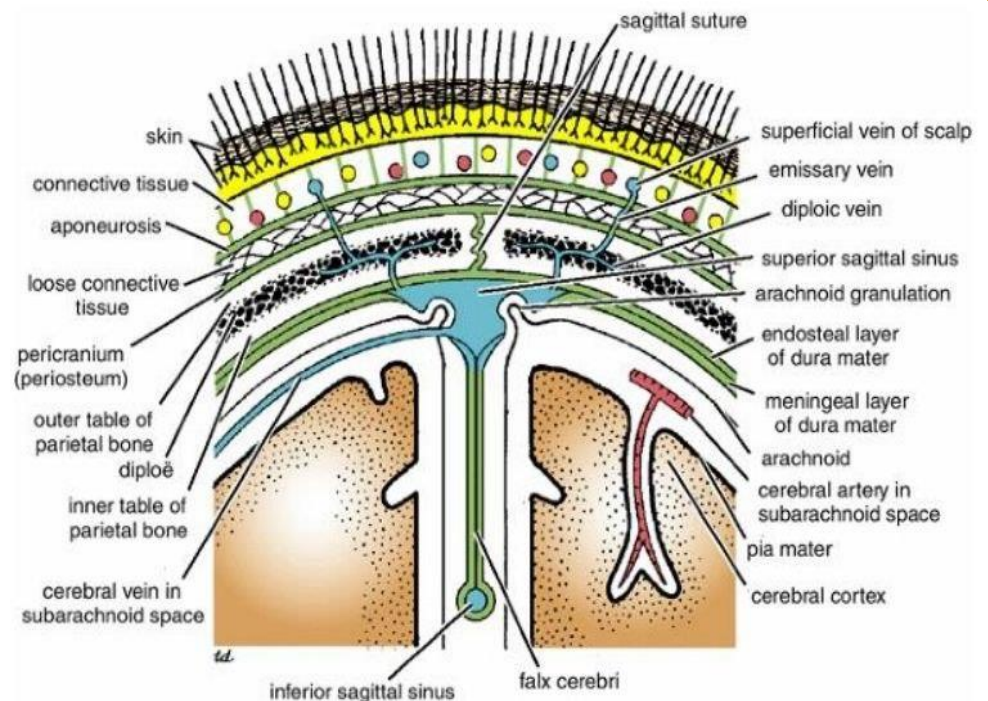
***The diaphragma sellae:** is a small circular fold of dura mater that forms the roof for the sella turcica.

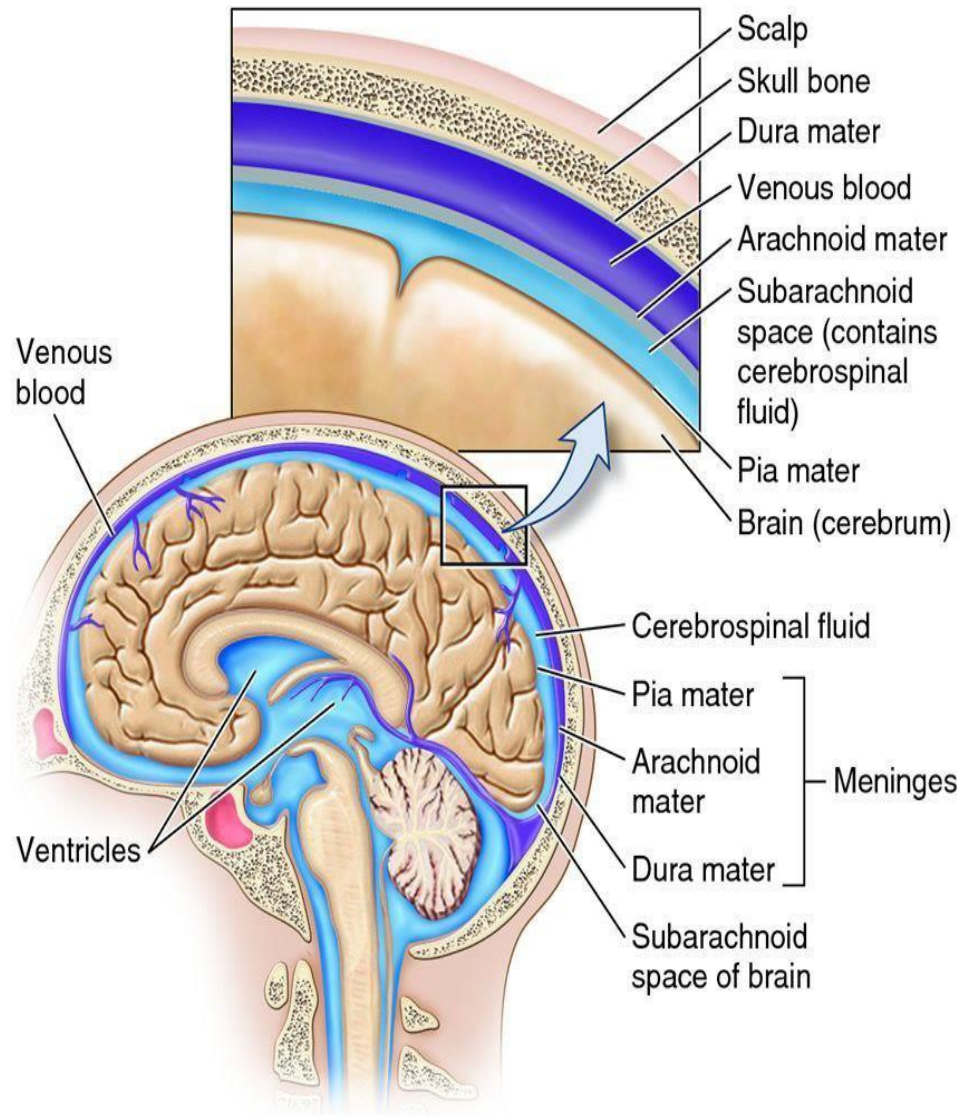
The dural sinuses and dural folds



2. Arachnoid mater: thin, impermeable, intermediate, avascular layer directly beneath the dural surface; it is separated from the dura by a potential space, the subdural space. The space between the arachnoid and the underlying pia is called the subarachnoid space and contains CSF, which bathes and protects the central nervous system.

3. Pia mater: delicate internal vasculated layer of connective tissue that intimately envelops the brain and spinal cord.

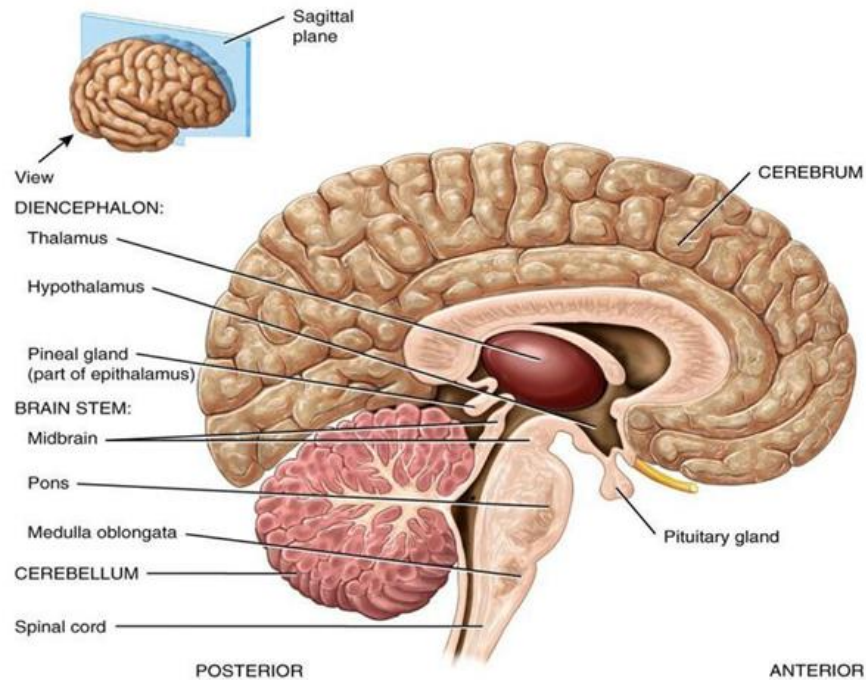




The Brain

The brain is that part of the central nervous system that lies inside the cranial cavity. It is also known as encephalon. It is continuous with the spinal cord through the foramen magnum.

Parts of the Brain



(a) Sagittal section, medial view

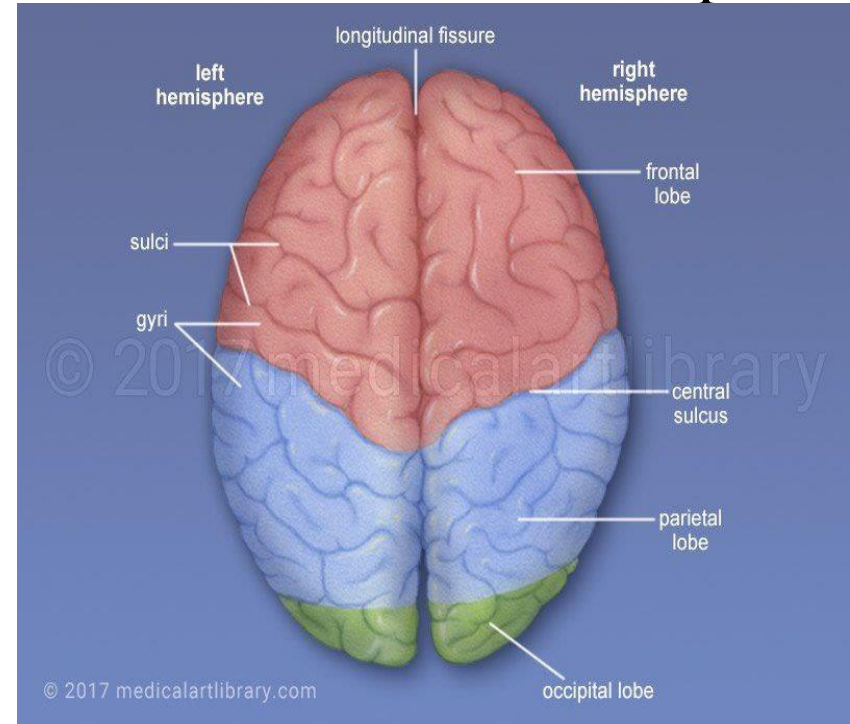
Parts of the Brain

It consists of the following parts:

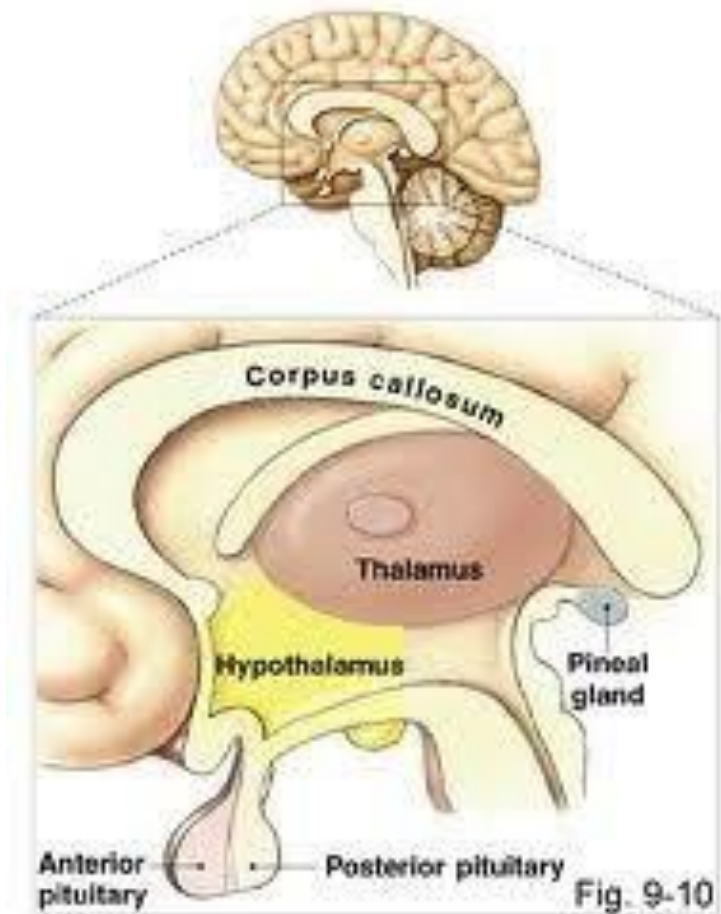
A. Forebrain: It is further subdivided into cerebrum and diencephalon

□ **Cerebrum:** It is the largest part of the brain and consists of two cerebral hemispheres connected by a mass of white matter called the corpus callosum. Each hemispheres extend from the frontal to occipital bone above the anterior and middle cranial fossae and posteriorly above tentorium cerebelli. The hemispheres are separated by a deep cleft the **longitudinal fissure**, into which project the **falx cerebri**.

******The surface layer of each hemisphere is called the **cortex** and composed of **gray matter**. The cavity present between two cerebral hemispheres is called **Lateral ventricle**.



□ **Diencephalon:** It is almost completely hidden from the surface of the brain. It consists of a **dorsal thalamus** (which is a large mass of gray matter lies on either side of third ventricle) and a **ventral hypothalamus** (forms the lower part of lateral wall and floor of third ventricle).



B. Midbrain: It is the narrow part of the brain that connects the forebrain to the hindbrain. It comprises of two lateral halves called cerebral peduncles; The narrow cavity of the midbrain is the **cerebral aqueduct**.

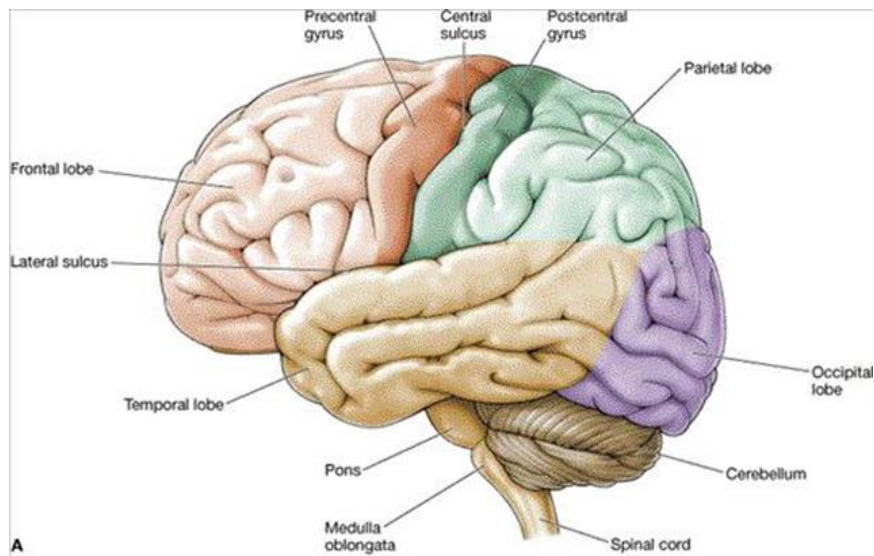
C. Hindbrain: It is made up of pons and medulla oblongata (ventrally) and cerebellum (dorsally).

-- **Pons:** is situated on the anterior surface of cerebellum below the midbrain and above medulla oblongata.

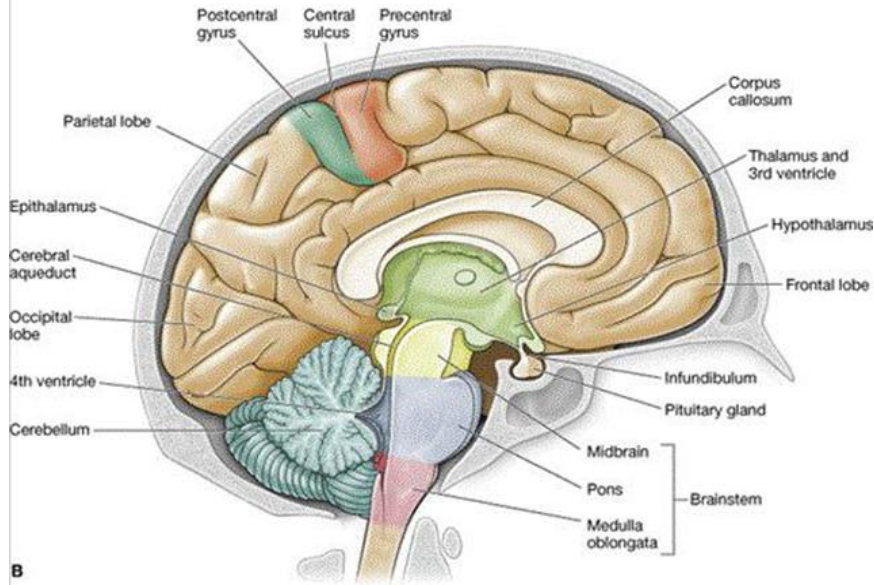
--**Medulla oblongata:** is conical in shape and connects the pons above to the spinal cord below.

--**Cerebellum:** lies within posterior cranial fossa beneath the tentorium cerebelli, Its situated posterior to the pons and medulla oblongata. Its consist of two hemispheres connected by **vermis**.

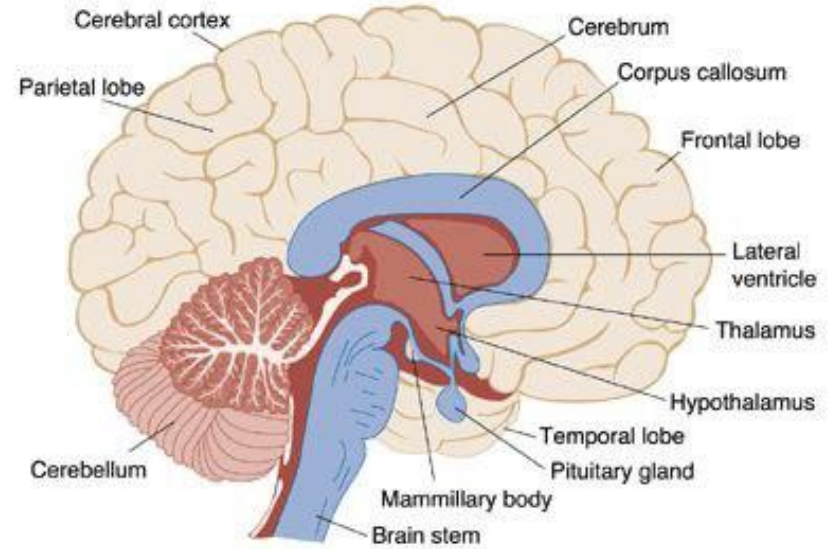
****** The cavity of hindbrain is the **fourth ventricle**.



A



B



Ventricular System of the Brain

The ventricles of the brain consist of the two lateral ventricles, the 3rd ventricle, and the 4th ventricle. The lateral ventricles are in communicate with the third ventricle through **interventricular foramina**; the third ventricle communicates with the fourth ventricle by **cerebral aqueduct**. The cerebrospinal fluid (CSF), largely secreted by the choroid plexuses of the ventricles, fills these brain cavities and the subarachnoid space of the brain and spinal cord.

CSF protects the brain by providing a cushion against blows to the head. The CSF in the subarachnoid space provides the buoyancy that prevents the weight of the brain from compressing the cranial nerve roots and blood vessels against the internal surface of the cranium. In addition, it removes the waste products that associated with neuronal activity.

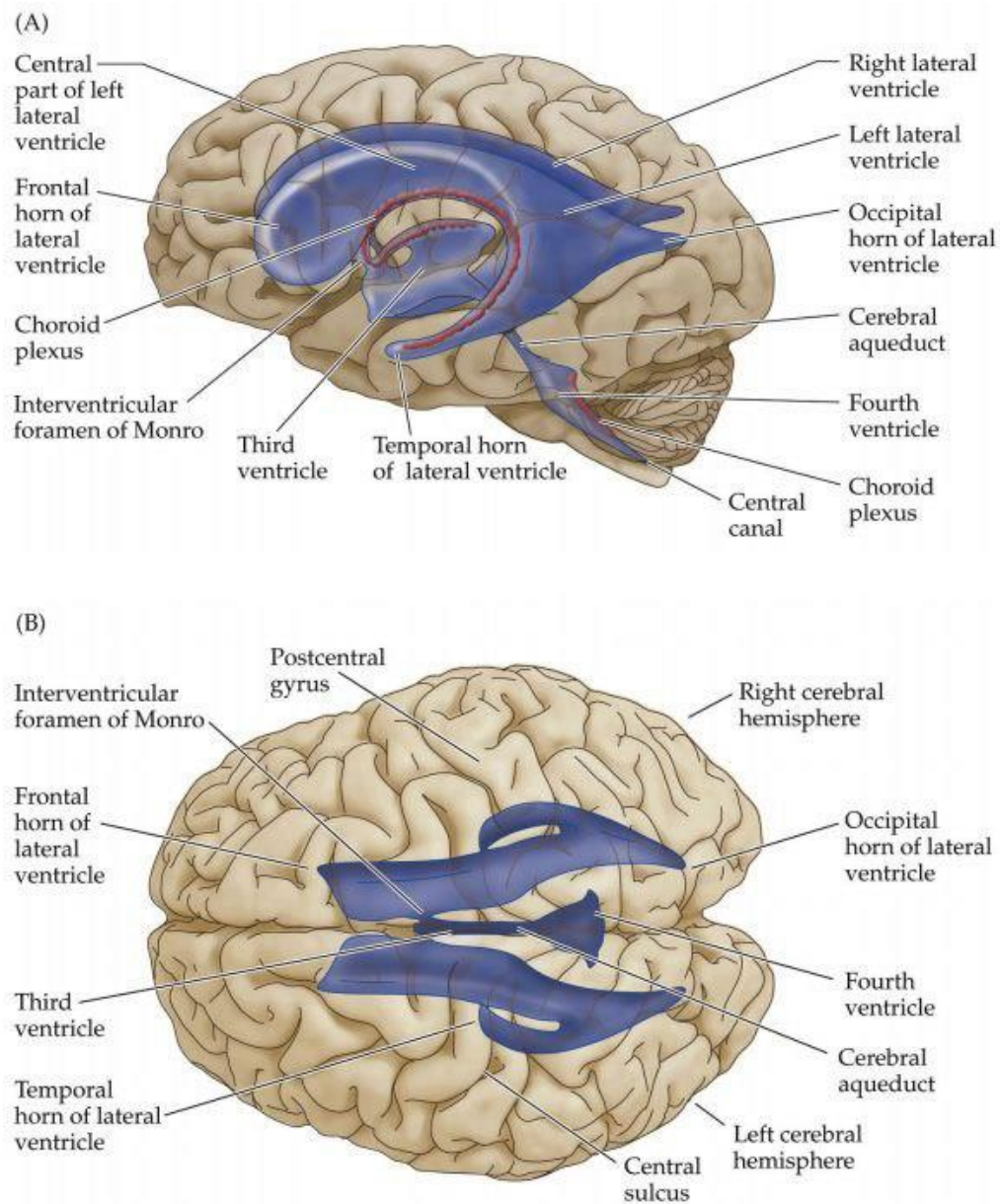
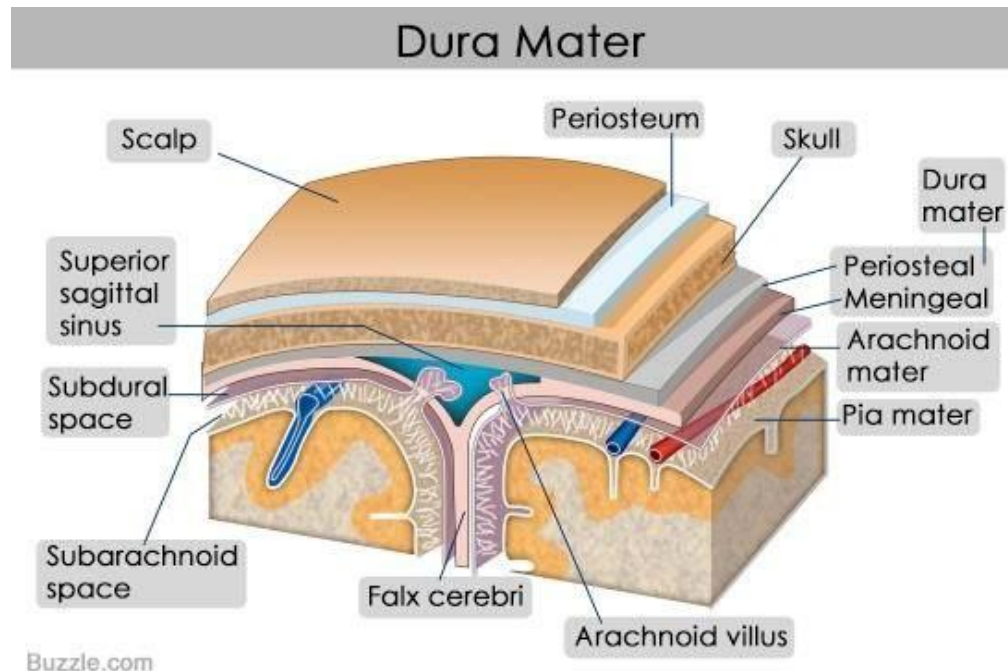


Figure 5.7. The ventricular system. (A) Location of the ventricles as seen in a transparent left lateral view. Note the presence of choroid plexus in each ventricle, which is the vascularized tissue that produces cerebrospinal fluid. (B) Dorsal view of the ventricles. (Figure A23 from *Neuroscience*, 5th Ed., Sinauer Assoc., Inc.)

The Venous Blood Sinuses (Dural Sinuses)

The venous sinuses of the cranial cavity are blood-filled spaces situated between the layers of the dura mater; they are lined by endothelium. Their walls are thick and composed of fibrous tissue; they have no muscular tissue. The sinuses have no valves. They receive tributaries from the brain, the diploë of the skull, the orbit, and the internal ear.



The dural venous sinuses : they are blood-filled spaces situated between the layer of dura mater

These sinuses are:

- The superior and inferior sagittal sinuses
- The straight sinus
- The right transverse sinus (a continuation of the superior sagittal sinus)
- The left transverse sinus (a continuation of the straight sinus)
- The sigmoid sinuses (a direct continuation of the transverse sinuses)
- The occipital sinus
- The confluence of sinuses (meeting of superior sagittal, inferior sagittal, straight, occipital sinuses and two transverse sinuses)
- The superior and inferior petrosal sinuses
- The cavernous sinus (on each side of the sella turcica)
- The sphenoparietal sinus

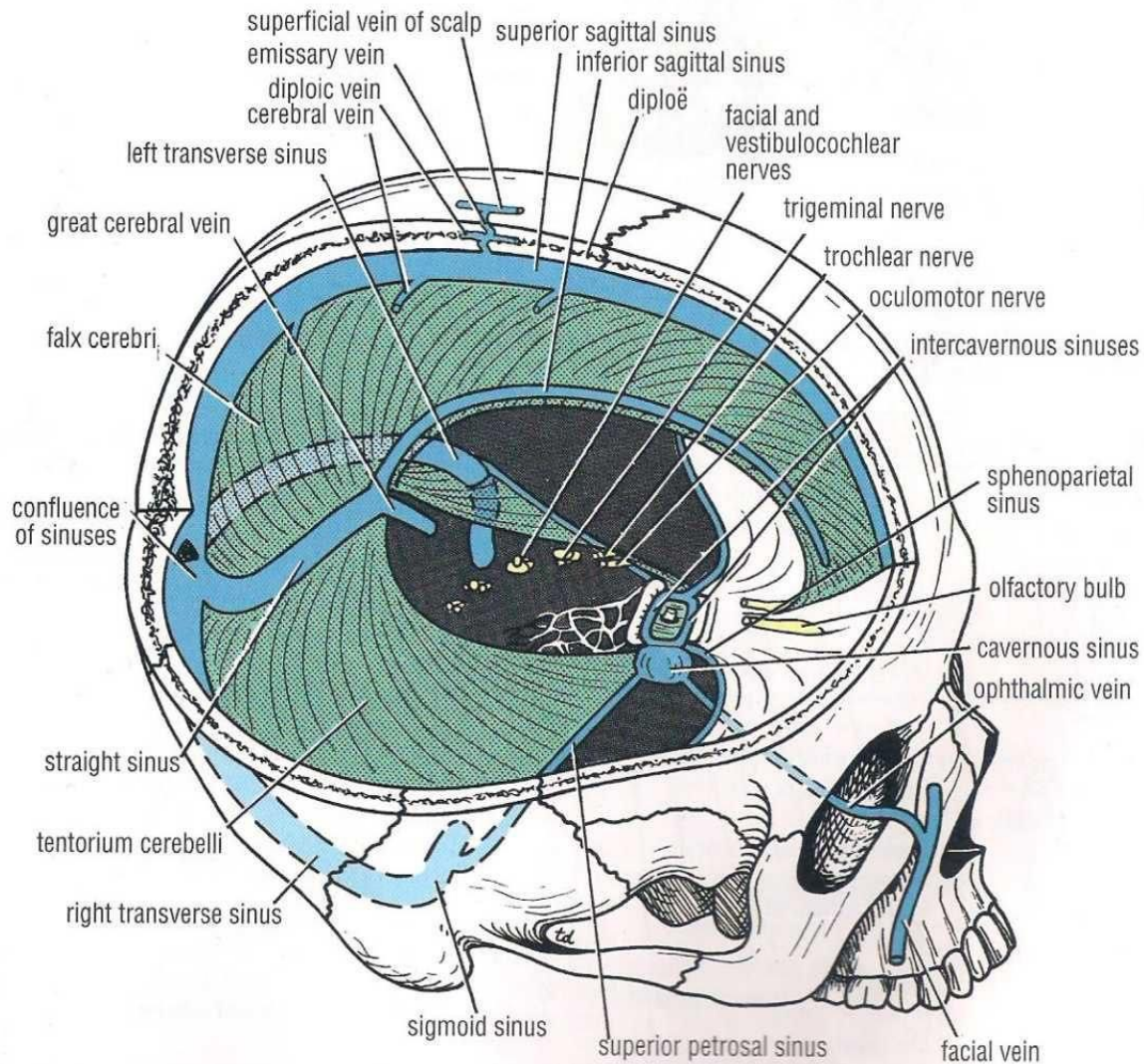
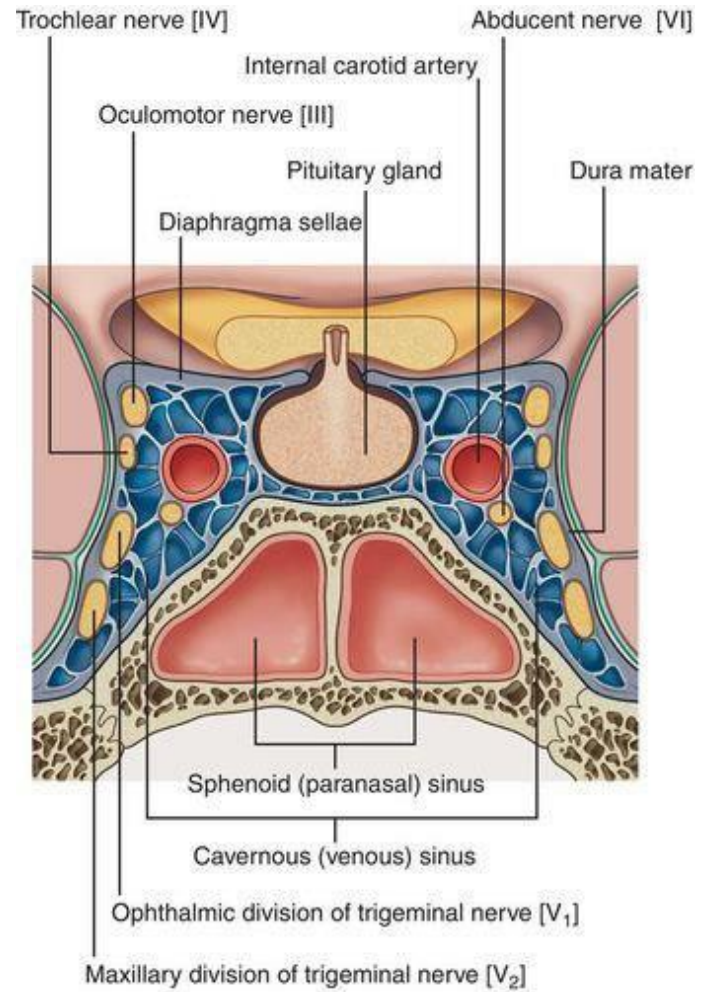
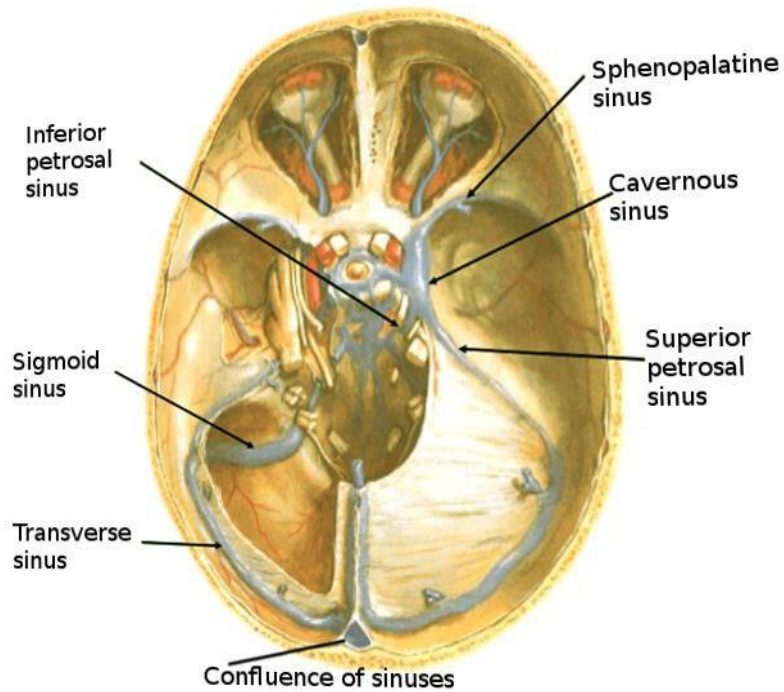


Figure 11-36 Interior of the skull showing the dura mater and its contained venous sinuses. Note the connections of the veins of the scalp and the veins of the face with the venous sinuses.

The cavernous sinus: are situated in middle cranial fossa on each side of the body of sphenoid bone. The sinus drains posteriorly into the superior and inferior petrosal sinuses and inferiorly into the pterygoid venous plexus.

- The important structures associated with cavernous sinus:
- The internal carotid artery and the 6th cranial nerve, which travel through it.
- In the lateral wall, the 3rd and 4th cranial nerve, and ophthalmic and maxillary division of 5th cranial N .
- The pituitary gland, which lie medially in the sella turcica.
- The vein of face, which connected with C.S via the facial v. and inferior ophthalmic v. are an important route for the spread of infection from the face.
- The superior and inferior petrosal sinuses, which run along the upper and lower borders of the petrous part of the temporal bone.



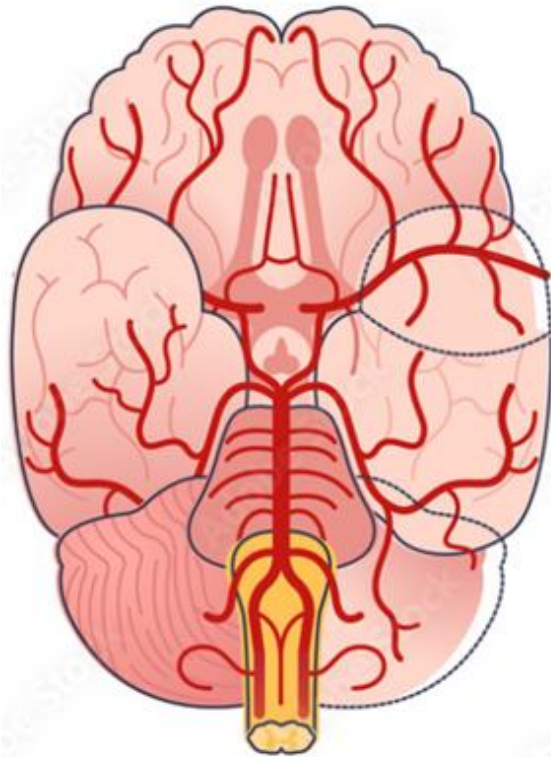
Blood Supply of the Brain

Arteries of the Brain Although it accounts for only about 2.5% of body weight, the brain receives about one sixth of the cardiac output and one fifth of the oxygen consumed by the body at rest. The brain is supplied by the **two internal carotid** and the **two vertebral** arteries. The four arteries anastomose on the inferior surface of the brain and form the circle of Willis. The **1 posterior communicating arteries** are branches of **internal carotid arteries**.

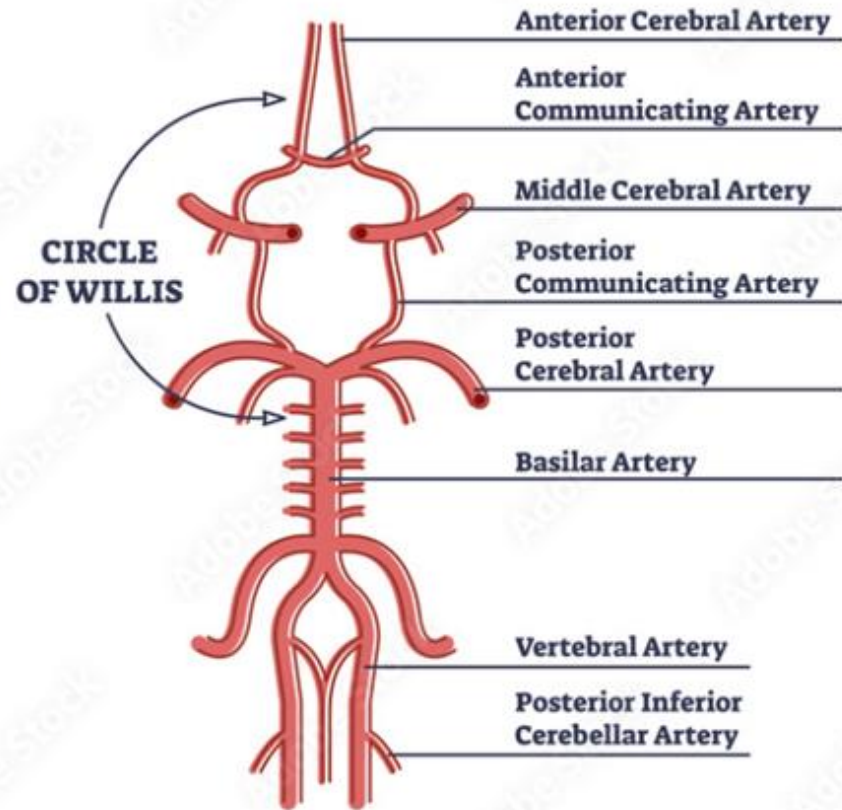
The terminal branches of the internal carotid arteries are the **2 anterior** and **3 middle cerebral arteries**. The anterior cerebral arteries are connected by the **anterior communicating artery**.

The intracranial parts of the vertebral arteries unite at the caudal border of the pons to form the **basilar artery**. It ends by dividing into the two **posterior cerebral arteries**. The internal carotid arteries are joined to the **posterior cerebral arteries** by the **1 posterior communicating arteries** to close the circle.

CIRCLE OF WILLIS

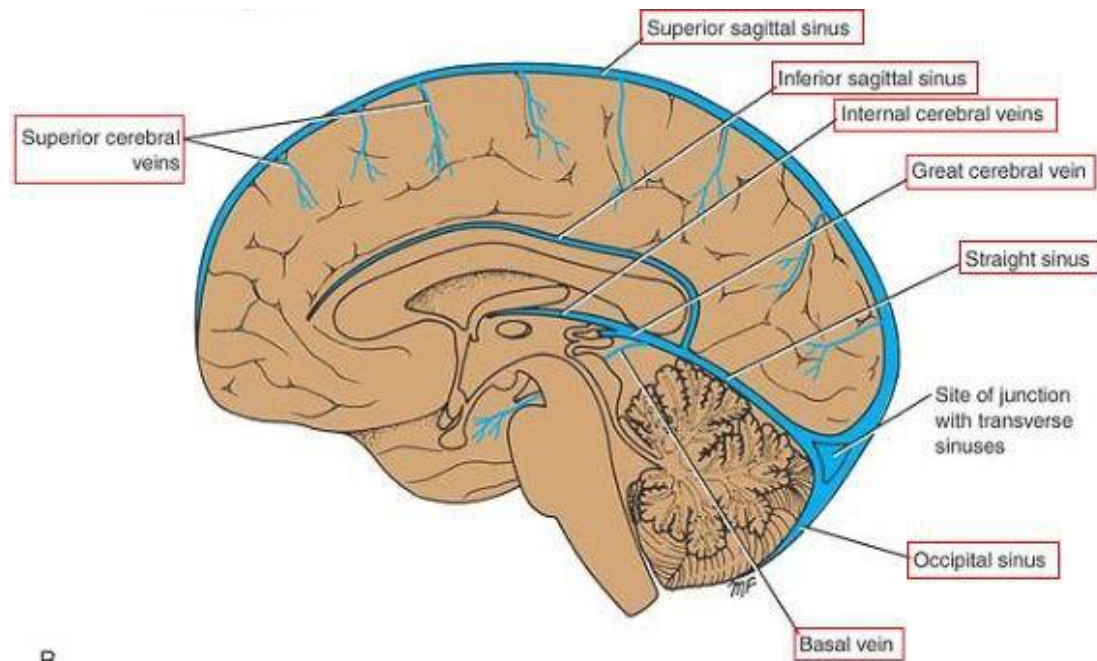


INFERIOR VIEW



Veins of the Brain

The veins of the brain have no muscular tissue in their thin walls, and they possess no valves. Venous drainage from the brain occurs via cerebral and cerebellar veins that drain to the adjacent dural venous sinuses. The **great cerebral vein** is formed by the union of the **two internal cerebral veins** and drains into the straight sinus.





THANK YOU



HUMAN ANATOMY

Cranial Nerves

Lec 3

Asis.Lec. Noor Ghazi

Like spinal nerves, cranial nerves are bundles of sensory or motor fibers that innervate muscles or glands, carry impulses from sensory receptors, or have a combination of motor and sensory fibers. They are called cranial nerves because they emerge through foramina or fissures in the cranium and are covered by tubular sheaths derived from the cranial meninges. Twelve pairs of cranial nerves arise from the brain, and they are identified both by their names and by Roman numerals I to XII. Their names reflect their general distribution or function. Some cranial nerves are purely sensory, others are considered purely motor, and several are mixed.

The cranial nerves are somewhat unique and can contain multiple functional components:

- **General**: same general functions as spinal nerves.
- **Special**: functions found only in cranial nerves.
- **Afferent and efferent**: sensory and motor functions, respectively.
- **Somatic and visceral**: related to skin and skeletal muscle (somatic) or to smooth muscle, cardiac muscle, and glands (visceral).

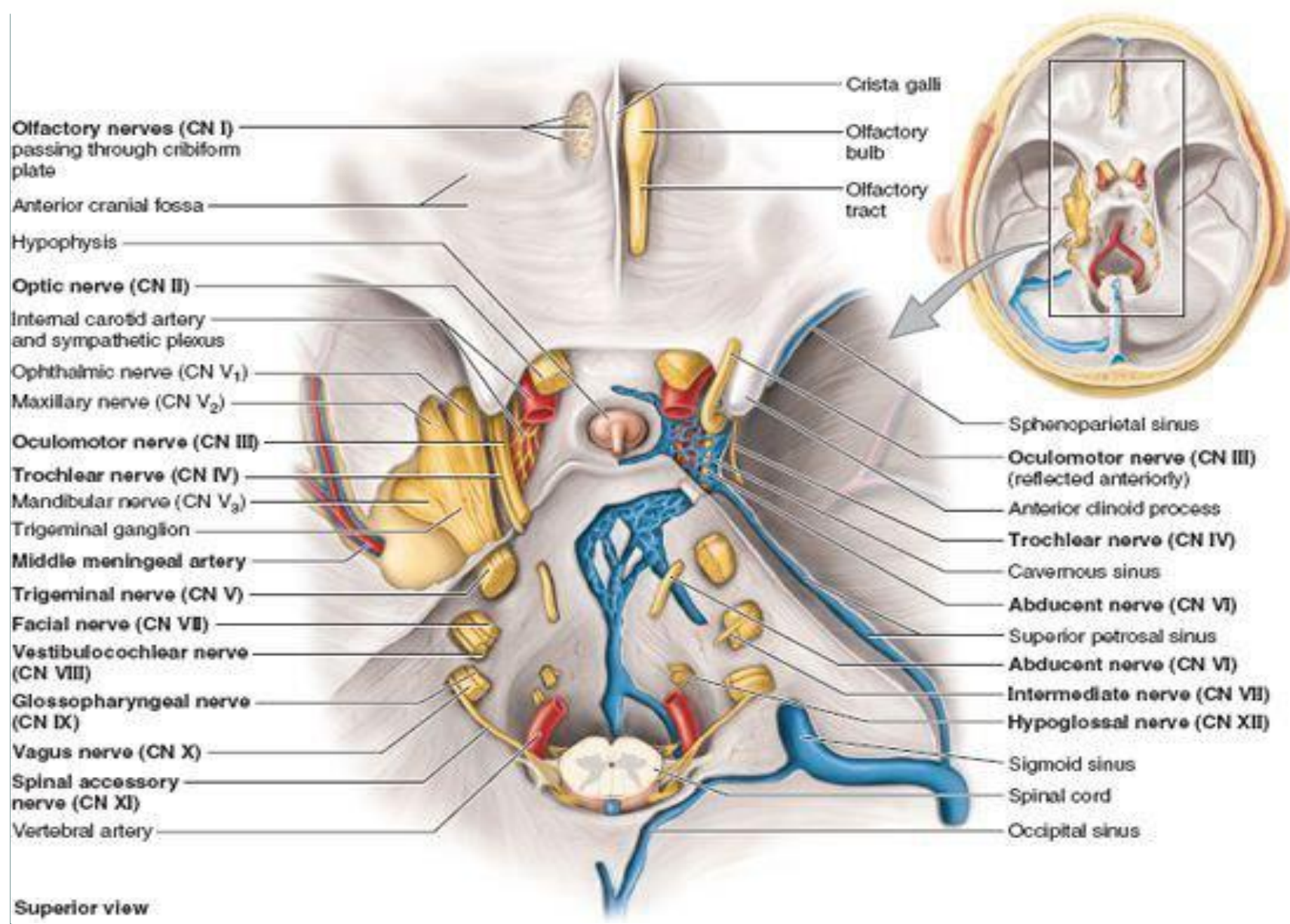
Nerve	components	Brain connection part	Function	Opening in Skull
I. Olfactory	Sensory	cerebrum	Smell	Opening in cribriform plate of ethmoid
II. Optic	Sensory	cerebrum	Vision	Optic canal
III. Oculomotor	Motor	midbrain	Lifts upper eyelid, turns eyeball upward, downward, medially, constricts pupil; accommodates eye	Superior orbital fissure
IV. Trochlear	Motor	midbrain	Assists in turning eyeball downward and laterally	Superior orbital fissure
V. Trigeminal		Pons		Superior orbital fissure
A. Ophthalmic division	Sensory		Cornea, Skin of forehead, scalp, eyelids, and nose; also mucous membrane of paranasal sinuses and nasal cavity	
B. Maxillary division	Sensory		Skin of face over maxilla and the upper lip; teeth of upper jaw; mucous membrane of the nose, the maxillary air sinus, and palate	Foramen rotundum

Nerve	Components	Brain connection part	Function	Opening in Skull
C. Mandibular division	<p>Motor</p> <p>Sensory</p>		<p>Muscle of mastication; mylohyoid, anterior belly of digastric, tensor veli palatini, and tensor tympani</p> <p>Skin of cheek, skin over mandible, lower lip, and side head; teeth of lower jaw and temporomandibular joint; mucous membrane of mouth and anterior two thirds of tongue</p>	Foramen ovale
VI. Abducent	Motor	Anterior surface of brain betw. Lower border of pons & medulla oblongata	Lateral rectus muscle: turns eyeball laterally	Superior orbital fissure

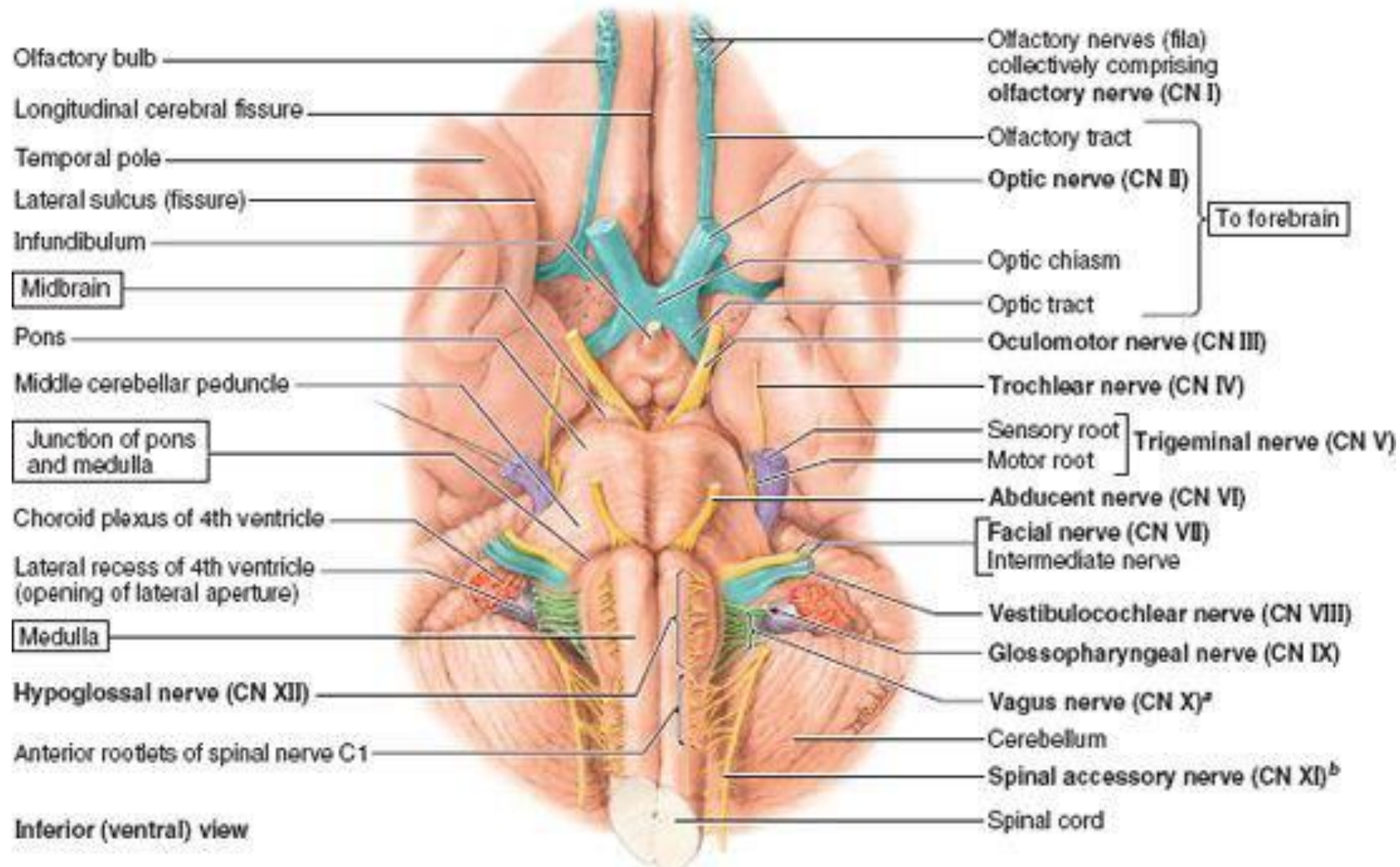
VII. Facial	Motor	Anterior surface of brain betw. Lower border of pons & medulla oblongata	Muscle of face, cheek, and scalp; stapedius muscle of middle ear, stylohyoid; and posterior belly of digastric, buccinator.	Internal acoustic meatus, facial canal, stylomastoid foramen
	Sensory		Taste from anterior two thirds of tongue, floor of mouth, and palate	
	Secretomotor or parasympathatic		Submandibular and sublingual salivary glands, lacrimal gland, and glands of nose and palate	
VIII. Vestibulochlear - Vestibular - Cochlear	Sensory Sensory	Anterior surface of brain betw. Lower border of pons & medulla oblongata	Position and movement of head Hearing	Internal acoustic meatus
IX. Glossopharyngeal	Motor	Medulla oblongata	Stylopharyngeus muscle: assists swallowing	Jugular foramen

	Secretomotor parasympathatic		Parotid salivary gland	
	Sensory		General sensation and taste from postrior third of tongue and pharynx ; carotid sinus and carotid body	
X. Vagus	Motor	Medulla oblongata	Constrictor muscles of pharynx and intrinsic muscles of larynx; involuntary muscle of trachea and bronchi,, heart, alimentary tract from pharynx to splenic flexure of colon; liver and pancreas	Jugular foramen
	Sensory		Taste from epiglottis and vallecula and afferent fibers from structure named above	

XI. Accessory Cranial	Motor	Medulla oblongata	Muscle of soft palate, pharynx, and larynx	Jugular foramen
Spinal	Motor		Sternocleidomastoid, and trapezius muscles	
XII. Hypoglossal	Motor	Medulla oblongata	Muscles of tongue controlling its shape and movement (except palatoglossus)	Hypoglossal canal



Superior view



Thank You

Larynx



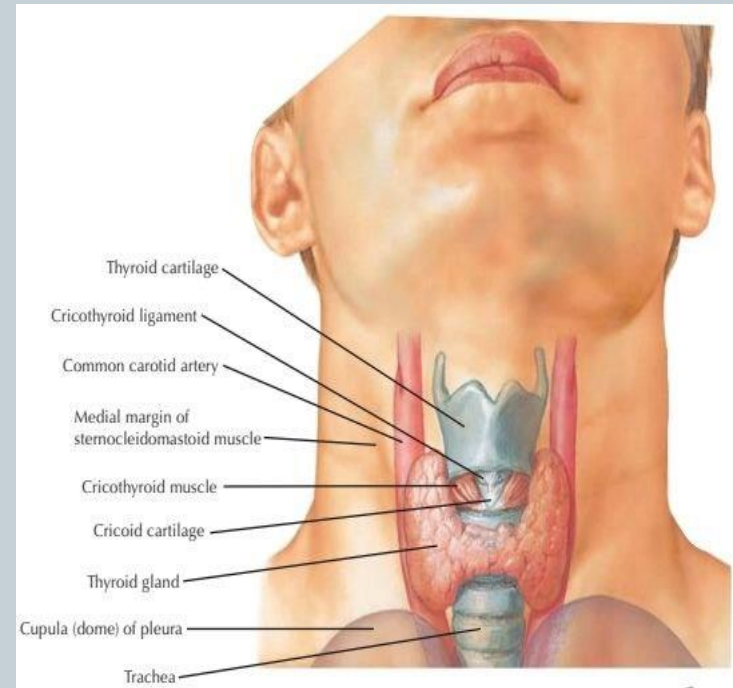
ASSIS. LEC. NOOR GHAZI

2/5/2023



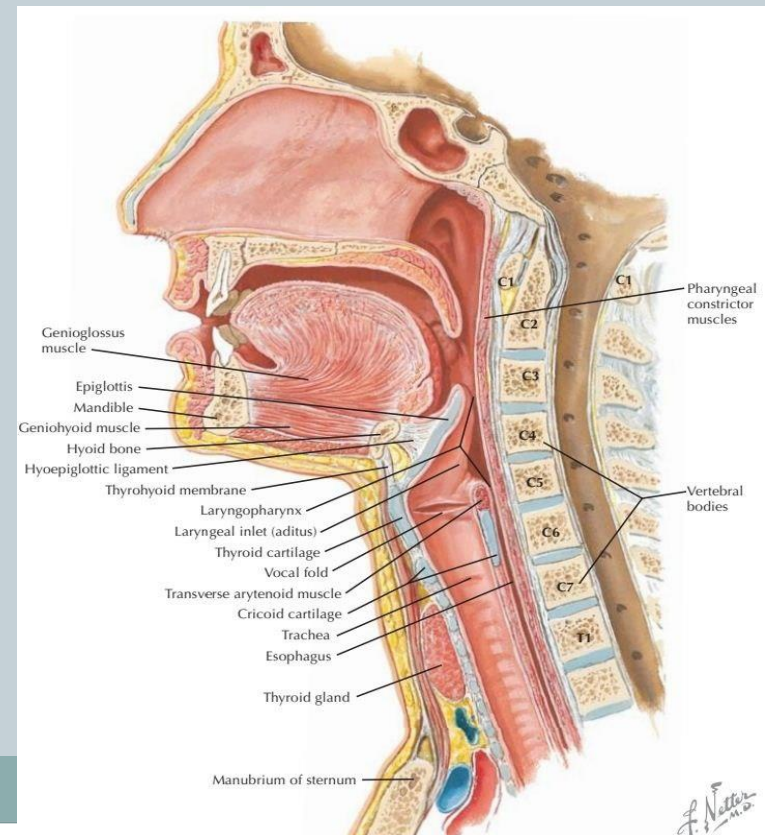
● GENERAL INFORMATION

- Larynx: connection between the pharynx and the trachea
- Designed for the production of sound (phonation)
- Shorter in women and children
- Formed by 9 cartilages: 3 paired and 3 unpaired
- Located in the midline opposite the 3rd to the 6th cervical vertebra



Relations of the Larynx

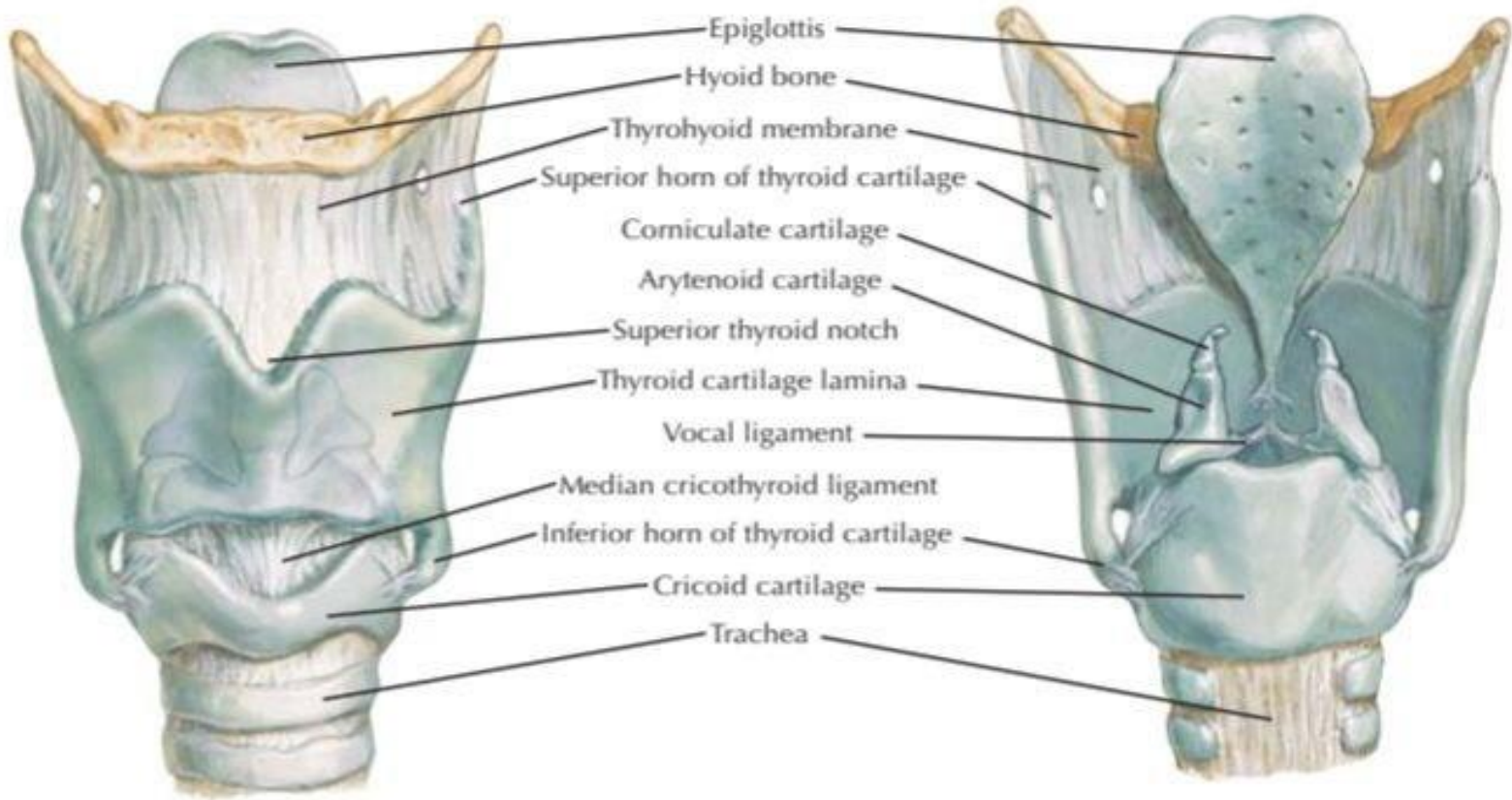
- Anterolateral—infrahyoid muscles, platysma
- Lateral—lobes of the thyroid gland, carotid sheath
- Posterior—it forms the anterior wall of the laryngopharynx
- Superior—base of tongue and vallecula
- Inferior—trachea



Cartilages

GENERAL INFORMATION

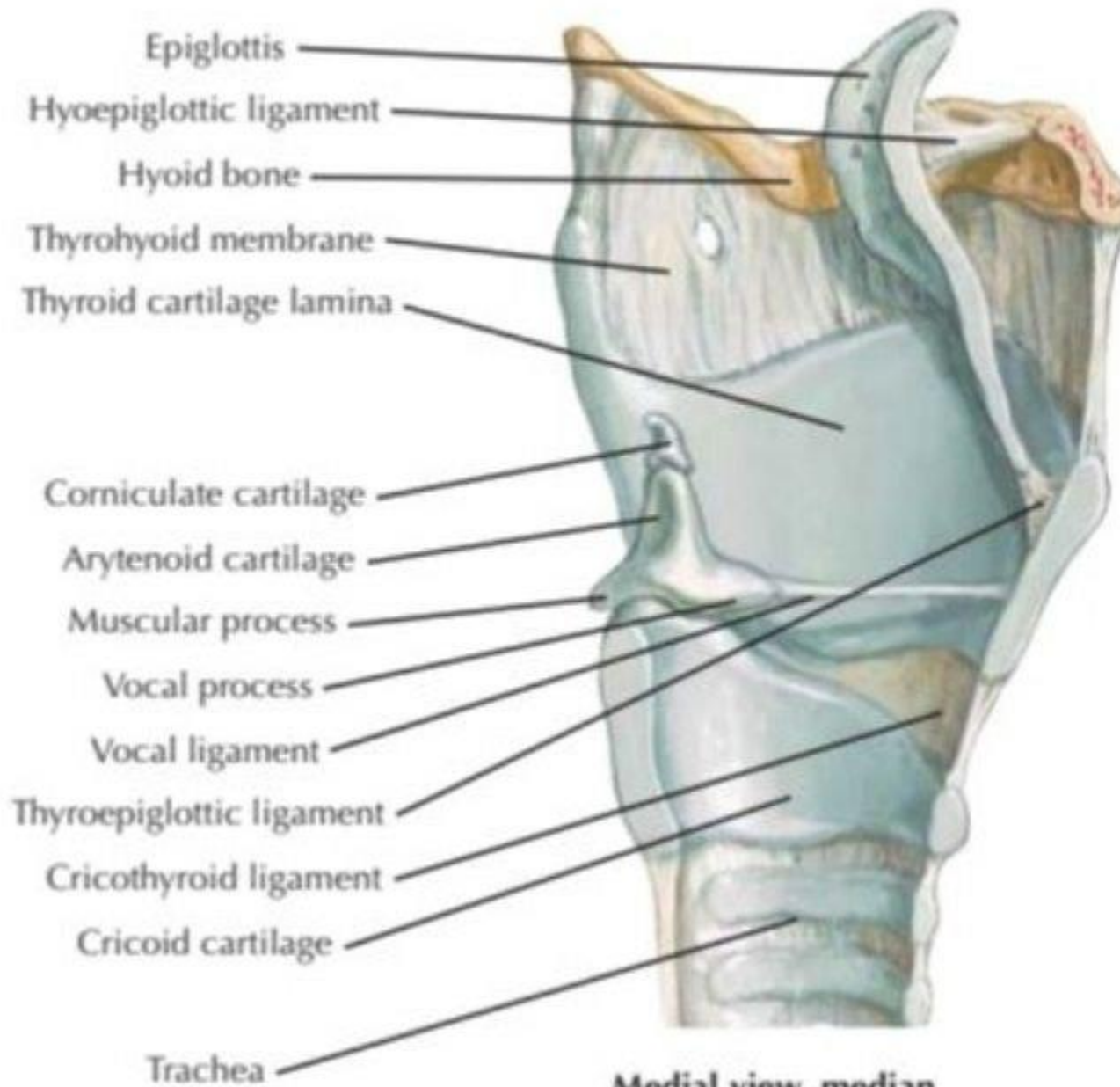
Cartilage	Cartilage Type	Paired	Comments
Thyroid	Hyaline	No	Largest of the laryngeal cartilages Connects to the hyoid bone via the thyrohyoid membrane, which allows the internal laryngeal n. and superior laryngeal vessels to pass through to enter the larynx Lies between C4 and C6
Cricoid			Only complete ring of cartilage in the respiratory system Signet in shape Both intrinsic and extrinsic laryngeal muscles attach to the cricoid Lies at C6
Arytenoid			Yes
Epiglottis	Elastic	No	Helps prevent foreign bodies from entering the larynx
Corniculate (minor)		Yes	Minor cartilages that lie in the aryepiglottic fold
Cuneiform (minor)			



Anterior view

Posterior view

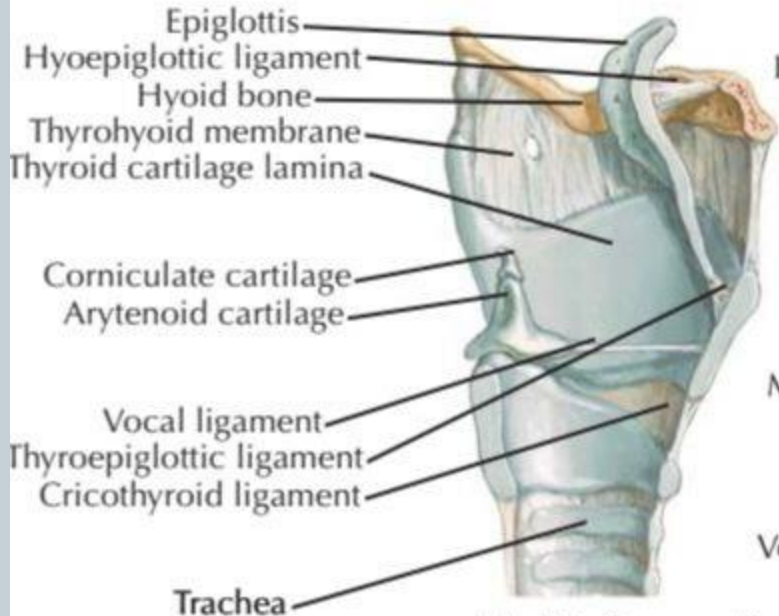
Anterosuperior view



Membranes and Ligaments

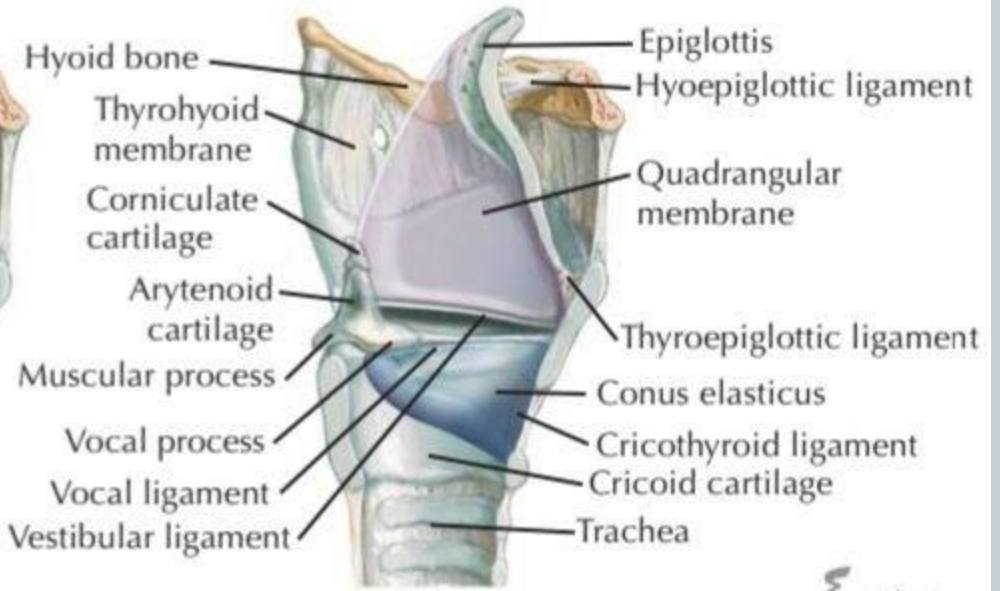
MAJOR EXTRINSIC LIGAMENTS

Ligament(s)	Location	Comments
2 lateral thyrohyoid ligaments 1 median thyrohyoid ligament Thyrohyoid membrane	Thyroid cartilage to hyoid bone	The thyrohyoid membrane allows passage of the internal laryngeal n. and superior laryngeal vessels
Median cricothyroid ligament	Cricoid cartilage to thyroid cartilage	Primary site for establishing an emergency airway
Cricotracheal ligament	Cricoid cartilage to trachea	Attaches the cricoid cartilage to the first tracheal ring May be used in establishing an emergency airway



- Epiglottis
- Hyoepiglottic ligament
- Hyoid bone
- Thyrohyoid membrane
- Thyroid cartilage lamina
- Corniculate cartilage
- Arytenoid cartilage
- Vocal ligament
- Thyroepiglottic ligament
- Cricothyroid ligament
- Trachea

Medial view, median (sagittal) section



- Hyoid bone
- Thyrohyoid membrane
- Corniculate cartilage
- Arytenoid cartilage
- Muscular process
- Vocal process
- Vocal ligament
- Vestibular ligament
- Epiglottis
- Hyoepiglottic ligament
- Quadrangular membrane
- Thyroepiglottic ligament
- Conus elasticus
- Cricothyroid ligament
- Cricoid cartilage
- Trachea

F. Netter M.D.
K. Carter



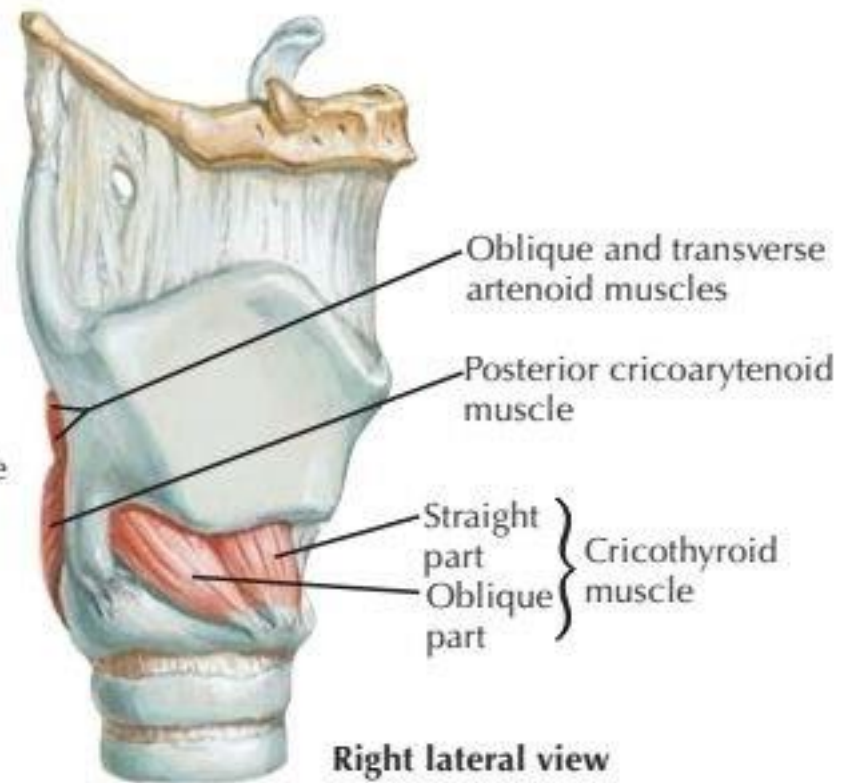
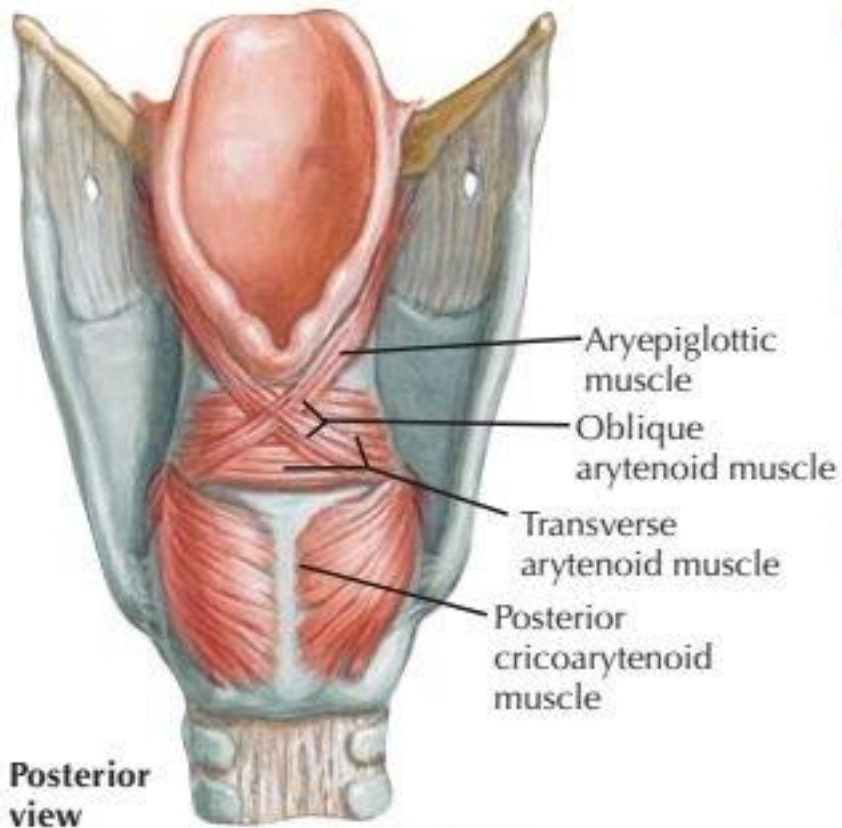
MAJOR INTRINSIC LIGAMENTS

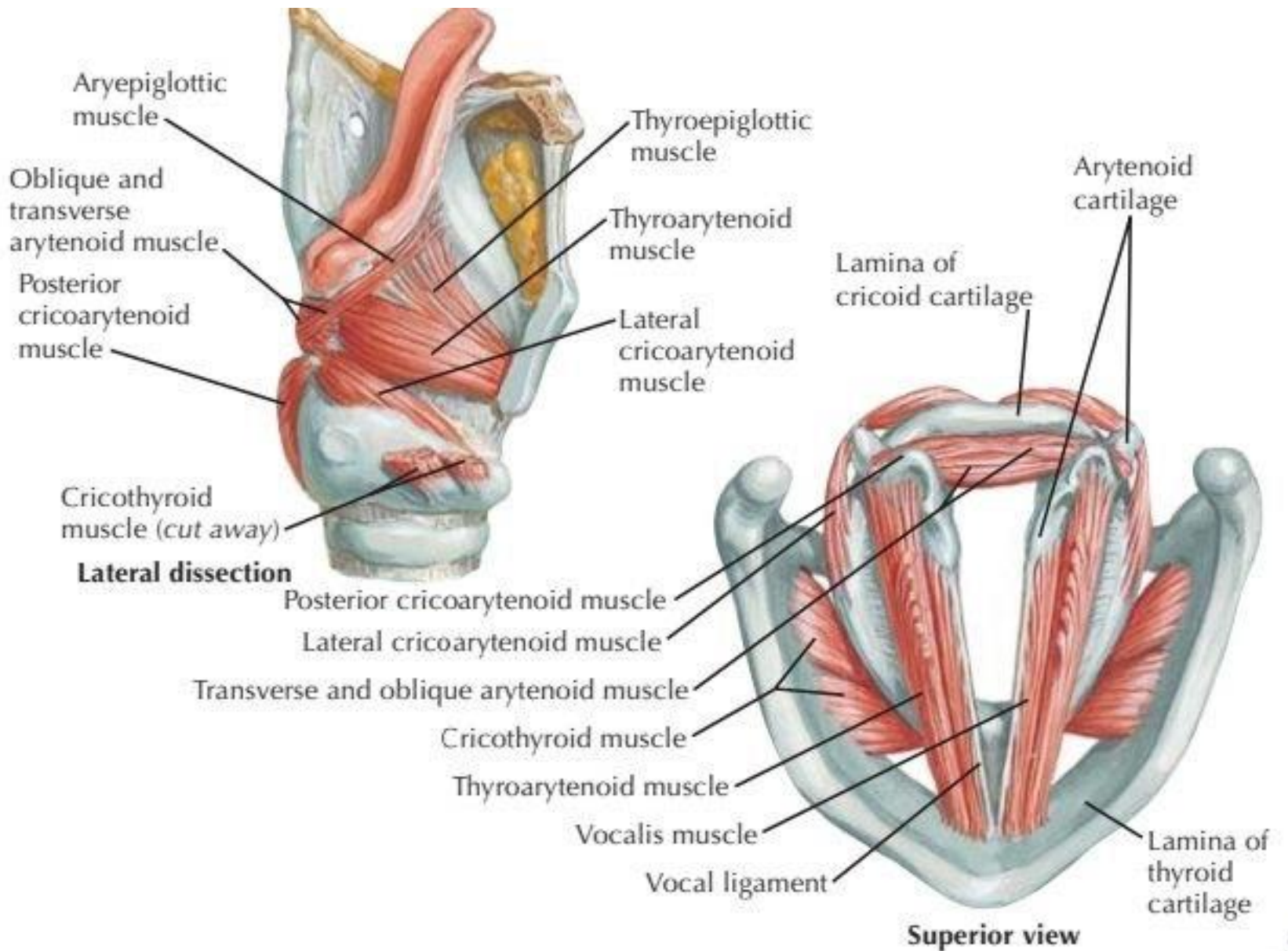
Ligament	Location	Comments
Vocal ligament	Arytenoid (vocal) to thyroid cartilage	Help form <i>true</i> vocal cord
Conus elasticus	Superior—thyroid, vocal lig., arytenoid (vocal) Inferior—upper border of cricoid	
Quadrangular membrane	Arytenoid to epiglottis	Help form <i>false</i> vocal cord
Vestibular ligament	Free edge of quadrangular membrane	

Muscles



Muscle	Origin	Insertion	Action(s)	Nerve Supply
Cricothyroid	Arch of cricoid	Lamina and inferior cornu of thyroid	Increases tension on vocal ligaments	External laryngeal n.
Thyroarytenoid	Angle of thyroid cartilage	Arytenoid (vocal process)	Decreases tension on vocal ligaments	Recurrent laryngeal n.
Posterior cricoarytenoid	Lamina of cricoid	Arytenoid (muscular process)	Opens rima glottidis	
Lateral cricoarytenoid	Arch of cricoid (lateral portion)		Closes rima glottidis	
Transverse arytenoid	Arytenoid (muscular process)	Opposite arytenoid (muscular process)		
Oblique arytenoid		Opposite arytenoid (apex)		
Aryepiglotticus	Arytenoid (apex)	Epiglottis	Helps close laryngopharyngeal opening	
Thyroepiglotticus	Thyroid lamina			





Muscles

OVERVIEW *CONTINUED*

SUMMARY OF MUSCLE ACTIONS

Altering the Rima Glottidis

Altering Tension on the Vocal Cords

Muscle

Action

Muscle

Action

Posterior cricoarytenoid

Opens the rima glottidis

Cricothyroid

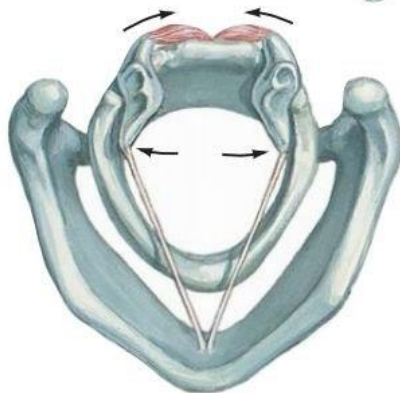
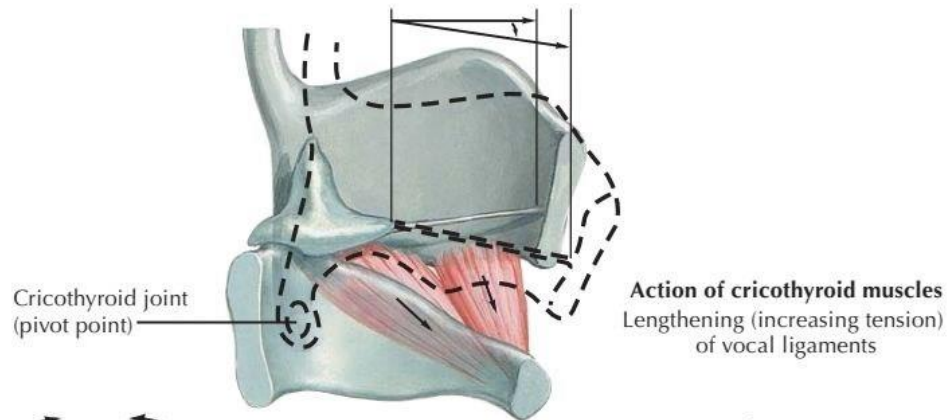
Increasing tension

Transverse arytenoids
Oblique arytenoids
Lateral cricoarytenoid

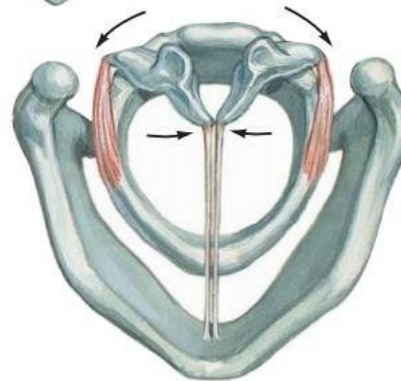
Closes the rima glottidis

Thyroarytenoid

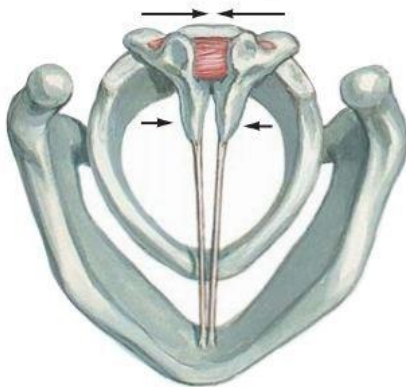
Decreasing tension



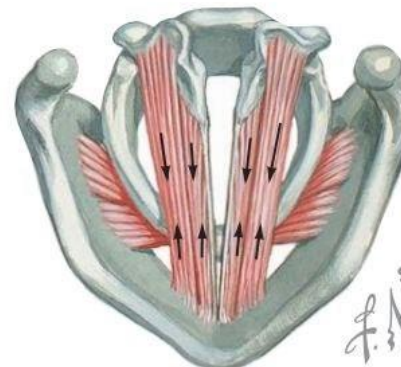
Action of posterior cricoarytenoid muscles
Abduction of vocal ligaments



Action of lateral cricoarytenoid muscles
Adduction of vocal ligaments



Action of transverse arytenoid muscles
Adduction of vocal ligaments



Action of vocalis and thyroarytenoid muscles
Shortening (relaxation) of vocal ligaments

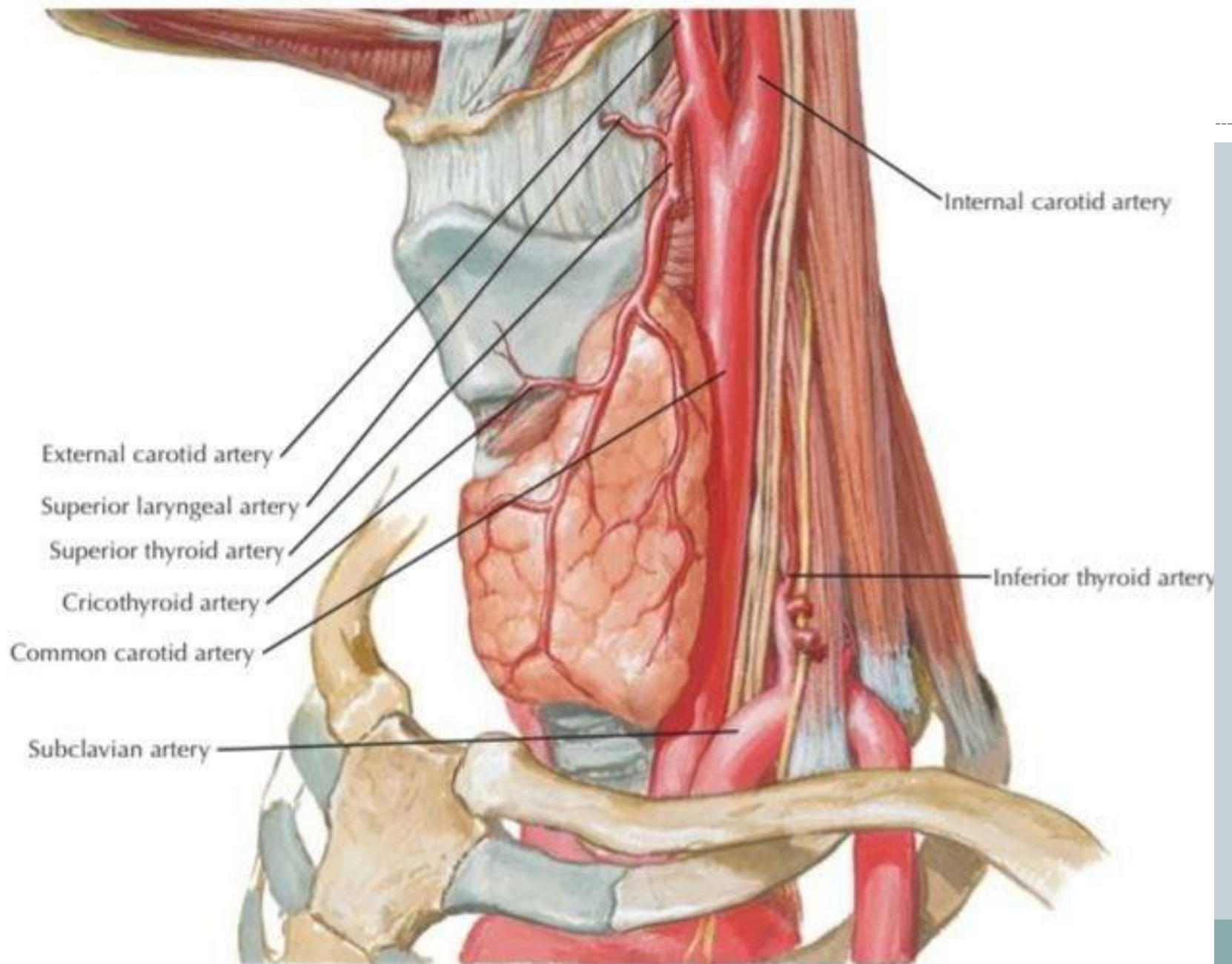
F. Netter M.D.

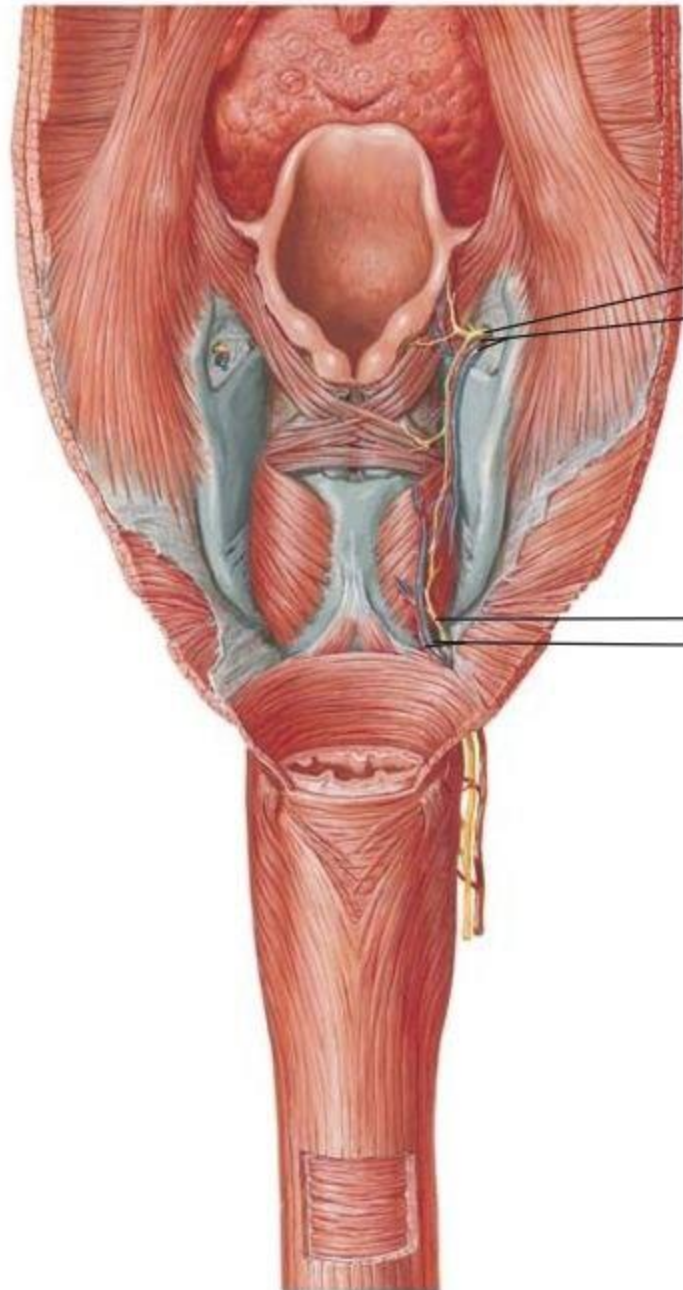


Vascular Supply

ARTERIAL SUPPLY

Artery	Source	Course
Superior laryngeal	Superior thyroid a., which arises from the external carotid a.	Passes through the thyrohyoid membrane with the internal laryngeal n. to enter the deep surface of the larynx
Inferior laryngeal	Inferior thyroid a., which arises from the thyrocervical trunk	Passes superiorly on the trachea to reach the posterior border of the larynx Lies immediately deep to the inferior constrictor m. traveling beside the recurrent laryngeal n.





Internal laryngeal nerve
Superior laryngeal artery
and vein

Recurrent laryngeal nerve
Inferior laryngeal artery
and vein

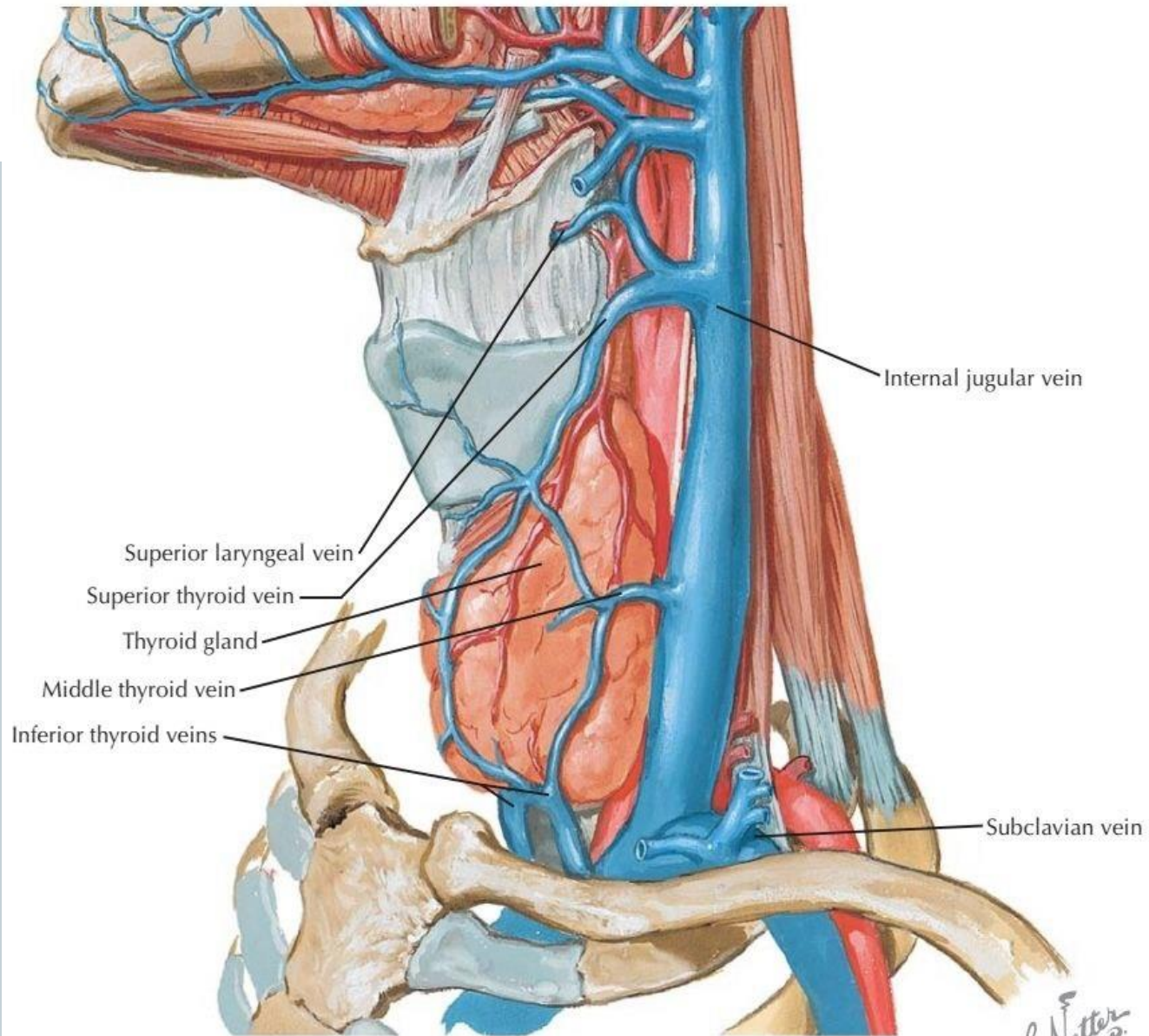
*F. Netter
M.D.*



Vascular Supply

VENOUS DRAINAGE

Vein	Course
Superior laryngeal	Begins in the deep surface of the superior part of the larynx Passes with the superior laryngeal a. and the internal laryngeal n. Passes through the thyrohyoid membrane to lie on the superficial surface of the larynx Drains into the superior thyroid v., which drains into the internal jugular v.
Inferior laryngeal	Arises within the deep surface of the inferior part of the larynx Passes with the inferior laryngeal a. and the recurrent laryngeal n. Passes inferiorly deep to the inferior constrictor to exit the larynx Drains into the inferior thyroid v., which drains into the brachiocephalic vv.

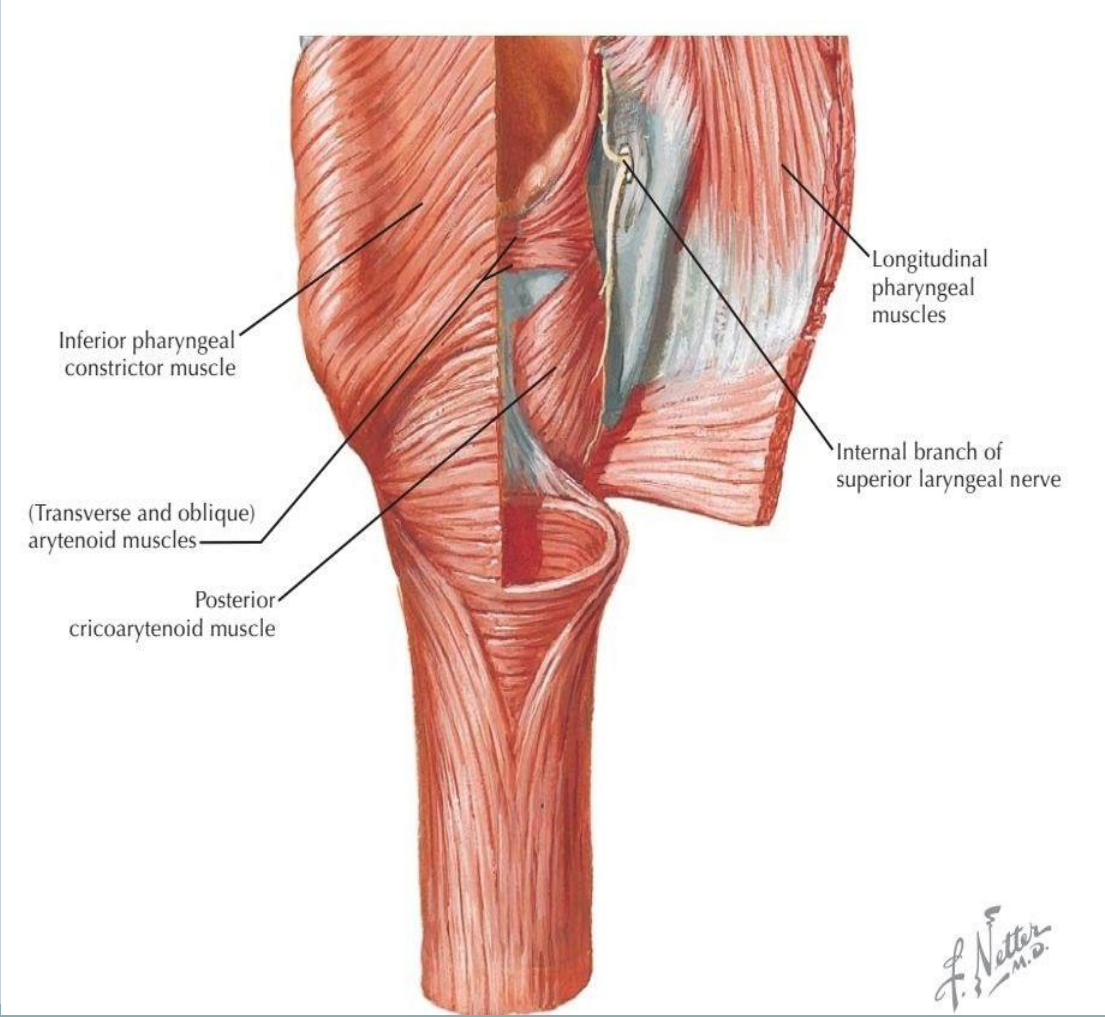


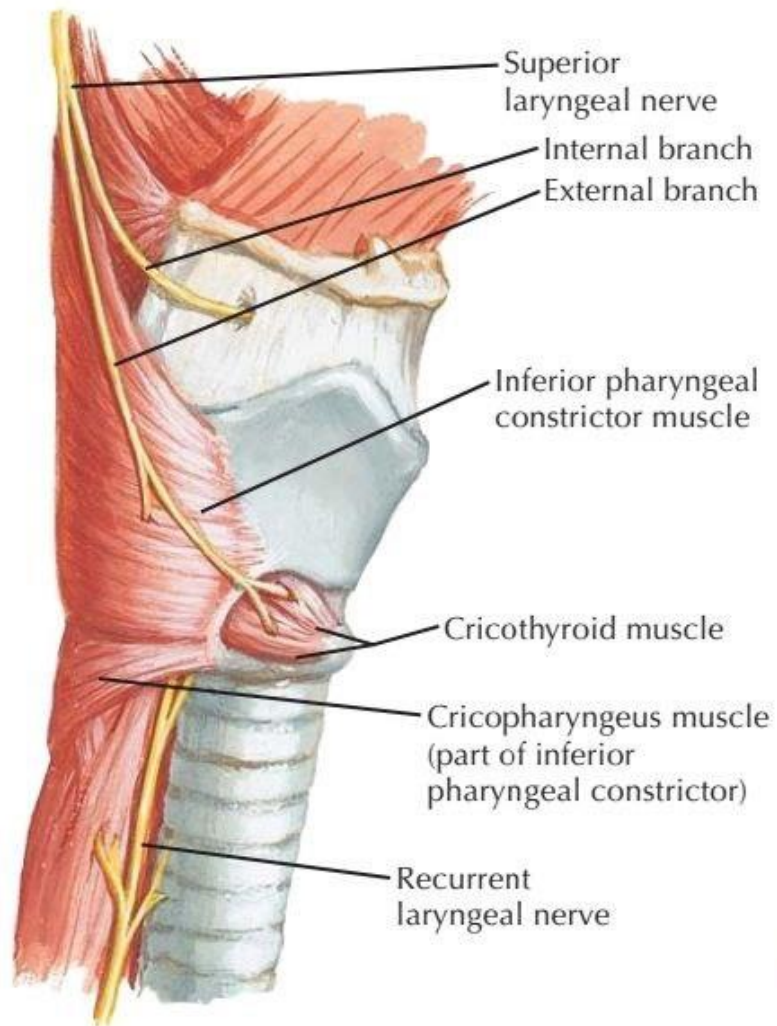
F. Netter M.D.

Nerve Supply

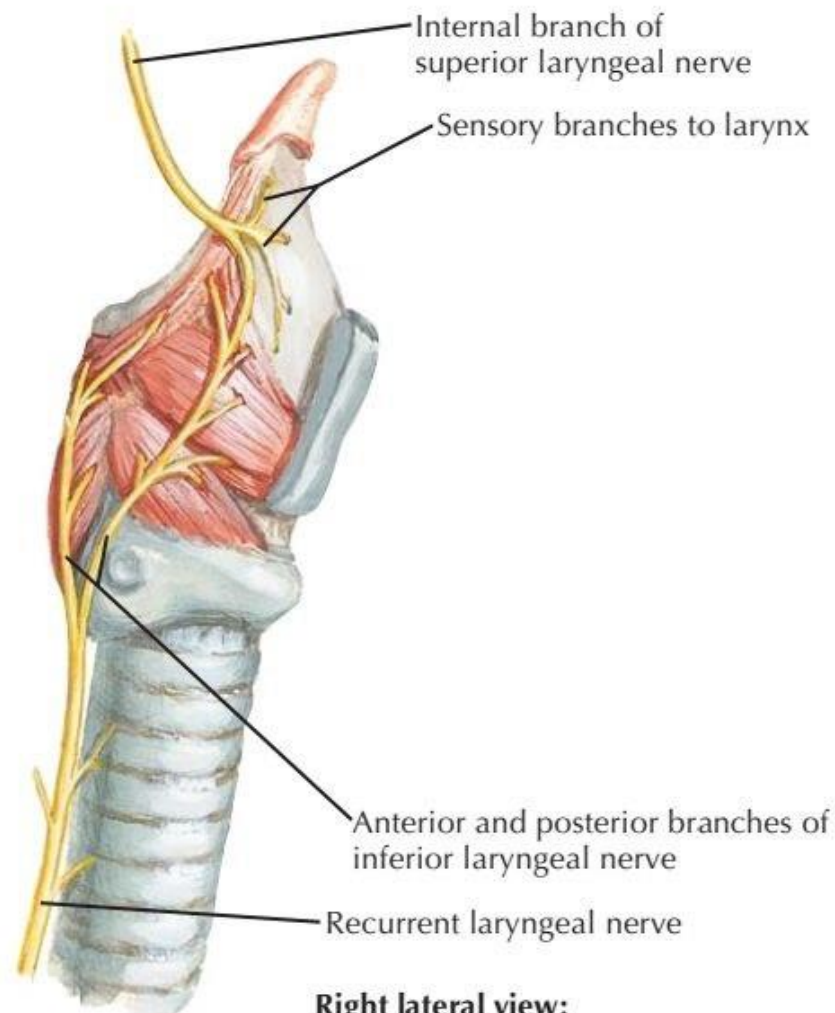
MOTOR AND SENSORY BRANCHES FROM THE VAGUS NERVE

Nerve	Type	Sensory Target	Muscles Innervated	Comments
Internal laryngeal	Sensory	Membranes above the false vocal folds		Branch of superior laryngeal nerve from the vagus
Recurrent laryngeal	Sensory and motor	Membranes below the false vocal folds	Thyroarytenoid Posterior cricoarytenoid Lateral cricoarytenoid Transverse arytenoid Oblique arytenoid Aryepiglotticus Thyroepiglotticus	Branch of the vagus Wraps around the aorta posterior to the ligamentum arteriosum on the left side Wraps around the right subclavian artery on the right side Ascends on the lateral aspect of the trachea until reaching the pharynx, where it passes deep to the inferior constrictor to reach the larynx
External laryngeal	Motor		Cricothyroid	Branch of superior laryngeal nerve from the vagus





Right lateral view



**Right lateral view:
thyroid cartilage lamina removed**

Clinical Correlate

EMERGENCY AIRWAY: CRICOTHYROTOMY

Cricothyrotomy: a procedure for establishing an emergency airway when other methods are unsuitable

Once the anatomy of the larynx is identified, the procedure can be performed with 2 incisions:

- Incision through the skin
- Incision through the cricothyroid membrane

The correct location for the incision is easiest to find by identifying the thyroid notch on the thyroid cartilage

By sliding the examining finger in an inferior direction, the groove between the thyroid and cricoid cartilages can be located

A 3-cm vertical incision is made through the skin, and the thyrohyoid membrane is located

A small midline incision is made, and a tracheostomy tube is inserted to establish an airway



LARYNGITIS

Laryngitis: an inflammation of the vocal cords in the larynx that typically does not persist longer than 7 days

Characterized by a weak and hoarse voice, sore throat, and cough

Most common cause is a viral infection, although it may be caused by a bacterial infection

Can also be caused excessive yelling (such as cheering at a sporting event) and smoking

Because most cases of laryngitis are viral in nature, antibiotics generally are not used as treatment



Thank you



Human Anatomy

Nasal region

lec. 8

Asis. Lec. Noor Ghazi

The Nasal region

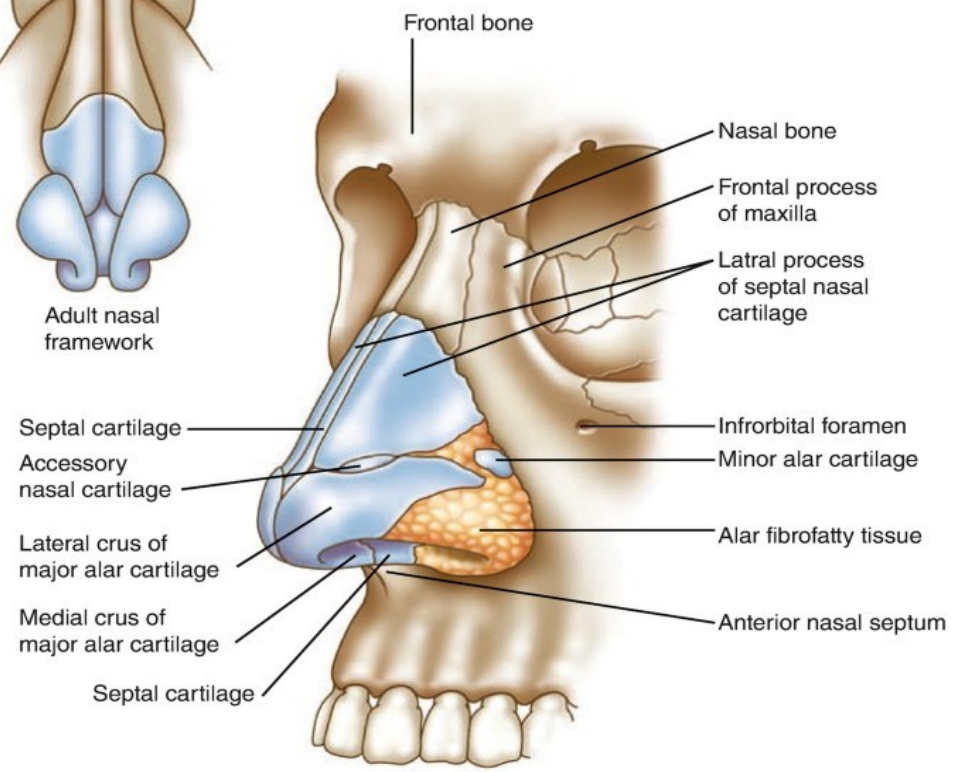
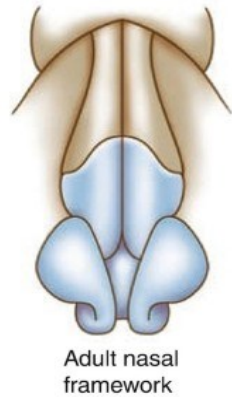
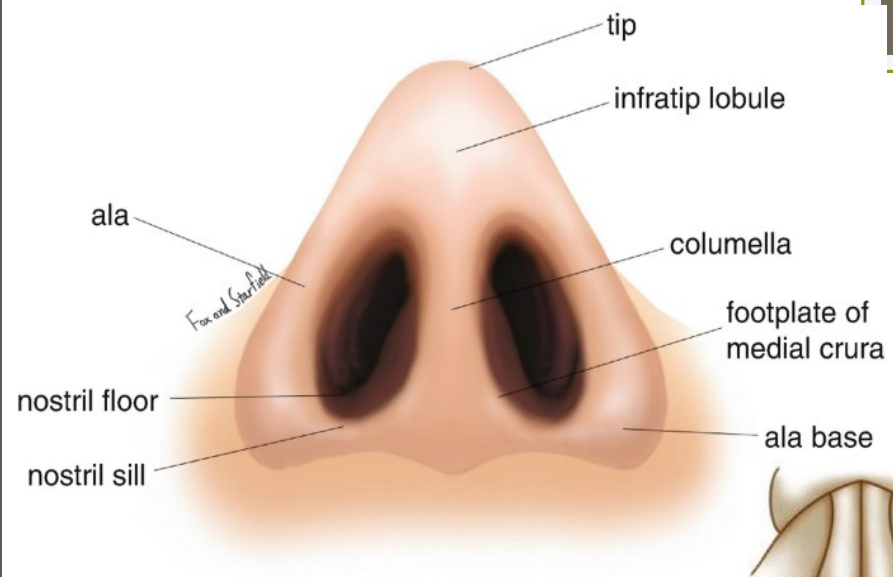
The Nose

The nose consists of the external nose and the nasal cavity, both of which are divided by a septum into right and left halves.

*External Nose

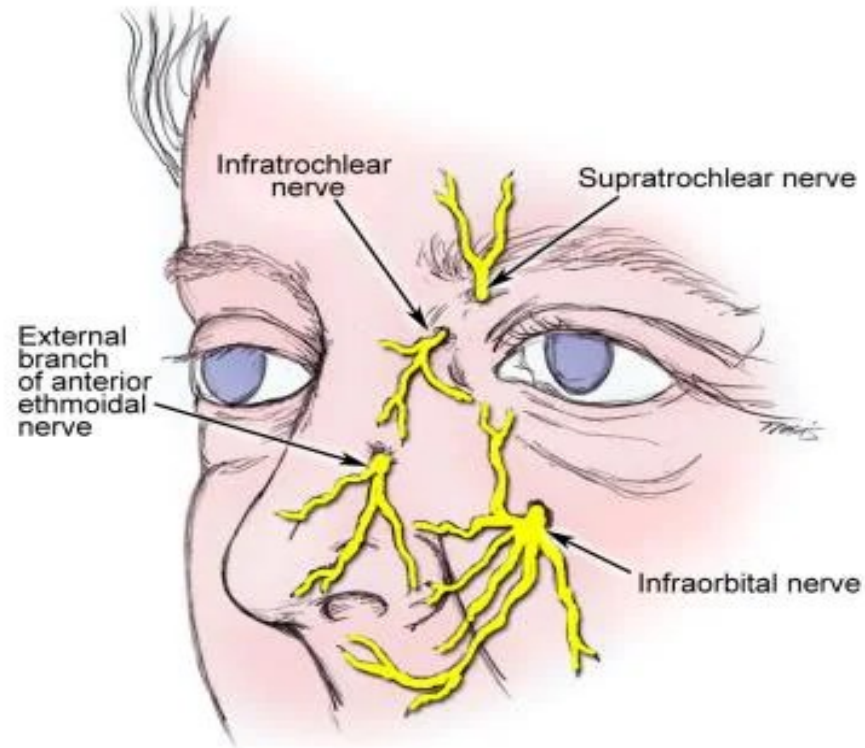
The external nose has two elliptical orifices called the nostrils, which are separated from each other by the nasal septum. The lateral margin, the ala nasi, is rounded and mobile. The framework of the external nose is made up above by the nasal bones, the frontal processes of the maxillae, and the nasal part of the frontal bone.

Below, the framework is formed of plates of hyaline cartilage, which include upper and lower nasal cartilages and the septal cartilage.



Nerve Supply of the External Nose :-

The external nose is supplied by the infratrochlear and external nasal branches of the ophthalmic nerve (CN V1), and the infraorbital branch of the maxillary nerve (CN V2).

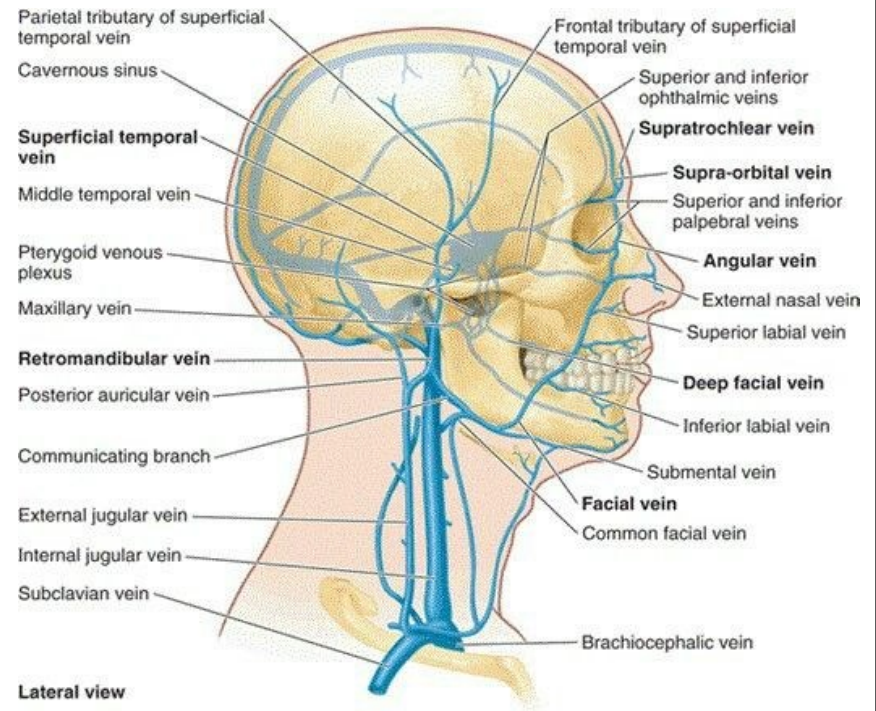
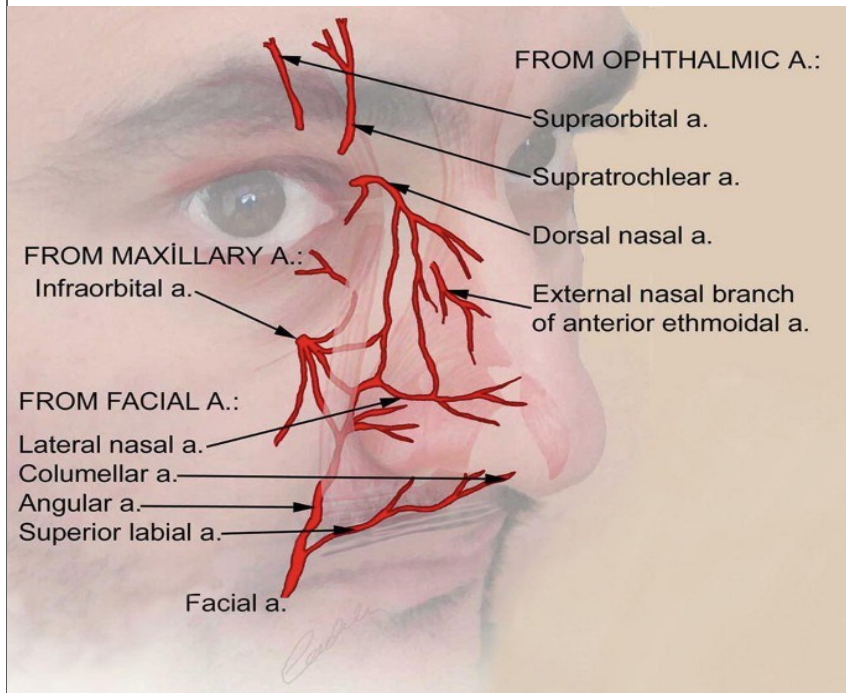


Blood Supply and Venous Drainage of the External Nose:-

The skin of the external nose is supplied by branches of the ophthalmic and the maxillary arteries.

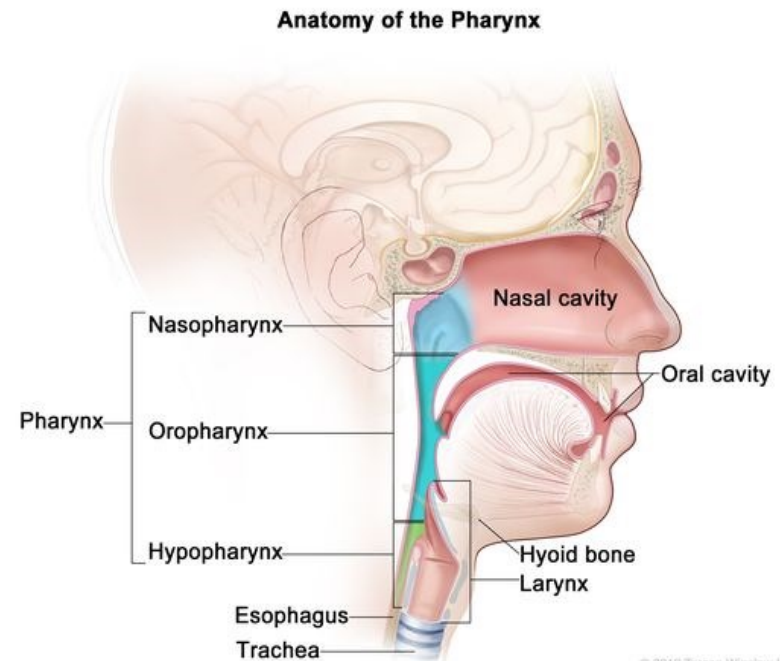
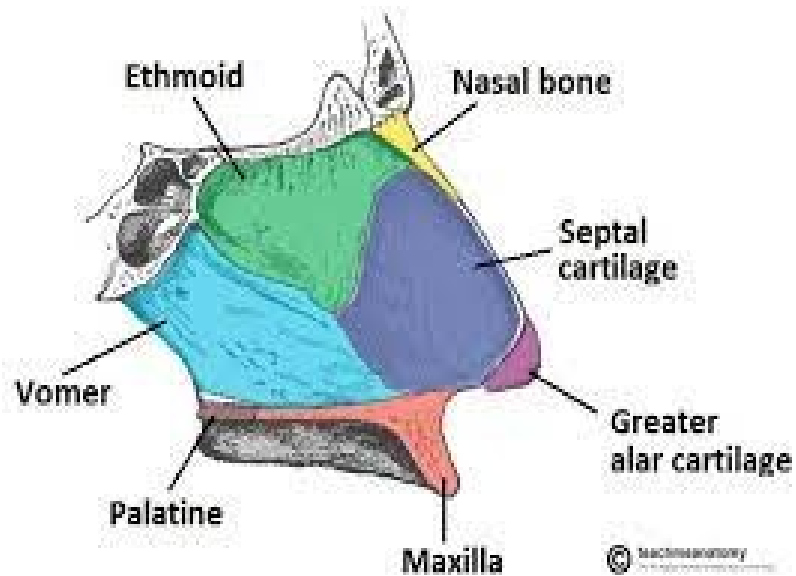
The skin of the ala and the lower part of the septum are supplied by branches from the facial artery.

Venous blood from the external nose drains mostly into the facial vein via the angular and lateral nasal veins.



*Nasal Cavity

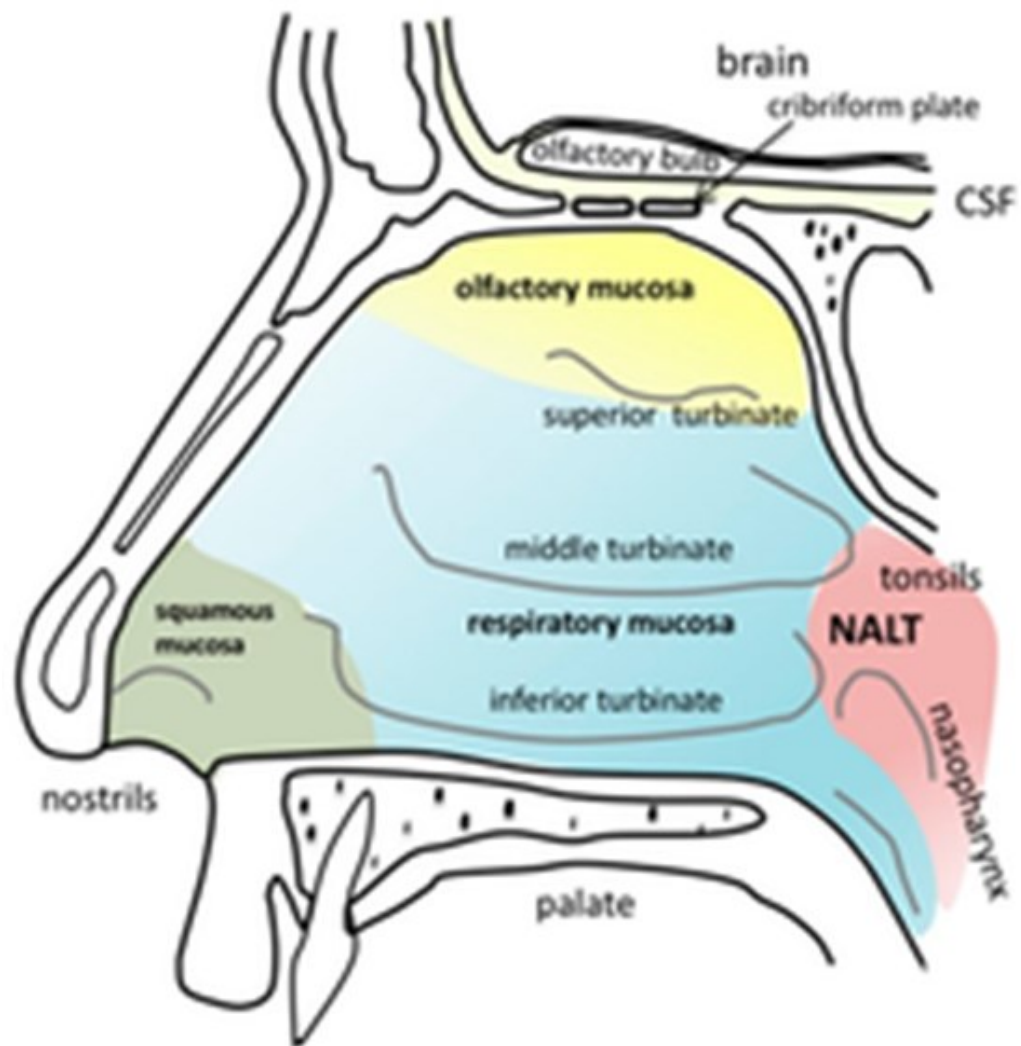
The nasal cavity extends from the nostrils in front to the posterior nasal apertures or choanae behind, where the nose opens into the nasopharynx. The nasal vestibule is the area of the nasal cavity lying just inside the nostril. The nasal cavity is divided into right and left halves by the nasal septum. The septum is made up of the septal cartilage, the vertical plate of the ethmoid, and the vomer.



Mucous Membrane of the Nasal Cavity

The vestibule is lined with modified skin and has coarse hairs. The area above the superior concha is lined with olfactory mucous membrane and contains specialized olfactory nerve cells.

The lower part of the nasal cavity is lined with respiratory mucous membrane. Its function is to warm, moisten, and clean the inspired air. The warming process is accomplished by the presence of a large plexus of veins in the submucous connective tissue. The presence of warm blood in the venous plexuses serves to heat up the inspired air as it enters the respiratory system. The moisture is derived from the abundant production of mucus secreted by glands and goblet cells. The presence of mucus on the surfaces of the conchae traps foreign particles and organisms in the inspired air, which are then swallowed and destroyed by gastric acid.



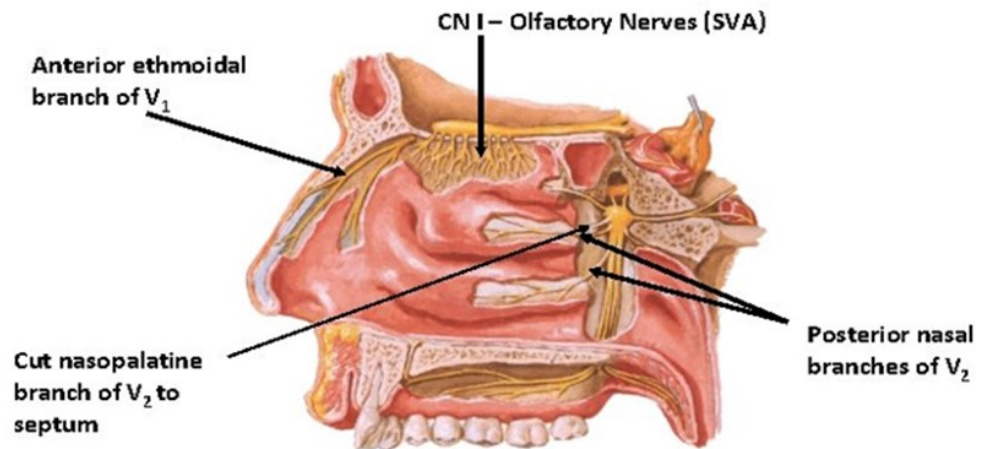
Nerve Supply of the Nasal Cavity

The olfactory nerves from the olfactory mucous membrane ascend through the cribriform plate of the ethmoid bone to the olfactory bulbs.

The nerves of general sensation are branches of the ophthalmic division (V1) and the maxillary division (V2) of the trigeminal nerve.

The nerve supply to the anterior part of the nasal cavity comes from the anterior ethmoidal nerve. The nerve supply to the posterior part of nasal cavity comes from the nasal, nasopalatine, and palatine branches of the pterygopalatine ganglion.

Nerve Supply of the Nasal Cavity



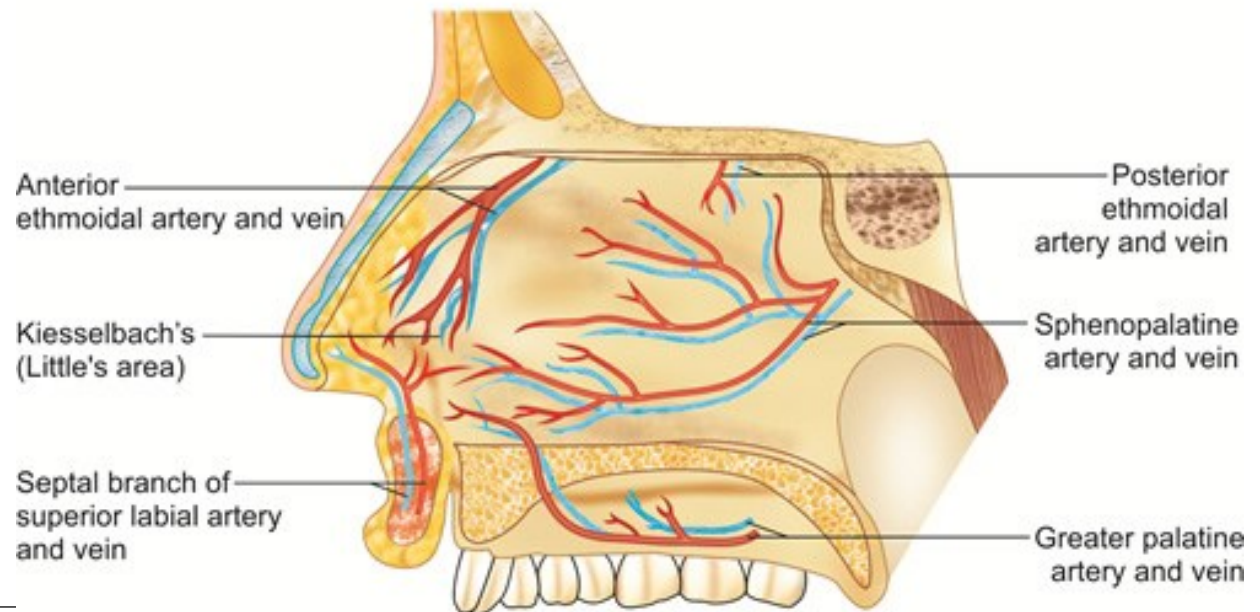
Blood Supply to the Nasal Cavity

The arterial supply to the nasal cavity is from branches of the maxillary, the ophthalmic, and the facial arteries.

The most important branch is the sphenopalatine artery.

The sphenopalatine artery anastomoses with the septal branch of the superior labial branch of the facial artery in the region of the vestibule. This is a common site of bleeding from the nose (epistaxis)

The submucous venous plexus is drained by veins that accompany the arteries. هذا الكلام موجود ب سنيل.



The arterial supply of the medial and lateral walls of the nasal cavity can be summarized as follow:

1. Anterior ethmoidal artery (a branch from the ophthalmic artery).
2. Posterior ethmoidal artery (a branch from the ophthalmic artery).
3. Sphenopalatine artery (a branch from the maxillary artery).
4. Greater palatine artery (a branch from the maxillary artery).
5. Septal branch of the superior labial artery (a branch from the facial artery).

The anterior part of the nasal septum is the site (Kiesselbach area) of an anastomotic arterial plexus involving all five arteries supplying the septum. The external nose receives blood from first and fifth arteries listed plus nasal branches of the infraorbital artery and the lateral nasal branches of the facial artery.

Venous Drainage of the Nasal Cavity

A rich submucosal venous plexus, deep to the nasal mucosa, provides venous drainage of the nose via the sphenopalatine, facial, and ophthalmic veins.

The plexus is an important part of the body's thermoregulatory system, exchanging heat and warming air before it enters the lungs.

Lymph Drainage of the Nasal Cavity

The lymph vessels draining the vestibule end in the submandibular nodes. The remainder of the nasal cavity is drained by vessels that pass to the upper deep cervical nodes.

The Paranasal Sinuses

The paranasal sinuses are cavities found in the interior of the maxilla, frontal, sphenoid, and ethmoid bones.

They are lined with mucoperiosteum and filled with air; they communicate with the nasal cavity through relatively small apertures.

The maxillary and sphenoidal sinuses are present in a rudimentary form at birth; they enlarge appreciably after the eighth year and become fully formed in adolescence.

Drainage of Mucus and Functions of Paranasal Sinuses:-

The mucus produced by the glands in the mucous membrane is moved into the nose by ciliary action of the columnar cells.

Drainage of the mucus is also achieved by the siphon action created during the blowing of the nose. The function of the sinuses is to act as resonators to the voice; they also reduce the weight of the skull. When the apertures of the sinuses are blocked or they become filled with fluid, the quality of the voice is markedly changed.

Maxillary Sinus

The maxillary sinus is pyramidal in shape and located within the body of the maxilla behind the skin of the cheek . The roof is formed by the floor of the orbit, and the floor is related to the roots of the premolars and molar teeth.

The maxillary sinus opens into the middle meatus of the nose through the hiatus semilunaris .

Frontal Sinuses

The two frontal sinuses are contained within the frontal bone. They are separated from each other by a bony septum. Each sinus is roughly triangular, extending upward above the medial end of the eyebrow and backward into the medial part of the roof of the orbit.

Each frontal sinus opens into the middle meatus of the nose through the infundibulum.

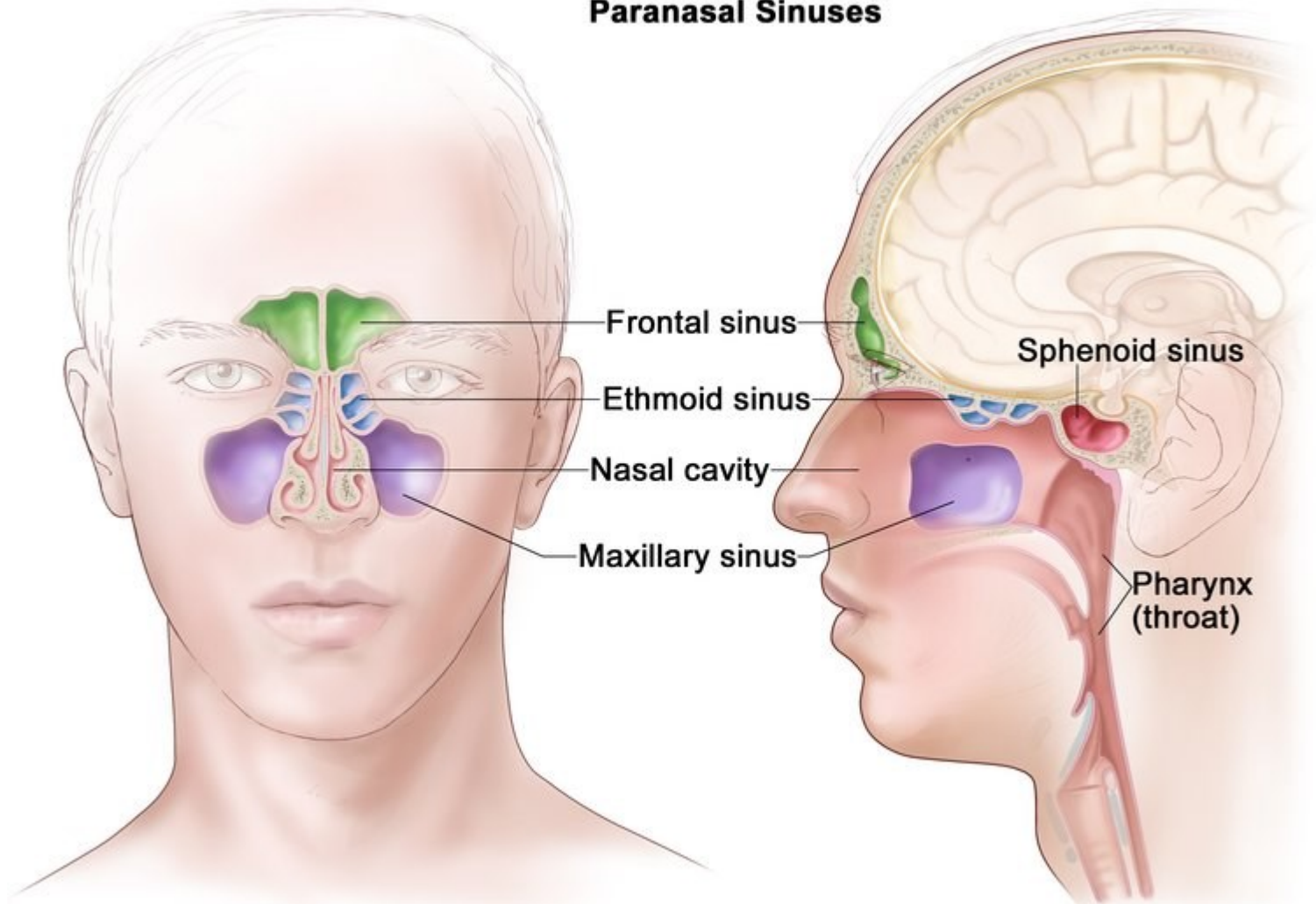
Sphenoidal Sinuses

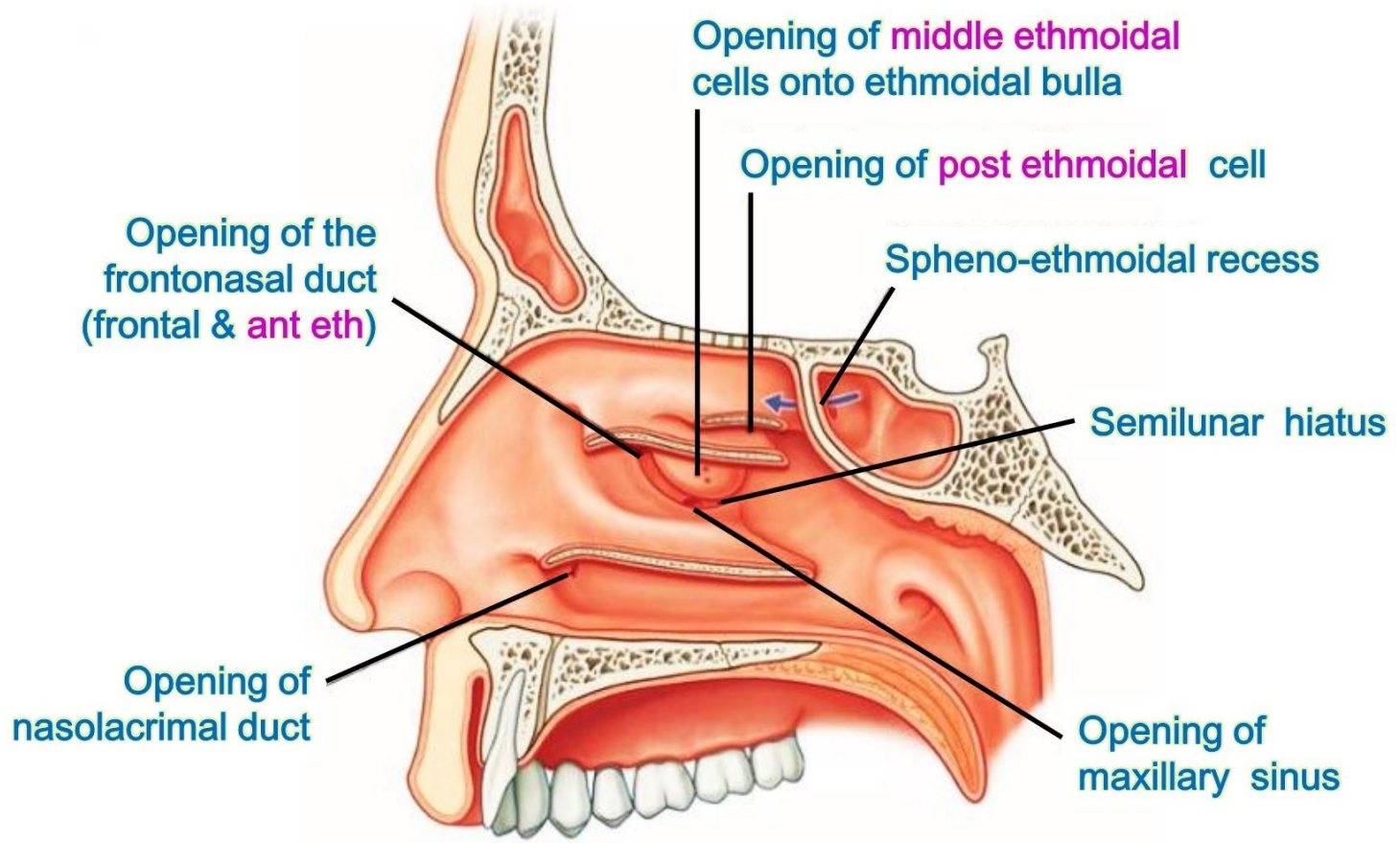
The two sphenoidal sinuses lie within the body of the sphenoid bone. Each sinus opens into the sphenoidal recess above the superior concha.

Ethmoid Sinuses

The ethmoidal sinuses are anterior, middle, and posterior and they are contained within the ethmoid bone, between the nose and the orbit. They are separated from the latter by a thin plate of bone so that infection can readily spread from the sinuses into the orbit. The anterior sinuses open into the infundibulum; the middle sinuses open into the middle meatus, on or above the bulla ethmoidalis; and the posterior sinuses open into the superior meatus.

Paranasal Sinuses





Infection of the Nasal Cavity

Infection of the nasal cavity can spread in a variety of directions.

The paranasal sinuses are especially prone to infection. Organisms may spread via the nasal part of the pharynx and the auditory tube to the middle ear.

It is possible for organisms to ascend to the meninges of the anterior cranial fossa, along the sheaths of the olfactory nerves through the cribriform plate, and produce meningitis.

Clinical Notes

Foreign bodies in the nose are common in children. It should be remembered that the nasal septum is rarely situated in the midline. A severely deviated septum may interfere with drainage of the nose and the paranasal sinuses.

□ Trauma to the Nose

Fractures involving the nasal bones are common. Blows directed from the front may cause one or both nasal bones to be displaced downward and inward. Lateral fractures also occur; the nasal septum is usually involved.

□ Nose Bleeding

Epistaxis, or bleeding from the nose, is a frequent condition. The most common cause is nose picking. The bleeding may be arterial or venous, and most episodes occur on the anteroinferior portion of the septum.

Sinusitis and the Examination of the Paranasal Sinuses

Infection of the paranasal sinuses is a common complication of nasal infections. Rarely, the cause of maxillary sinusitis is extension from an apical dental abscess. The frontal, ethmoidal, and maxillary sinuses can be palpated clinically for areas of tenderness.

The frontal sinus can be examined by pressing the finger upward beneath the medial end of the superior orbital margin. Here, the floor of the frontal sinus is closest to the surface.

The ethmoidal sinuses can be palpated by pressing the finger medially against the medial wall of the orbit.

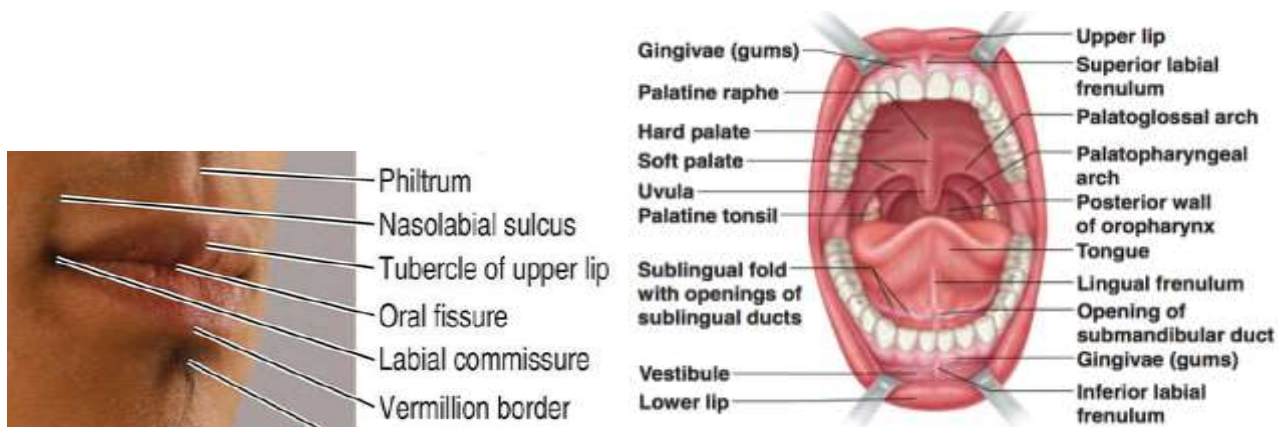
The maxillary sinus can be examined for tenderness by pressing the finger against the anterior wall of the maxilla below the inferior orbital margin; pressure over the infraorbital nerve may reveal increased sensitivity



Thank you

Lec [15]: The Oral Cavity

The Lips: are two fleshy folds that surround the oral orifice. They are covered on the outside by **skin** and are lined on the inside by **mucous membrane**. The substance of the lips is made up by the **orbicularis oris muscle** and the muscles that radiate from the lips into the face. Also included are the **labial blood vessels** and **nerves**, **connective tissue**, and many **small salivary glands**.



The **philtrum**: is the shallow vertical groove seen in the midline on the outer surface of the upper lip.

The labial frenulae: Median folds of mucous membrane connect the inner surface of the lips to the gums.

Nerve supply: motor fibers from **facial nerve** and sensory fibers from **mental branch of the inferior alveolar** and the **infraorbital branch of the maxillary nerve**; the last two also supply the **red margin** of the lower and upper lips respectively.

The Mouth Cavity [oral cavity]:

The mouth extends from the **lips** to the **pharynx**. The entrance into the pharynx, the **oropharyngeal isthmus**, is formed on each side by the **palatoglossal fold**. The mouth is divided into the **vestibule** and the **mouth cavity proper**.

1/ Vestibule:

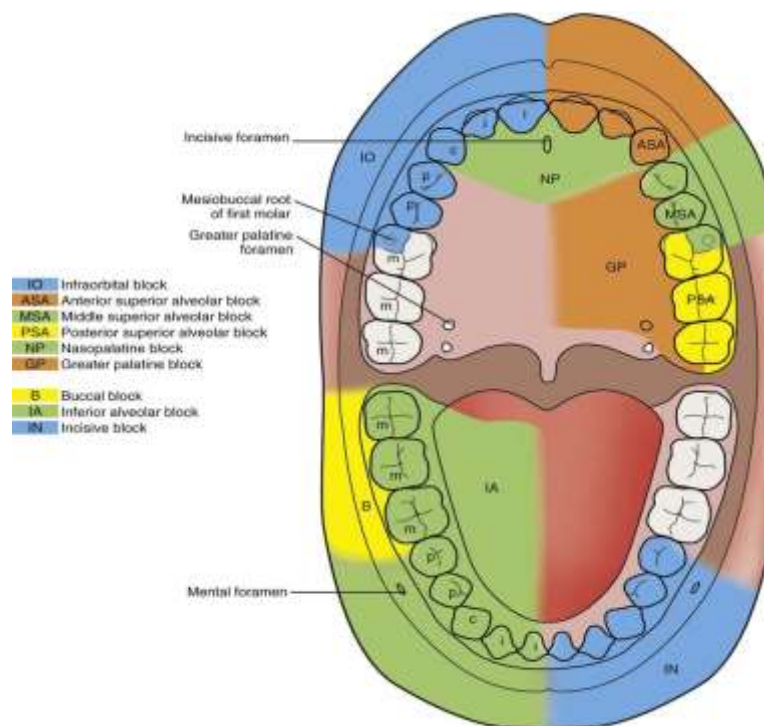
lies between the **lips** and the **cheeks** externally and the **gums** and the **teeth** internally. This slit like space communicates with the exterior through the **oral fissure**

between the lips. When the jaws are closed, it communicates with the **mouth proper** behind the third molar tooth on each side. The **duct** of the **parotid salivary gland** opens on a **small papilla** into **the vestibule** opposite the **upper second molar tooth**.

Mucous Membrane of the Mouth:

In the **vestibule**, the mucous membrane is tethered to the **buccinator muscle** by elastic fibers in the submucosa that prevent excessive folds of mucous membrane from being bitten between the teeth when the jaws are closed. **The mucous membrane of the gingiva, or gum**, is strongly attached to the **alveolar periosteum**.

Nerve supply:



Cheek: The skin and mucous membrane supplied by **buccal nerve [long buccal]**, a branch of the **mandibular** division of the **trigeminal nerve** and mental nerve (the **buccinator muscle** is innervated by the **buccal branch of the facial nerve**).

Buccal gum: superiorly by **posterior and middle superior alveolar** nerves (branches of maxillary nerve). Inferiorly, by **buccal branch** of mandibular nerve.

Labial gum: **infraorbital and mental** nerves for upper and lower respectively.

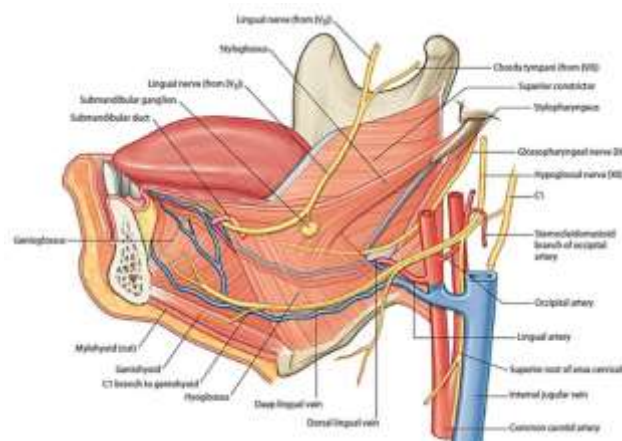
Upper and lower teeth: The upper teeth are supplied by the **superior alveolar nerves** [**anterior, middle and posterior**].

In the lower jaw the molars and premolars are supplied by the main trunk of the **inferior alveolar nerve**, whose terminal **incisor branch** supplies the **canine and incisors**, overlapping to the opposite central incisor.

2/ Mouth Proper: has a floor and a roof.

Floor of Mouth, is formed largely by the **anterior two thirds of the tongue** and by the reflection of the **mucous membrane** from the sides of the tongue to the **gum** of the **mandible**.

A fold of mucous membrane called the **frenulum of the tongue** [lingual frenulum] connects the **undersurface of the tongue** in the midline to the **floor of the mouth**. The **duct of the submandibular gland** opens onto the floor of the mouth on the summit of a small papilla on either side of the **frenulum of the tongue**. The **sublingual gland** projects up into the mouth, producing a **low fold of mucous membrane**, the **sublingual fold**. Numerous ducts of the gland open on the summit of the fold.



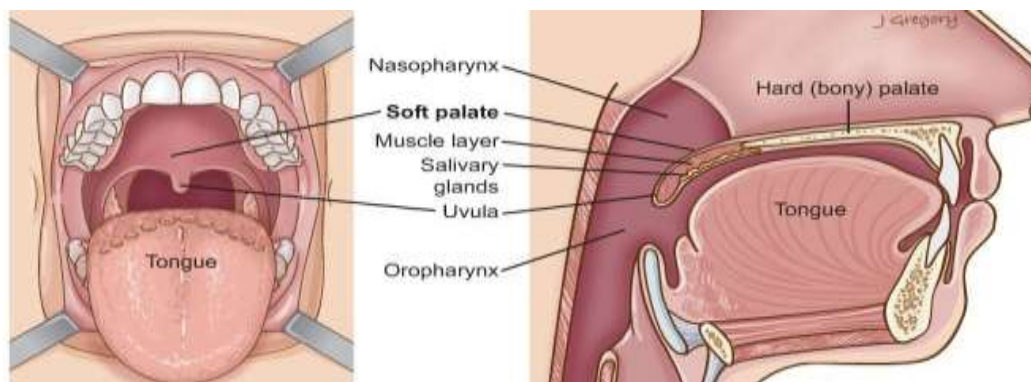
Nerve supply:

The **lingual nerve (common sensation)**, a branch of the mandibular division of the trigeminal nerve. **The taste fibers** from anterior 2/3 of travel in the **chorda tympani**

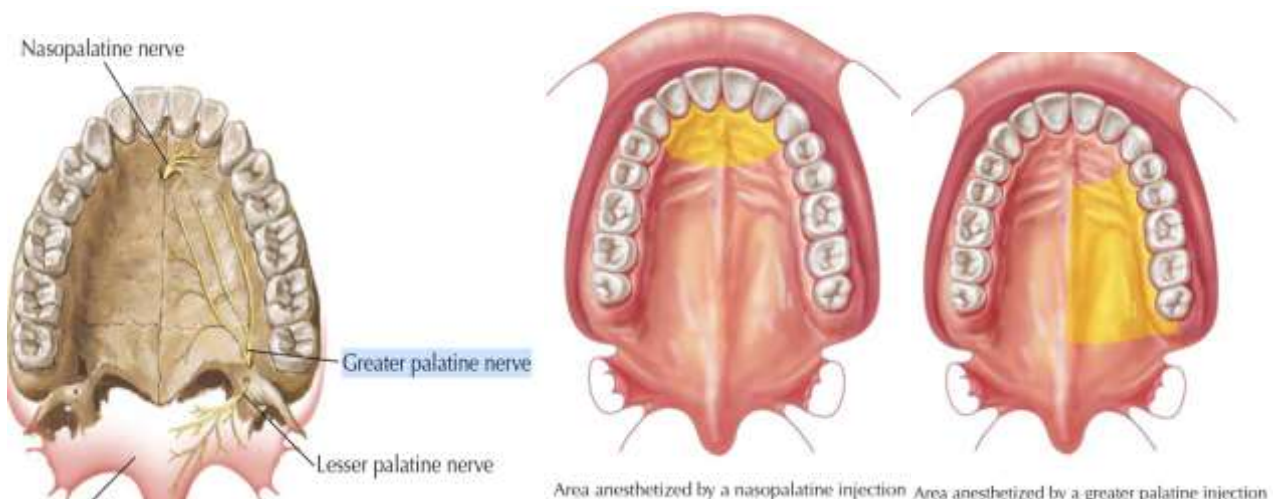
nerve, a branch of the facial nerve. **Motor innervation** mainly from **hypoglossal nerve XII**.

Roof of Mouth: is formed by the palate (forms the roof of the mouth and the floor of the nasal cavity). It is divided into two parts, the **hard palate** in front and the **soft palate** behind.

Hard Palate: The hard palate is formed by the palatine processes of the maxillae and the horizontal plates of the palatine bones. It is continuous posteriorly with the soft palate.



Nerve supply: The **greater palatine and nasopalatine** nerves from the maxillary division of the trigeminal nerve.



Blood supply: The **greater palatine artery** branch of descending palatine artery.

Venous drainage: **pterygoid venous plexuses**.

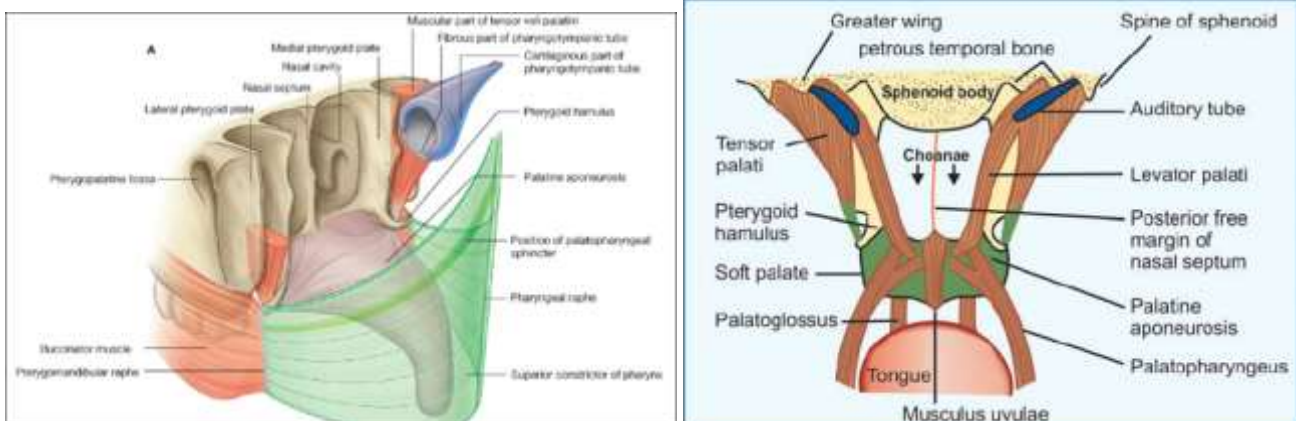
Lymphatic drainage: submandibular lymph nodes then to deep cervical lymph nodes

Soft Palate: Is a mobile fold attached to the posterior border of the hard palate. Its free posterior border presents in the midline a conical projection called the uvula. The soft palate is continuous at the sides with the **lateral wall of the pharynx**. The soft palate is composed of **mucous membrane, palatine aponeurosis, and muscles**.

Mucous Membrane: The mucous membrane covers the upper and lower surfaces of the soft palate.

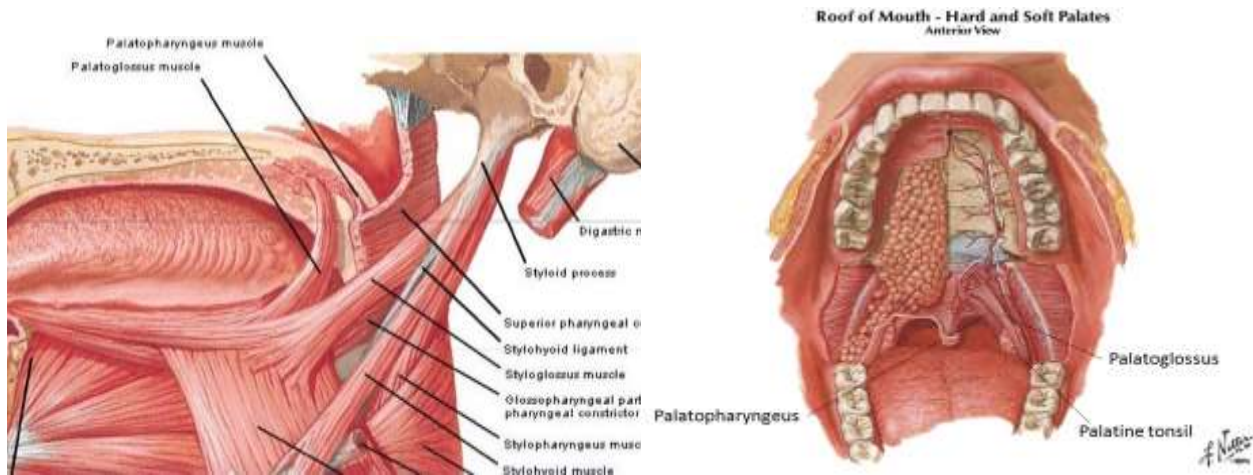
Palatine Aponeurosis

The palatine aponeurosis is a fibrous sheet attached to the posterior border of the hard palate. It is the expanded tendon of the tensor veli palatini muscle. The muscle fibers of the **tensor veli palatini** converge as they descend from their origin to form a narrow tendon, which turns medially around the **pterygoid hamulus**. The tendon, together with the tendon of the opposite side, expands to form the **palatine aponeurosis**. When the muscles of the two sides contract, the soft palate tightens so that it may move upward or downward as a tense sheet.



Muscles of the Soft Palate

The muscles of the soft palate are the **tensor veli palatini**, the **levator veli palatini**, the **palatoglossus**, the **palatopharyngeus**, and the **uvula**.



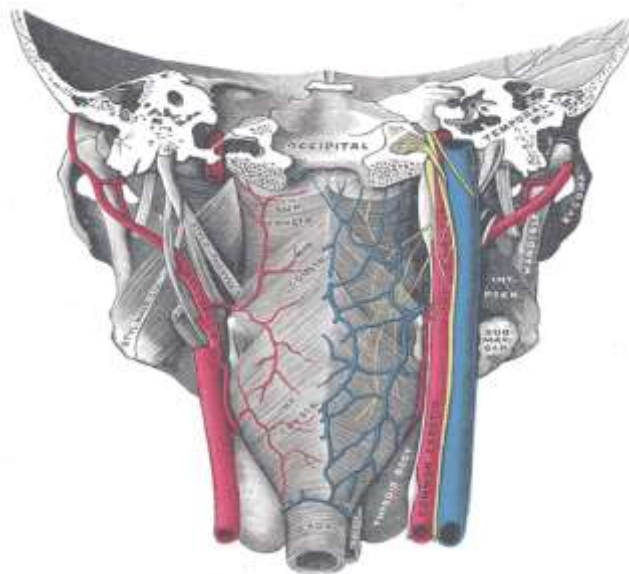
Muscles of the Soft Palate				
Muscle	Origin	Insertion	Nerve Supply	Action
Tensor veli palatini	Spine of sphenoid, auditory tube	With muscle of other side, forms palatine aponeurosis	Nerve to medial pterygoid from mandibular nerve	Tenses soft palate
Levator veli palatini	Petrous part of temporal bone, auditory tube	Palatine aponeurosis	Pharyngeal plexus	Raises soft palate
Palatoglossus	Palatine aponeurosis	Side of tongue	Pharyngeal plexus	Pulls root of tongue upward and backward, narrows oropharyngeal isthmus
Palatopharyngeus	Palatine aponeurosis	Posterior border of thyroid cartilage	Pharyngeal plexus	Elevates wall of pharynx, pulls palatopharyngeal folds medially
Musculus uvulae	Posterior border of hard palate	Mucous membrane of uvula	Pharyngeal plexus	Elevates uvula

Two arches extend off each side of the **soft palate**. The **palatoglossal arch** is a fold of mucous membrane containing the **palatoglossus muscle**, which extends from the **soft palate to the side of the tongue**. The **palatoglossal arch** marks where the oral cavity becomes the pharynx. The **palatopharyngeal arch** is a fold of mucous membrane behind the palatoglossal arch that runs downward and laterally to join the **pharyngeal wall**. This arch contains the **palatopharyngeus** muscle. The **palatine tonsils**, which are masses of lymphoid tissue, are located in the **tonsillar fossa** between the **palatoglossal and palatopharyngeal arches**.

Nerve supply:

Motor: All the muscles of the soft palate are supplied by the **pharyngeal plexus** except for **tensor palati**, which is supplied by a branch from the nerve to the **medial pterygoid (from the mandibular branch of the trigeminal nerve)**.

Parasympathetic and taste fibers and sensory: Postganglionic secretomotor fibers to the palatal glands run with the **lesser palatine nerves**, these nerves also carry **taste fibers** (cell bodies in geniculate ganglion) from the few taste buds on the oral surface of the soft palate. **Common sensation** from the mucous membrane of the soft palate is transmitted by the lesser palatine nerves also. On the oral surface there is slight overlap of **glossopharyngeal sensory** fibers from the lateral wall of the pharynx.

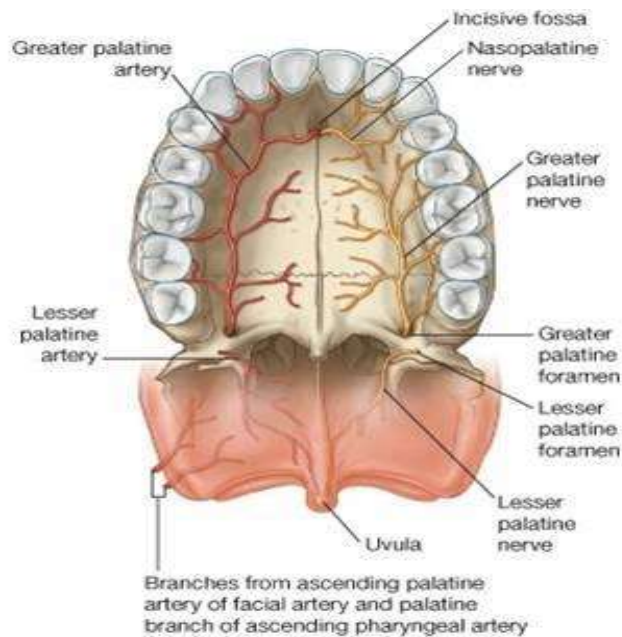
The pharyngeal plexus fibers:

1 – pharyngeal branches of glossopharyngeal nerve – sensory

2 – pharyngeal branch of vagus nerve – motor

3- superior cervical ganglion sympathetic fibers – vasomotor

Because the cranial part of accessory nerve (CN XI) leaves the jugular foramen as a part of the CN X, it is sometimes considered part of the plexus as well.



Blood supply:

1-Lesser palatine branches of the maxillary artery.

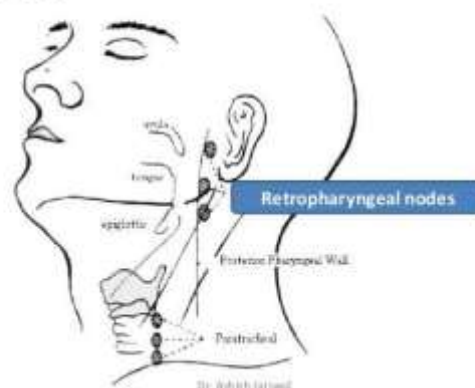
2-Ascending palatine branch of the facial artery.

3-Palatine branches of the ascending pharyngeal artery

The venous drainage: passes through the pharyngeal wall into the **pharyngeal venous plexus** and the **pterygoid plexus**.

Retropharyngeal Nodes

• Location :



muhadharaty.com

Lymph drainage:

Lymphatics from the soft palate empty into **retropharyngeal** lymph nodes then to **deep cervical lymph nodes**.

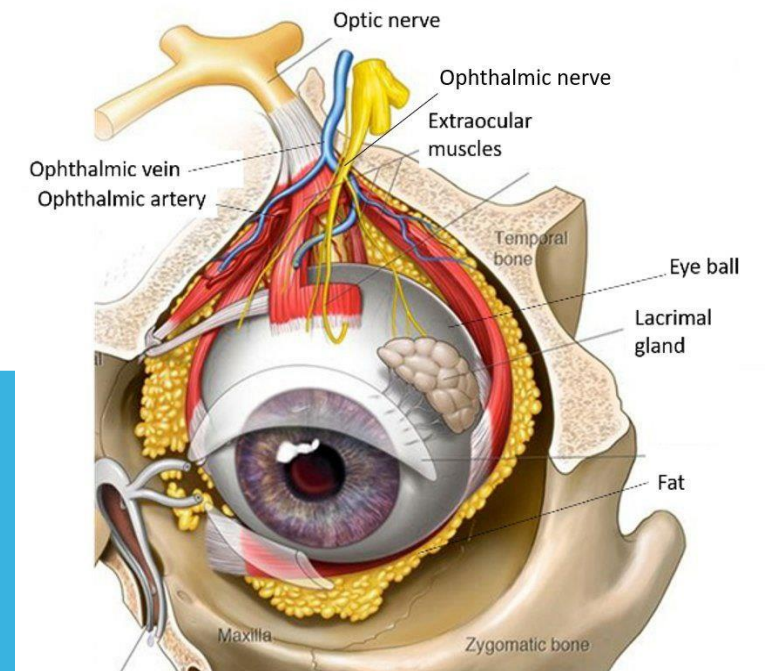
HUMAN ANATOMY

THE ORBITAL REGION

ASSIS. LEC. NOOR GHAZI

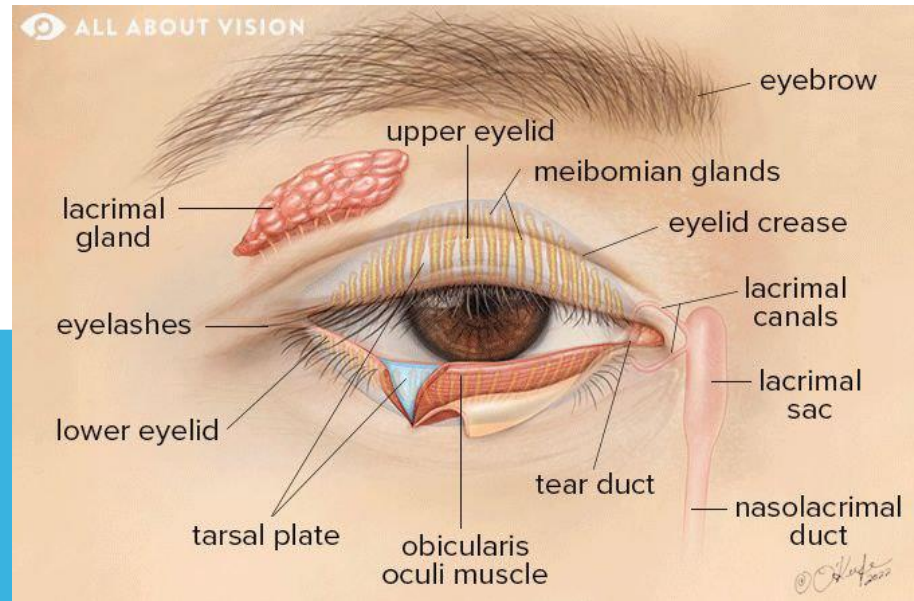
THE ORBITAL REGION

The orbits are a pair of bony cavities that contain the eyeballs; their associated muscles, nerves, vessels, and fat; and most of the lacrimal apparatus. The orbital opening is guarded by two thin, movable folds, the eyelids.



EYELIDS

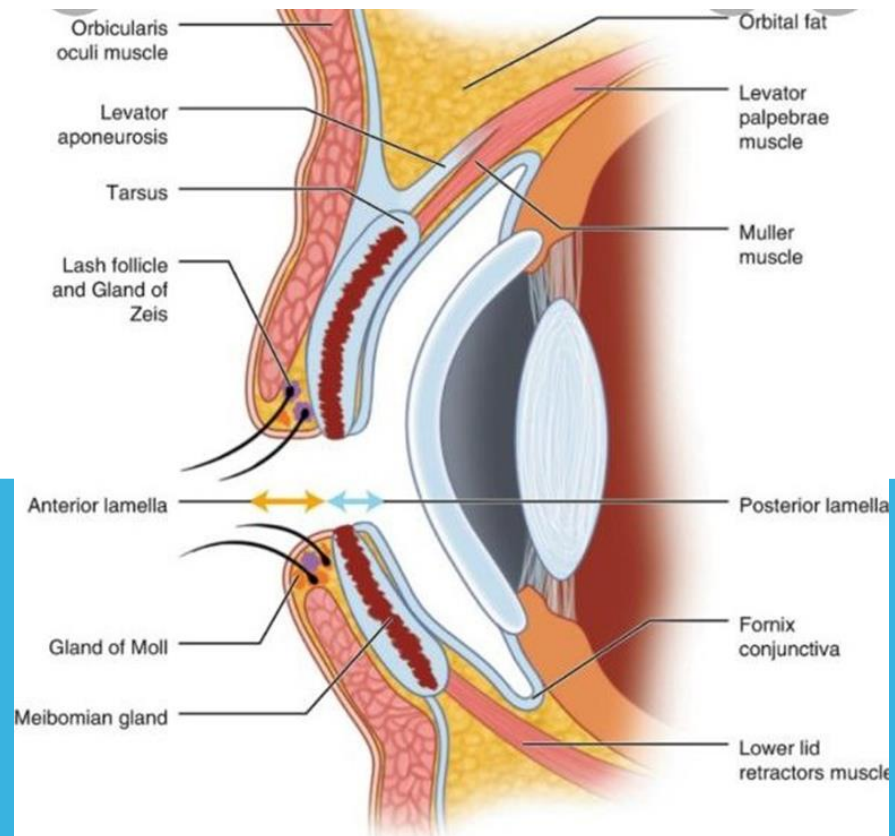
The eyelids protect the eye from injury and excessive light by their closure. The upper eyelid is larger and more mobile than the lower, and they meet each other at the **medial** and **lateral angles**. The **palpebral fissure** is the elliptical opening between the eyelids and is the entrance into the conjunctival sac. The superficial surface of the eyelids is covered by skin, and the deep surface is covered by a mucous membrane called the conjunctiva.



**The eyelashes are short, curved hairs on the free edges of the eyelids. They are arranged in double or triple rows at the mucocutaneous junction. The sebaceous glands (glands of Zeis) open directly into the eyelash follicles.

**The ciliary glands (glands of Moll) are modified sweat glands that open separately between adjacent lashes.

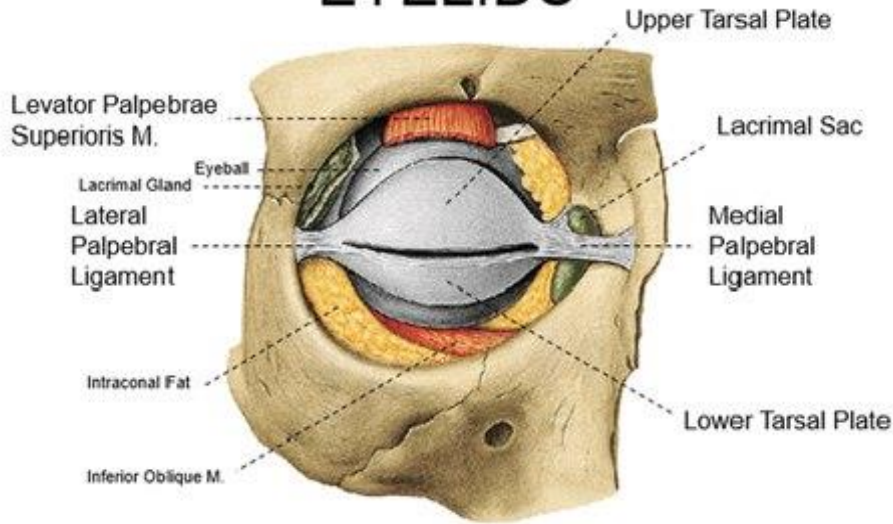
**The tarsal glands (Meibomian glands) are long, modified sebaceous glands that pour their oily secretion onto the margin of the lid; their openings lie behind the eyelashes. This oily material prevents the overflow of tears and helps make the closed eyelids airtight.



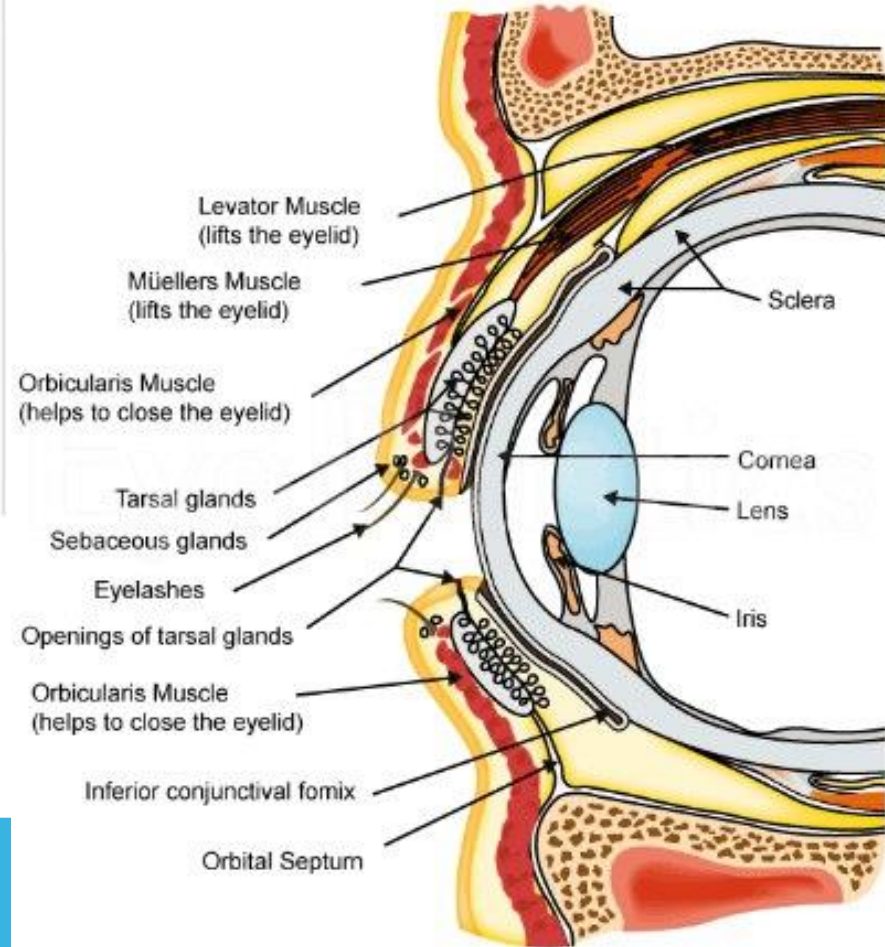
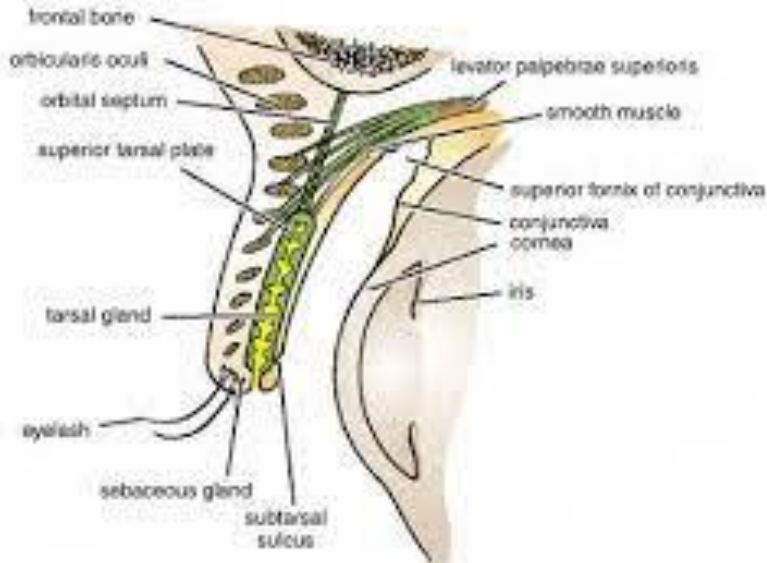
The fibrous framework of the eyelids is formed by a membranous sheet, the **orbital septum**, which thickened at the margins of the lids to form the **superior and inferior tarsal plates**. The lateral ends of the plates are attached by a band, the **lateral palpebral ligament** to a bony tubercle just within the orbital margin. The medial ends of the plates are attached by a band the **medial palpebral ligament** to the crest of the lacrimal bone.

The **conjunctiva** is a thin mucous membrane that lines the eyelids and is reflected at the superior and inferior fornices onto the anterior surface of the eyeball. The conjunctiva thus forms a potential space, the conjunctival sac, which is open at the palpebral fissure. Beneath the eyelid is a groove, the subtarsal sulcus, which tends to trap small foreign particles introduced into the conjunctival sac and is thus clinically important.

EYELIDS



Booth, Atlas of Human Anatomy, 13th English Ed., version 1, CD-ROM



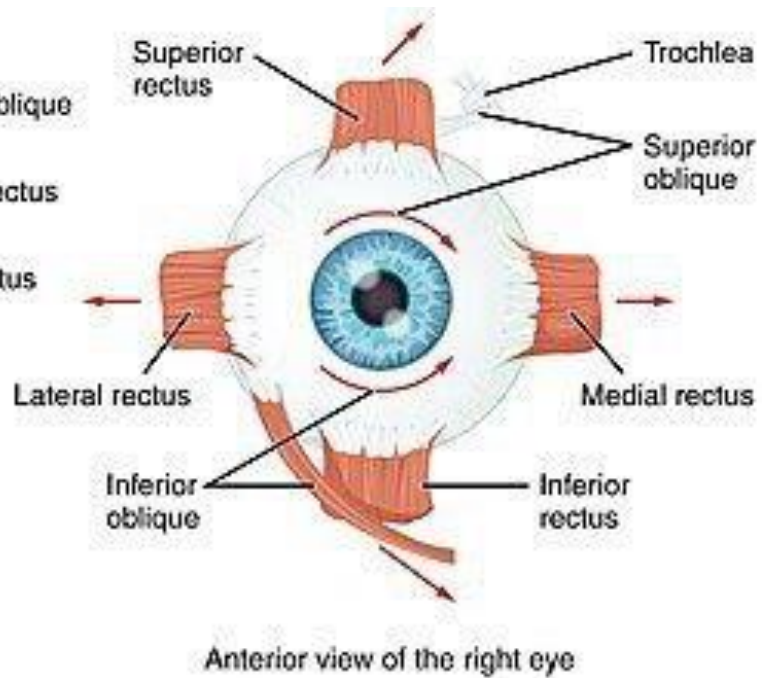
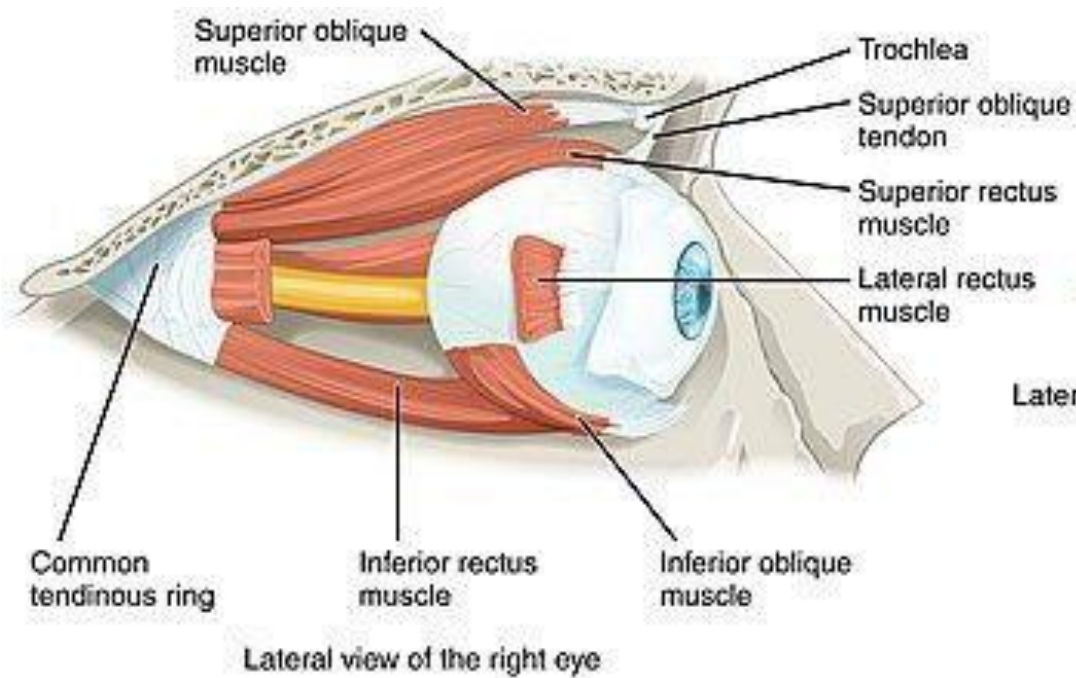
Movements of the Eyelids

The eyelids are **closed** by the contraction of the orbicularis oculi and the relaxation of the levator palpebrae superioris muscles. The eye is **opened** by the levator palpebrae superioris raising the upper lid. On looking **upward**, the levator palpebrae superioris contracts, and the upper lid moves with the eyeball. On looking **downward**, both lids move, the upper lid continues to cover the upper part of the cornea, and the lower lid is pulled downward slightly by the conjunctiva, which is attached to the sclera and the lower lid.

The origins and insertions of the muscles of the eyelids are summarized in this table :-

1. Extrinsic muscle of eyeball(striated skeletal muscle)

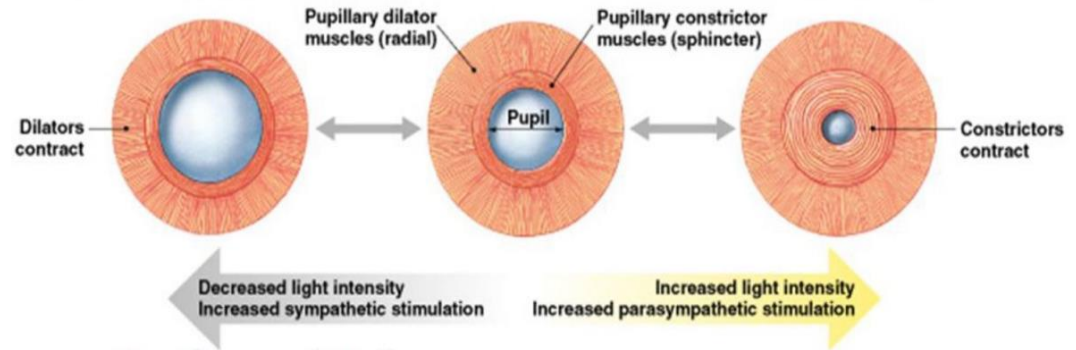
Muscle	Origin	Insertion	Nerve supply	Action
Superior rectus	Tendinous ring on the posterior wall of orbital cavity	Superior surface of the eyeball just posterior to corneoscleral junction	Oculomotor Nerve 3 rd C.N	Raises cornea upward and medially
Inferior rectus	Tendinous ring on the posterior wall of orbital cavity	Inferior surface of the eyeball just posterior to corneoscleral junction	3 rd C. N	Depresses cornea downward and medially
Medial rectus	Tendinous ring on the posterior wall of orbital cavity	Medial surface of the eyeball just posterior to corneoscleral junction	3 rd C. N	Rotates eyeball so that cornea looks medially
Lateral rectus	Tendinous ring on the posterior wall of orbital cavity	Lateral surface of the eyeball just posterior to corneoscleral junction	Abducent nerve 6 th C.N	Rotates eyeball so that cornea looks laterally
Superior oblique	Posterior wall of orbital cavity	Passes through pulley and is attached to superior surface of eyeball beneath superior rectus	Trochlear nerve 4 th C.N	Rotates eyeball so that cornea looks downward and laterally
Inferior oblique	Floor of the orbital cavity	Lateral surface of eyeball deep to lateral rectus	3 rd C.N	Rotates eyeball so that cornea looks upward and laterally



2. Intrinsic muscles of eyeball (smooth muscle)

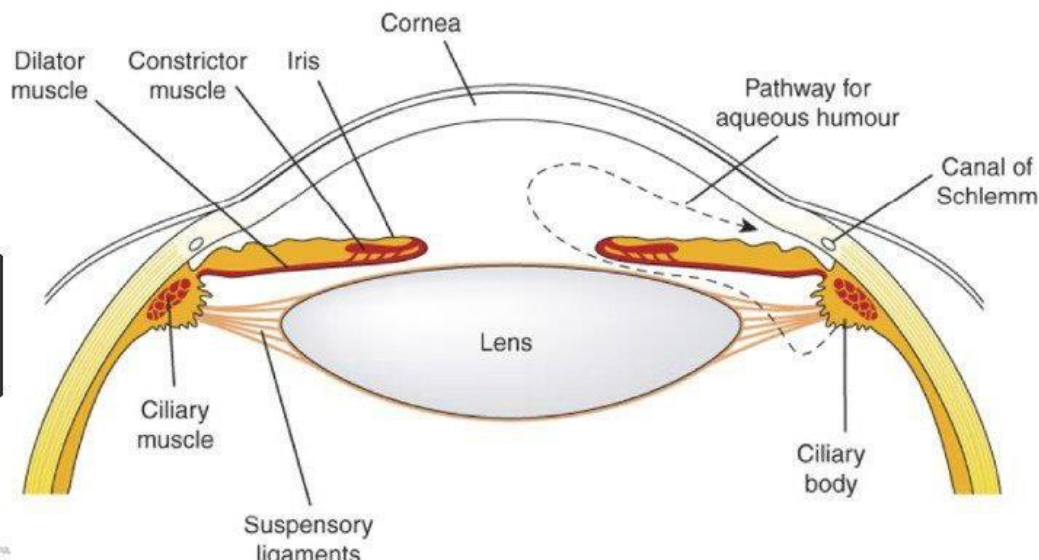
Muscle	origin	Inesrtion	Nerve supply	Action
Sphincter pupillae of iris			Parasympathetic by oculomotor nerve	Constricts pupil
Dilator pupillae of iris			Sympathetic	Dilates pupil
Ciliary muscle			Parasympathetic by oculomotor nerve	Controls shape of lens in accommodation, makes lens more globular

Intrinsic Eye Muscles of the Iris



- **Pupils constrict** (Parasympathetic)
 - Close vision and bright light
- **Pupils dilate** (Sympathetic)
 - Distant vision and dim light

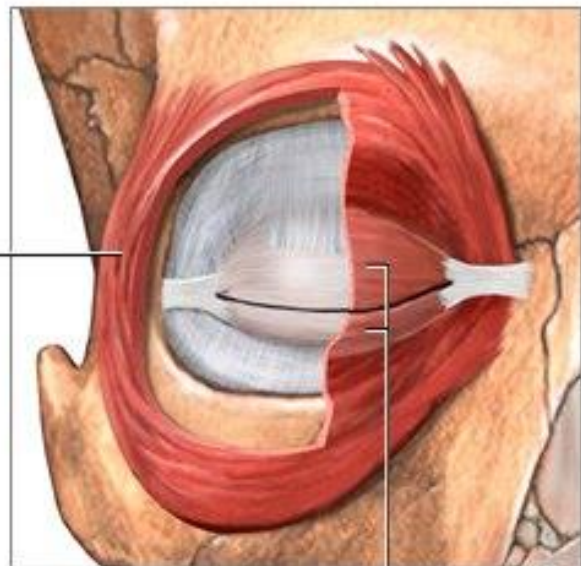
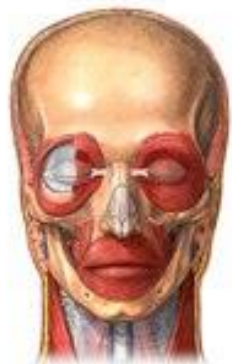10



3. Muscles of eyelids

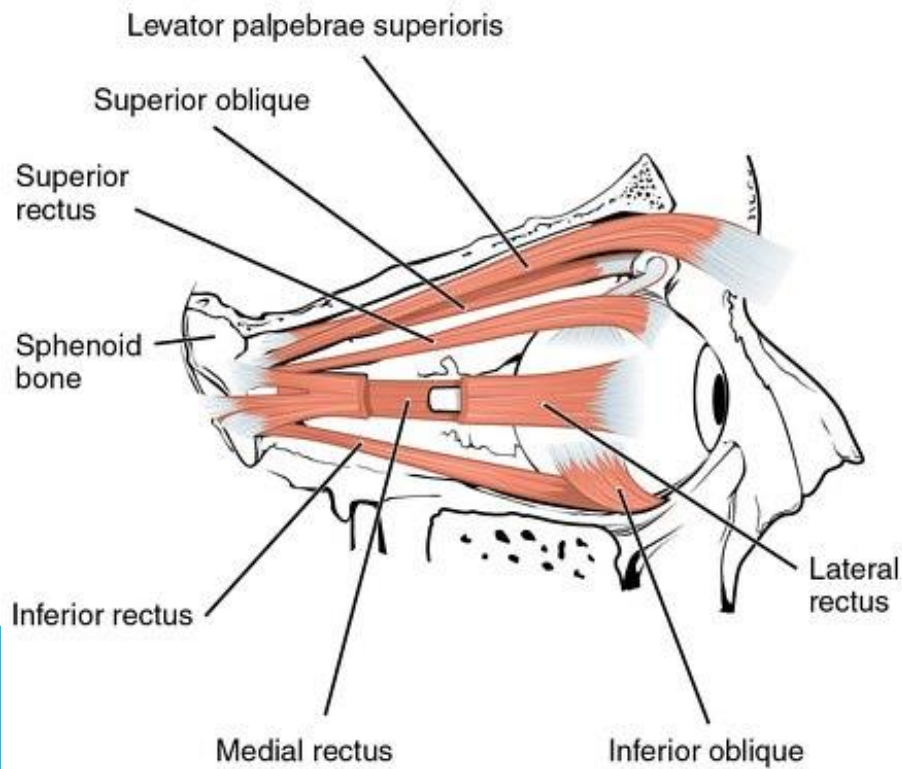
<p>Orbicularis oculi</p> <ul style="list-style-type: none"> -Palpebral part -Orbital part 	<p>Medial palpebral ligament</p> <p>Medial palpebral ligament and adjoining bone</p>	<p>Lateral palpebral raphe</p> <p>Loops return to origin</p>	<p>Facial nerve</p> <p>Facial nerve</p>	<p>Closes eyelids and dilates lacrimal sac</p> <p>Throws skin around orbit into folds to protect eyeball</p>
<p>Levator palpebrae superioris</p>	<p>Back of the orbital cavity</p>	<p>Anterior surface and upper margin of superior tarsal plate</p>	<p>Striated muscle: oculomotor nerve</p> <p>smooth muscle: sympathetic</p>	<p>Raises upper lid</p>

Orbicularis oculi
(Orbital part)



Orbicularis oculi
(Palpebral part)

ADAM.



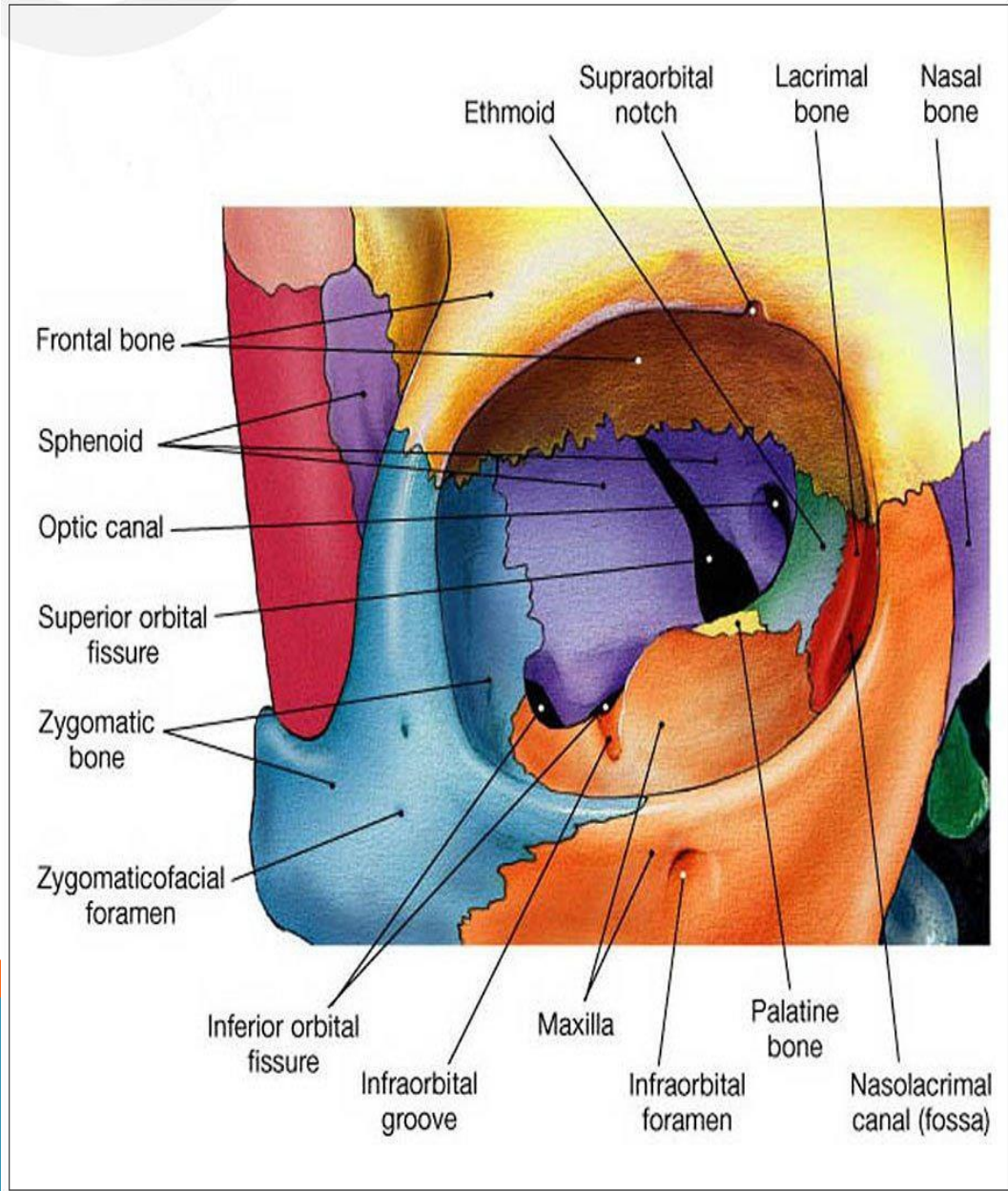
Openings into the Orbital Cavity

Orbital opening: Lies anteriorly. About one sixth of the eye is exposed; the remainder is protected by the walls of the orbit.

Supraorbital notch (Foramen): It is situated on the superior orbital margin and transmits the supraorbital nerve and blood vessels.

Infraorbital groove and canal: Situated on the floor of the orbit in the orbital plate of the maxilla; they transmit the infraorbital nerve and blood vessels.

Nasolacrimal canal: Located anteriorly on the medial wall; it communicates with the inferior meatus of the nose . It transmits the nasolacrimal duct.



Superior orbital fissure: Located posteriorly between the greater and lesser wings of the sphenoid ; it communicates with the middle cranial fossa. It transmits the oculomotor nerve (upper and lower divisions), the trochlear nerve, three branches of ophthalmic nerve(lacrimal, the frontal and nasociliary nerves), the abducent nerve, and the superior ophthalmic vein.

Inferior orbital fissure: Located posteriorly between the maxilla and the greater wing of the sphenoid; it communicates with the pterygopalatine fossa. It transmits the maxillary nerve and its zygomatic branch, the inferior ophthalmic vein, and sympathetic nerves.

Optic canal: Located posteriorly in the lesser wing of the sphenoid; it communicates with the middle cranial fossa. It transmits the optic nerve and the ophthalmic artery.

Nerves of the Orbit

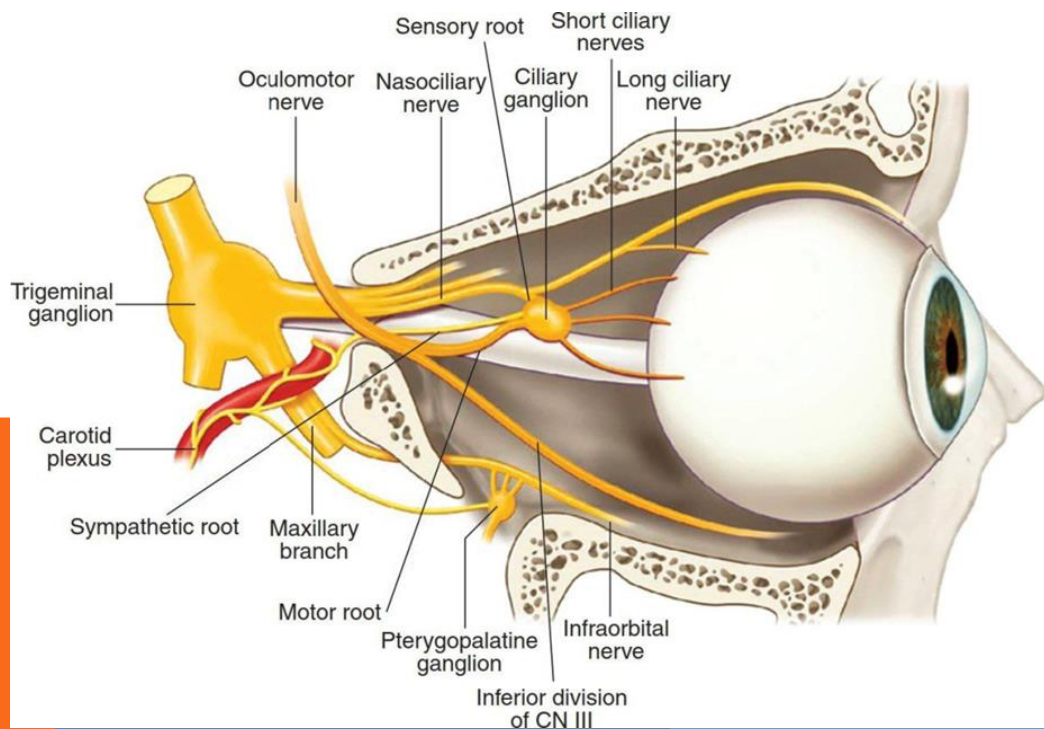
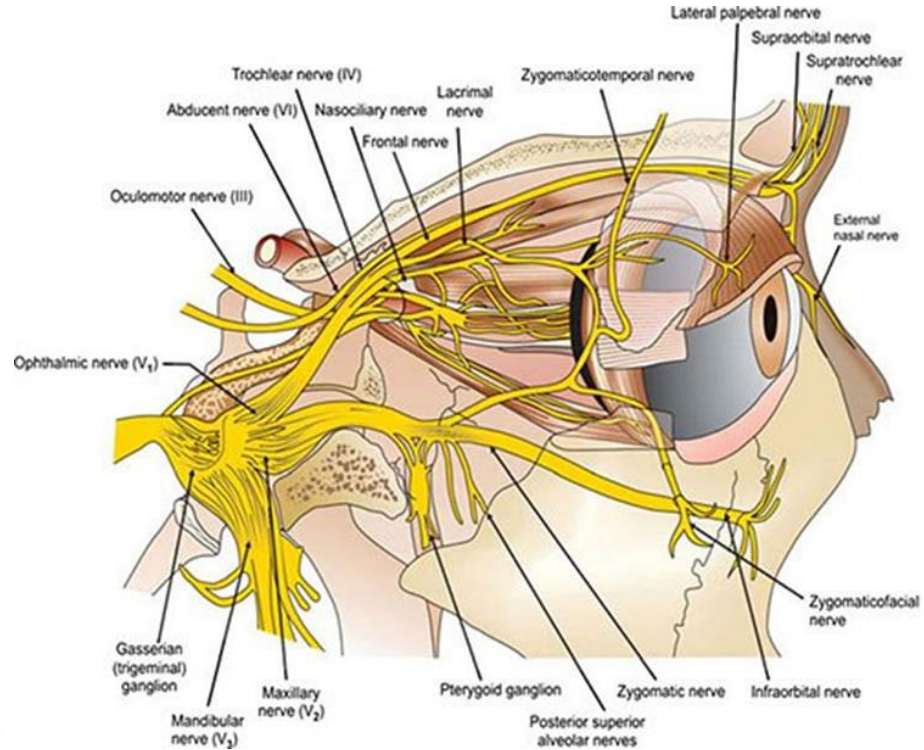
□ **Optic Nerve**

The nerve enters the orbit from the middle cranial fossae by passing through the optic canal, it is surrounded by sheaths of pia mater, arachnoid mater, and dura mater. Here, the meninges fuse with the sclera (so that the CSF in the subarachnoid space extend forward from the middle cranial fossae to the eyeball); a rise in pressure of the cerebrospinal fluid (CSF) within the cranial cavity therefore is transmitted to the back of the eyeball.

□ **Lacrimal Nerve**

The lacrimal nerve arises from the ophthalmic division of the trigeminal nerve. It is joined by a branch of the zygomaticotemporal nerve, which later leaves it to enter the lacrimal gland (parasympathetic secretomotor fibers). The lacrimal nerve ends by supplying the skin of the lateral part of the upper lid.

□ **Frontal Nerve** The frontal nerve arises from the ophthalmic division of the trigeminal nerve, then divides into the **supratrochlear** and **supraorbital** nerves that supply the skin of the forehead; the supraorbital nerve also supplies the mucous membrane of the frontal air sinus.



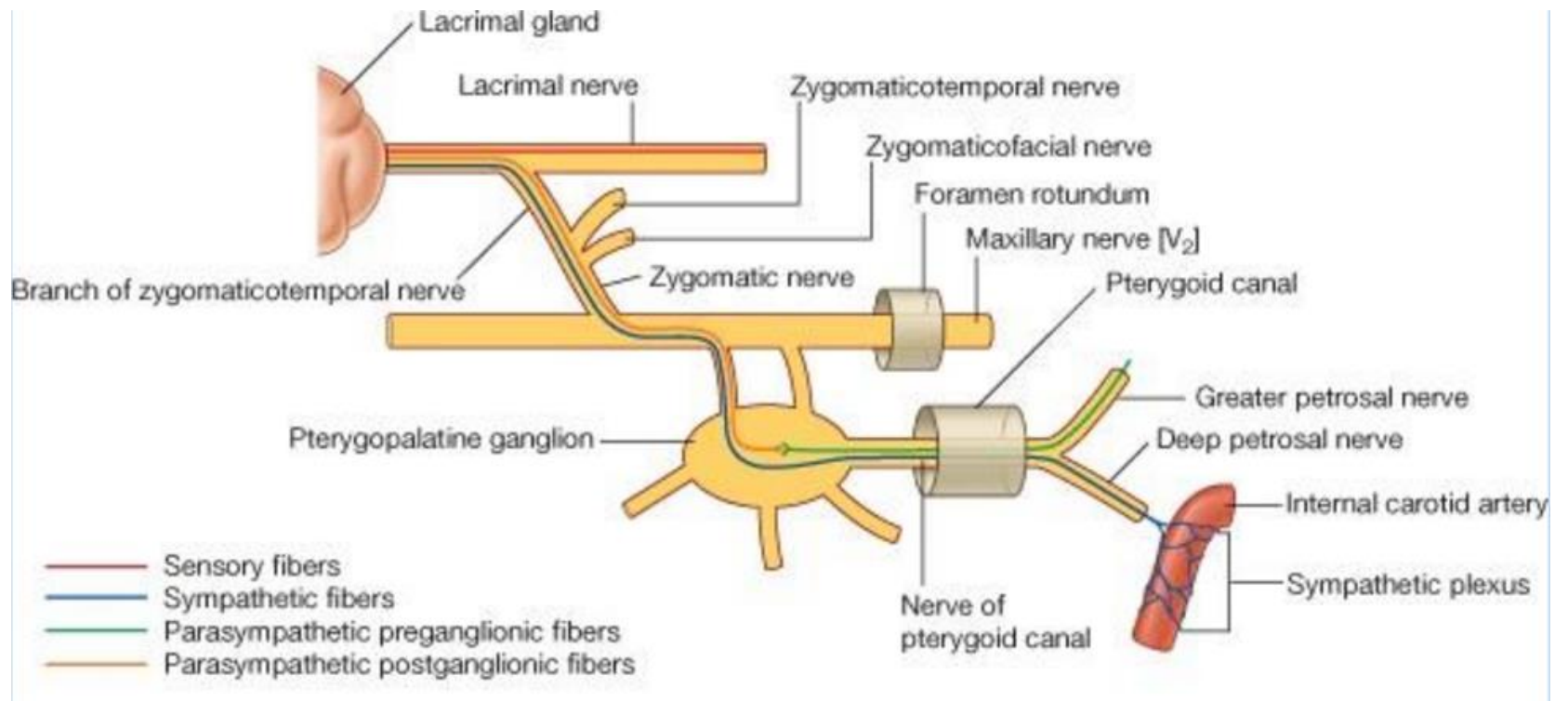
□ **Trochlear Nerve** supplies the superior oblique muscle.

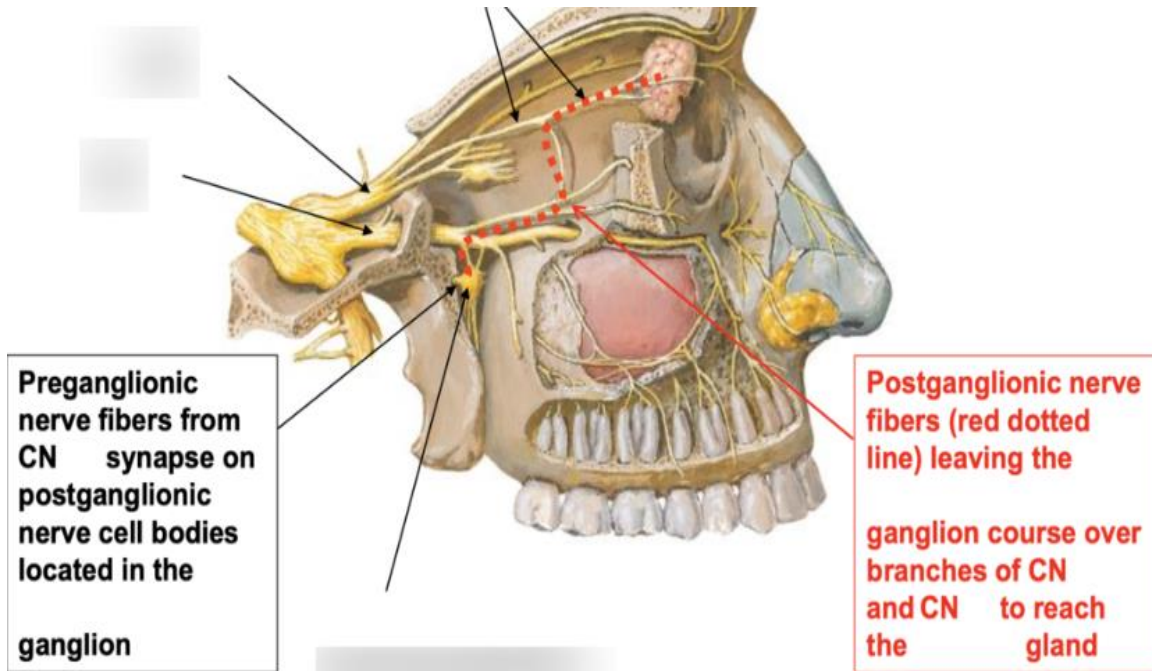
□ **Oculomotor Nerve.** The **superior ramus** of the oculomotor nerve supplies the superior rectus muscle, then pierces it, and supplies the levator palpebrae superioris muscle.

The **inferior ramus of the oculomotor nerve supplies the inferior rectus, the medial rectus, and the inferior oblique muscles. The nerve to the inferior oblique gives off a branch that passes to the ciliary ganglion and carries parasympathetic fibers to the sphincter pupillae and the ciliary muscle.

□ **Abducent Nerve** It supplies the lateral rectus muscle.

□ **Nasociliary Nerve** The nasociliary nerve arises from the ophthalmic division of the trigeminal nerve; provides sensory information to the cornea, eyelids, and the cell of nasal cavity.

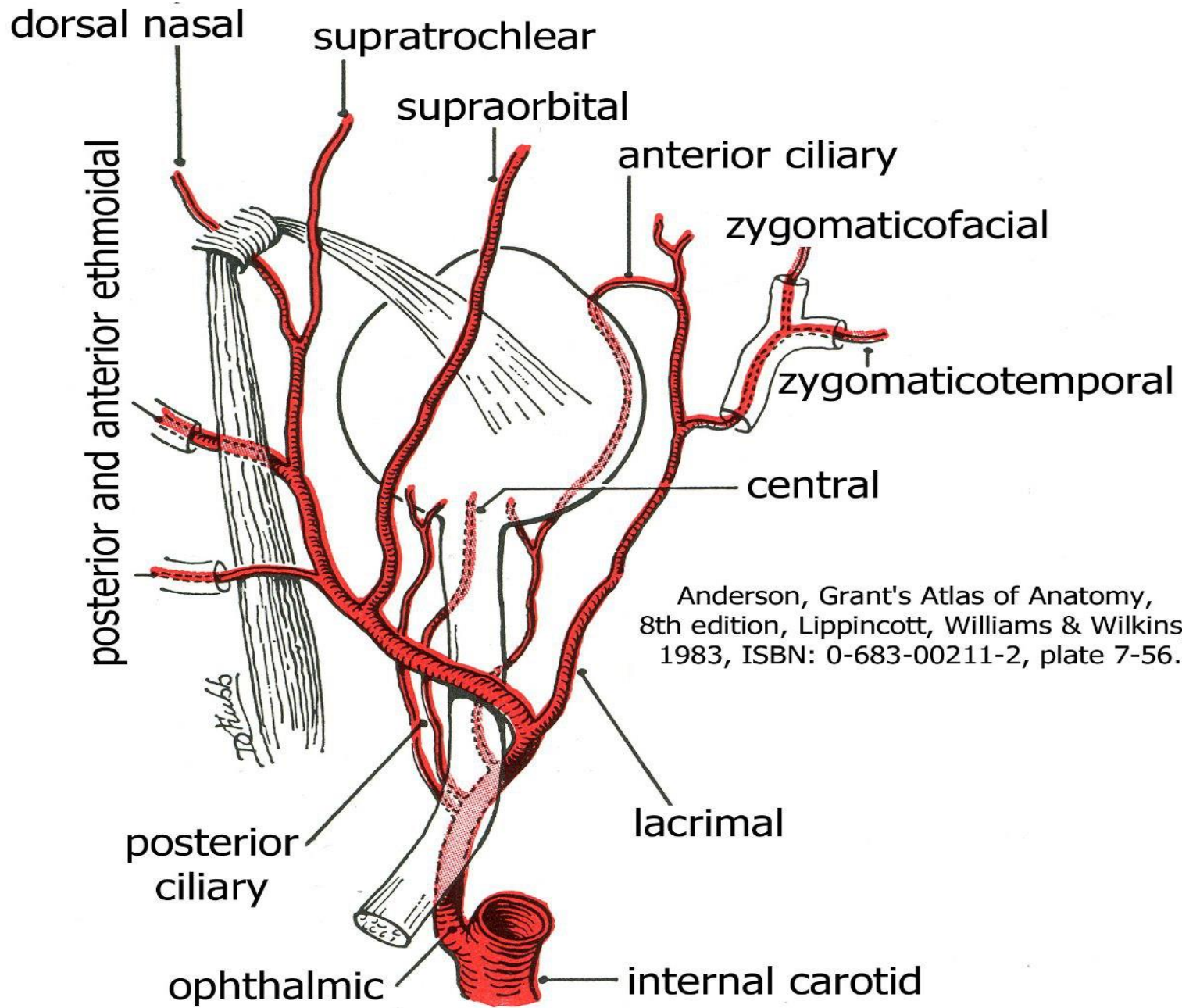




Blood and Lymph Vessels of the Orbit

□ **Ophthalmic Artery** The ophthalmic artery is a branch of the internal carotid artery. It enters the orbit through the optic canal with the optic nerve. It has the following branches:

1. The **central artery of the retina** enters the eyeball at the center of the optic disc.
2. The **muscular branches**.
3. The **ciliary arteries** can be divided into anterior and posterior groups.
4. The **lacrimal artery** to the lacrimal gland.
5. The **supratrochlear** and **supraorbital** arteries are distributed to the skin of the forehead.

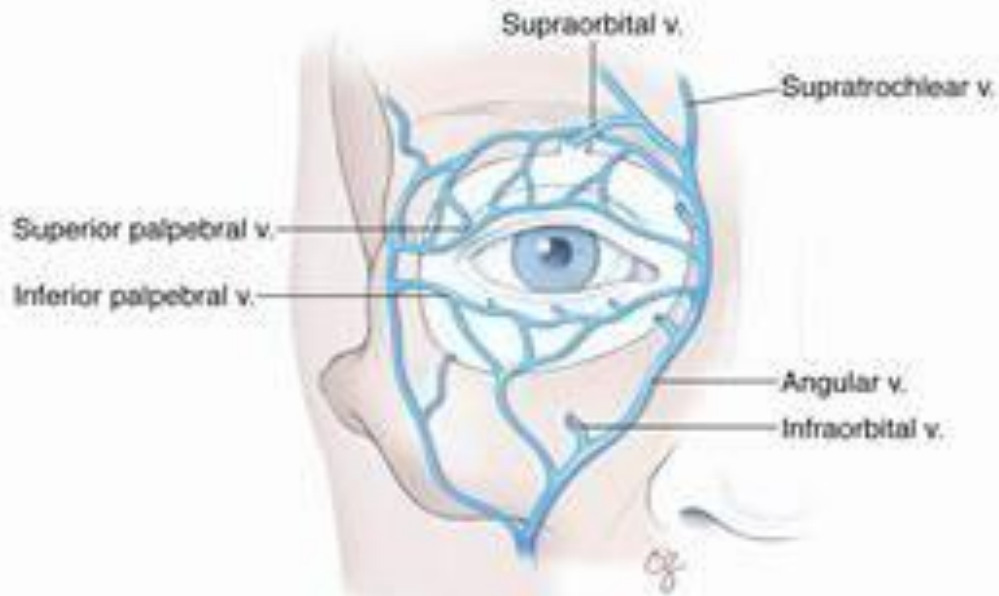


Anderson, Grant's Atlas of Anatomy,
 8th edition, Lippincott, Williams & Wilkins,
 1983, ISBN: 0-683-00211-2, plate 7-56.

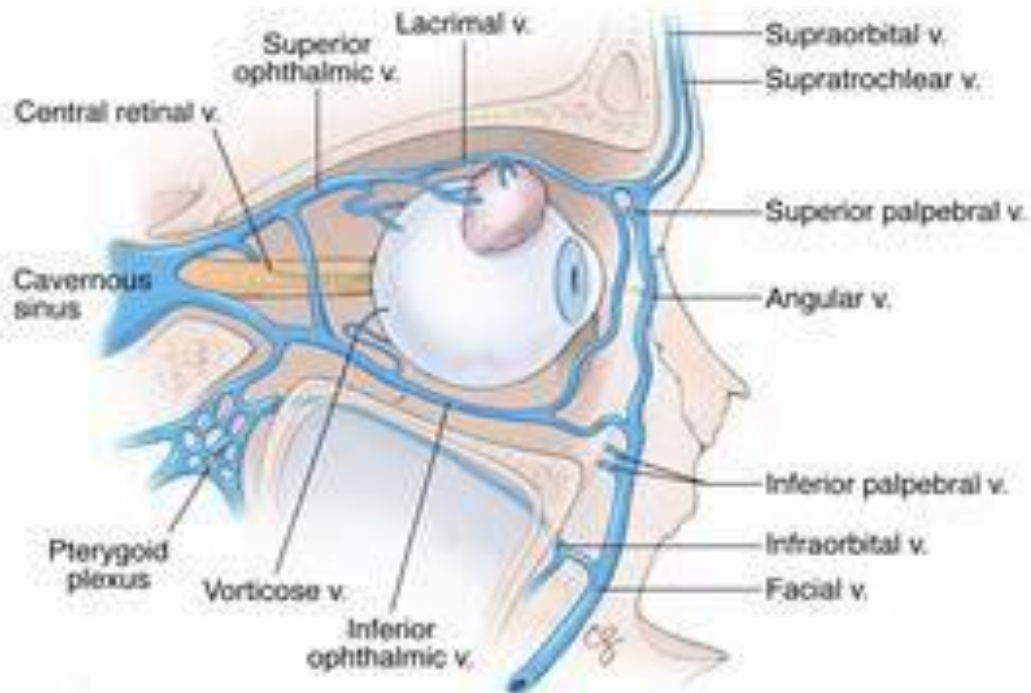
□ Ophthalmic Veins

The superior ophthalmic vein communicates in front with the **facial vein**. The **inferior ophthalmic vein** communicates through the inferior orbital fissure with the pterygoid venous plexus. Both veins pass backward through the superior orbital fissure and drain into the cavernous sinus.

****Lymph Vessels** No lymph vessels or nodes are present in the orbital cavity.



A



B

Structure of the Eye

The eyeball is embedded in orbital fat but is separated from it by the fascial sheath of the eyeball. The eyeball consists of **three coats**, which are the fibrous coat, the vascular pigmented coat, and the nervous coat.

1. Fibrous Coat :The fibrous coat is made up of a posterior opaque part, the sclera, and an anterior transparent part, the cornea.

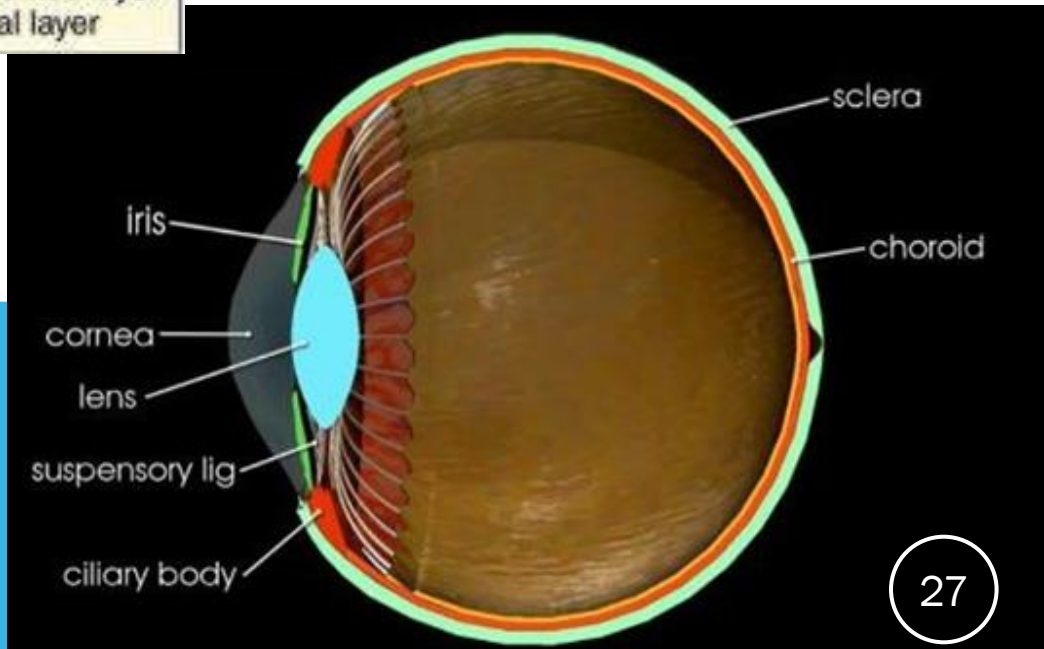
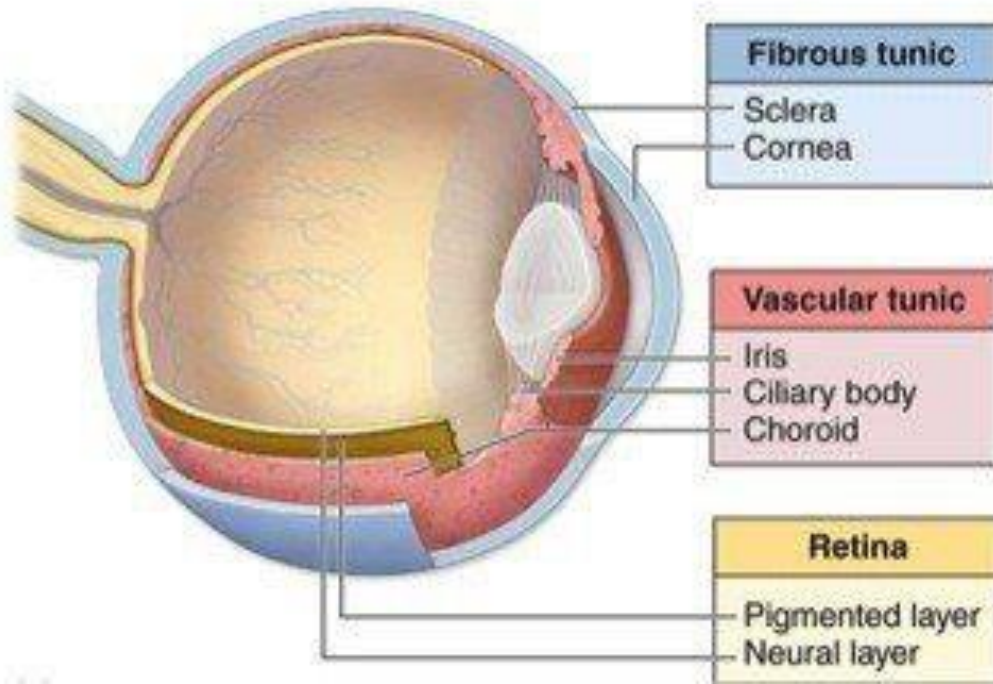
2. Vascular Pigmented Coat

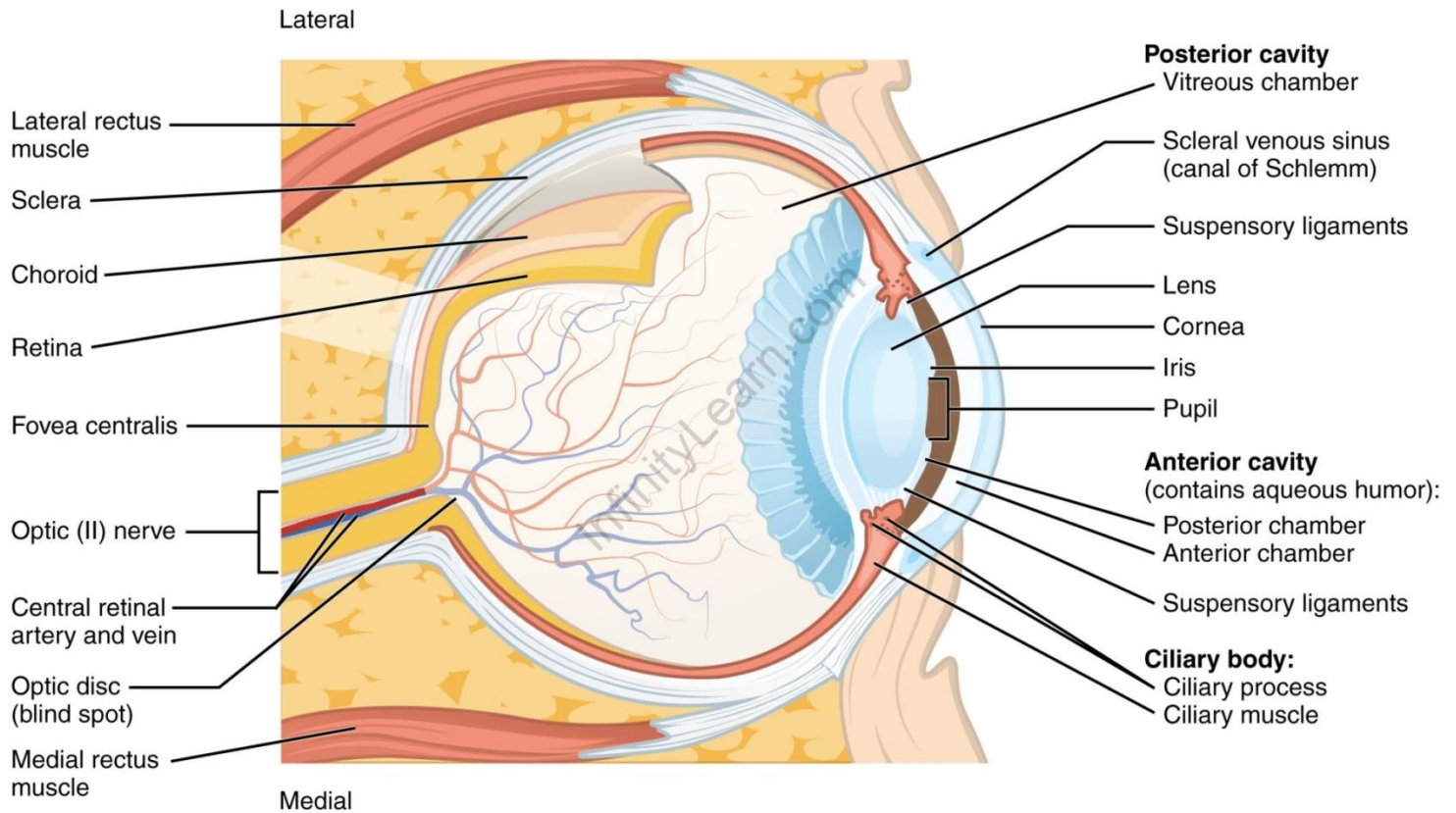
The vascular pigmented coat consists, from behind forward, of: the choroid, the ciliary body, and the iris.

The **choroid** is composed of an outer pigmented layer and an inner, highly vascular layer.

The **ciliary body** is composed of the ciliary ring, the ciliary processes, and the ciliary muscle.

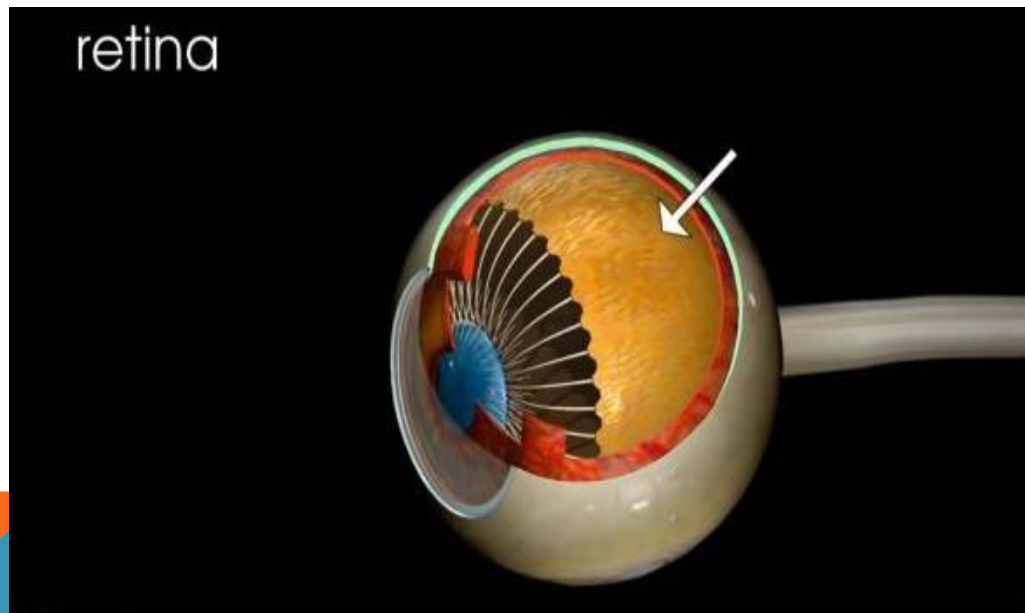
The **iris** is a thin, contractile, pigmented diaphragm with a central aperture, the pupil

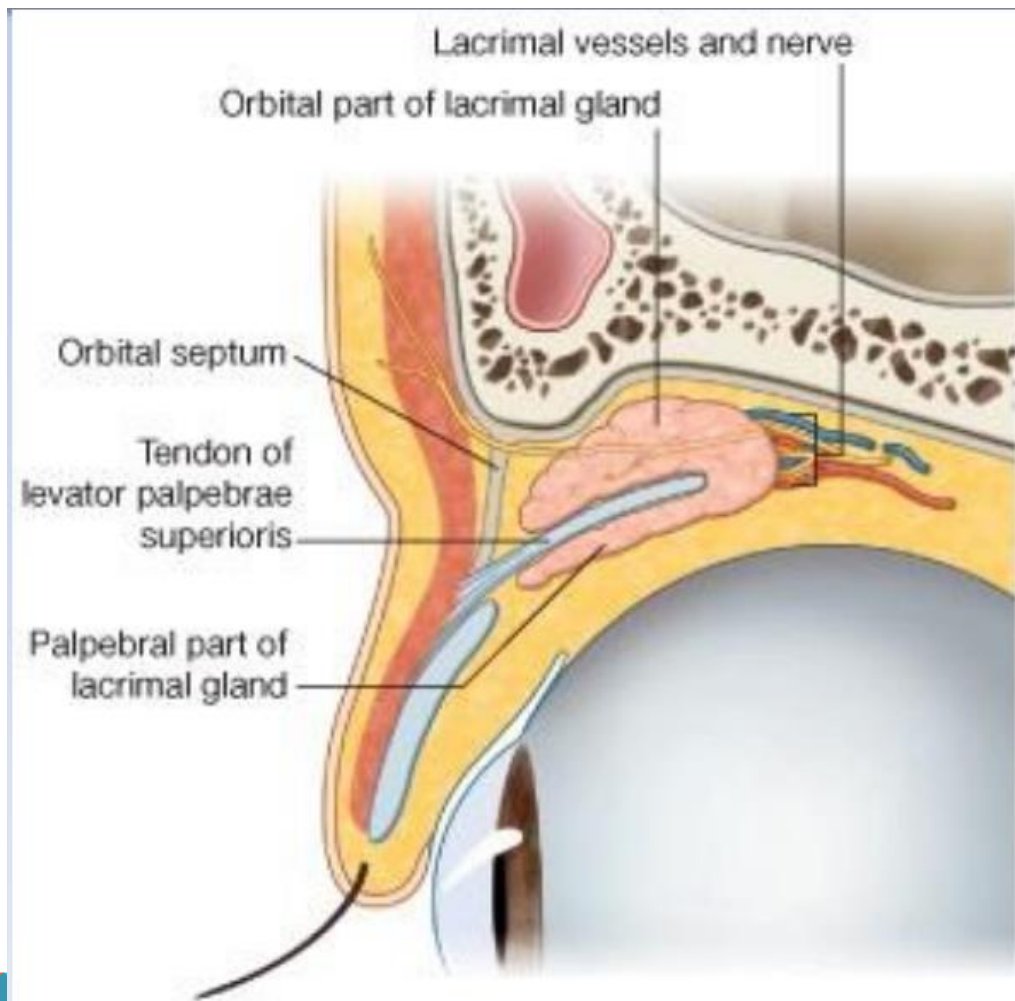




3. Nervous Coat: The Retina

The retina consists of an outer pigmented layer and an inner nervous layer. Its outer surface is in contact with the choroid, and its inner surface is in contact with the vitreous body. The posterior three fourths of the retina is the receptor organ.





Lacrimal Apparatus

*Lacrimal Gland

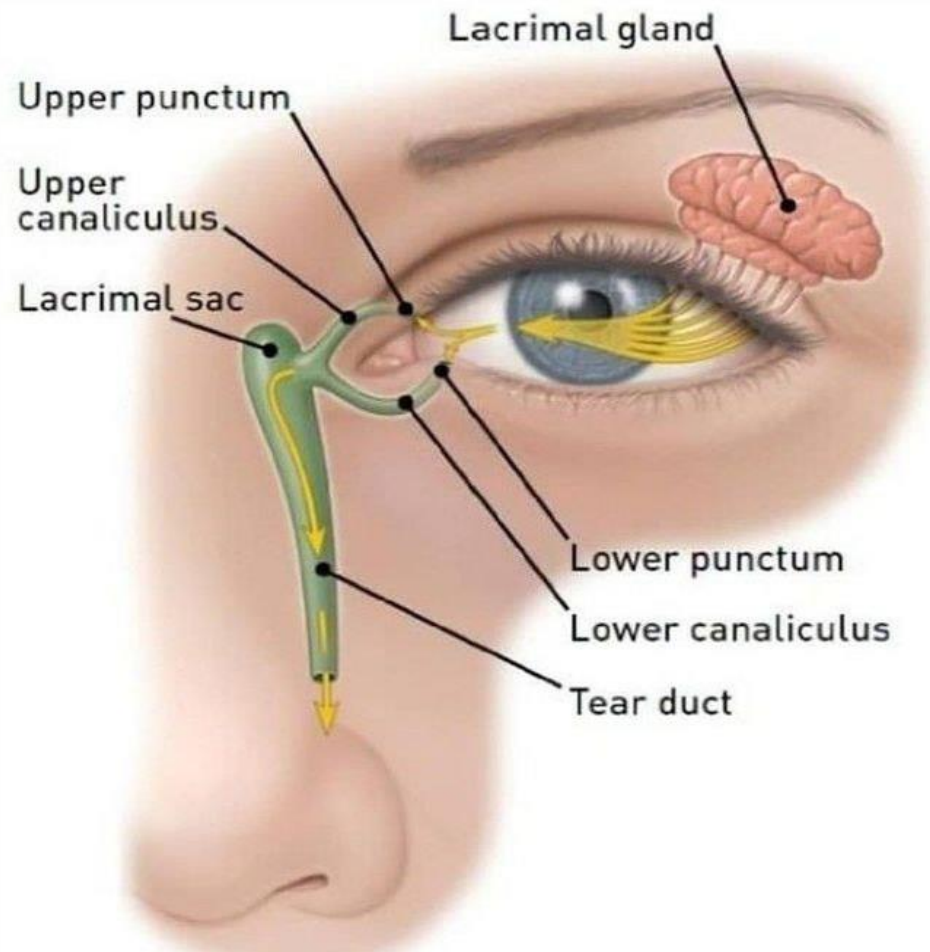
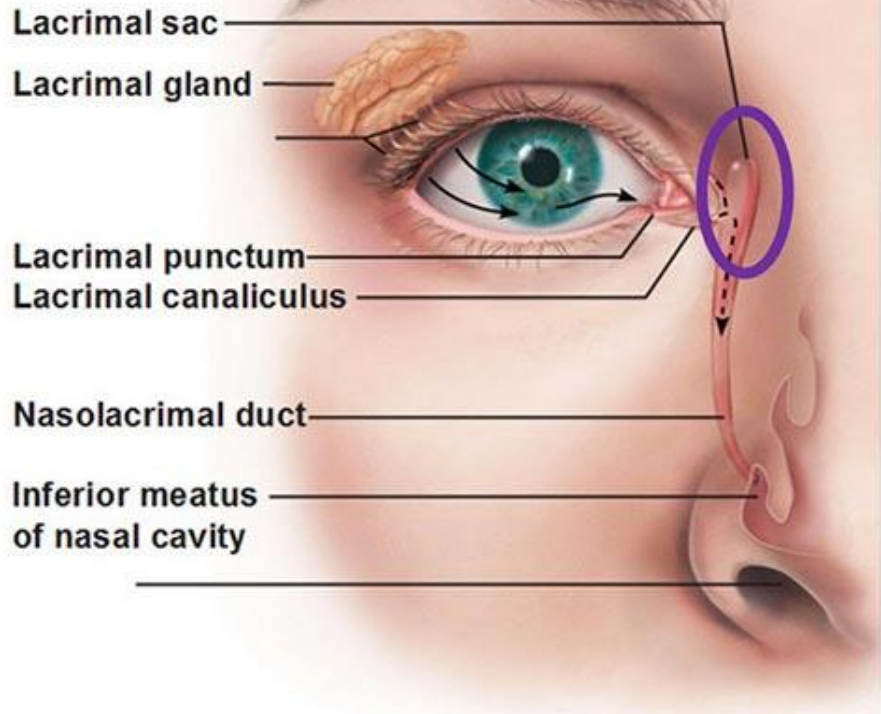
The lacrimal gland consists of a large **orbital part** and a small **palpebral part**. It is situated above the eyeball and opens by 12 ducts into the lateral part of the superior fornix of the conjunctiva.

The parasympathetic secretomotor nerve supply is derived from the **lacrimal nucleus of the facial nerve**. The preganglionic fibers reach the pterygopalatine ganglion (sphenopalatine ganglion) by great petrosal branch of facial nerve and then by the nerve of pterygoid canal which synapses in the pterygopalatine ganglion. The post ganglionic fibers leave the ganglion and join the maxillary nerve. They then pass into its zygomatic branch and then pass into the zygomaticotemporal nerve. Finally parasympathetic fibers leave the zygomaticotemporal nerve and join the lacrimal nerve through communicating branch to reach the lacrimal gland.

The sympathetic postganglionic nerve supply is from the internal carotid plexus (fibers around internal carotid artery) and travels in the deep petrosal nerve, and then with the nerve of the pterygoid canal, then pass through pterygopalatine ganglion without synapses and reach the maxillary nerve and join the zygomatic nerve, then run through its zygomaticotemporal branch, and finally to the lacrimal nerve.

*Lacrimal Ducts

The tears circulate across the cornea and enter the canaliculi lacrimales through the puncta lacrimalis. The canaliculi lacrimales pass medially and open into the lacrimal sac, which lies in the lacrimal groove behind medial palpebral ligament. The nasolacrimal duct is about 0.5 inch (1.3 cm) long and emerges from the lower end of the lacrimal sac. It descends downward, backward, and laterally in a bony(osseous) canal and opens into the inferior meatus of the nose. The opening is guarded by a fold of mucous membrane known as the **lacrimal fold**. This prevents air from being forced up the duct into the lacrimal sac on blowing the nose.



Clinical Notes

□ Eye Trauma

Blowout fractures of the orbital floor involving the maxillary sinus commonly occur as a result of blunt force to the face. If the force is applied to the eye, the orbital fat explodes inferiorly into the maxillary sinus, fracturing the orbital floor. Not only can blowout fractures cause displacement of the eyeball, with resulting symptoms of double vision (diplopia), but also the fracture can injure the infraorbital nerve, producing loss of sensation of the skin of the cheek and the gum on that side.

Entrapment of the inferior rectus muscle in the fracture may limit upward gaze.

□ Pupillary Reflexes

The pupillary reflexes, that is the reaction of the pupils to light and accommodation, depend on the integrity of nervous pathways.

In the direct light reflex, the normal pupil reflexly contracts when a light is shone into the patient's eye.

The accommodation reflex is the contraction of the pupil that occurs when a person suddenly focuses on a near object after having focused on a distant object.

THANK YOU

Lec [5] / Parotid region

The part of the face **in front of the ear and below the zygomatic arch** is the parotid region.

Boundaries:

Superiorly: zygomatic arch.

Inferiorly: angle and lower border of mandible.

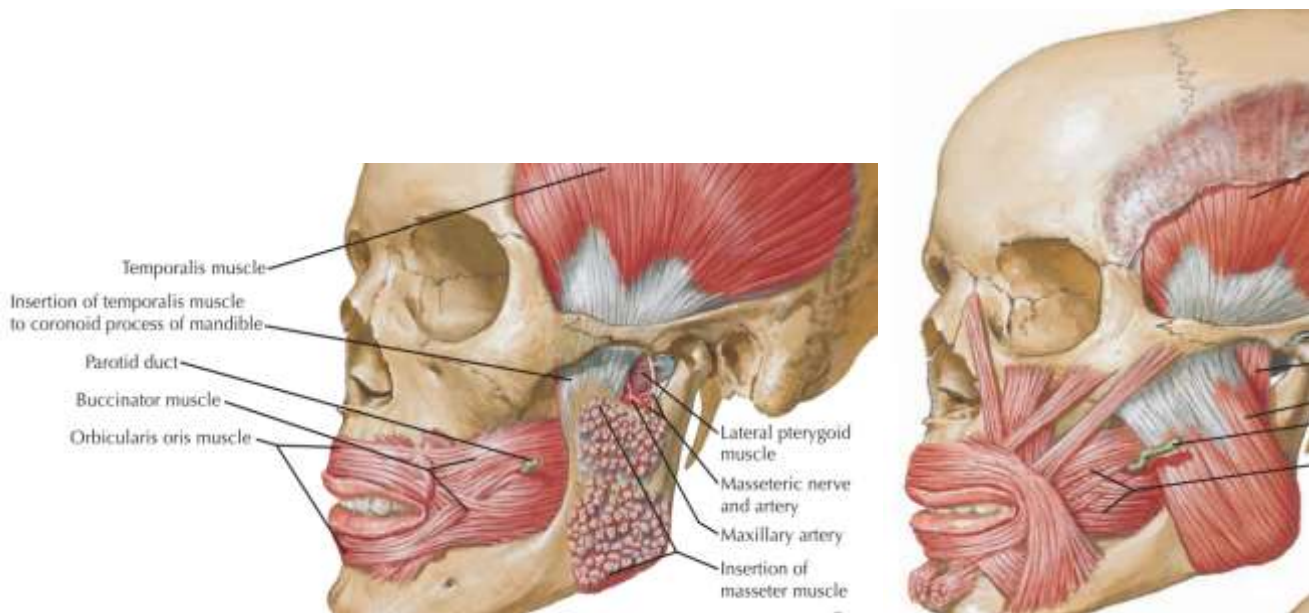
Anteriorly: anterior border of masseter muscle.

Posteriorly: external ear and anterior border of sternocleidomastoid muscle.

Medially: ramus of mandible.

Contents:

- 1- Masseter muscle.
- 2- Parotid gland with its associated structures.

Masseter muscle:

It considers as one of the four masticatory muscles; the **parotid duct** and the **accessory parotid gland** lie on its lateral surface.

originated from the **lower border of the zygomatic arch and bone** and is **inserted** into almost the **whole of the lateral surface of the mandibular ramus**.

Blood supply: branches of the **facial artery**, **maxillary artery** and **superficial temporal artery**. particularly its **transverse facial artery**

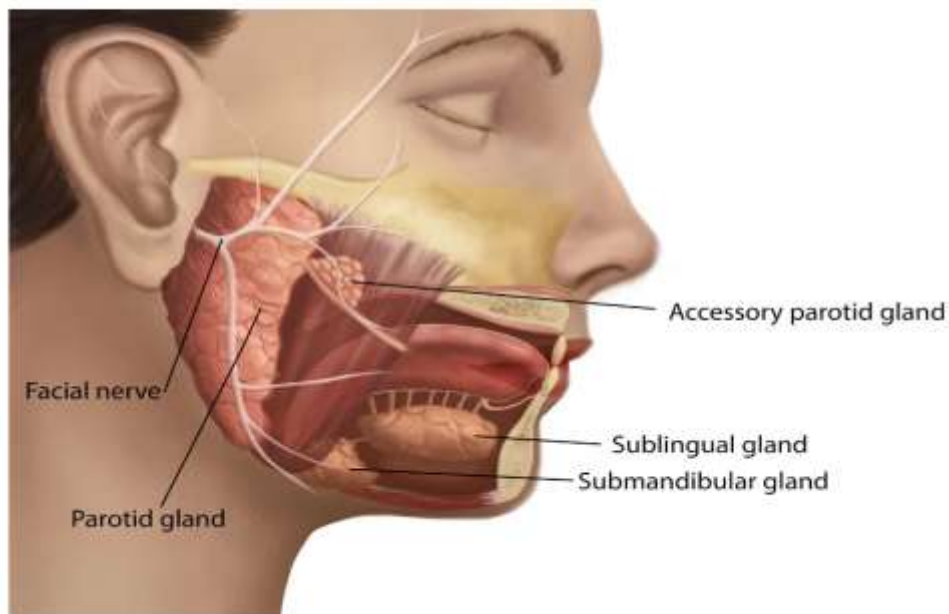
Nerve supply. By the **masseteric branch** of the **mandibular nerve**, which passes through the mandibular notch.

Action. Masseter elevates the mandible and close the mouth.

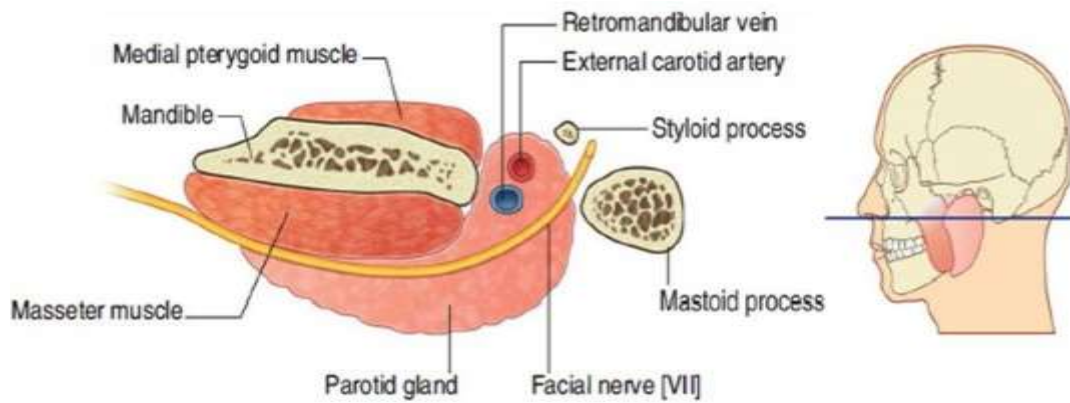
Parotid gland:

The parotid gland is the largest of the major salivary glands, it is a mainly serous gland, with only a few scattered mucous acini. It is a **large, irregular, lobulated** gland which extends from the **zygomatic arch** to the **upper part of the neck**. Anteriorly the gland overlaps **masseter** muscle and a small, usually detached **accessory parotid** lies above the parotid duct on the **masseter**. Posteriorly the gland extends in front and below the **external acoustic meatus** and in front the **sternocleidomastoid muscle** and **mastoid process**.

Parotid Gland Anatomy



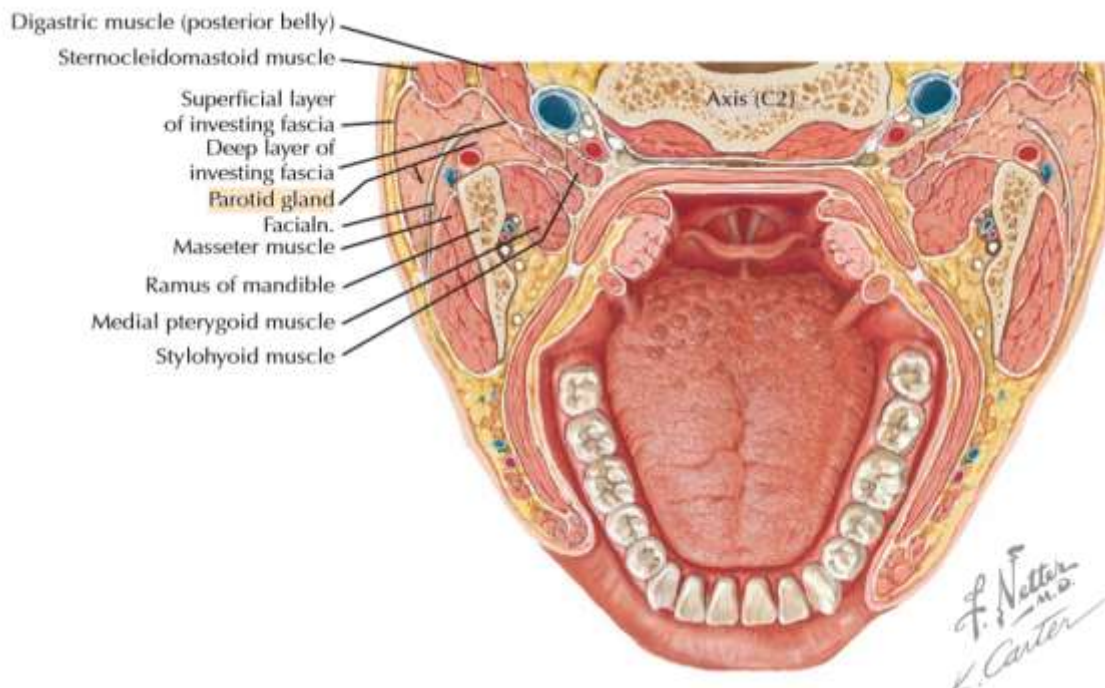
Parotid capsule is derived from the investing layer of deep cervical fascia which split at the lower end of the gland to envelope the gland.



Parotid gland: cross section

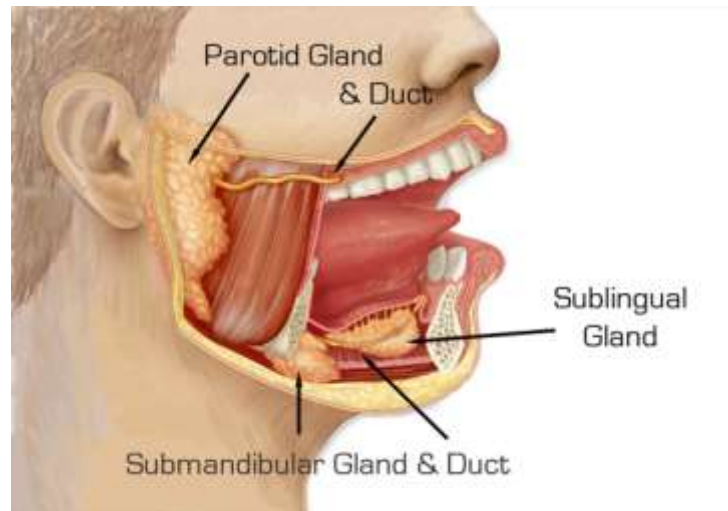
In transverse section the posterior part the gland occupies the gap between the **ramus of the mandible and the mastoid and styloid processes of the temporal bone**, and reaching close to the lateral wall of the oropharynx.

More medially, the styloid process and its attached muscles (stylohyoid, stylopharyngeus and styloglossus) separate the gland from the carotid sheath and its contained **internal jugular vein, vagus nerve and internal carotid artery**. The external carotid artery enters the gland through the lower part of this surface.



The **facial nerve** divides the gland into **superficial** and **deep lobes**. Within the gland the nerve branches communicate with each other, forming a plexus that lies superficial to the **retromandibular vein**, which in turn is superficial to the **external carotid artery**. The

retromandibular vein is formed within the parotid by the confluence of the **superficial temporal and maxillary veins**. The retromandibular vein emerges from the lower part of the gland and divides into **anterior and posterior branches**. Lymph nodes of the **preauricular (parotid)** group lie on or deep to the **capsule of the parotid**, as well as within the gland.



The **parotid duct** (of Stensen), about 5 cm long, passes forwards across the masseter and turns around its anterior border to pass through the buccal fat pad and pierce the buccinator. The duct opens on the mucous membrane of the cheek opposite the second upper molar tooth.

Blood supply: Branches from the **external carotid artery** supply the gland.

Venous drainage: is to the **retromandibular vein**.

Lymph drainage: Lymph drains to the preauricular (parotid) nodes and then to the deep cervical nodes.

Nerve supply:

1/ parasympathetic: The **tympanic nerve** arises from the **glossopharyngeal nerve**, just below the **jugular foramen**. It passes through the **floor of the middle ear cavity**, it splits into branches, which form the **tympanic plexus**. The tympanic plexus gives off the **lesser petrosal nerve (consist of parasympathetic secretomotor fibers)**. lesser petrosal nerve directed forward and medially, leaves the anterior aspect of petrous and runs shortly toward **foramen ovaly** and leaves the skull to joins the **otic ganglion [parasympathetic**

ganglion] medial to **mandibular nerve**. The postganglionic fibers arise from cell bodies in the **otic ganglion** and reach the gland along the **auriculotemporal nerve**.

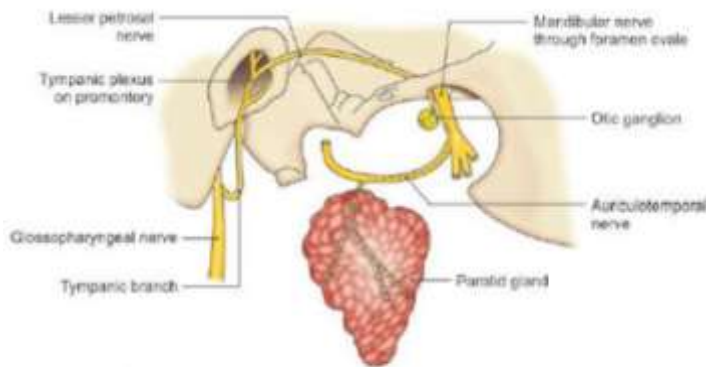
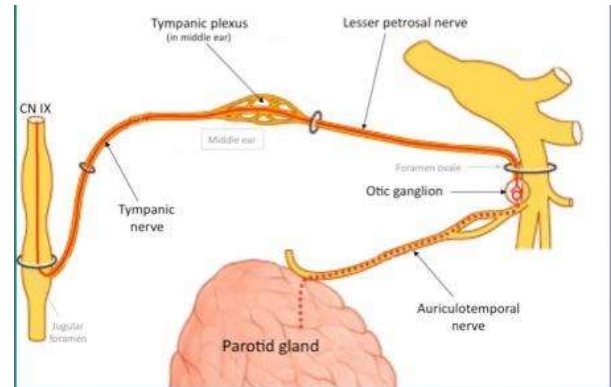
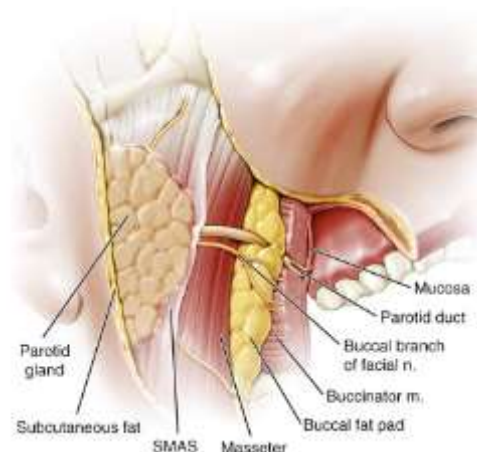


Fig. 5.6: Parasympathetic nerve supply to the parotid gland



2/Sympathetic (vasoconstrictor) fibers reach the gland from the **superior cervical ganglion** by way of the plexus on the **external carotid and middle meningeal arteries**.

3/Sensory innervation is supplied by the **auriculotemporal nerve** and **great auricular nerve**. **Auriculotemporal nerve**, a mandibular branch, often arises as 2 roots surrounding the **middle meningeal artery**. Supplies the **deep and superior portions** of parotid gland. **Great auricular nerve (the cervical plexus branch)**, supplies the **superficial and inferior portions** of parotid gland.

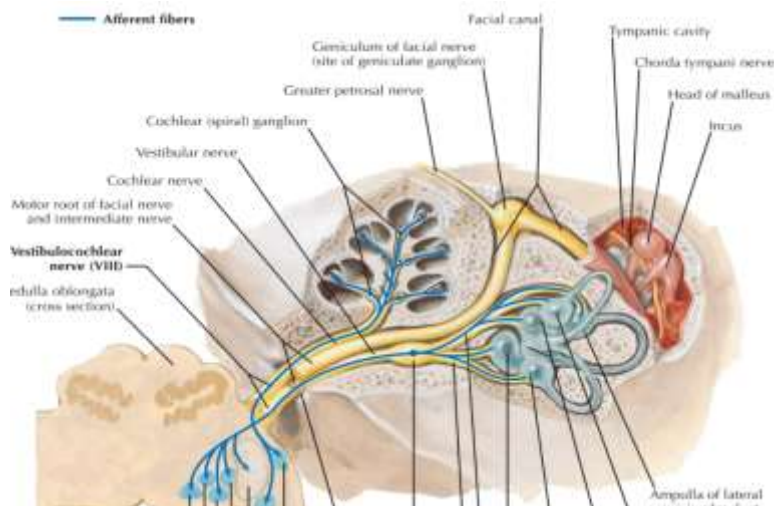


The buccal pad of fat: superficial to buccinator are collection of fat, these are much larger in infant, to reinforce the cheeks and keep them from collapsing during sucking.

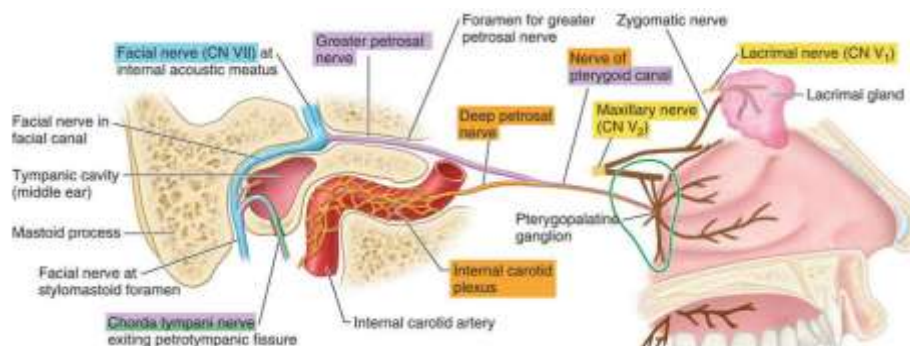
Blood supply: Branches from **maxillary artery, superficial temporal artery and facial artery**.

Facial nerve:

The facial nerve has a **motor root and a sensory root (nervus intermedius)**. The nerve emerges from the brain between the **pons** and the **medulla oblongata**. The roots pass laterally in the **posterior cranial fossa** with the **vestibulocochlear nerve** and enter the **internal acoustic meatus** in the **petrous part of the temporal bone**. At the end of the meatus, the nerve enters the **facial canal**, the nerve **swells** to form the **sensory geniculate ganglion**. Near the **medial wall of the middle ear (tympanic cavity)** the nerve bends sharply backward. From here the nerve runs back in the **facial canal** in the medial wall of the middle ear.



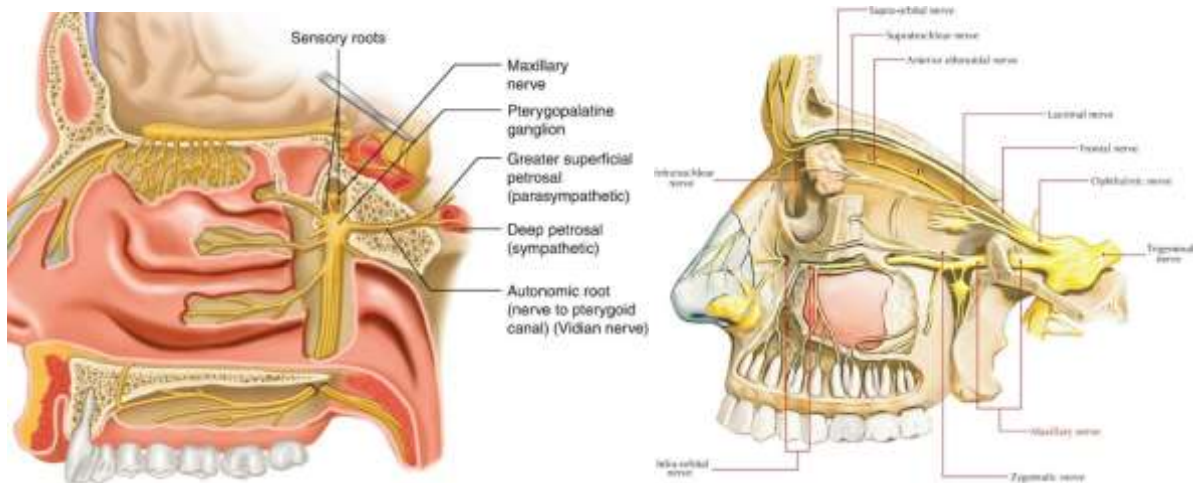
At the posterior wall of the middle ear, the nerve bends and descends downward. and emerges from the temporal bone through the stylomastoid foramen. The facial nerve now passes forward through the parotid gland to its distribution.

**Important Branches of the Facial Nerve**

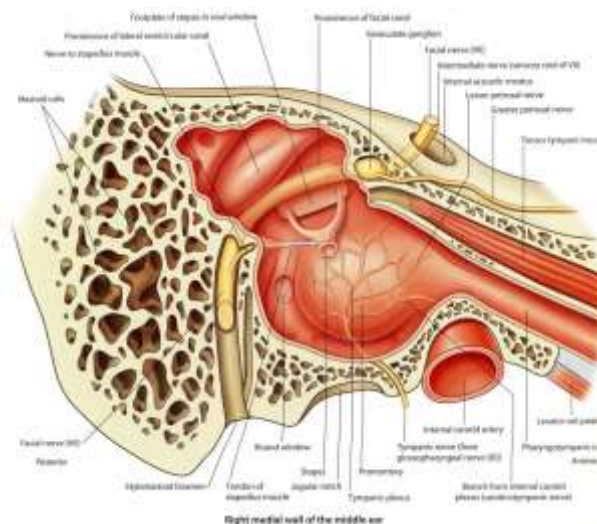
1-Greater petrosal nerve: The greater petrosal nerve, leaves the **geniculate ganglion** and travels forwards and medially at a 45° through the petrous bone. It emerges from the

anterior surface of the petrous bone and runs forwards. The nerve passes beneath the **trigeminal ganglion** and reaches the **foramen lacerum**, where it is joined by the **deep petrosal** nerve from the **sympathetic plexus on the internal carotid artery**.

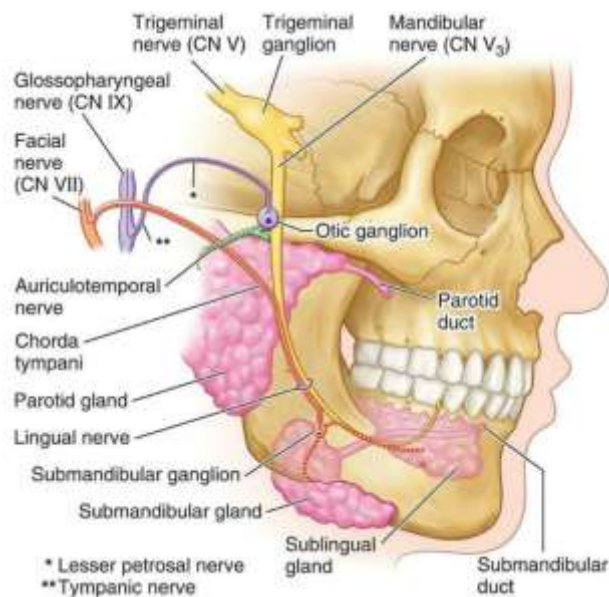
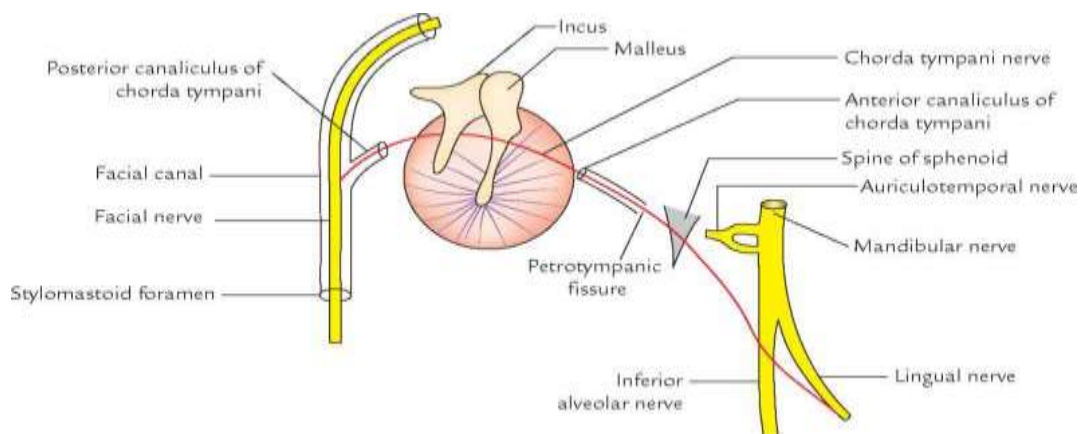
The two unite and pass forwards through the **pterygoid canal**. This **nerve of the pterygoid canal** [vidian nerve] emerges into the **pterygopalatine fossa** and enters the **pterygopalatine ganglion**. Greater petrosal nerve contains **preganglionic parasympathetic fibers** that synapse in the **pterygopalatine ganglion** and also contain **taste fibers**.



Taste fibers and sympathetic fibers pass straight through the ganglion without relay. Postganglionic secretomotor fibers are distributed with the branches of the ganglion to the **nose, paranasal sinuses, hard and soft palates, and nasopharynx**. **Lacrimary postganglionic fibers** join the **maxillary nerve** and enter the **orbit in its zygomatic branch**. **2-Nerve to stapedius** supplies the stapedius muscle in the middle ear. The nerve to stapedius is given off in the facial canal and reaches the muscle by a minute canaliculus.



3-Chorda tympani arise from the facial nerve in the **facial canal** in the posterior wall of the **middle ear**. It runs forward over the medial surface of the upper part of the **tympanic membrane** and leaves the middle ear through the **petrotympanic fissure**, thus entering the **infratemporal fossa** and joining the **lingual nerve**. The chorda tympani contain **preganglionic parasympathetic secretomotor fibers** to the **submandibular and the sublingual salivary glands**. It also contains **taste fibers** from the **anterior two thirds of the tongue**.

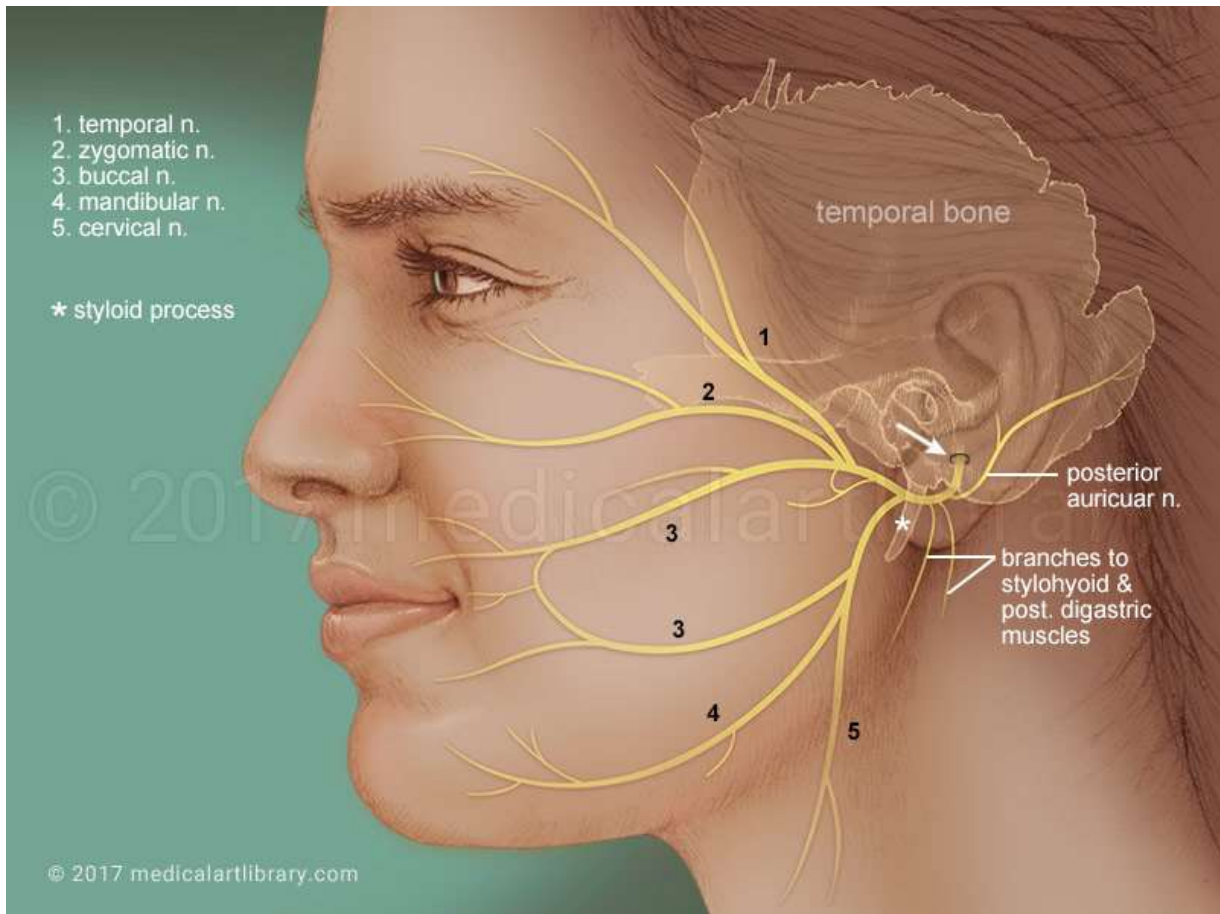


4-muscular branches given off by the facial nerve as it emerges from the **stylomastoid foramen**. They innervate the **posterior belly of the digastric**, and the **stylohyoid** muscles.

5-Posterior auricular branch: muscular branch supplies, **occipitalis**, **auricularis posterior** and **auricularis superior**.

6-Five terminal branches to the muscles of facial expression: These are the **temporal**, the **zygomatic**, the **buccal**, the **marginal mandibular**, and the **cervical** branches.

The facial nerve thus controls **facial expression, salivation, and lacrimation** and is a **pathway for taste sensation from the anterior two third of the tongue.**



Clinical notes:

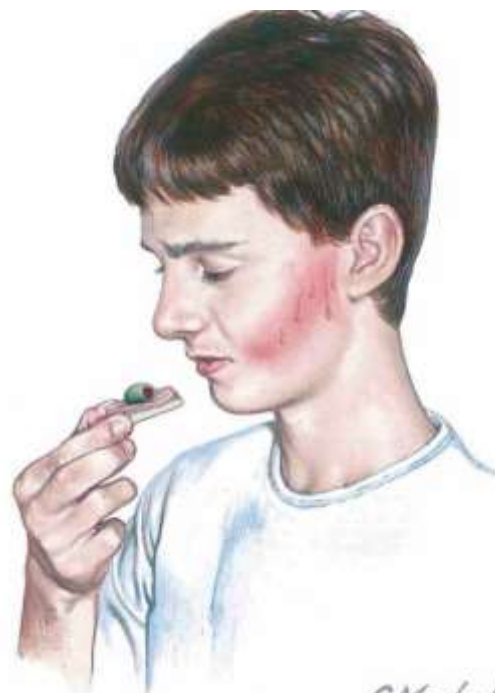- 1- **Parotid Duct Injury:** The parotid duct, which is a somewhat superficial structure on the face, may be damaged in injuries to the face or may be accidentally cut during surgical operations on the face.
- 2- **Parotid Salivary Gland and Lesions of the Facial Nerve:** The parotid salivary gland consists essentially of superficial and deep parts, and the important facial nerve lies in the interval between these parts. A **benign parotid neoplasm** rarely causes facial palsy. A **malignant tumor** of the parotid is usually highly invasive and quickly involves the facial nerve, causing unilateral facial paralysis.
- 3- **Parotid Gland Infections:** The parotid gland may become acutely inflamed as a result of retrograde bacterial infection from the mouth via the parotid duct. The gland may also become infected via the bloodstream, as in **mumps**. In both cases, the gland is

swollen; it is painful because the fascial capsule derived from the investing layer of deep cervical fascia is strong and limits the swelling of the gland.

- 4- **Frey's Syndrome**: Caused by regeneration of the **auriculotemporal autonomic fibers** in an abnormal fashion, innervating the sweat glands near the parotid gland after a **parotidectomy** Symptoms include **sweating** and **redness** in the distribution of the auriculotemporal nerve during eating.



Parotitis
(obstruction or
ascending infection)



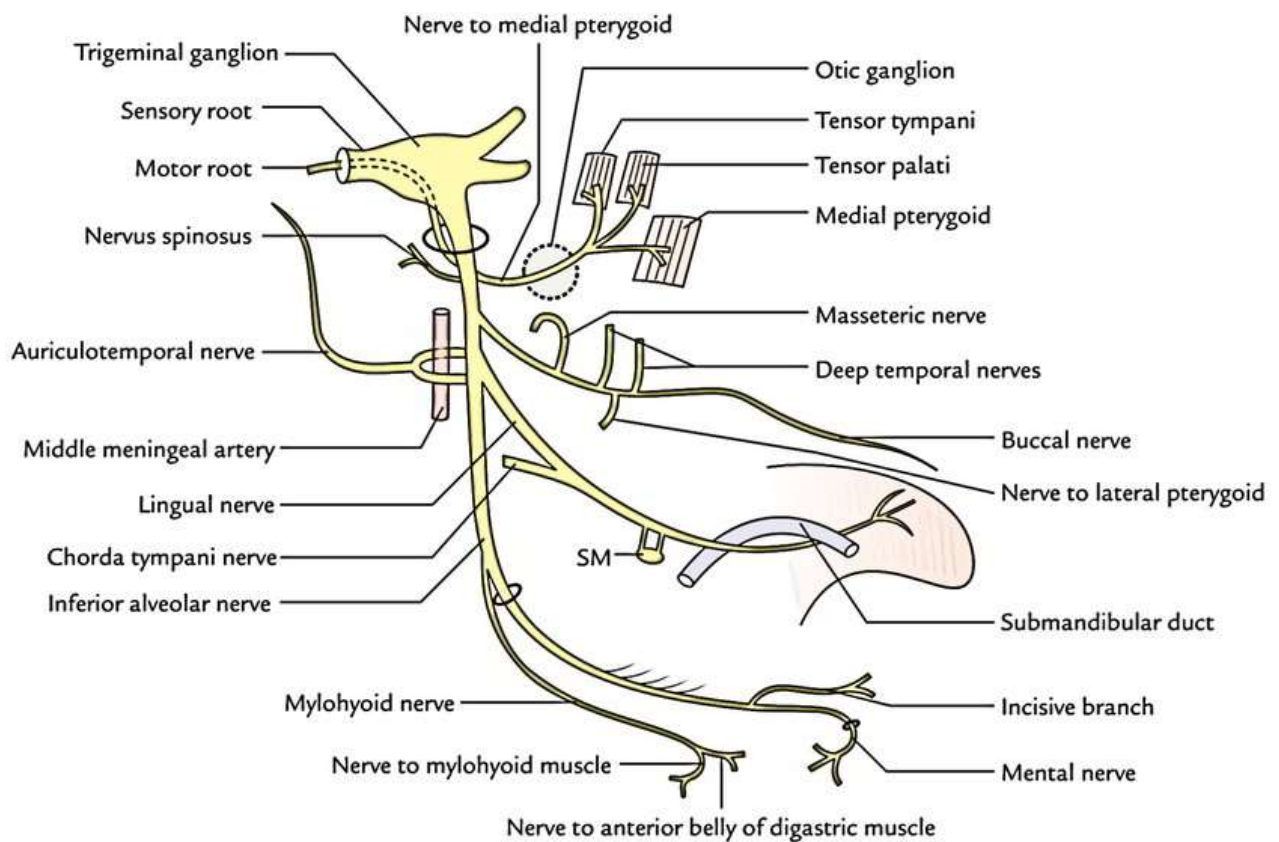
Frey's Syndrome

C. Machado
—M.D.

Lec. [13] / temporal region (part 2)

Mandibular nerve:

Is both motor and sensory. The **sensory root** leaves the trigeminal ganglion and passes out of the skull through the **foramen ovale** to enter the infratemporal fossa. The **motor root** of the trigeminal nerve also leaves the skull through the **foramen ovale** and joins the sensory root to form the **trunk** of the mandibular nerve, and then divides into a small anterior (mainly motor) and a large posterior (mainly sensory) branches.

**Branches from the main trunk**

One **sensory** and one **motor**.

1-The **meningeal branch (sensory)**: or **nervus spinosus**, re-enters the middle cranial fossa via the **foramen spinosum**, supplying the meninges of the middle cranial fossa.

2- The **nerve to the medial pterygoid muscle** runs forwards to the muscle, and gives a branch which passes through the **otic ganglion** without synapse and through which motor fibers are transmitted to **tensor palatini** and **tensor tympani**.

Branches from the anterior division

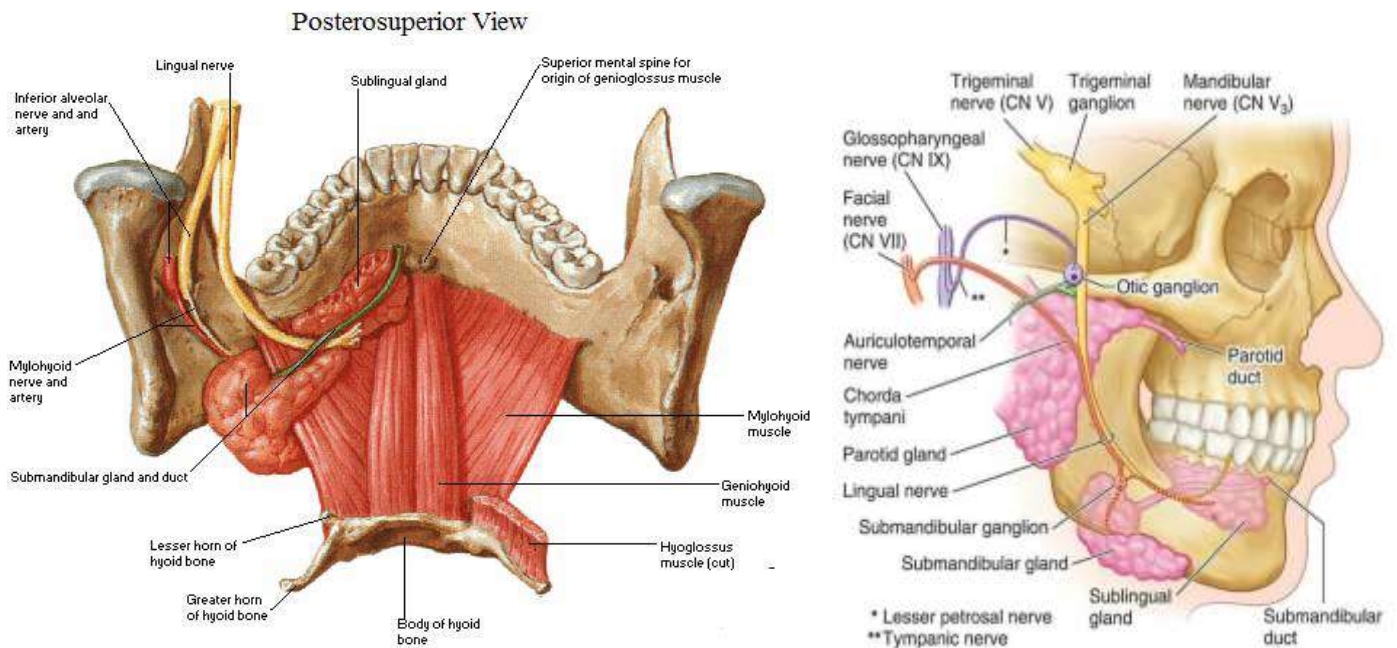
- 1- **Masseteric nerve** to the masseter muscle.
- 2- **Deep temporal nerves (anterior and posterior)** to the temporalis muscle
- 3- **Nerve to the lateral pterygoid muscle**
- 4- **Buccal nerve** to the skin and the mucous membrane of the cheek and buccal gum. The buccal nerve does not supply the buccinator muscle (which is supplied by the facial nerve), and it is the only sensory branch of the anterior division of the mandibular nerve.

Branches from the posterior division

The branches of the posterior division of the mandibular nerve are sensory (except the nerve to the mylohyoid muscle). Its branches are:

- 1- **Auriculotemporal nerve**, is derived by two roots from the posterior division; they **embrace the middle meningeal artery**. The nerve passes backwards between the **neck of the mandible and the sphenomandibular ligament**, lying above the maxillary vessels. It supplies the skin of the **auricle, the external auditory meatus, tympanic membrane, the temporomandibular joint, parotid gland and the scalp**. This nerve also conveys **postganglionic parasympathetic secretomotor** fibers from the otic ganglion to the **parotid salivary gland**.

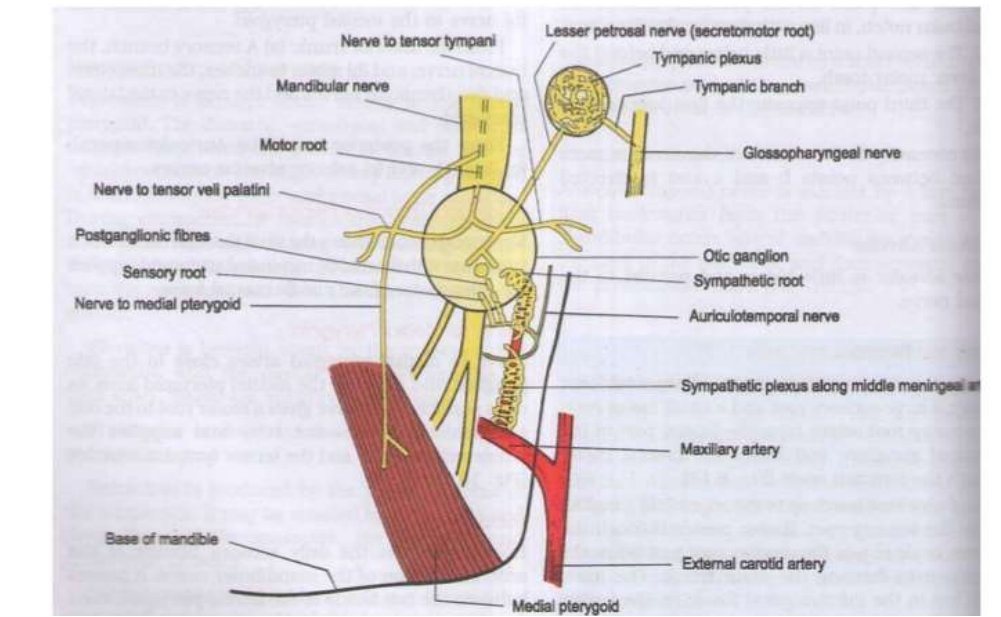
- 2- **Lingual nerve**, which descends in front and medial to the **inferior alveolar nerve** and enters the mouth. It then runs forward on the side of the tongue and crosses the **submandibular duct**. In its course, it is joined by the **chorda tympani nerve**, and it supplies the mucous membrane of the **anterior two thirds of the tongue, the floor of the mouth and the lingual gum**. It also gives off **preganglionic parasympathetic secretomotor fibers to the submandibular ganglion**.



The **chorda tympani** (from the facial nerve) emerges through the **petrotympanic fissure**, and joins the lingual nerve at an acute angle, and is distributed with it to the **anterior two thirds of the tongue**. It carries **parasympathetic secretomotor fibers** to the **submandibular ganglion** and **taste fibers** from the anterior two-thirds of the tongue.

3- **Inferior alveolar nerve**, which enters the **mandibular canal** to supply the teeth of the lower jaw and emerges through the **mental foramen** (mental nerve) to supply the skin of the **chin, lower lip and labial mucous membrane**. Before entering the canal, it gives off the **mylohyoid nerve**, which supplies the **mylohyoid muscle and the anterior belly of the digastric muscle**.

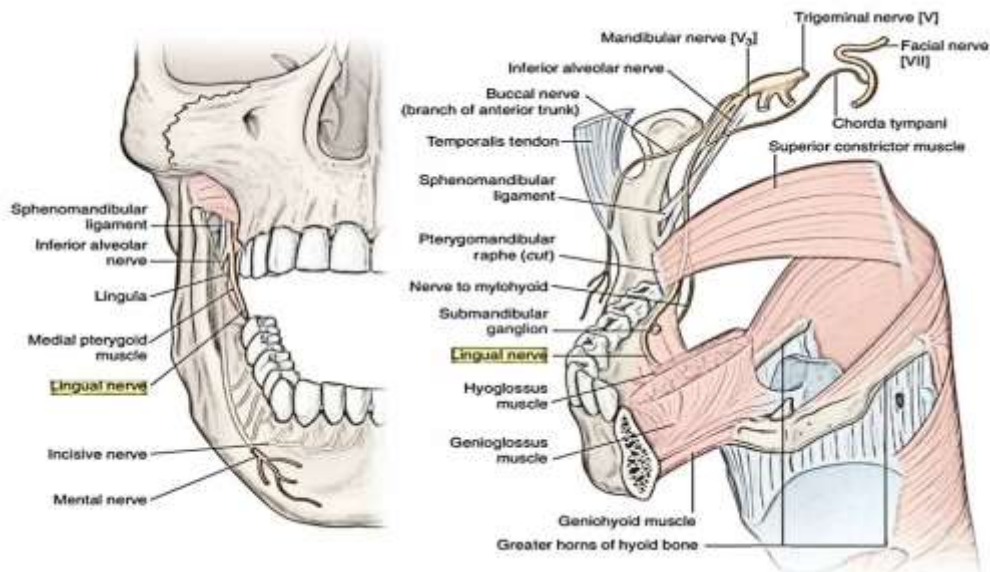
The posterior superior alveolar nerve: is a branch of the maxillary nerve, given off in the pterygopalatine fossa and soon dividing into two or three branches which pierce the posterior wall of the maxilla separately. They are distributed to the molar teeth and the mucous membrane of the maxillary sinus and buccal gum.

Otic ganglion**OTIC GANGLION:-ITS CONNECTIONS**

The otic ganglion has **parasympathetic, sympathetic, sensory, and motor roots**. a **branch from the nerve to the medial pterygoid** pass through the ganglion without relay and leaves the ganglion to supplies **tensor tympani and palati**. The otic ganglion is a **parasympathetic ganglion** that is located **medial to the mandibular nerve** just below the **foramen ovale**. The preganglionic fibers originate in the **glossopharyngeal nerve**, and they reach the ganglion via the **lesser petrosal nerve**. The postganglionic secretomotor fibers reach the **parotid salivary gland** via the **auriculotemporal nerve**.

Communications of infratemporal fossa:

- (1) **middle cranial fossa:** through **foramen ovale** and **foramen spinosum**.
- (2) **pterygopalatine fossa:** through **pterygomaxillary fissure**.
- (3) **orbital cavity:** through **inferior orbital fissure**.
- (4) **mandibular canal:** through **mandibular foramen**.
- (5) **temporal fossa:** through gap inferior to **temporal fossa**.

Clinical notes:**1- Injury to the Lingual Nerve**

The lingual nerve passes forward into the **submandibular region** from the **infratemporal fossa** by running beneath the origin of the **superior constrictor muscle**, which is attached to the **posterior border of the mylohyoid line** on the mandible. Here, it is closely related to the **last molar tooth** and is liable to be damaged in cases of forceful extraction of an impacted third molar.

2- Lesions of mandibular nerve:

Will cause unilateral **paralysis** of **muscles of mastication** followed by **atrophy**, results in a **sunken** -in appearance along the ramus and above the zygomatic arch.

Lec. [10] / The temporal region:

Can be divided into two main regions: the **superior region (temporal fossa)** and the **inferior region (infratemporal fossa)**, separated by the **zygomatic arch**.

Temporal fossa:

Borders of the Temporal Fossa:

Superior: Superior temporal line.

Inferior: gap between zygomatic arch and infratemporal crest of sphenoid bone.

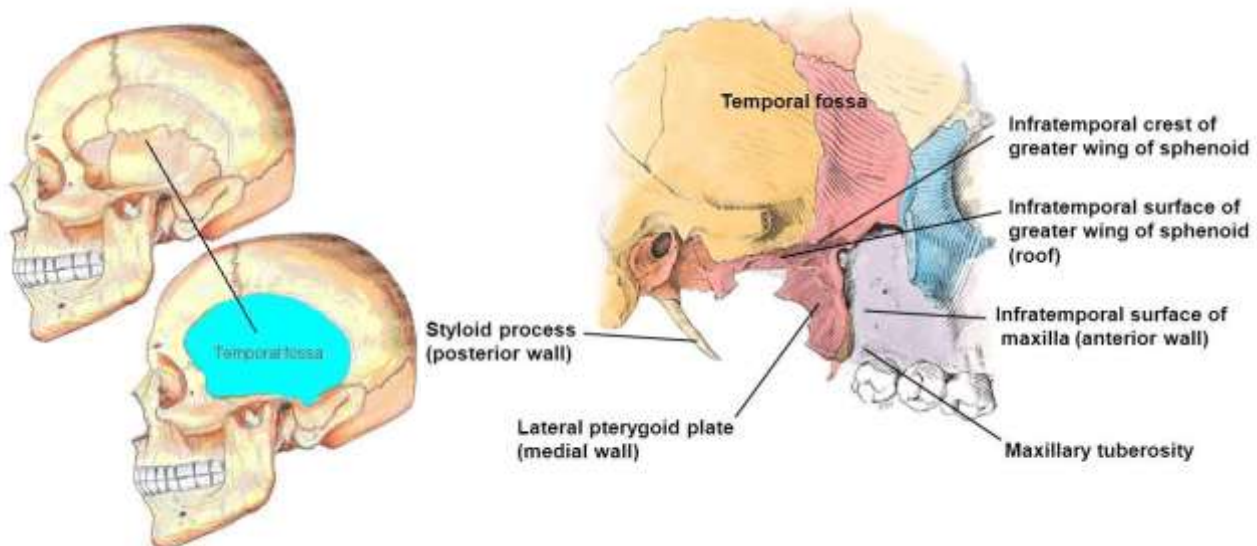
Anterior: Frontal process of the zygomatic bone and zygomatic process of the frontal bone.

Posterior: Superior temporal line.

lateral wall (roof): is the skin, extrinsic muscles of the ear and temporalis fascia.

Medial wall [floor]: is the part of the side of the skull that includes the **pteron**, where the **frontal**, the **parietal** and the **temporal bones** articulate with the **greater wing of the sphenoid**. The fossa is occupied primarily by the upper portion of the temporalis muscle.

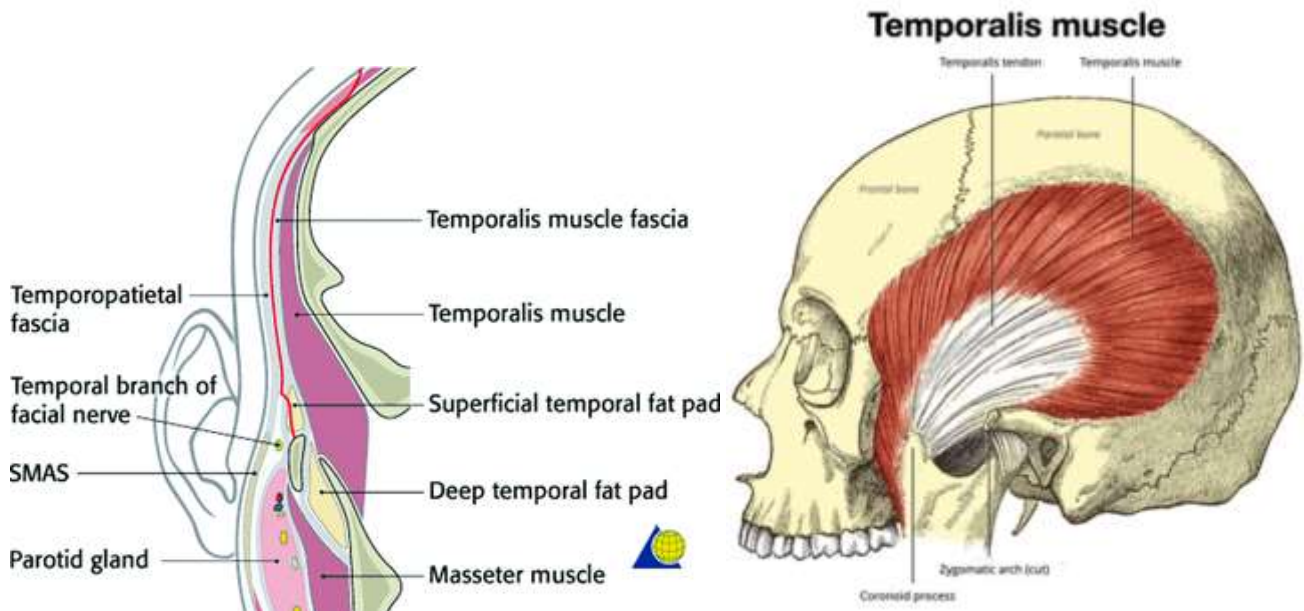
Inferiorly, the fossa becomes continuous with the lateral part of the **infratemporal fossa**.



The temporal fascia (deep temporal fascia): which forms the **roof of the temporal fossa** is attached to the **superior temporal line** and passes down to the upper border of the **zygomatic arch**. Above the arch it splits into two layers, one attached to the lateral and the other to the medial margin of the upper border of the arch.

This tough fascia also tethers the zygomatic arch superiorly. The powerful **masseter** muscle is attached to the inferior border of the arch. When it contracts, exerting a strong downward pull on the zygomatic arch, the temporal fascia provides resistance.

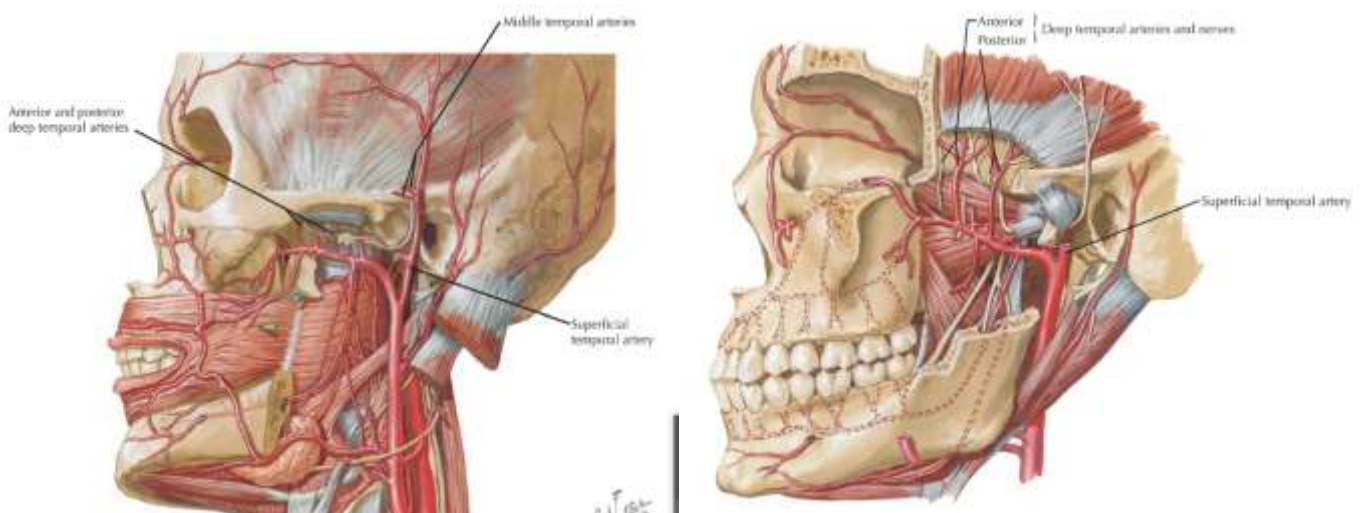
The temporoparietal fascia (superficial temporal fascia): superiorly continuous with ***galea aponeurotica***.



Contents: Temporalis muscle, deep temporal nerves and vessels, auriculotemporal nerve, superficial temporal artery and vein.

Temporalis: Origin: from the **entire rim of the fossa** and from the **deep surface of the temporalis fascia**. The most anterior fibers are vertical and the most posterior are horizontal, turning downwards.

Insertion: coronoid process and anterior border of ramus of mandible.



Blood supply: anterior and posterior deep temporal (branches of the maxillary artery) and superficial temporal arteries.

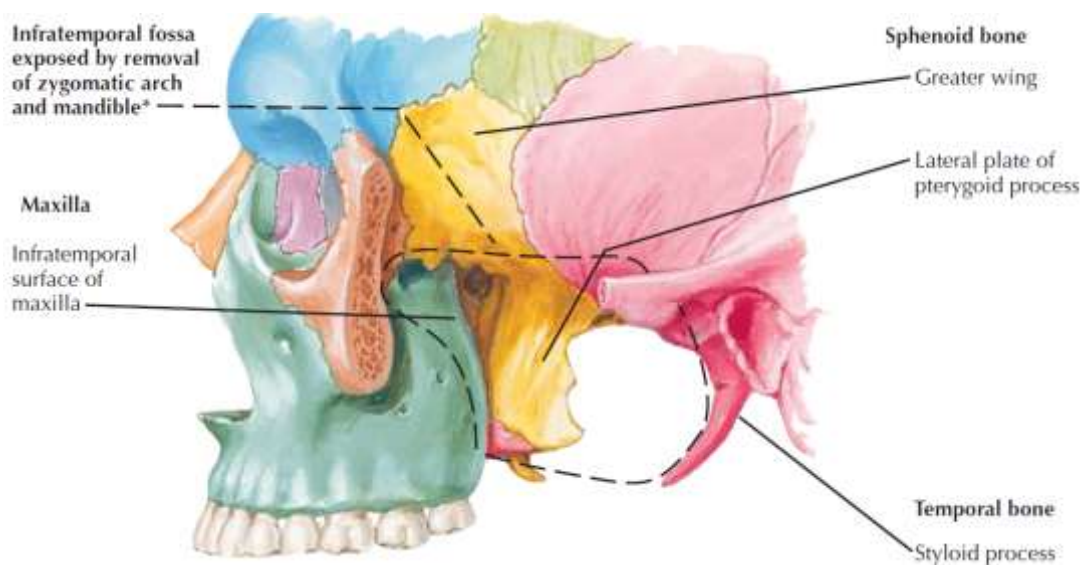
Nerve supply. anterior and posterior deep temporal branches of the mandibular nerve enter the deep surface of the muscle.

Action. elevates the mandible, closes the jaw, the posterior fibers retract the mandible.

Infratemporal fossa:

This is an irregularly shaped space lying between the **lateral wall of the pharynx** and the **ramus of the mandible**. It is also referred to as the **parapharyngeal** or **lateral pharyngeal space**.

Boundaries



Medially: the lateral surface of the **lateral pterygoid plate**

Laterally: the **ramus of the mandible**, **condylar process** and its **coronoid process**.

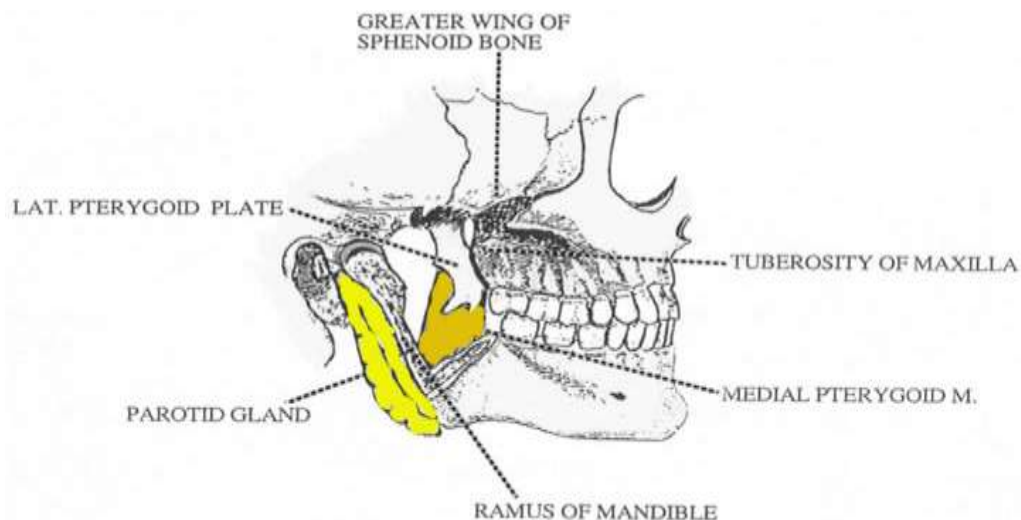
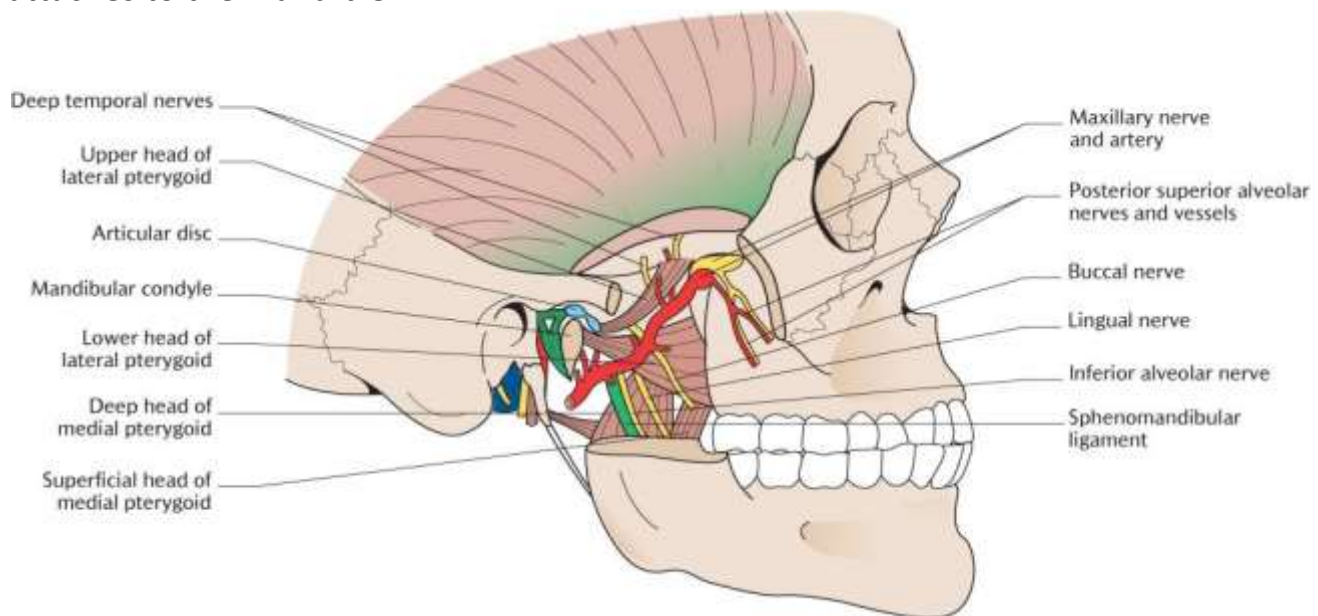
Anteriorly: the **posterior surface of the maxilla**, at the upper margin of which is a gap between it and the greater wing of sphenoid—the **inferior orbital fissure**.

Posteriorly: the **tympenic plate**, the **mastoid process** and **styloid processes** with the.

Superiorly: The *roof* of the fossa is formed medially by the **infratemporal surface of the greater wing of the sphenoid** (perforated by the foramen ovale and foramen spinosum). This infratemporal surface of the sphenoid is bounded laterally by the **infratemporal crest**, where the bone takes an almost right-angled turn upwards to become part of the side of

the skull, deep to the zygomatic arch and part of the temporal fossa. Thus, the roof of the infratemporal fossa lateral to the infratemporal crest is not bony, but is the space deep to the zygomatic arch where the temporal and infratemporal fossae communicate.

Inferiorly: No anatomic floor as the boundary of the fossa ends where the medial pterygoid attaches to the mandible



CONTENTS OF THE INFRATEMPORAL FOSSA

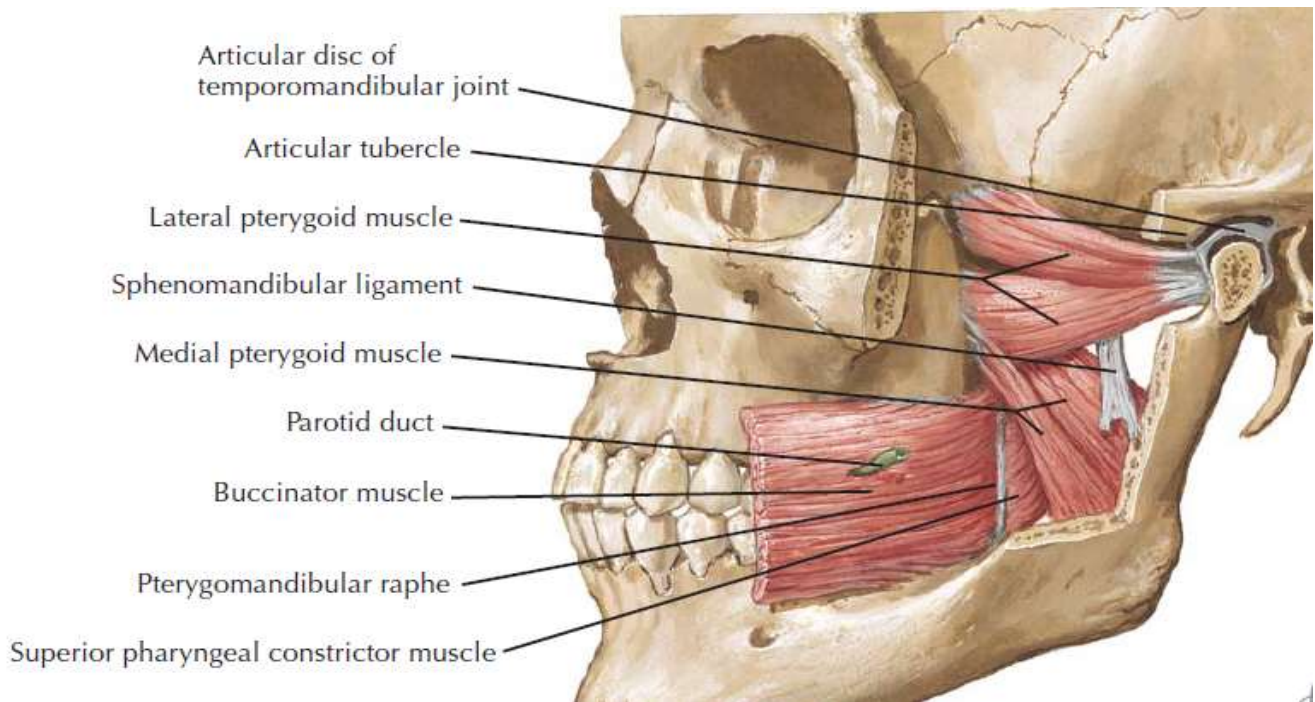
MUSCLES: ● Temporalis (lower part) ● Lateral pterygoid ● Medial pterygoid

ARTERIES: ● Maxillary artery and its branches

VEINS: ● Pterygoid plexus of veins and tributaries

NERVES: ● Mandibular nerve and its branches ● Posterior superior alveolar branch of maxillary nerve ● Chorda tympani branch of the facial ● Otic ganglion ● Lesser petrosal

Gland: ● deep part of parotid gland



Lateral pterygoid

Origin: This muscle arises by two heads: the **superior** from the roof of the **infratemporal fossa** and the **inferior** from the lateral surface of the **lateral pterygoid plate**. The two heads, converge and fuse into a short thick tendon.

Insertion: **superior** head into the **capsule** and the **articular disc** of the **temporomandibular joint**. The **inferior head** into the **neck of the mandible condyle**.

Nerve supply: By a branch from the **anterior division** of the **mandibular nerve**.

Action: protrudes mandible, opens mouth, unilateral contraction moves the mandible from side to side.

Medial pterygoid

Origin: This muscle also arises by two heads. The larger **deep head** arises from the medial surface of the **lateral pterygoid plate**. A small **superficial head**, arises from the **tuberosity of the maxilla**.

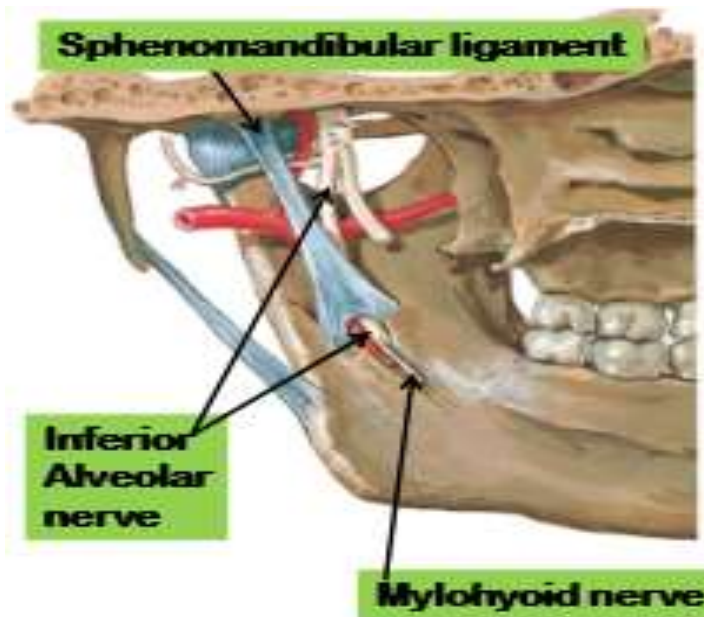
Insertion: medial surface of the **ramus** near the angle.

Nerve supply. By a branch from the **main trunk** of the **mandibular nerve**.

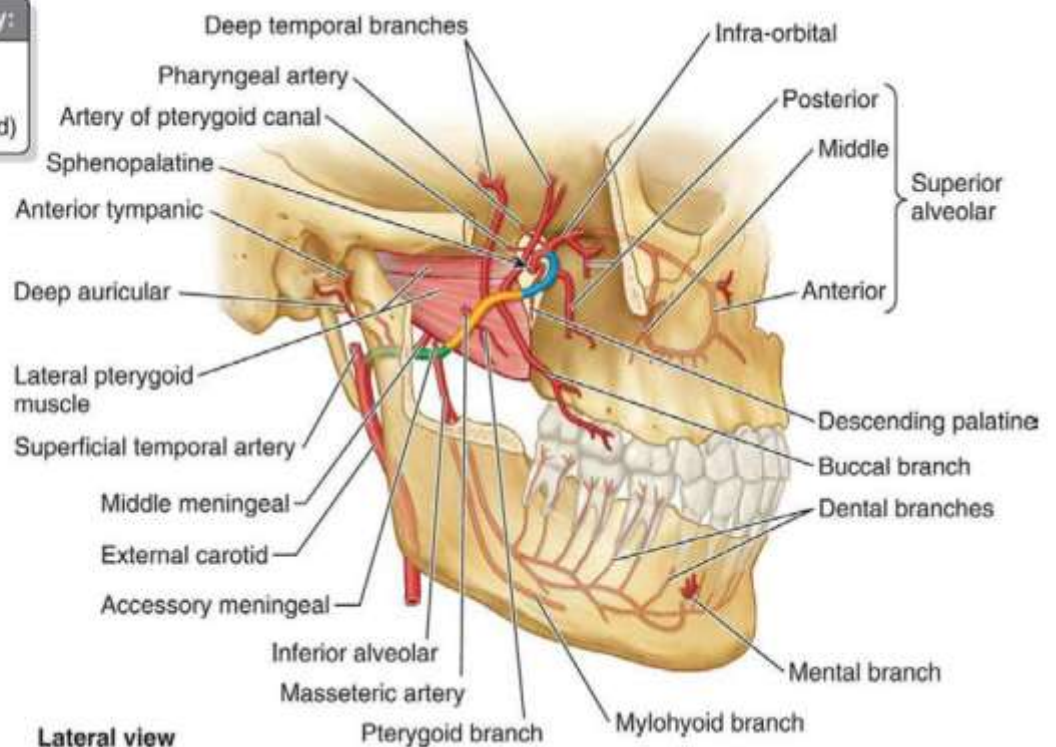
Action: Elevates mandible, closes the jaw with bilateral contraction, helps grinding movements with one side movement.

Maxillary artery:

The **maxillary artery** is the larger of the two terminal branches of the **external carotid artery** (**maxillary artery** and **superficial temporal artery**). It arises posterior to the neck of the mandible. Then it runs **forward medially** and enters the **pterygopalatine fossa**. It is divided into three parts based on its relation to the **lateral pterygoid muscle**.



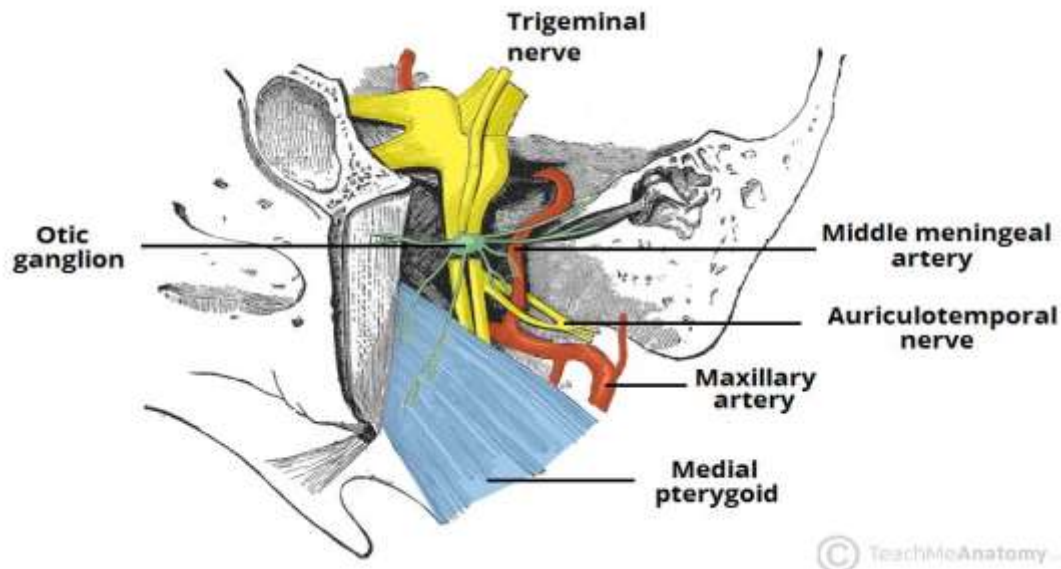
Parts of maxillary artery:	
█	Mandibular (1st)
█	Pterygoid (2nd)
█	Pterygopalatine (3rd)



The five branches from the **first part** or mandibular portion (or bony portion) are :

1-The **deep auricular artery** is the more superficial branch and supplies the external acoustic meatus, passing between the cartilage and bone.

2-The deeper is the **anterior tympanic artery** which passes through the **petrotympanic fissure** to the middle ear to join the circular anastomosis around the tympanic membrane.



3-The **middle meningeal artery** passes vertically upwards to the foramen **spinosum**. It is embraced by the **two roots of the auriculotemporal nerve**.

From the **sympathetic plexus** on the artery a branch enters the **otic ganglion**.

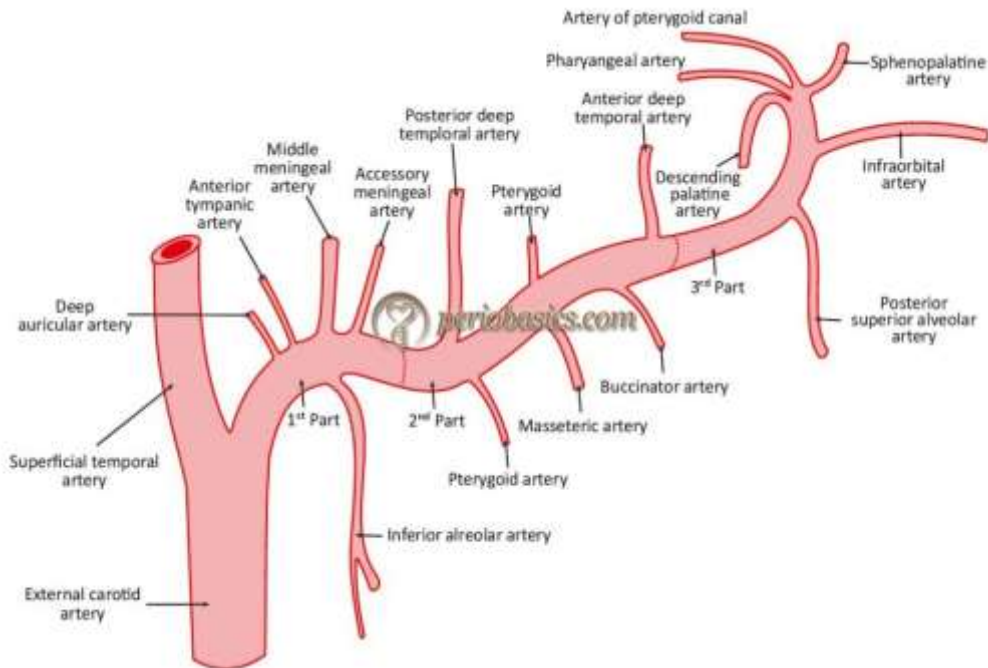
4-The **accessory meningeal artery** passes upwards through the **foramen ovale** and supplies the duramater of the floor of the middle fossa and of the trigeminal ganglion in trigeminal (Meckel's) cave. It is the chief source of blood supply to the trigeminal ganglion.

5-The **inferior alveolar artery** passes downwards and forwards (vein behind it) towards the inferior alveolar nerve and all three enter the mandibular foramen. It passes forwards in the mandible, supplying the pulps of the mandibular molar and premolar teeth and the body of the mandible. Its **mental branch** emerges from the mental foramen and supplies the nearby lip and skin.

The **second part** or pterygoid portion (or muscular portion) of the maxillary artery gives off branches to the **pterygoid muscles, masseter, anterior and posterior deep temporal branches to temporalis** which ascend between the muscle and the temporal fossa and a **small buccal branch** accompanies the **buccal nerve**.

The **third part** or pterygomaxillary portion of the maxillary artery, in the **pterygopalatine fossa**, gives six branches:

1/**posterior superior alveolar** artery gives branches that accompany the corresponding nerves through foramina in the posterior wall of the maxilla.



2/ **pterygoid canal artery**, the *artery of the pterygoid canal* runs into its own canal.

3/**descending palatine** artery [greater and lesser palatine arteries].

4/**pharyngeal artery**, the very small **pharyngeal artery** enters the **palatovaginal canal**.

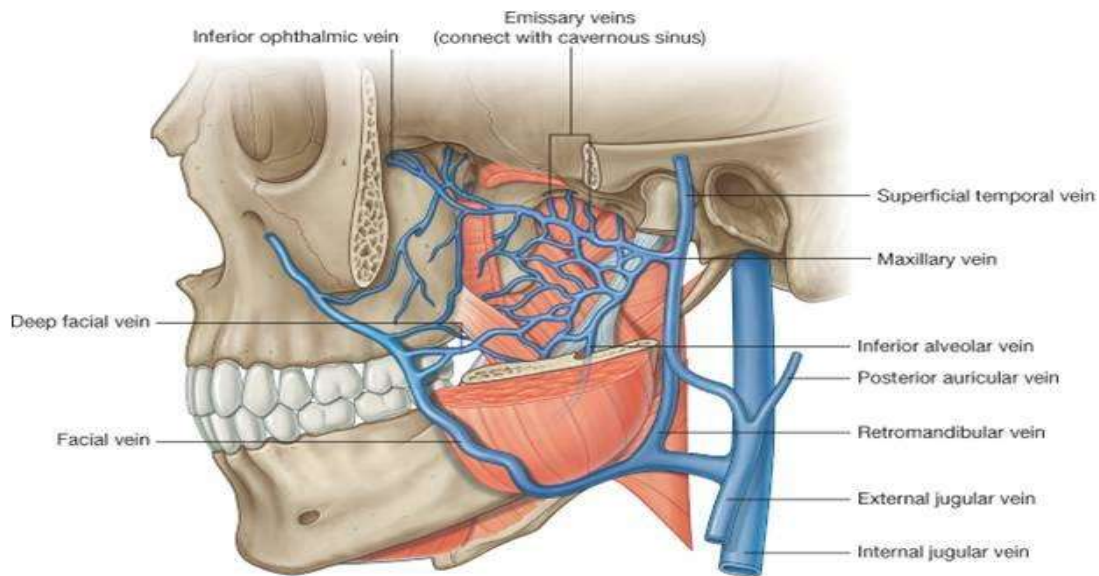
5/**sphenopalatine artery** passes through the sphenopalatine foramen to enter the **nasal cavity** as its main artery of supply.

6/**infraorbital artery**, the artery passes forwards, with the maxillary nerve, through the inferior orbital fissure into the orbit as the small **infraorbital artery**, which continues along the floor of the orbit and infraorbital canal to emerge with the infraorbital nerve on the face; its middle and anterior superior alveolar branches supply maxillary incisor and canine teeth.

The pterygoid plexus:

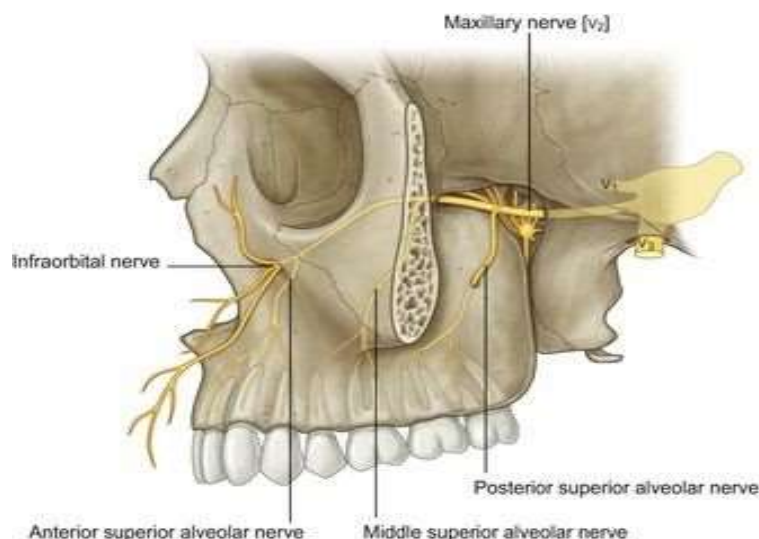
Is a network of very small veins that lie between the temporalis and pterygoid muscles. Most of the veins that accompany the branches of the maxillary artery drain into this plexus

and / or its principal anastomotic veins. These veins are valveless, so flow can go in either direction based on gravity and pressure.



On the other hand, the pterygoid plexus receives the drainage of the *inferior ophthalmic vein*, via the inferior orbital fissure, and the *deep facial vein*. The pterygoid plexus drains into a short maxillary vein which lies deep to the neck of the mandible. The plexus communicates with cavernous sinus via emissary veins.

The posterior superior alveolar nerve:



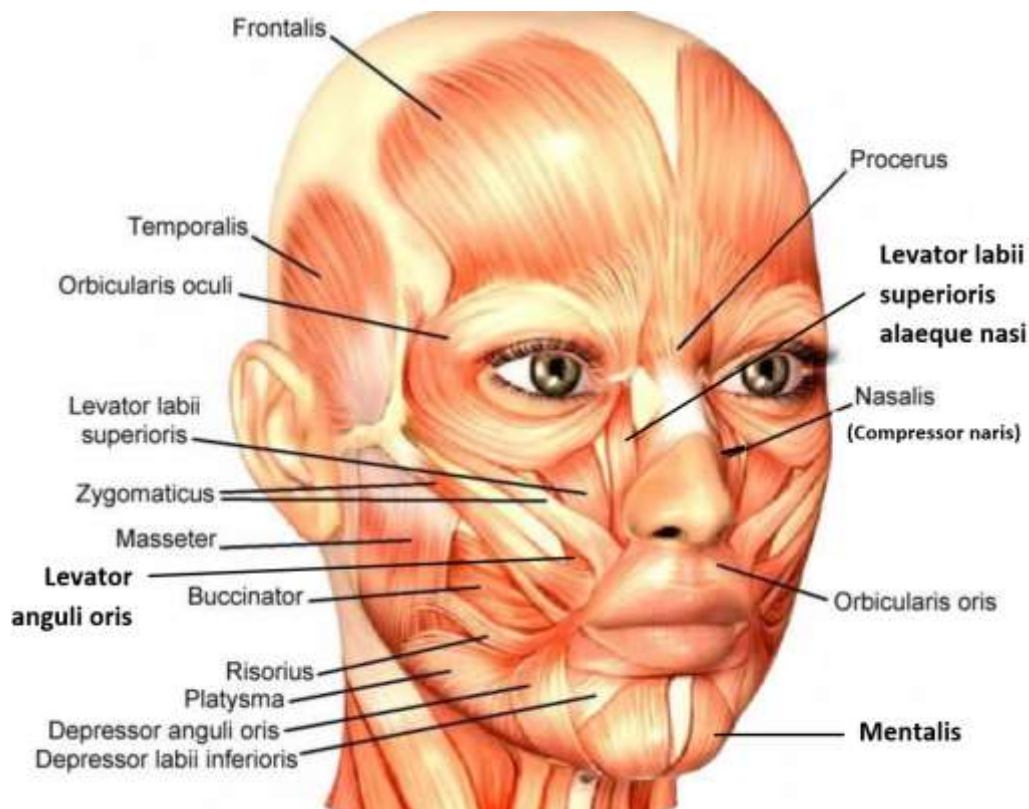
Is a branch of the maxillary nerve, given off in the pterygopalatine fossa and soon dividing into two or three branches which pierce the posterior wall of the maxilla separately. They are distributed to the molar teeth and the mucous membrane of the maxillary sinus.

Part	Course	Branches	Distribution
First (mandibular)	Proximal (posterior) to lateral pterygoid muscle; runs horizontally, deep (medial) to neck of condylar process of mandible and lateral to stylomandibular ligament	Deep auricular artery	Supplies external acoustic meatus, external tympanic membrane, and temporomandibular joint
		Anterior tympanic artery	Supplies internal aspect of tympanic membrane
		Middle meningeal artery	Enters cranial cavity via foramen spinosum to supply periosteum, bone, red bone marrow, dura mater of lateral wall and calvaria of neurocranium, trigeminal ganglion, facial nerve and geniculate ganglion, tympanic cavity, and tensor tympani muscle
		Accessory meningeal artery	Enters cranial cavity via foramen ovale; its distribution is mainly extracranial to muscles of infra-temporal fossa, sphenoid bone, mandibular nerve, and otic ganglion
		Inferior alveolar artery	Descends to enter mandibular canal of mandible via mandibular foramen; supplies mandible, mandibular teeth, chin, mylohyoid muscle
Second (pterygoid)	Adjacent (superficial or deep) to lateral pterygoid muscle; ascends obliquely anterosuperiorly, medial to temporalis muscle	Masseteric artery	Traverses mandibular notch, supplying temporomandibular joint and masseter muscle
		Deep temporal arteries	Anterior and posterior arteries ascend between temporalis muscle and bone of temporal fossa, supplying mainly muscle
		Pterygoid branches	Irregular in number and origin; supply pterygoid muscle
		Buccal artery	Runs antero-inferiorly with buccal nerve to supply buccal fat-pad, buccinator, and buccal oral mucosa
Third (pterygoid-palatine)	Distal (anteromedial) to lateral pterygoid muscle; passes between heads of lateral pterygoid and through pterygomaxillary fissure into pterygopalatine fossa	Posterior superior alveolar artery	Descends on maxilla's infratemporal surface with branches traversing alveolar canals to supply maxillary molar and premolar teeth, adjacent gingiva, and mucous membrane of maxillary sinus
		Infra-orbital artery	Traverses inferior orbital fissure, infra-orbital groove, canal, and foramen; supplies inferior oblique and rectus muscles, lacrimal sac, maxillary canines and incisors teeth, mucous membrane of maxillary sinus, and skin of infra-orbital region of face
		Artery of pterygoid canal	Passes posteriorly through pterygoid canal; supplies mucosa of upper pharynx, pharyngotympanic tube, and tympanic cavity
		Pharyngeal branch	Passes through palatovaginal canal to supply mucosa of nasal roof, nasopharynx, sphenoidal air sinus, and pharyngotympanic tube
		Descending palatine artery	Descends through palatine canal, dividing into greater and lesser palatine arteries to mucosa and glands of hard and soft palate
		Sphenopalatine artery	Terminal branch of maxillary artery, traverses sphenopalatine foramen to supply walls and septum of nasal cavity; frontal, ethmoidal, sphenoid, and maxillary sinuses; and anteriormost palate

The Face: Lec [3] part 2

Muscles of Facial Expression:

- 1- The muscles of the face are embedded in the superficial fascia, and most arise from the bones of the skull and are inserted into the skin.
- 2- The orifices of the face, namely, the orbit, nose, and mouth, are guarded by the eyelids, nostrils, and lips, respectively.
- 3- Facial muscles act as sphincters or dilators of these structures.
- 4- A secondary function of the facial muscles is to modify the expression of the face.
- 5- All the muscles of the face are developed from the second pharyngeal arch and are supplied by the facial nerve.

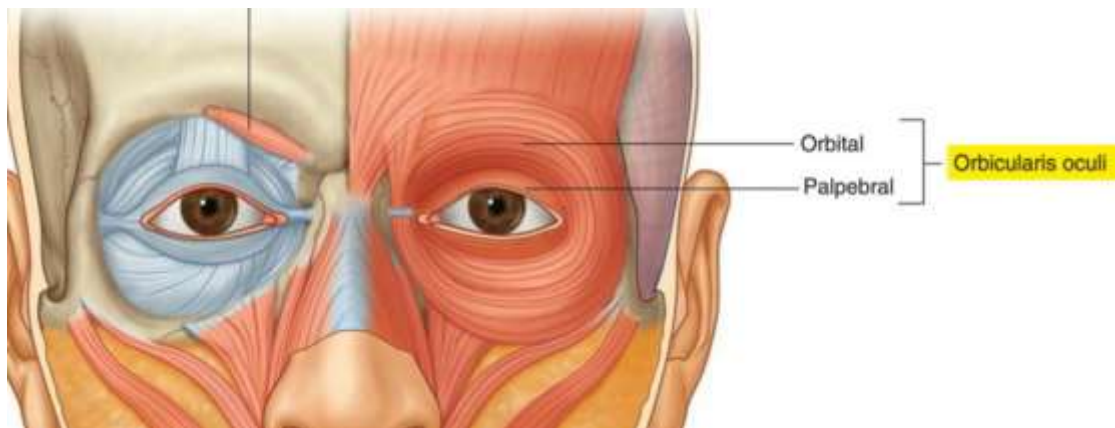


Muscles of the eyelids: The sphincter muscle of the eyelids is the **orbicularis oculi**, and has a dilator mechanism consisting of **levator palpebrae superioris** and **frontalis** (which is part of the scalp).

Orbicularis oculi has a palpebral part, and an orbital part

1. The **palpebral part** originated from the **medial palpebral ligament** and inserted in the **lateral palpebral raphe**.

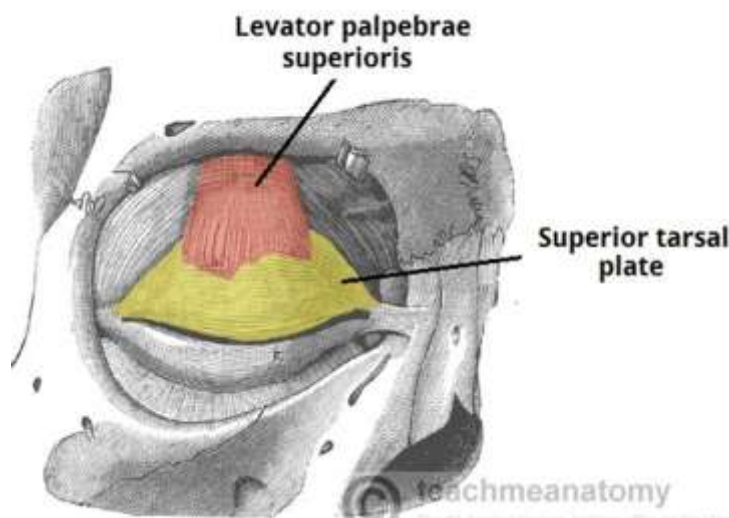
2. The **orbital part**, arises from the **medial palpebral ligament**, the **frontal bone**, and the **frontal process of the maxilla**. The fibers loops and return to origin.



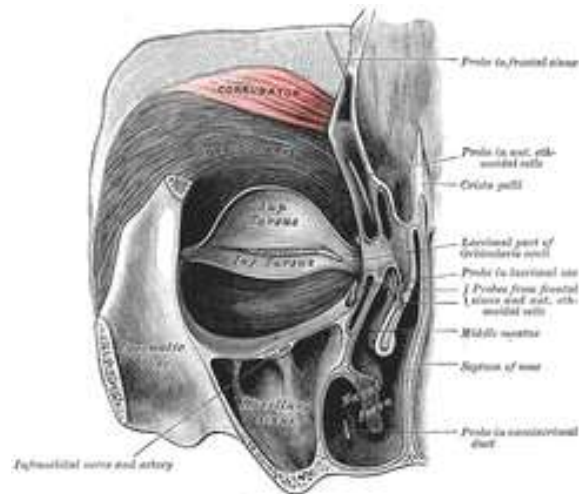
Nerve supply. By temporal and zygomatic branches of the facial nerve.

Action: Closes the eyelids. Contraction of the palpebral fibers closes the lids gently. When the orbital and palpebral parts contracting together close the eyelids toughly.

Note: **Levator palpebrae superioris** is the antagonist of the upper palpebral fibers of orbicularis oculi and **occipitofrontalis** opposes the orbital part.



The **corrugator supercilii** is a small, narrow, pyramidal muscle. It is located at the medial end of the eyebrow, originated from supraorbital margin, and inserted in the skin of eyebrow.

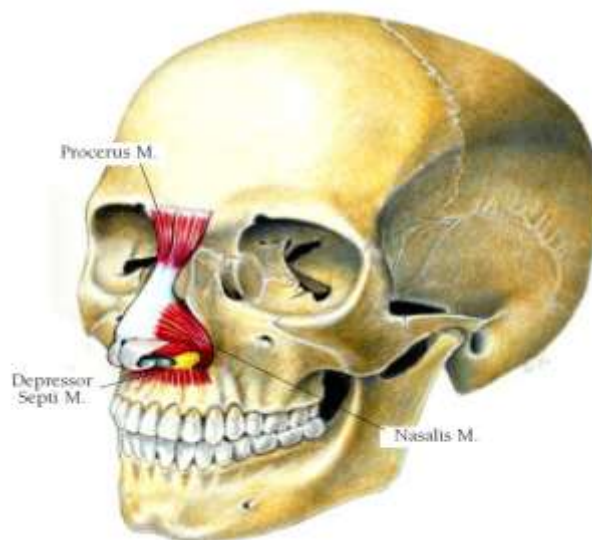


function: The corrugator draws the eyebrow downward and medially, producing the vertical wrinkles of the forehead, as in frowning.

Muscles of the nostrils:

Compressor naris: originated from **maxilla** and inserted in the **aponeurosis of bridge of nose**.

Function: It compresses nasal cartilages



Dilator naris: originated from **maxilla** and inserted in the **ala of nose**.

Function: It widens nasal aperture.

Procerus: arises from the **nasal bone** and inserted into the **skin between the two eyebrows**.

function: The procerus wrinkles the skin of the nose. Its contraction can produce transverse wrinkles.

In addition, **levator labii superioris alaeque nasi** and **depressor septi** contribute to widening the nostril.

Depressor septi arises from the **maxilla above the central incisor** and is attached to the **nasal septum**. **Nerve supply:** by buccal branches of the facial nerve.

Muscles of the lip:

The sphincter muscle of the lip is the **orbicularis oris** and the dilator mechanism consists of the remainder of the facial muscles, which radiate outwards from the lips .

Muscles of Facial Expression

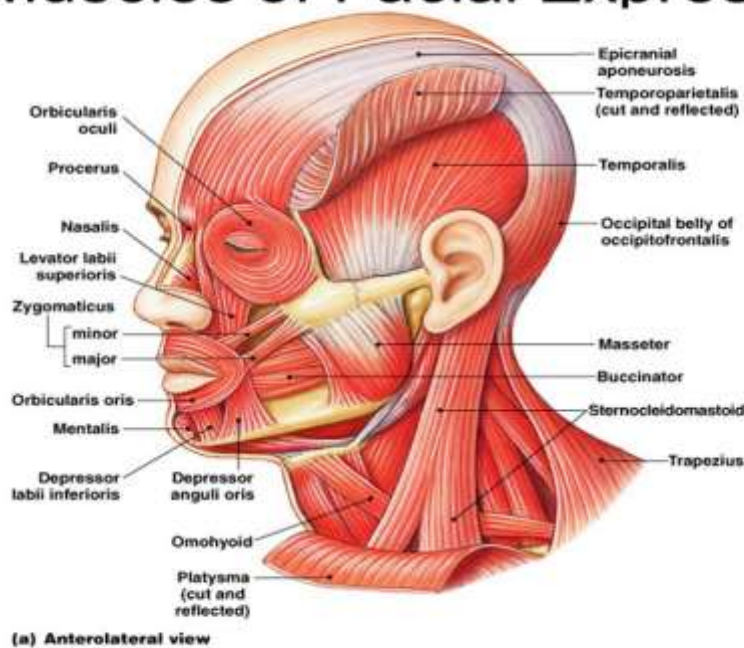


Figure 11-4a

Orbicularis oris:

Origin and insertion: The fibers encircle the oral orifice within the substance of the lips. Some of the fibers arises from **the maxilla** above and **the mandible** below and from the **other muscles of the cheek**. It inserts onto the **skin and mucous membrane of the lips**.

Nerve supply: Buccal and mandibular branches of the facial nerve

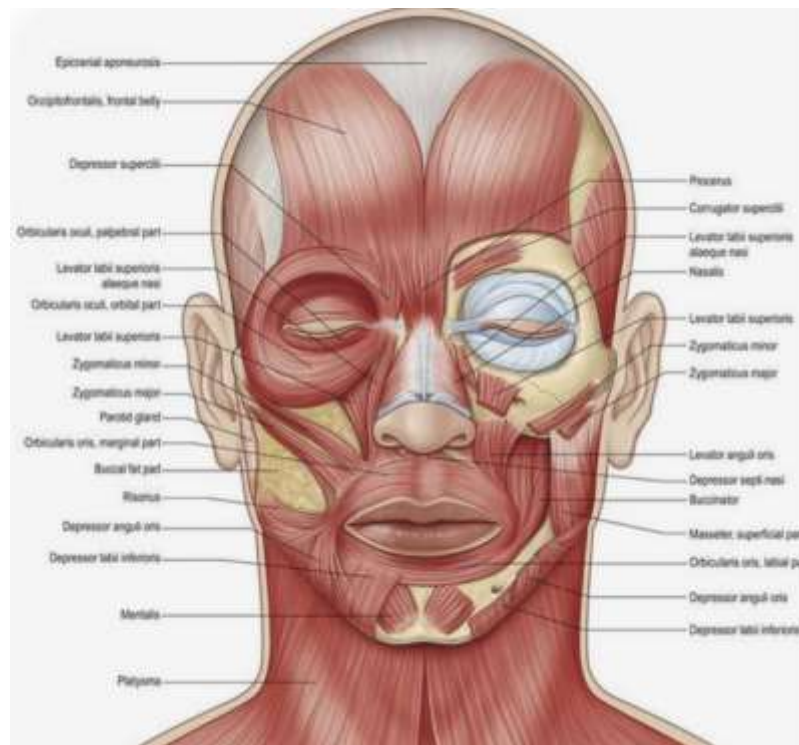Action: Compresses the lips together, Contraction of the orbicularis oris causes narrowing of the mouth (the whistling expression).

Dilator muscles of the lips:

The dilator muscles radiate out from the lips, and their action is to separate the lips. Traced from the side of the nose to the angle of the mouth and then below the oral aperture, the muscles are named as follows:

■ Levator labii superioris alaeque nasi ■ Levator labii superioris ■ Levator anguli oris (deep to the zygomatic muscles) ■ Zygomaticus minor ■ Zygomaticus major ■ Risorius ■ Depressor anguli oris ■ Depressor labii inferioris ■ Mentalis

Nerve Supply: Buccal and mandibular branches of the facial nerve



Levator labii superioris alaeque nasi: arises from the frontal process of the maxilla and is inserted into the ala of the nose and the upper lip; it elevates both.

Levator labii superioris: arises from the inferior orbital margin and is inserted into the upper lip, which it elevates. The muscle overlies the exit of the infraorbital nerve.

Levator anguli oris: arises from the canine fossa below the infraorbital foramen (the infraorbital nerve lies sandwiched between it and the overlying levator labii superioris). The fibers of this muscle, converge and inserted in to the modiolus.

Zygomaticus minor: originates from the zygomaticomaxillary suture and **zygomaticus major:** originates from the surface of the zygomatic bone the two muscles inserted in to the modiolus.

Risorius: is a variable muscle that converges on the modiolus from the parotid fascia. All these muscles are supplied by buccal branches of the facial nerve.

Depressor anguli oris: arises from the mandible below the mental foramen. its fibers insert in the modiolus.

Depressor labii inferioris: arises from the mandible in front of the mental foramen, its fibers are inserted into the lower lip.

Mentalis is a muscle that arises near the midline of the mandible. Its fibers pass downwards to reach the skin. It is an elevator of the skin of the chin. These muscles are supplied by the mandibular branch of the facial nerve.

Muscle of the Cheek: Buccinator

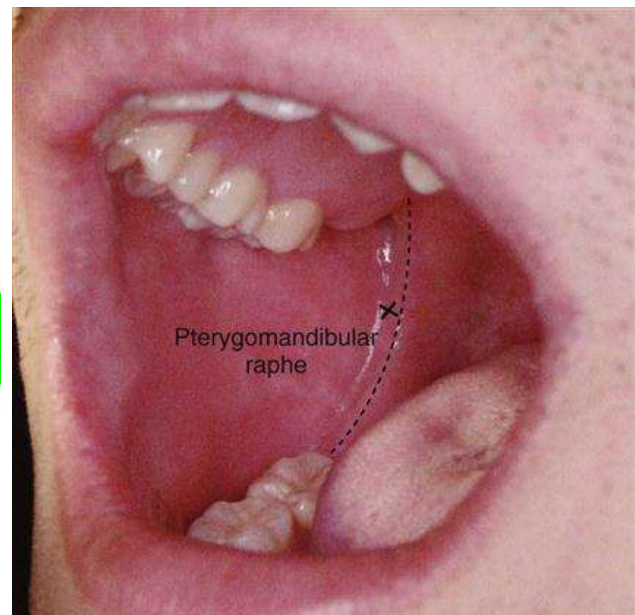
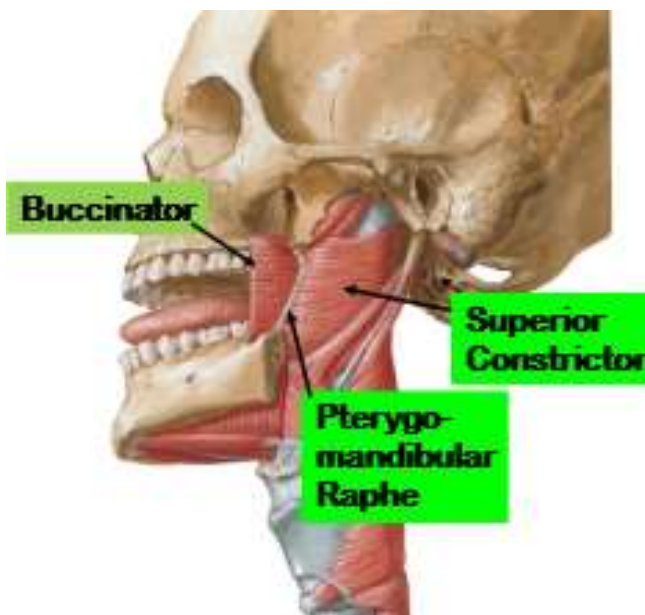
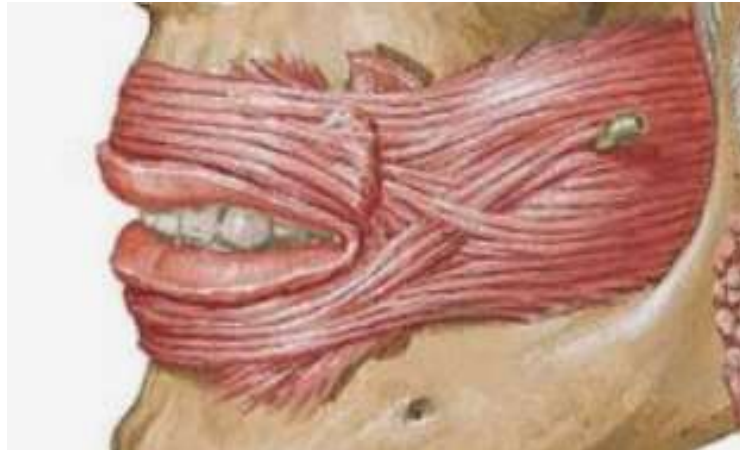Origin: From the outer surface of the alveolar margins of the maxilla and mandible opposite the molar teeth and from the **pterygomandibular ligament**.

Insertion:

The muscle fibers pass forward, forming the muscle layer of the cheek. The muscle is pierced by the **parotid duct**. At the angle of the mouth the central fibers decussate, those from below entering the upper lip and those from above entering the lower lip; the highest and lowest fibers continue into the upper and lower lips, respectively, without intersecting. The buccinator muscle thus blends and forms part of the orbicularis oris muscle.

Nerve supply: Buccal branch of the facial nerve

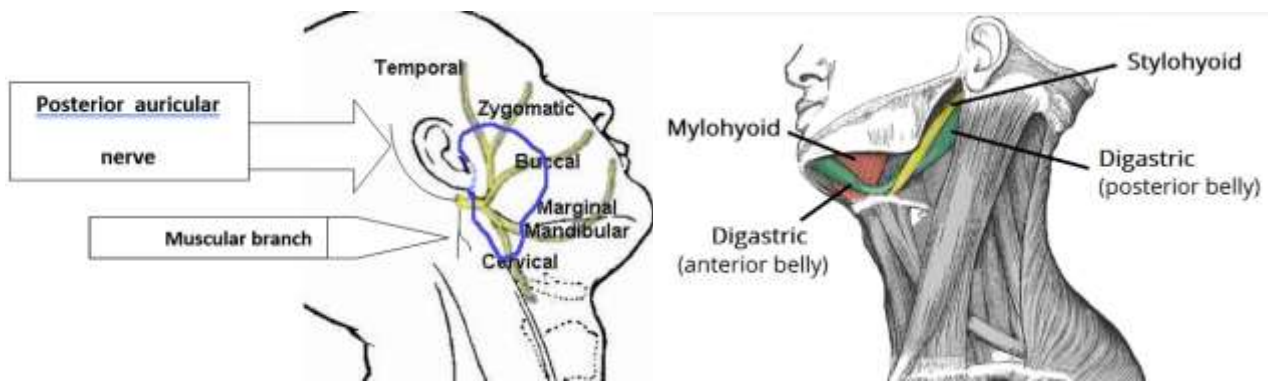Action: Compresses the cheeks and lips against the teeth



Nerve supply of face muscles

The **facial nerve** emerges from the stylomastoid foramen. It immediately gives off the **posterior auricular nerve** which passes upwards behind the ear to supply **auricularis posterior** and **superior** and the **occipital belly** of occipitofrontalis.

A **muscular branch** is next given off which divides to supply the **posterior belly of digastric** and **stylohyoid**. The nerve now runs forward within the substance of the parotid gland, it divides into five branches. These branches lie superficial to the **retromandibular vein** and the **external carotid artery**.

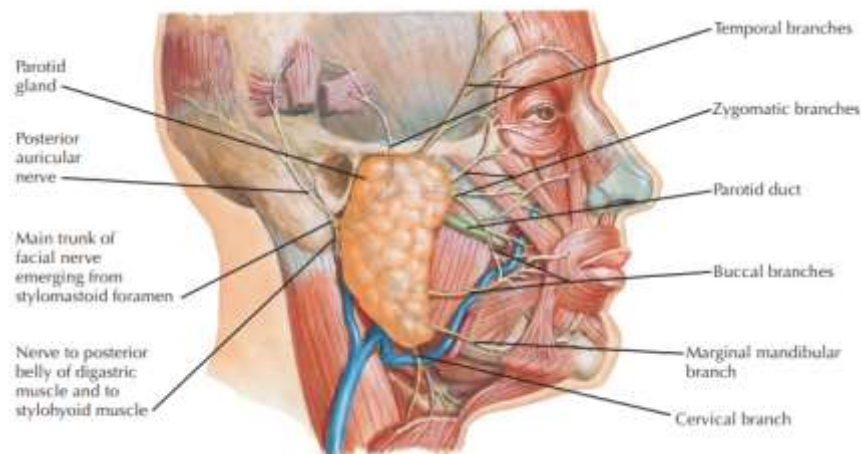


1-The **temporal branches**: emerges from the upper border of the gland and supplies the **anterior and superior auricular** muscles, the **frontal belly** of the occipitofrontalis, the **orbicularis oculi**, and the **corrugator supercilii**.

2-The **zygomatic branches**: emerges from the anterior border of the gland and supplies the **orbicularis oculi**.

3-The **buccal branches**: emerges from the anterior border of the gland supplies the buccinator muscle and the muscles of the upper lip and nostril.

4- The **marginal mandibular (mandibular) branch**: emerges from the anterior border of the gland and supplies the muscles of the lower lip.

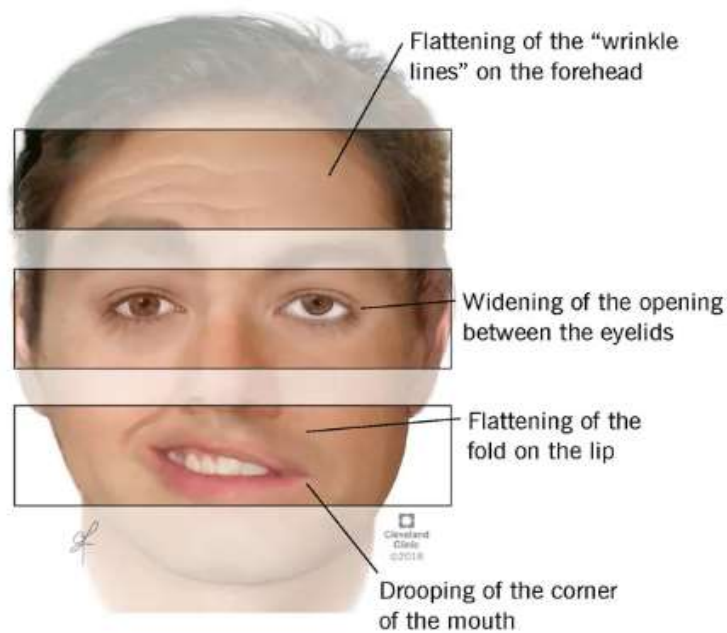


5-The **cervical branch** passes downwards from the lower border of the parotid gland and supplies platysma, it may cross the lower margin of the body of the mandible to supply the depressor anguli oris muscle.

Note : The details of the pattern of branching of the facial nerve differs in different individuals and even on the two sides of the face of the same person.

Clinical notes:**Facial Muscle Paralysis:**

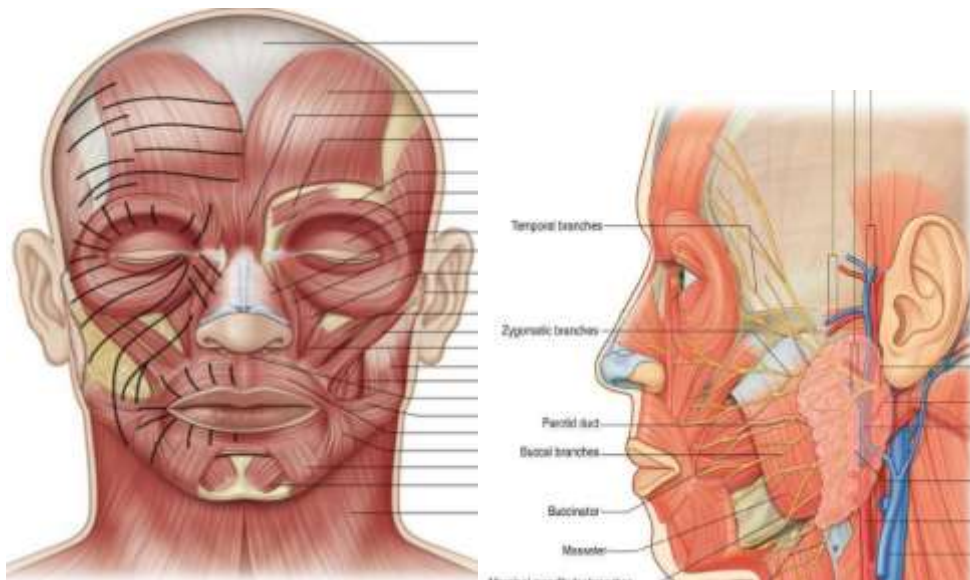
Various viruses may trigger **Bell's palsy**. The condition occurs when **swelling** or **inflammation** temporarily puts pressure on the facial nerve. This pressure weakens the function of the nerve making it difficult to control facial muscles or expressions. As the inflammation subsides, the nerve starts to function again. It may take several months for symptoms to go away.



The Face: Lec [2] part 1

Skin of the face:

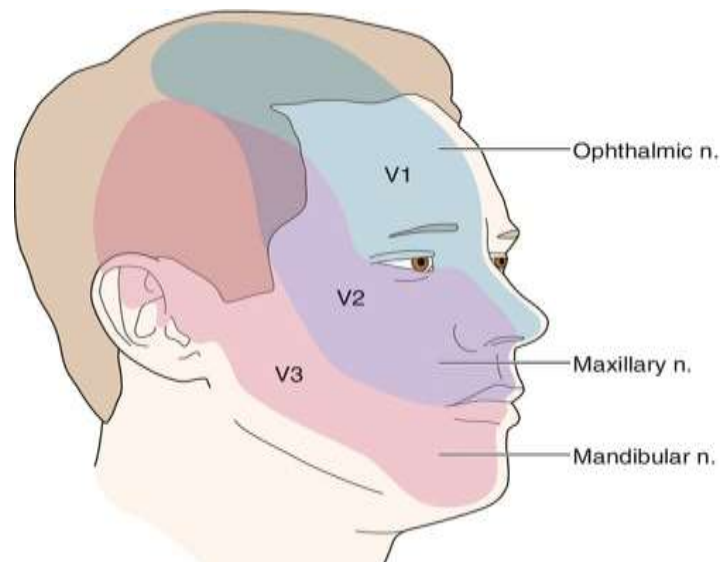
- 1- The skin of the face possesses numerous sweat and sebaceous glands.
- 2- It is connected to the underlying bones by loose connective tissue (superficial fascia) , in which are embedded the muscles of facial expression.
- 3- No deep fascia is present in the face.
- 4- Wrinkle lines of the face result from the repeated folding of the skin perpendicular to the long axis of the underlying contracting muscles.



Note : Deep fascia is absent in the face, except over the parotid gland where it forms the parotid fascia, over masseter muscles where it forms massetric fascia & over the buccinator forms the buccopharyngeal fascia.

Sensory nerve supply of the face:

The trigeminal nerve has three divisions: ophthalmic, maxillary and mandibular. The skin of the face is supplied by the branches of the three divisions of the trigeminal nerve except for the small area over the angle of the mandible and the parotid gland and part of the auricle of the ear [lower part], which supplied by the great auricular nerve (C2 and 3).

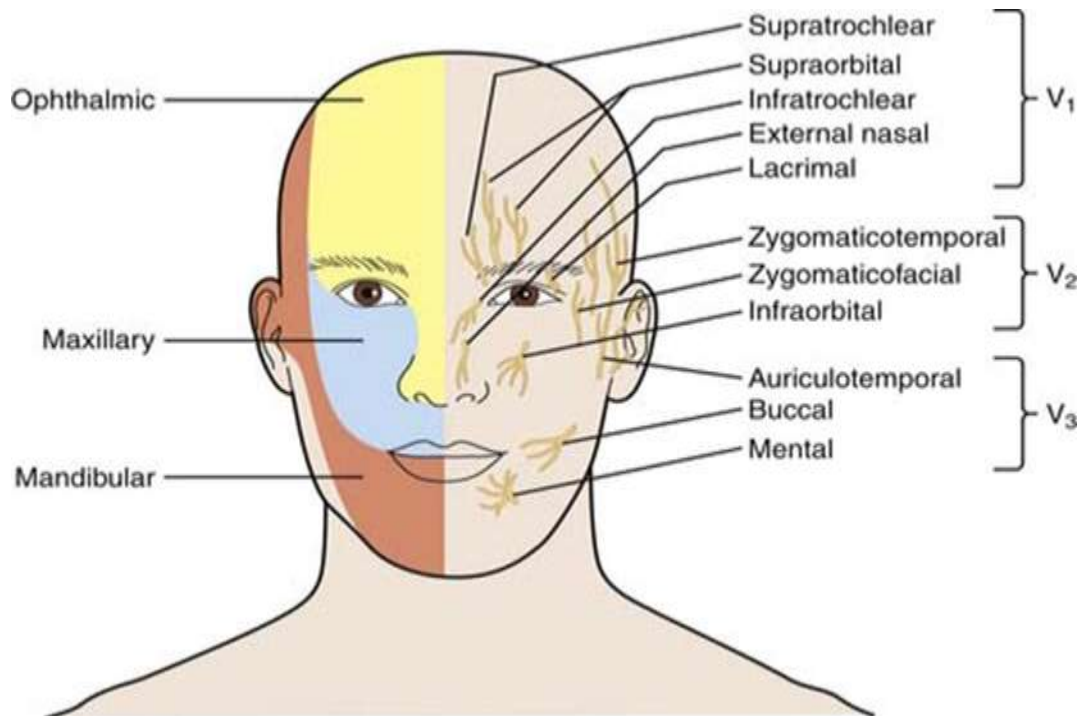


The ophthalmic nerve supplies the region developed from the **frontonasal process**; the maxillary nerve serves the region developed from the **maxillary process** of the first pharyngeal arch; and the mandibular nerve serves the region developed from the **mandibular process** of the first pharyngeal arch.


Note: These nerves not only supply the skin of the face, but also supply **proprioceptive fibers** to the underlying **muscles of facial expression**.

Ophthalmic nerve branches:

- 1- The **lacrimal nerve** supplies the **skin and conjunctiva** of the lateral part of the upper eyelid
- 2- The **supraorbital nerve** winds around the upper margin of the orbit at the supraorbital notch. It divides into branches that supply the **skin and conjunctiva** on the **central part of the upper eyelid**; it also supplies **the skin of the forehead**.
- 3- The **supratrochlear nerve** winds around the upper margin of the orbit medial to the supraorbital nerve. It divides into branches that supply **the skin and conjunctiva on the medial part of the upper eyelid** and the **skin over the forehead**, close to the median plane.



- 4- The **infratrochlear nerve** leaves the orbit below the pulley of the superior oblique muscle (trochlea). It supplies the skin and conjunctiva on the medial part of the upper eyelid and the adjoining part of the side of the nose.

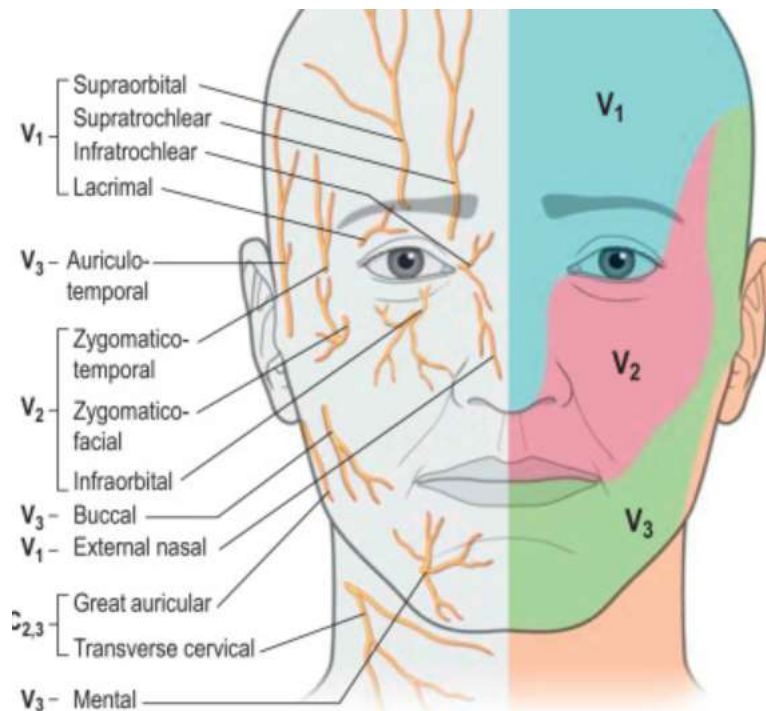


- 5- The **external nasal nerve** leaves the nose by emerging between the nasal bone and the upper nasal cartilage. It supplies the skin on the side of the nose down as far as the tip.

Note: The supraorbital and supratrochlear nerves are branches of the **frontal nerve [branch of the ophthalmic nerve]**. The infratrochlear and external nasal nerves are derived from the **nasociliary [branch of the ophthalmic nerve]**

Maxillary nerve branches:

1- The **infraorbital nerve** is a direct continuation of the maxillary nerve. It enters the orbit and appears on the face through the **infraorbital foramen**. It immediately divides into numerous small branches, which radiate out from the foramen and supply the skin of the **lower eyelid and cheek**, the **side of the nose**, and the **upper lip**.



2- The **zygomaticofacial nerve** passes onto the face through a small foramen on the lateral side of the zygomatic bone. It supplies the skin over the **prominence of the cheek**.

3- The **zygomaticotemporal nerve** emerges in the temporal fossa through a small foramen on the posterior surface of the zygomatic bone. It supplies **the skin over the temple**.

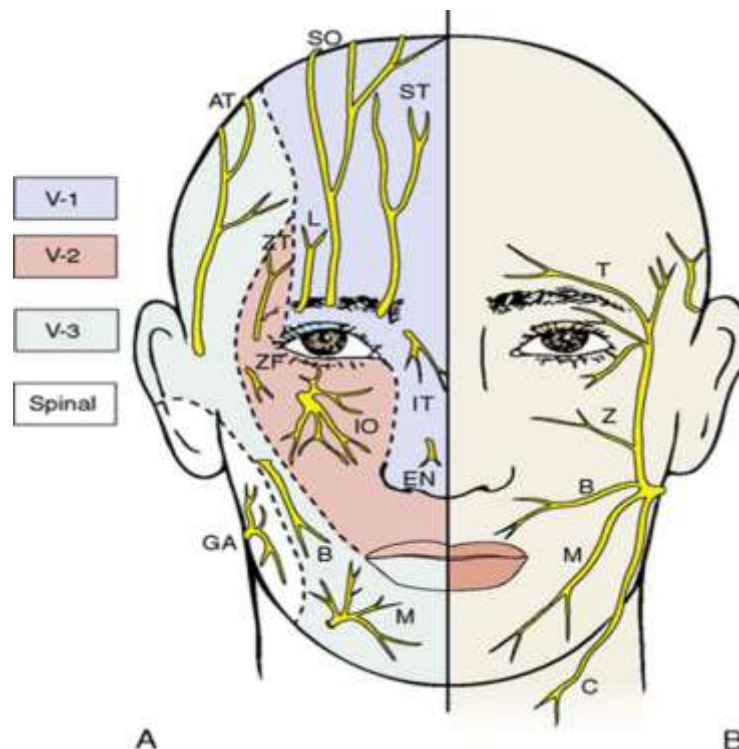
Mandibular Nerve branches:

1- The **mental nerve** [branch of inferior alveolar nerve which is branch of mandibular division of trigeminal nerve]. emerges from the mental foramen of the mandible, it

breaks up into branches; these radiate away from the mental foramen to supply the skin of the **lower lip** and **chin**.

2-The **buccal nerve** supplies the skin over a small area of the **cheek**. The **buccal nerve** gives off cutaneous branches before it pierces the buccinator muscle to supply **oral mucous membrane**.

3-The **auriculotemporal nerve** ascends from the upper border of the **parotid gland** between the **superficial temporal vessels** and the **auricle**. It supplies the skin of the upper part of **auricle**, the **external auditory meatus**, the **outer surface of the tympanic membrane**, and the **skin of the scalp above the auricle**.



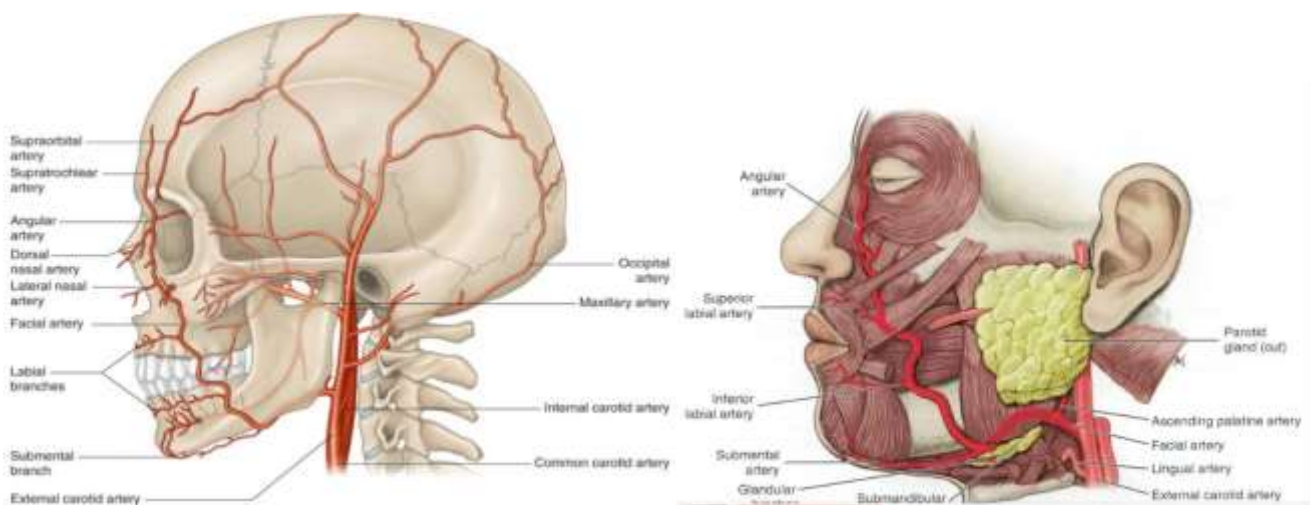
Blood supply of the face:

The face receives a rich blood supply from two main vessels, **the facial and superficial temporal arteries**, which are supplemented by several small arteries that accompany the sensory nerves of the face.

1- The facial artery:

Arises from the external carotid artery. Having arched upward and over the **submandibular salivary gland**, it curves around the **inferior margin of the body of the**

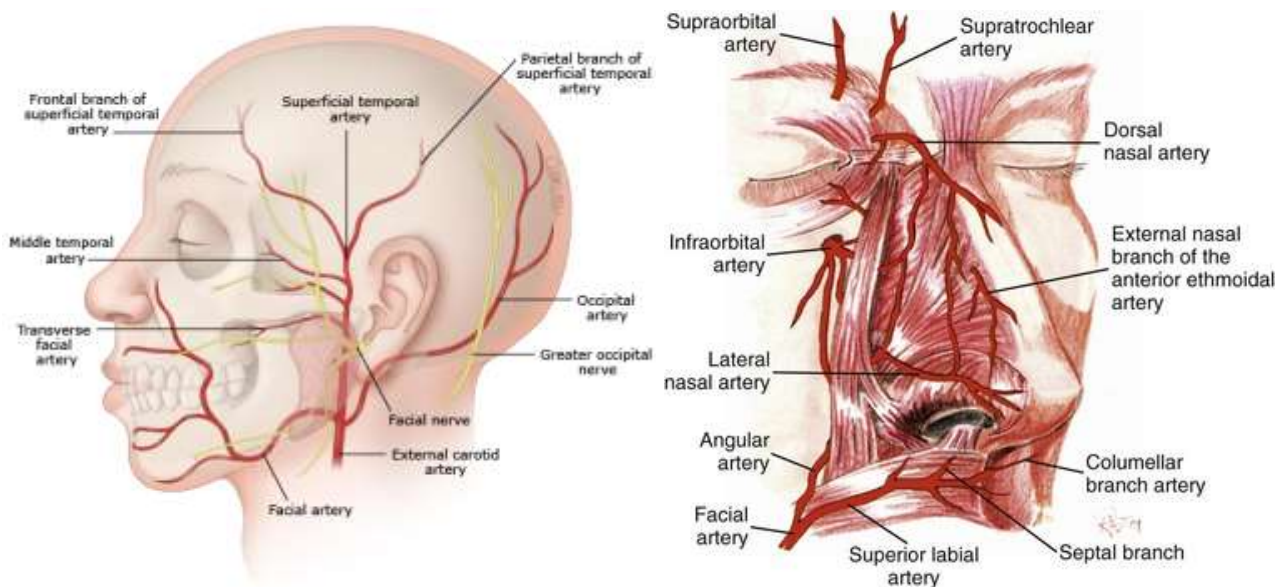
mandible at the anterior border of the **masseter muscle**. It is here that the pulse can be easily felt. It runs upward in a **tortuous course** toward the angle of the mouth and is covered by the **platysma and the risorius muscles**. It then ascends deep to the **zygomaticus muscles and the levator labii superioris muscle** and runs along the side of **the nose** to the **medial angle of the eye**, where it anastomoses with the terminal branches of the **ophthalmic artery**.



Branches:

- A. The **submental artery** arises from the facial artery at the lower border of the body of the mandible. It supplies the skin of the chin and lower lip.
- B. The **inferior labial artery** arises near the angle of the mouth. It runs medially in the lower lip and anastomoses with its fellow of the opposite side.
- C. The **superior labial artery** arises near the angle of the mouth. It runs medially in the upper lip and gives branches to the **septum and ala of the nose**.
- D. The **lateral nasal artery** arises from the facial artery alongside the nose. It supplies the skin on the side and dorsum of the nose.
- E. The **angular artery** terminal branch of facial artery

- 2- **The Superficial temporal artery**: the smaller terminal branch of the external carotid artery, commences in the parotid gland. It ascends in front of the auricle to supply the scalp. The **transverse facial artery**, a branch of the superficial temporal artery, arises within the parotid gland. It runs forward across the cheek just above the parotid duct.



- 3- **Supraorbital** and 4- **Supratrochlear** branches of the **ophthalmic artery**. supply the skin of the forehead
- 5- **Dorsal nasal artery**, branch of the **ophthalmic artery**, supplies skin at the root of the nose.
- 6- **External nasal artery** branch from **ophthalmic artery**, supplies skin at the bridge of the nose.

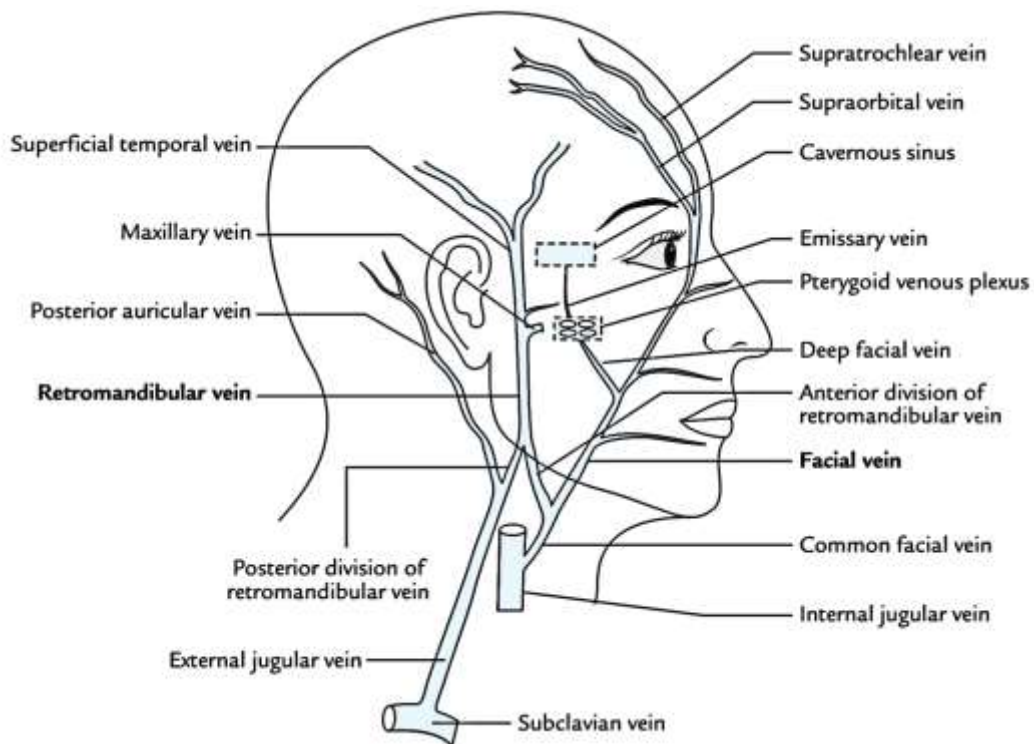
Veins of the Face:

Facial Vein: The beginning of **facial vein [angular vein]** is formed at the medial angle of the eye by the union of the **supraorbital** and **supratrochlear** veins. It is connected through the **ophthalmic veins** with the **cavernous sinus**. this connection is of great clinical importance because it provides a pathway for the spread of **infection** from the **face** to the **cavernous sinus**. The **facial vein** descends downward, backward and follows a straight course behind the convoluted **facial artery** to the lower margin of

the body of the mandible. It crosses superficial to the **submandibular gland** and is joined by the **anterior division of the retromandibular vein**, to form **common facial vein** which drains into the **internal jugular vein**.

Tributaries The **facial vein** receives tributaries that correspond to the branches of the **facial artery**. It is joined to the **pterygoid venous plexus** by the **deep facial vein** (runs between the **masseter and buccinator muscles**), and to the **cavernous sinus** by the **superior ophthalmic vein**.

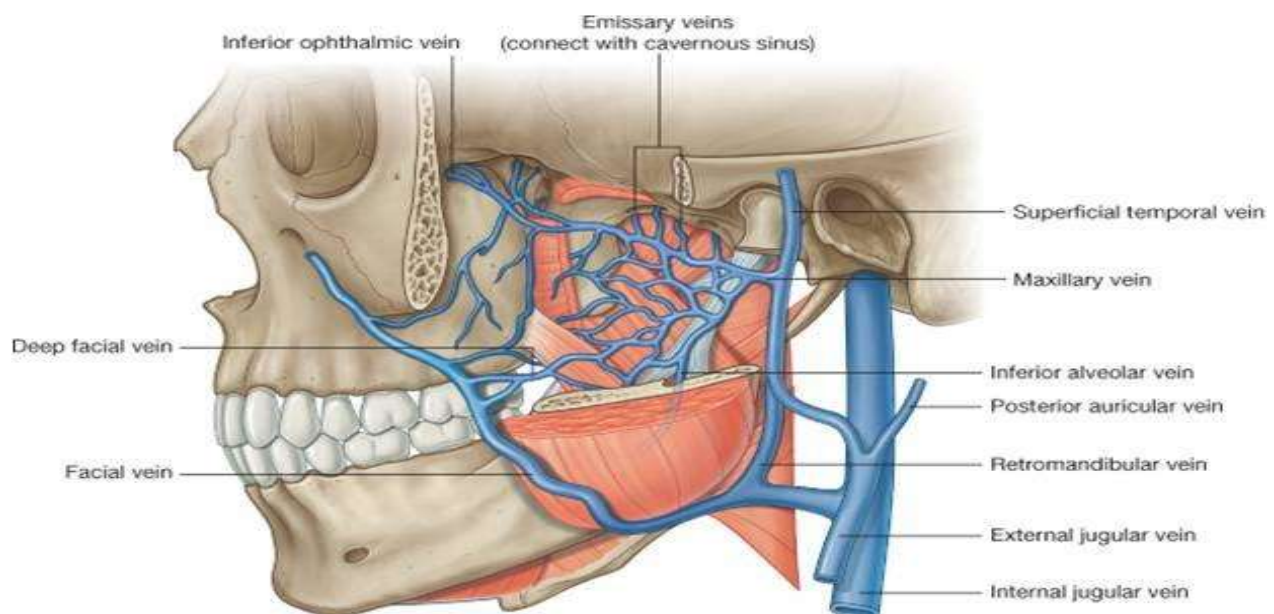
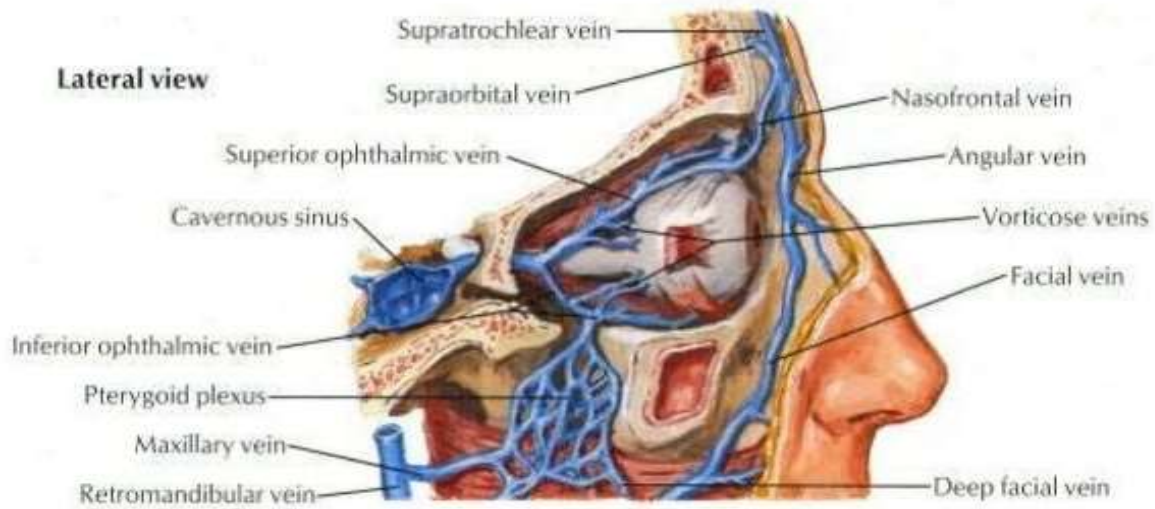
Note: The venous return from the face is normally entirely superficial.



Superficial Temporal Vein:

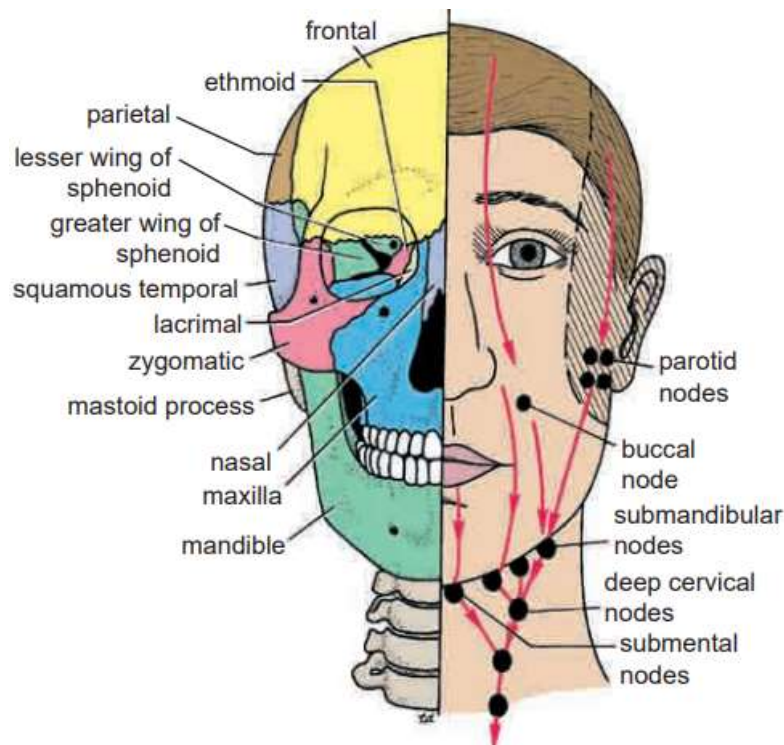
The **transverse facial vein** joins the **superficial temporal vein** within the parotid gland and then, the **superficial temporal vein** joins the **maxillary vein** to form the **retromandibular vein**. The **retromandibular vein** passes downwards in the substance of the parotid gland and on leaving the gland, it divides into an anterior branch, which joins the **facial vein**, and a posterior branch, which joins the **posterior auricular vein** to form the **external jugular vein**. This courses down in the subcutaneous tissue over

sternocleidomastoid and pierces the investing layer of deep cervical fascia to enter the posterior triangle and empty into the **subclavian vein**.



Lymph Drainage of the Face:

- 1- Lymph from the **forehead** and the **anterior part of the face** drains into the **submandibular lymph nodes**. A few **buccal lymph nodes** may be present along the course of these lymph vessels.
- 2- The **lateral part of the face**, including the **lateral parts of the eyelids**, is drained by lymph vessels that end in the **parotid lymph nodes**.



- 3- The **central part of the lower lip** and the **skin of the chin** are drained into the **submental lymph nodes**.

Clinical notes:

1-Sensory Innervation and Trigeminal Neuralgia:

*Usually affects the maxillary (V2) or mandibular (V3) division of the trigeminal nerve; rarely affects the ophthalmic division (V1).

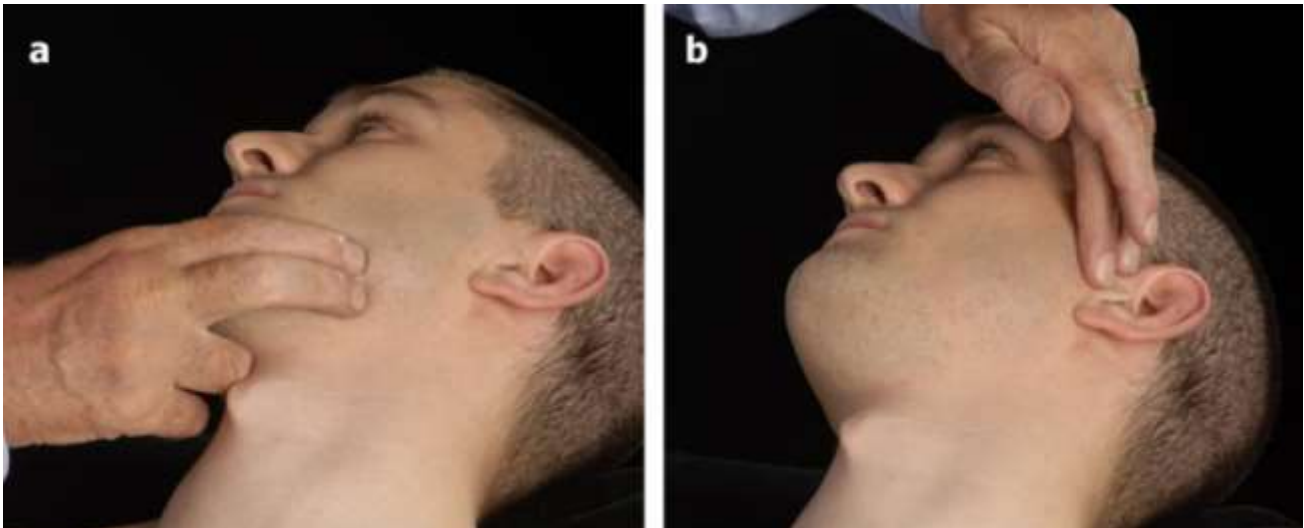
*More common in the 5th and 6th decades of life.

*Cause is unknown—theories involve nerve irritation from abnormal vascularity or tumor compression, or a nerve injury.

* lasting 1 to 2 minutes pain along one of the divisions of the trigeminal nerve.

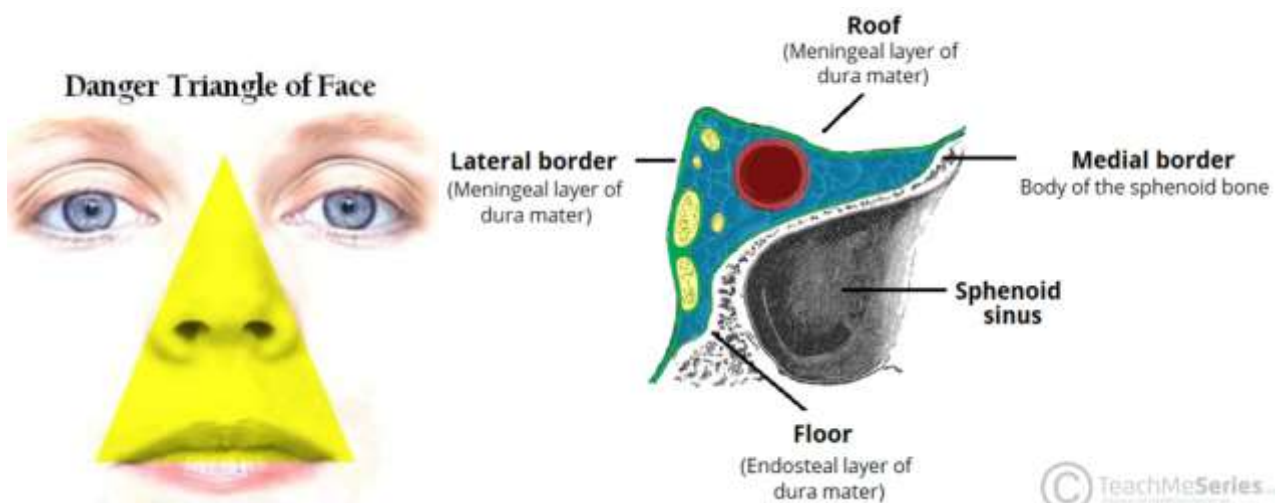
*Pain normally is initiated by (putting on makeup, washing the face, shaving, mastication, or brushing teeth)

2-Facial Arteries and Taking the Patient's Pulse:



The **superficial temporal artery**, as it crosses the zygomatic arch in front of the ear, and the **facial artery**, as it winds around the lower margin of the mandible level with the anterior border of the masseter, are commonly used by the anesthetist to take the patient's pulse.

3-Facial Infections and Cavernous Sinus Thrombosis:



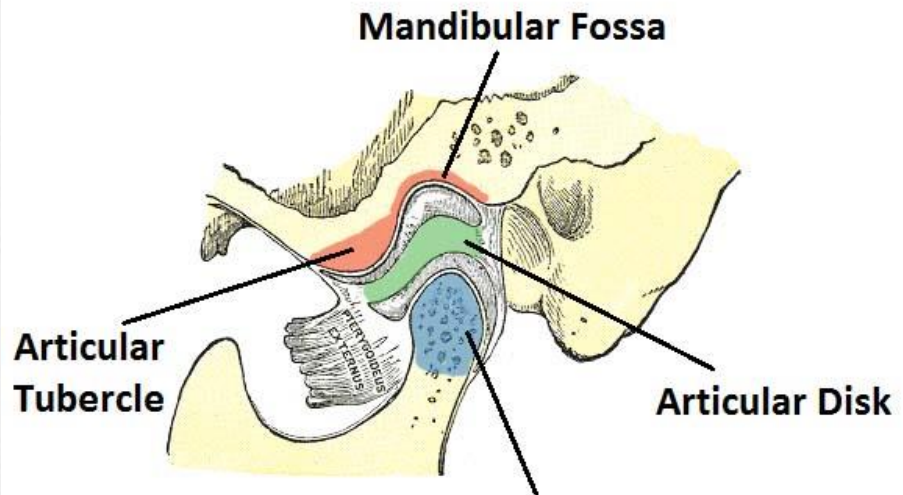
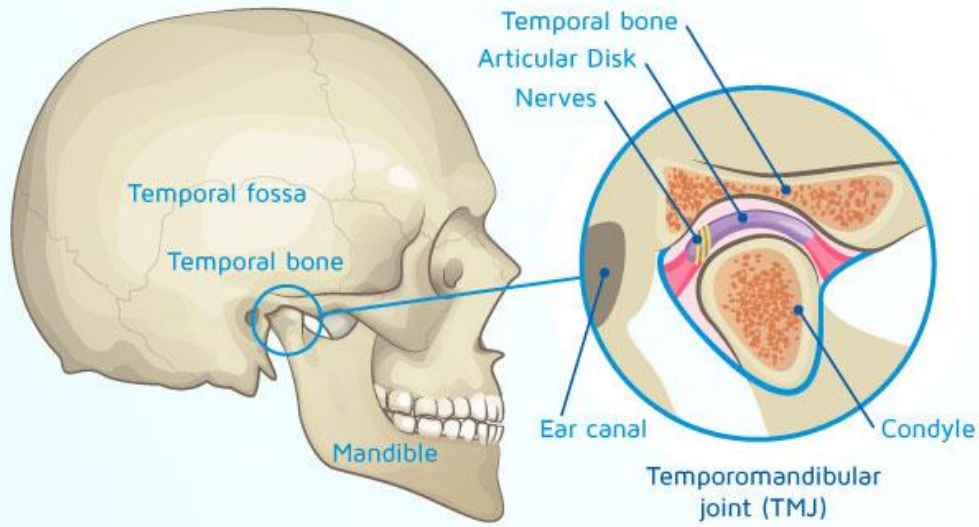
The area of facial skin bounded by the **nose**, the **eye**, and the **upper lip** is a potentially **dangerous zone** to have an **infection**. For example, a **boil** in this region can cause **thrombosis of the facial vein**, with spread of organisms through the **inferior or superior ophthalmic veins to the cavernous sinus**. The resulting cavernous sinus thrombosis may be fatal unless adequately treated with antibiotics.

Temporomandibular joint

Lec

Assis. Lec. Noor Ghazi

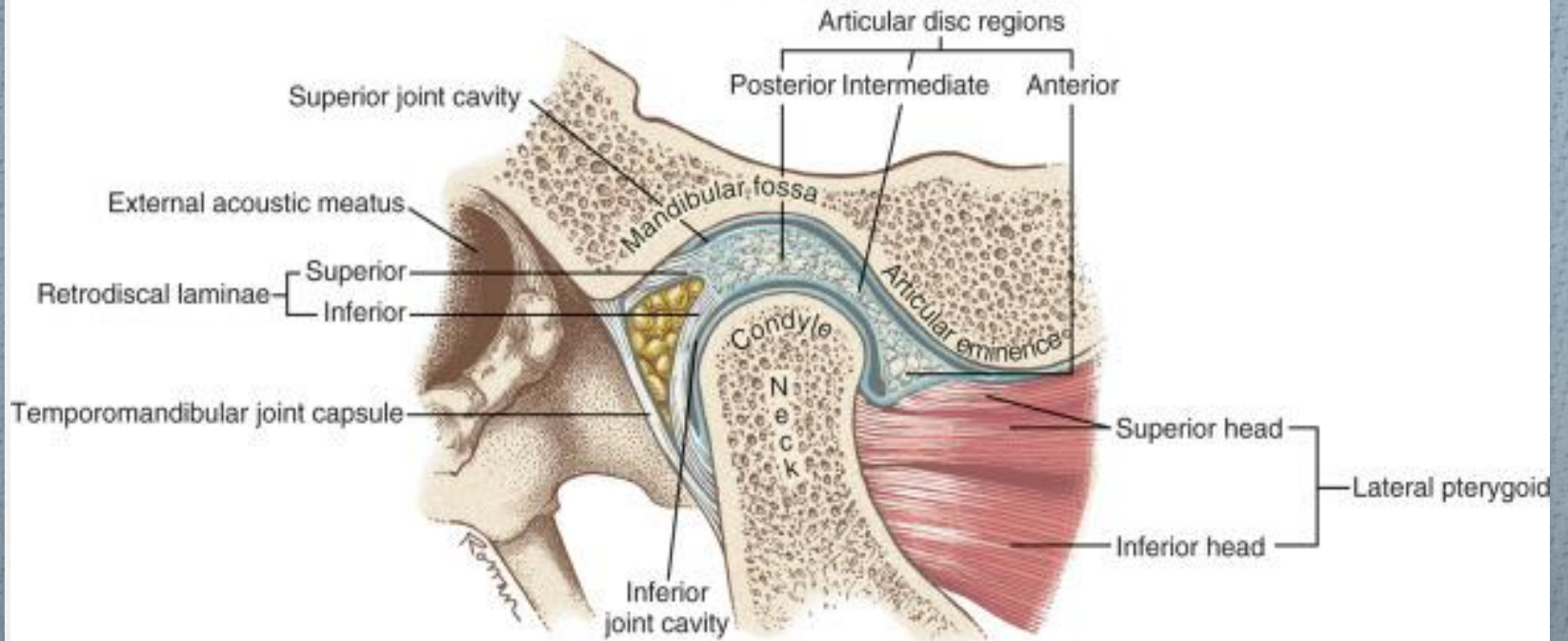
o The temporomandibular joint (TMJ) : is a modified hinge type of synovial joint, permitting gliding (translation) and a small degree of rotation (pivoting) in addition to flexion (elevation) and extension (depression) movements typical for hinge joints. The bony articular surfaces involved are the mandibular fossa (the anterior portion) and articular tubercle of the temporal bone superiorly, and the head of the mandible (condylar process) inferiorly. Unlike most synovial joints, its articular surfaces are covered with fibrous cartilage rather than hyaline cartilage and the joint cavity is divided by a fibrocartilaginous articular disc into upper and lower cavities



o The Articular Disk :-

- o The articular disk is composed fibrocartilage and is non-vascularized and non-innervated, an adaptation that allows it to resist pressure.
- o **Anatomically** the disk can be divided into three general regions: the anterior band, the central intermediate zone, and the posterior band. The intermediate zone is thinnest and is generally the area of function between the mandibular condyle and the temporal bone

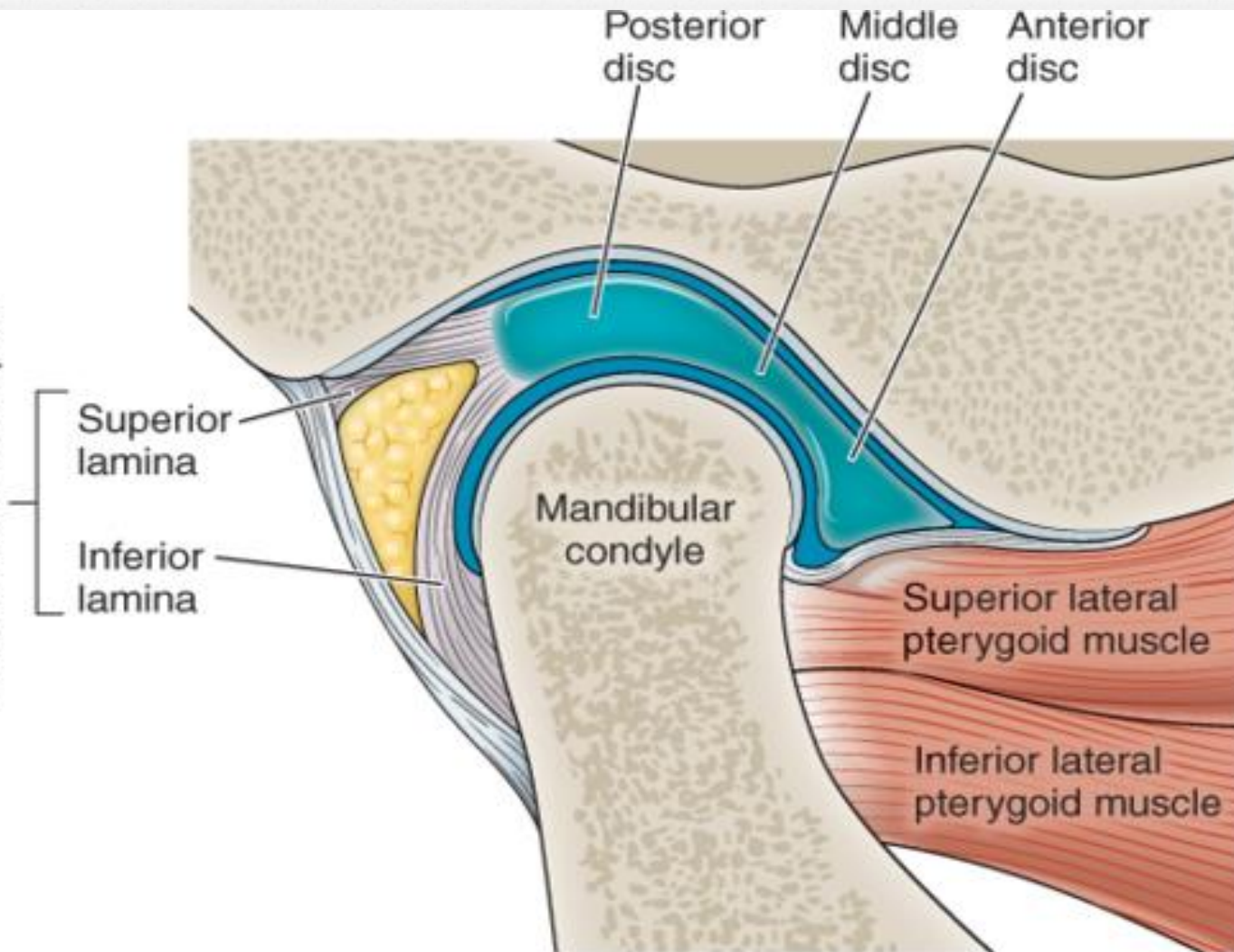
Lateral view



o Retrodiscal Tissue :-

Posteriorly the articular disk blends with a highly vascular, highly innervated structure (the bilaminar zone), which is involved in the production of synovial fluid. The superior aspect of the retrodiscal tissue, termed the **superior retrodiscal lamina**, contains elastic fibers attached to the tympanic plate and act as a restraint to disk movement in extreme translator movements. The inferior aspect of the retrodiscal tissue, termed the **inferior retrodiscal lamina**, consists of collagen fibers connected to the posterior margin of the condyle and thought to serve to prevent extreme rotation of the disk on the condyle in rotational movements.

Bilateral retrodiscal pad

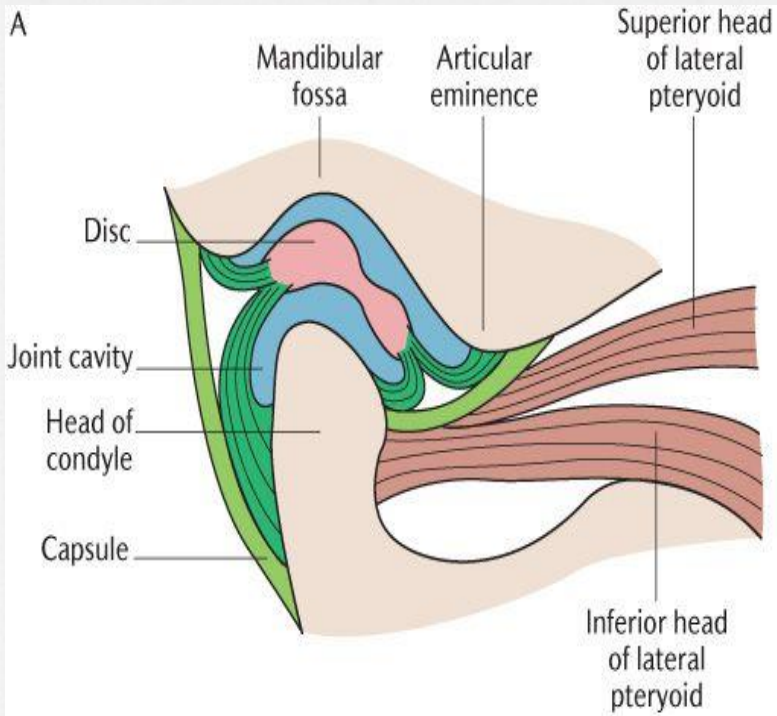


Source: Pamela K. Levangie, Cynthia C. Norkin, Michael D. Lewek
Joint Structure & Function: A Comprehensive Analysis, 6th Ed.
Copyright © F. A. Davis Company. All right reserved.

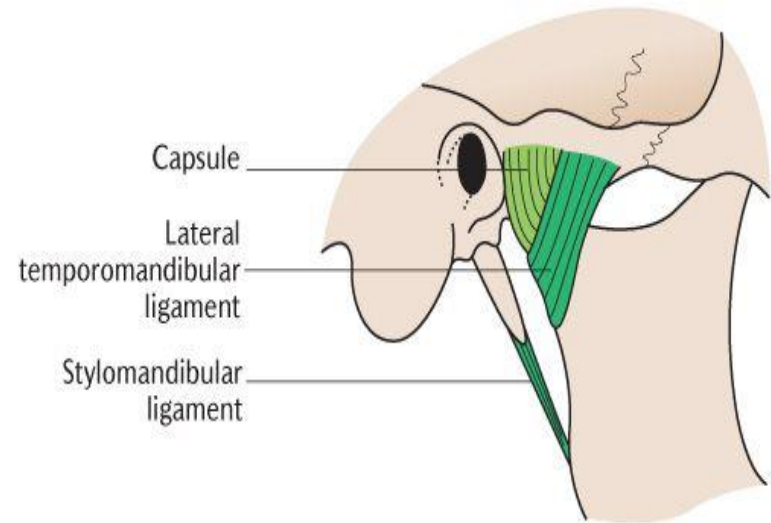
o Capsule:-

The capsule surrounds the joint and is attached above to the articular tubercle and the margins of the mandibular fossa and below to the neck of the mandible. It permits side to-side motion, protrusion, and retrusion. The two bony articular surfaces are completely separated by intervening fibrocartilage, the articular disc of the TMJ (Meniscus), attached at its periphery to the internal aspect of the fibrous capsule. This creates separate superior and inferior articular cavities, or compartments, lined by separate superior and inferior synovial membranes.

A



B



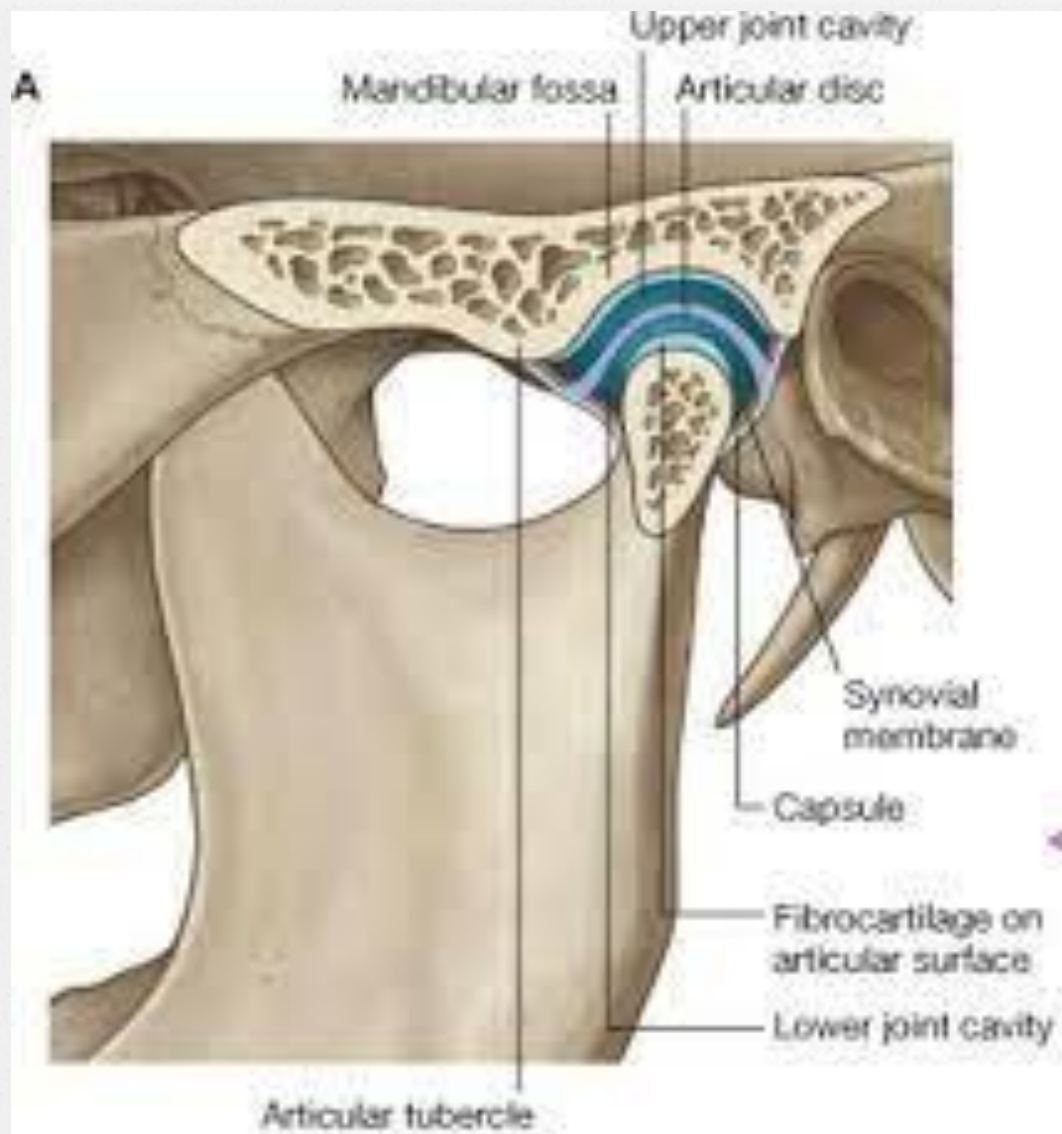
C

o Synovial Membrane :-

The synovial membrane is a thin, smooth, richly innervated vascular tissue (without an epithelium) that lines the capsule.

Lining the inner aspect of TMJ, are two types of tissue: articular cartilage and synovium. The space bound by these two structures is termed the synovial cavity, which is filled with synovial fluid that contains a high concentration of hyaluronic acid that is thought to be responsible for the fluid's high viscosity. The synovium is capable of rapid and complete regeneration following injury.

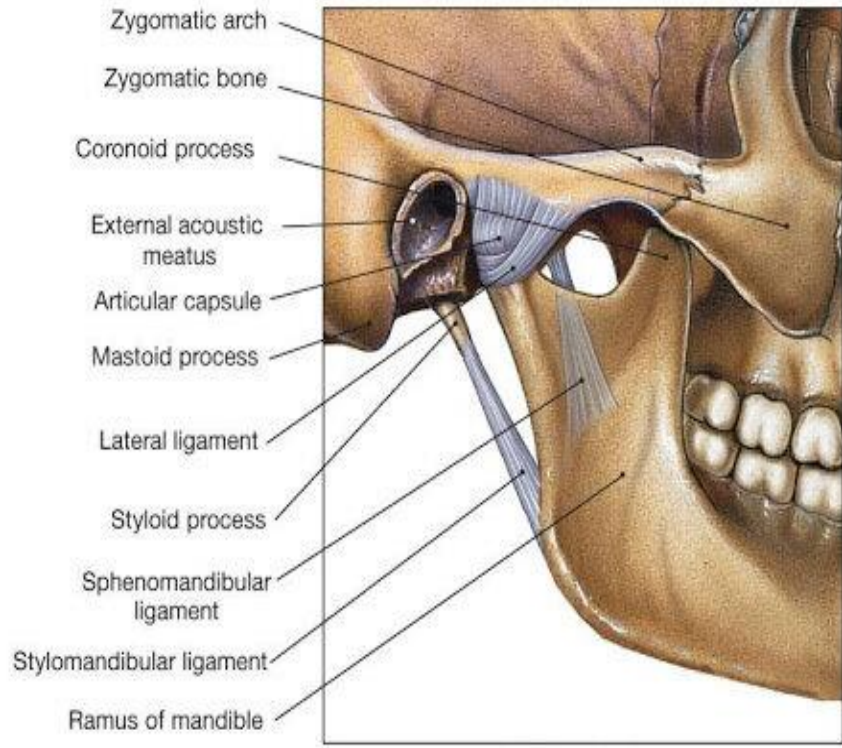
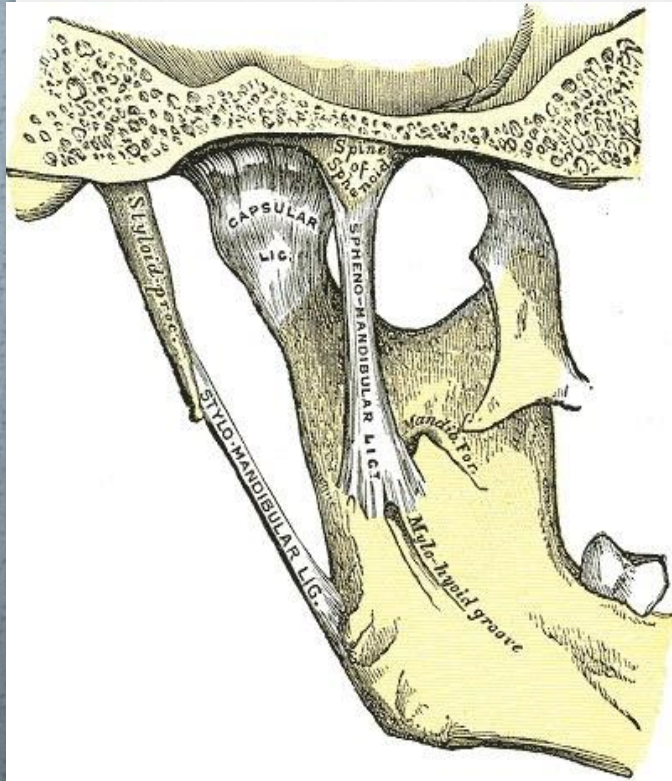
Functions of the synovial fluid include lubrication of the joint, phagocytosis of particulate debris, and nourishment of the articular cartilage. The concentration of hyaluronic acid and hence the viscosity of the synovial fluid is greater at the point of load, thus protecting the articular surfaces.



o Ligaments :-

- o The lateral temporomandibular ligament strengthens the lateral aspect of the capsule, and its fibers run downward and backward from the tubercle (in the root of zygoma) to the lateral surface of the neck of the mandible. This ligament limits the movement of the mandible in a posterior direction and thus protects the external auditory meatus.
- o The articular disc divides the joint into upper and lower cavities. It is an oval plate of fibrocartilage that is attached circumferentially to the capsule. It is also attached in front to the tendon of the lateral pterygoid muscle and by fibrous bands to the head of the mandible. These bands ensure that the disc moves forward and backward with the head of the mandible during protraction and retraction of the mandible. The upper surface of the disc is concavo-convex from before backward to fit the shape of the articular tubercle and the mandibular fossa; the lower surface is concave to fit the head of the mandible.

- o The stylomandibular ligament lies behind and medial to the joint and extends from the apex of the styloid process to the angle of the mandible. This ligament limits anterior protrusion of mandible.
- o The sphenomandibular ligament lies on the medial side of the joint. It is a thin band that is attached above to the spine of the sphenoid bone and below to the lingula of the mandible. This ligament may act as a pivot by providing tension during opening and closing.



(a) Lateral view

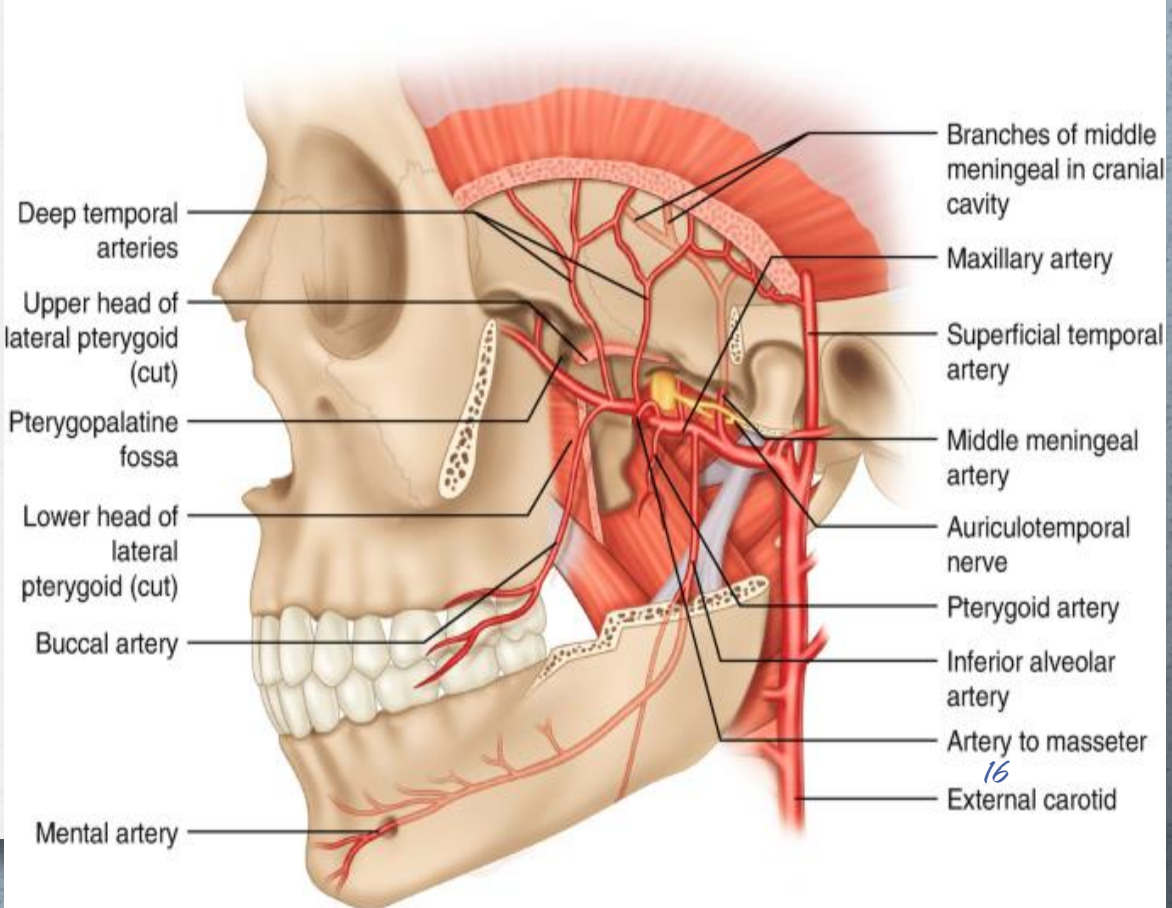
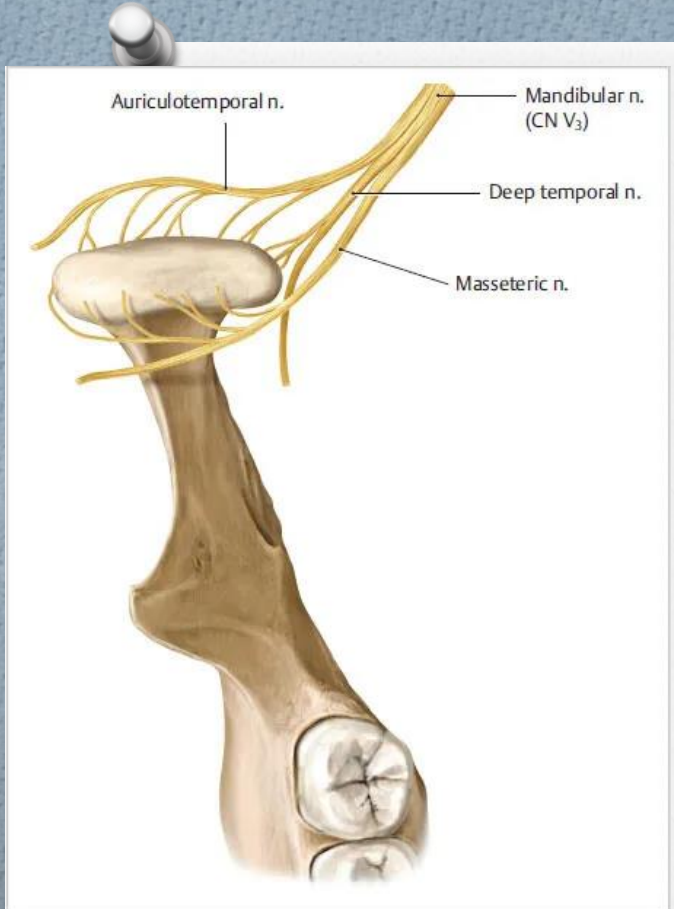
Copyright © 2003 Pearson Education, Inc., publishing as Benjamin Cummings.

o Nerve Supply :-

o The nerve supply to the TMJ is predominantly from branches of the auriculotemporal nerve with anterior contributions from the masseteric nerve and the posterior deep temporal nerve.

o Vascular Supply :-

o The vascular supply of the TMJ arises primarily from branches of the superficial temporal and maxillary arteries posteriorly and the masseteric artery anteriorly. There is a rich plexus of veins in the posterior aspect of the joint, which alternately fill and empty with protrusive and retrusive movements respectively, and which also function in the production of synovial fluid.

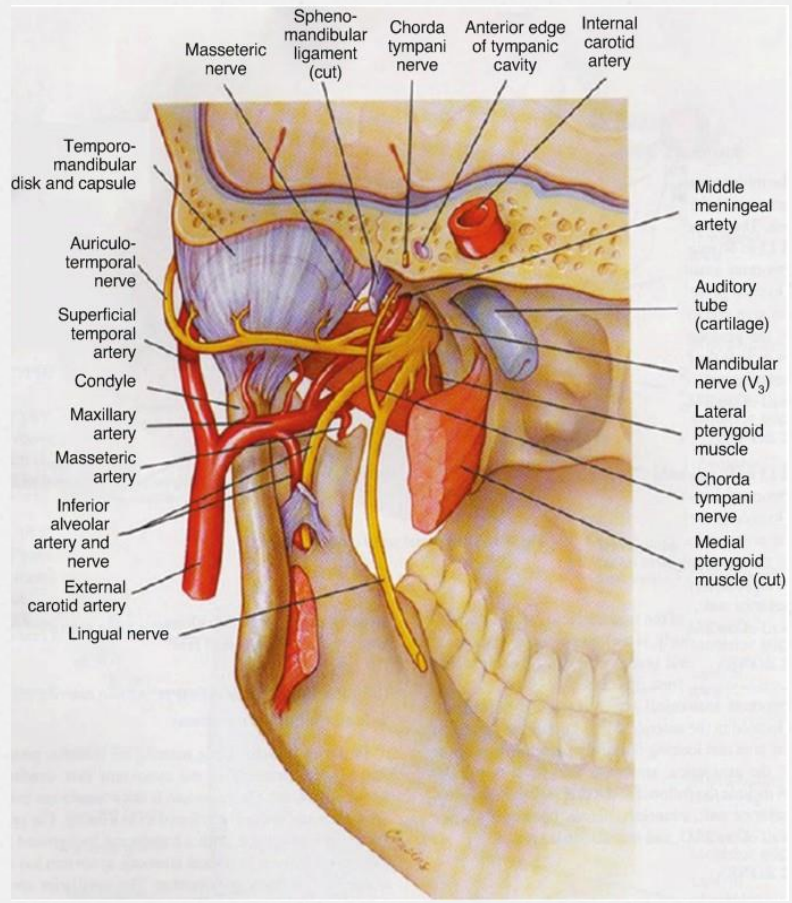
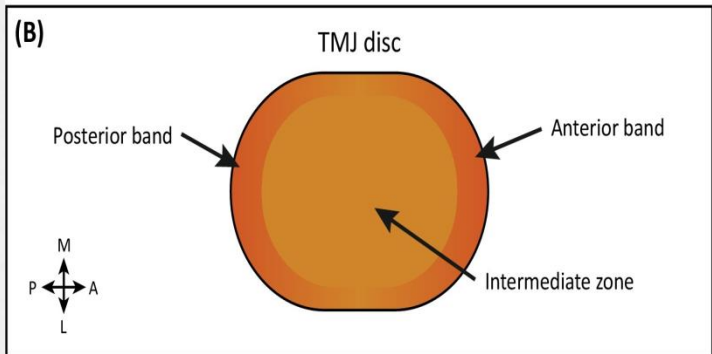
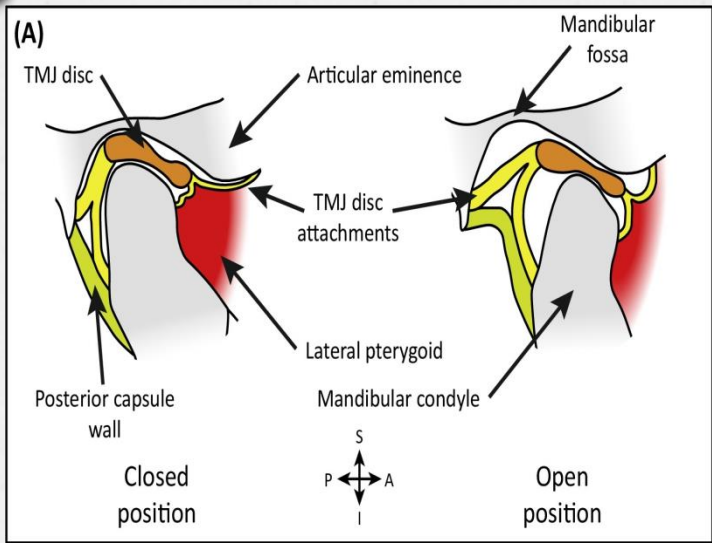


o Movements :-

- o TMJ movements are produced chiefly by the muscles of mastication. The mandible can be depressed or elevated, protruded or retracted. Rotation can also occur, as in chewing. In the position of rest, the teeth of the upper and lower jaws are slightly apart. On closure of the jaws, the teeth come into contact. Generally, depression of the mandible is produced by gravity. The suprahyoid and infrahyoid muscles are primarily used to raise and depress the hyoid bone and larynx. Indirectly they can also help depress the mandible, especially when opening the mouth suddenly, against resistance, or when inverted (e.g., standing on one's head). The platysma can be similarly used.

o Important Relations of the Temporomandibular Joint

- o Anteriorly:** The mandibular notch and the masseteric nerve and artery.
- o Posteriorly:** The tympanic plate of the external auditory meatus and the glenoid process of the parotid gland
- o Laterally:** The parotid gland, fascia, and skin.
- o Medially:** The maxillary artery and vein and the auriculotemporal nerve



Movement of mandible	Muscles
Elevation (close mouth)	Temporlis, masseter and medial pterygoid.
Depression (open mouth)	Lateral pterygoid, suprahyoid and infrahyoid muscles.
Protrusion (protrude chin)	Lateral pterygoid, masseter and medial pterygoid.
Retrusion (retrude chin)	Temporalis (posterior oblique and near horizontal fiber) and masseter
Lateral movement (grinding and chewing)	Temporalis of the same side, pterygoids of the opposite side, masseter.

o Clinical Notes:-

- o The temporomandibular joint lies immediately in front of the external auditory meatus. The great strength of the lateral temporomandibular ligament prevents the head of the mandible from passing backward and fracturing the tympanic plate when a severe blow falls on the chin. The articular disc of the temporomandibular joint may become partially detached from the capsule, and this results in its movement becoming noisy and producing an audible click during movements at the joint.
- o **Dislocation of TMJ** Sometimes during yawning or taking a large bite, excessive contraction of the lateral pterygoids may cause the heads of the mandible to dislocate anteriorly (pass anterior to the articular tubercles). In this position, the mandible remains depressed and the person is unable to close his or her mouth and the condition can be quite painful. Posterior dislocation is uncommon, being resisted by the presence of the postglenoid tubercle and the strong intrinsic lateral ligament.

Reduction of the dislocation is easily achieved by pressing the gloved thumbs downward on the lower molar teeth and pushing the jaw backward. The downward pressure overcomes the tension of the temporalis and masseter muscles, and the backward pressure overcomes the spasm of the lateral pterygoid muscles.

- o **Surgery of TMJ** Because of the close relationship of the facial and auriculotemporal nerves to the TMJ, care must be taken during surgical procedures to preserve both of them. Injury to these nerves usually leads to laxity and instability of the TMJ.
- o **Arthritis of TMJ** The TMJ may become inflamed from degenerative arthritis. Abnormal function of the TMJ may result in structural problems such as dental occlusion and joint clicking (crepitus). The clicking is thought to result from delayed anterior disc movements during mandibular depression and elevation.

Thank you