

(Definition, Classification, Principles)

DEFINITION OF TOOTH PREPARATION

Tooth preparation is defined as the mechanical alteration of a defective, injured, or diseased tooth to best receive a restorative material that will reestablish a healthy state for the tooth with normal form and function

OBJECTIVES OF TOOTH PREPARATION

In general terms, the objectives of tooth preparation are to:

- To remove diseased tissue as necessary
- To restore the integrity of the tooth surface
- To restore the function of the tooth- **(so that under the force of mastication the tooth or the restoration or both will not fracture and the restoration will not be displaced)**
- To restore the appearance of the tooth-

NOMENCLATURE: Nomenclature refers to a set of terms used in communication by persons in the same profession that enables them to better understand one another.

CARIES TERMINOLOGY

Dental caries is an infectious microbiologic disease that results in localized dissolution and destruction of the calcified tissues of the teeth.

Morphologic types of caries:

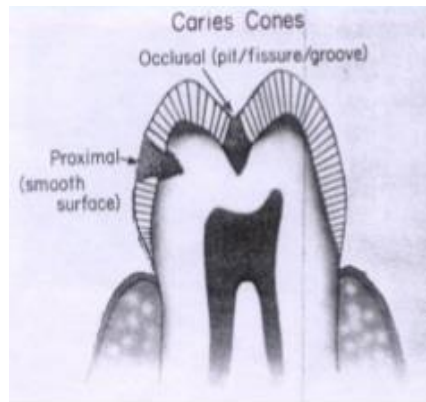
Cariou lesions originating:

- (1) on enamel pits and fissures,
- (2) on enamel smooth surfaces, or
- (3) on root surfaces (Senile caries).

1-Caries of Pit-and-Fissure Origin. The caries forms a small area of penetration in the enamel at the bottom of a pit or fissure and does not spread laterally to a great extent until the *dentinoenamel junction (DEJ)* is reached. In diagrammatic terms, pit-and-fissure caries may be represented as

two cones, base to base, with the apex of the enamel cone at the point of origin and the apex of the dentin cone directed toward the pulp.

2-Caries of Enamel Smooth-Surface Origin. The disintegration in the enamel in smooth-surface caries also may be pictured as a cone, but with its base on the enamel surface and the apex at, or directed to, the DEJ. The caries again spreads at this junction in the same manner as in pit-and-fissure caries. Thus, the apex of the cone of caries in the enamel contacts the base of the cone of caries in the dentin. (Double inverted cone).



TOOTH PREPARATION TERMINOLOGY:A tooth preparation is termed

1-simple if a tooth preparation only one tooth surface is involved

2-compound if a tooth preparation two surfaces are involved

3-complex if a tooth preparation involving three (or more) surfaces

Abbreviated Descriptions of Tooth Preparations. the description of a tooth preparation is abbreviated by using the first letter, capitalized, of each tooth surface involved. Examples are:

(1) an occlusal tooth preparation is an O; (2) a preparation involving the mesial and occlusal surfaces is an MO; and (3) a preparation involving the mesial, occlusal, and distal surfaces is an **MOD**.

Tooth Preparation Walls

Internal Wall. An internal wall is a prepared (cut) surface that does not extend to the external tooth surface (Fig. 10).

Axial wall. An axial wall is an internal wall parallel with the long axis of the tooth (see Fig. 10).

Pulpal wall. A pulpal wall is an internal wall that is both perpendicular to the long axis of the tooth and occlusal of the pulp.

External Wall. An external wall is a prepared (cut) surface that extends to the external tooth surface, and such a wall takes the name of the tooth surface (or aspect) that the wall is toward (see Fig. 10).

Floor (or Seat). A floor (or seat) is a prepared (cut) *wall* that is reasonably flat and perpendicular to the long axis of the tooth). Examples are the pulpal and gingival walls.

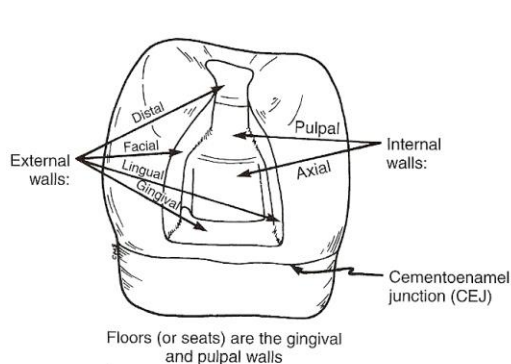


FIG 6-10 Illustration indicating external and internal walls.

Tooth Preparation Angles: the junction of two or more prepared (cut) surfaces is referred to as an angle

Line Angle. A line angle is the junction of two planal surfaces of different orientation along a line. An internal line angle is a line angle whose apex points into the tooth. An external line angle is a line angle whose apex points away from the tooth

Point Angle. A point angle is the junction of three planal surfaces of different orientation.

Cavosurface Angle and Cavosurface Margin. The cavosurface angle is the angle of tooth structure formed by the junction of a prepared (cut) wall and

the external surface of the tooth. The actual junction is referred to as the cavosurface margin.

Proximal surface: is the surface that face the adjacent tooth

Marginal ridge: border the lingual surface of anterior teeth and the occlusal surfaces of posterior teeth

DENTAL ROTARY AND HAND INSTRUMENTS

Lec. 2

د. العلاء جمال

The removal and shaping of tooth structure are essential aspects of restorative dentistry. Initially this was a difficult process accomplished entirely by the use of

- Hand instruments.
- Rotary, powered cutting instruments.

Hand instruments

Definition:

It is hand-powered dental instruments.

- G.V. Black is credited with the first acceptable nomenclature and classification of hand instruments. His classification system enabled both dentists and manufacturers to communicate more clearly and effectively in regard to instrument design and function.
- For many years, carbon steel was the primary material used in hand instruments because they were harder and maintained sharpness better than stainless steel.
- Stainless steel is now the preferred material because stainless steel instrument remains bright with steam or dry heat sterilization, and because the properties of stainless steel have improved by incorporating a significant amount of chromium imparts corrosion resistance and carbon imparts hardness.
- Hand instruments used in operative dentistry may be categorized as:
 1. Cutting instruments and,
 2. Non cutting instruments.

Cutting instruments

These instruments are used to cut hard or soft tissue of the mouth.

Hand cutting instruments are composed of three parts: handle, shank and blade (Fig 1).

For non cutting instruments; the part corresponding to the blade is termed the nib or working end.




Fig. (1) Double-ended instrument illustrating three component parts of hand instrument: blade (a), shank (b), and handle (c)

- **The blade or nib;** is the working end of the instrument and is connected to the shank. Some instrument have a blade on both ends of the handle and are known as double ended instrument. The blades have many designs and sizes, depending on the function they are to perform.
- **The Shank;** serves to connect the handle to the blade of the instrument. The shank may be straight, mon-angle (with one angle), bin-angle (with two angles) , triple-angle (three angles) , or quadr-angle (four angles) as in Fig(3&4&5).

The term contra-angle refers to shank in which two or more angles are present.

The angles in the shank are important to keep the blade edge within 1-2 mm to the long axis of the instrument. This is a basic factor to concentrate the force onto the blade for balancing the instrument during use and prevent its rotation

- **The Handle;** is the part that is grasped by the operator hand while he is using the instrument.

Instrument Formula Given by G.V.Black:

3 Number instrument formula: Cutting edge of the Instrument is at a right angle to the blade.

- First number- Width of the blade in tenths of a millimeter.
- Second number - Length of the blade in millimeter.
- Third number - Angle the blade forms with the axis of the handle in centigrade.

Example: Enamel hatchet. Fig2

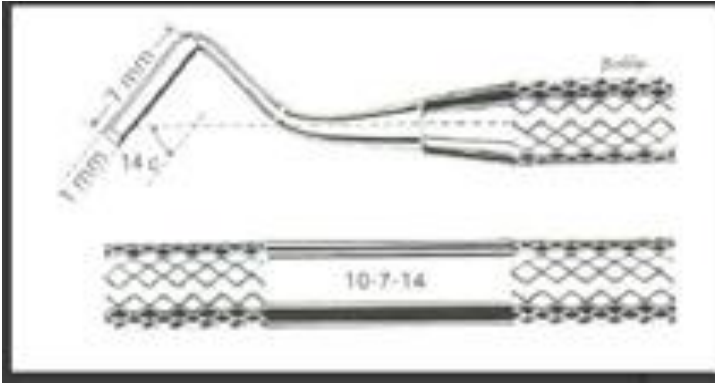


Fig (2): Enamel hatchet formula

4 Number instrument formula: Cutting edge of the instrument is at an angle other than a right angle to the blade.

- a. First number - Width of the blade in tenths of a millimeter.
- b. Second number - Angle the cutting edge forms with the axis of the handle in centigrade.
- c. Third number - Length of the blade in millimeter.
- d. Fourth number - Angle the blade forms with the axis of the handle in centigrade.

Example: Gingival marginal trimmer & angle former. Fig3

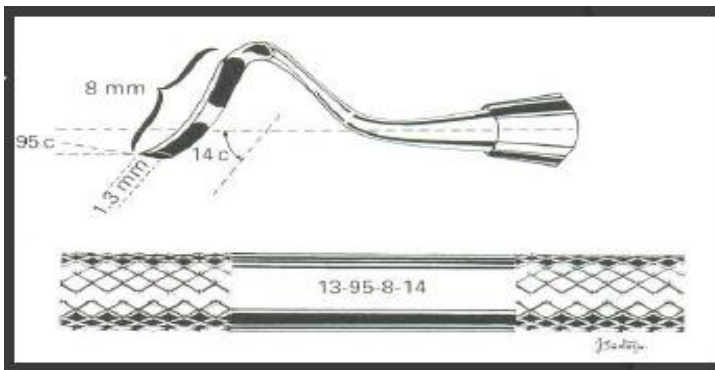


Fig3 Gingival marginal trimmer formula

Examples of the cutting instruments are:

1. **Chisel:** - either has a straight shank or with slight blade curvature or bin-angle chisel, and the blade has bevel only on one side of the edge. Its cutting edge is perpendicular to the axis of the handle. The chisels are used for cutting enamel and dentin with pushing motion. The shank and blade of the chisel. (Fig. 4 A , B, C).

2. **Hoe:** - It is like chisel with cutting edge is perpendicular to the axis of the handle (Fig. 4 D), however its blade has a greater angle from the long axis of the handle than does that of the chisel. It has the same uses of the chisel.

3. **Hatchet:** - also called enamel hatchet. The cutting edge of the hatchet is parallel to the long axis of the handle and beveled only from one side (Fig. 5 A). It is used for cutting enamel and dentin and comes as right or left types for using on opposite sides of the preparation.

4. **Gingival margin trimmer:** - This instrument is used for beveling of the gingival enamel margin of proximo-occlusal preparations. Also it is used for beveling of axiopulpal line angle of two surface preparation as in class II cavities.

It is similar in design to the hatchet, except the blade is curved, and cutting edge is at an angle (other than parallel) to the long axis of the blade (Fig. 5, B and C). It is made as right and left types. Also it is made either a mesial pair or a distal pair.

5. **Spoon excavator:-** The blade is curved and the cutting edge at the end of the blade is in the form of a semicircle. This gives the instrument an outer convexity and inner concaving that makes it look like a spoon Fig. (6). Like the hatchet the cutting edge at the end of the blade is parallel to the handle, therefore there are left cutting and right cutting spoons. The shank of some spoons holds a small circular (disk blade) or claw – like blade at its end. The disk blade is known as a discoid, where the claw - like blade is termed a cleoid (Fig 7, A and B).

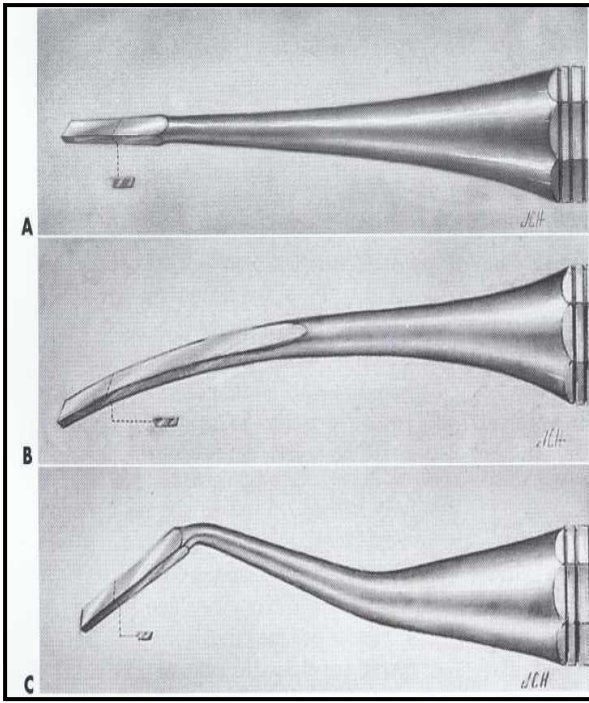


Fig . (4) Examples of hand instrument called chisels (with corresponding instrument formulas). A, Straight (12-7-0). B, Wedelstaedt (11 1/2-15-3). C, Bin-angle (10-7-8) , D,Hoe.

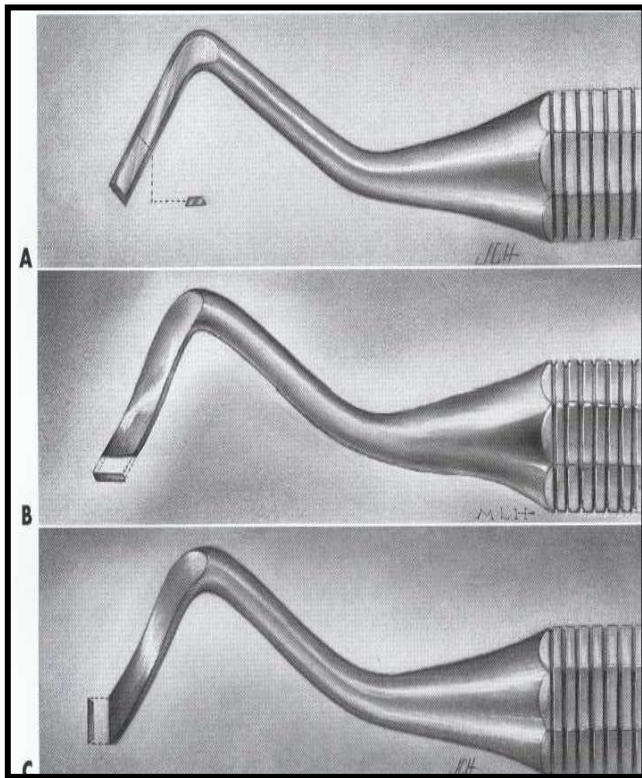



Fig .(5) Examples of hand cutting instrument (with corresponding instrument formulas). A, Enamel hatchet (10-7-14). B, Gingival margin trimmer (12 1/2-100-7-14). C, Gingival margin trimmer (12 1/2-75-7-14).

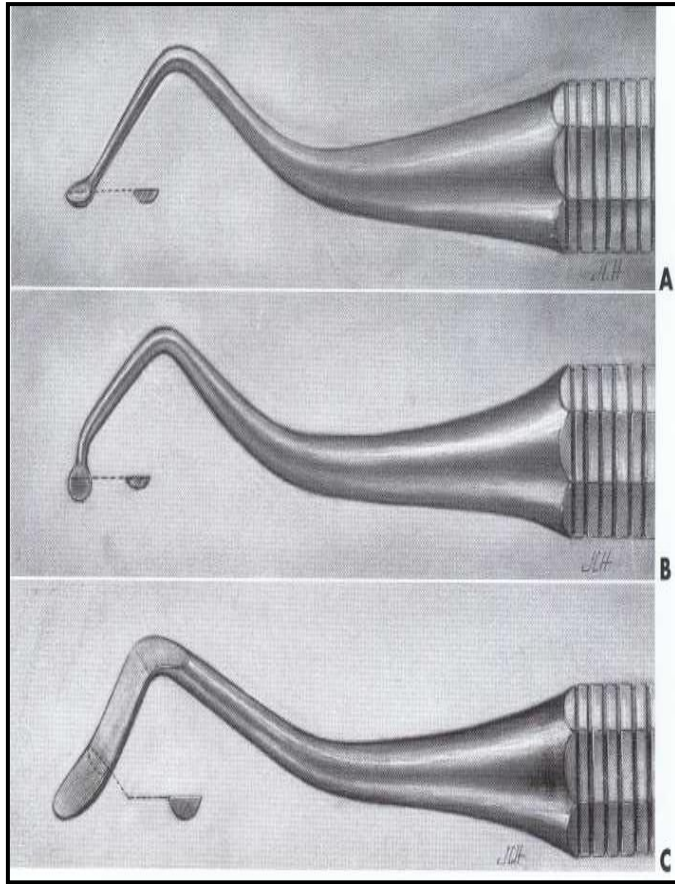


Fig. (6) Examples of hand instrument called spoon excavators (with corresponding instrument formulas). A, Binangle spoon (13-7-14). B, Triple-angle spoon (13-7-14). C, Spoon (15-7-14).

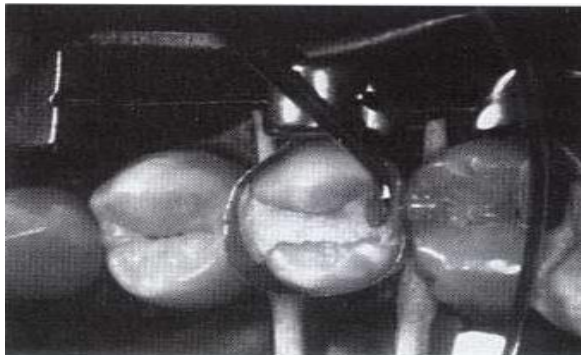
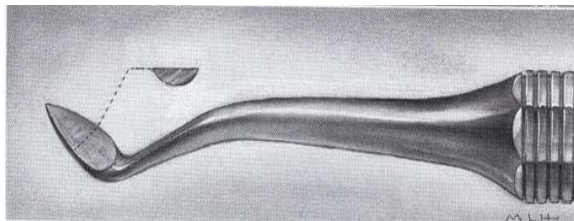


Fig . (7) Examples of other hand instrument for cutting (spoons) 1st picture is Cleoid blade. 2nd picture is Discoid blade carving amalgam.

Non-cutting instruments

In these instruments the blade is replaced by a nib or point. These are divided according to **function** into: -

- 1- Diagnostic instruments
- 2- Plastic instruments
- 3- Amalgam instruments

Diagnostic instruments

These are basic instruments that will be needed during each appointment for diagnosis and treatment.

1. Mirror: used for:

- indirect visualization of any tooth surface that cannot be seen by the eye.
- reflection of light into the area being examined or treated.
- retractor of soft tissue (tongue, cheek and lip) to aid access and visualization.

2. Probe or explorer: pointed instruments used:

- to feel tooth surface for irregularities
 - to determine the hardness of exposed dentin and caries detection.
- Probes have different shapes either sickle, straight or angled

3. Tweezer or cotton forceps: used for aiding the operator to carry small items to the mouth of the patient.

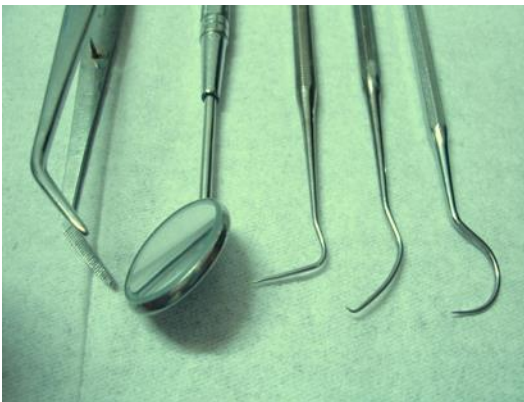

Fig. (8): diagnostic instruments

Plastic instruments: Or plastic filling instrument are used to:

- carry and shape tooth colored restorative material such as composite resin and glass ionomer.
- packing temporary filling material inside unfilled cavities preparation.
- or for placing of basing and lining material into the cavities. In past these instruments are made of plastic.

Ash 49: - is double ended instrument with cylindrical nibs and rounded ends. Fig. (9): A

Ash 6: - is one of plastic instrument similar to carver but the margin of its working end is not sharp. Fig. (9): B

Dycal applicator: - is small hand instrument with small round nib used for mixing and placing dycal lining material in the cavity. Fig. (9): C

Cement spatula: - it is used for mixing variety of material which required mixing (such as cement or temporary filling material) on glass or on a paper pad. Fig. (9): D

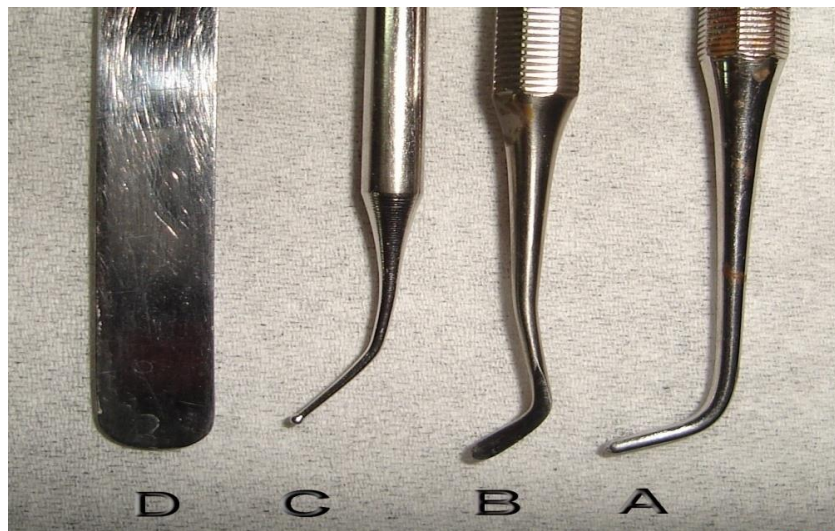


Fig.(9): Plastic instruments

Amalgam instruments

Those instruments used to place dental amalgam, and to a certain extent, resin composite restorative material.

Condensers: - condensers are used to compress the amalgam into all areas of the prepared cavity. The working end or nib of the condenser is usually round with flat end (face). The nibs have different shapes triangular, rectangular or diamond shape ends.

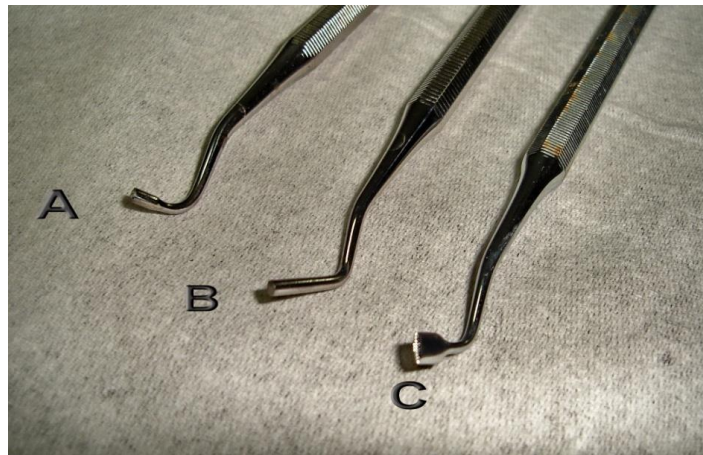


Fig.(10): Condenser

Burnisher: It have different nib shapes: round, oval or rounded cone shapes, also with different sizes, used for several functions such as;

- burnishing of the amalgam on the margins of the cavity.
- smoothing of the carved amalgam surface.
- shaping metal matrix band to have more desirable contours for restoration.
- bend cast gold restoration (inlay or onlay) near the margin of the prepared cavity to narrow the gap between gold and the tooth.

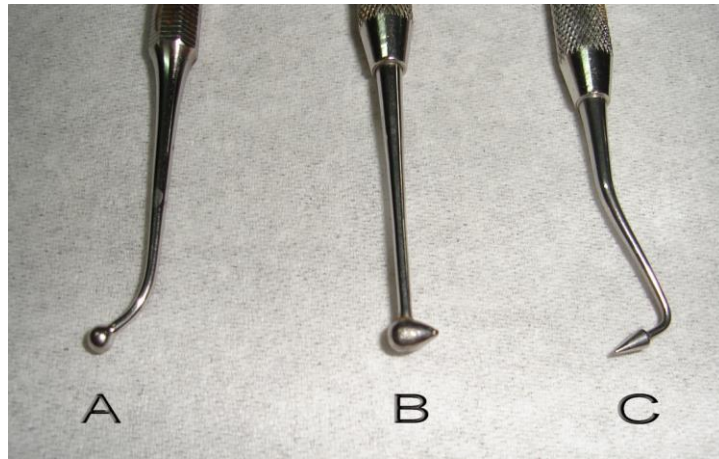


Fig.(11):Burnisher

Carver: - carvers are used to shape amalgam or resin composites (tooth colored) material after they have been placed in the tooth preparations. Carvers have many shapes but usually the nibs are flat with sharp margins for carving.

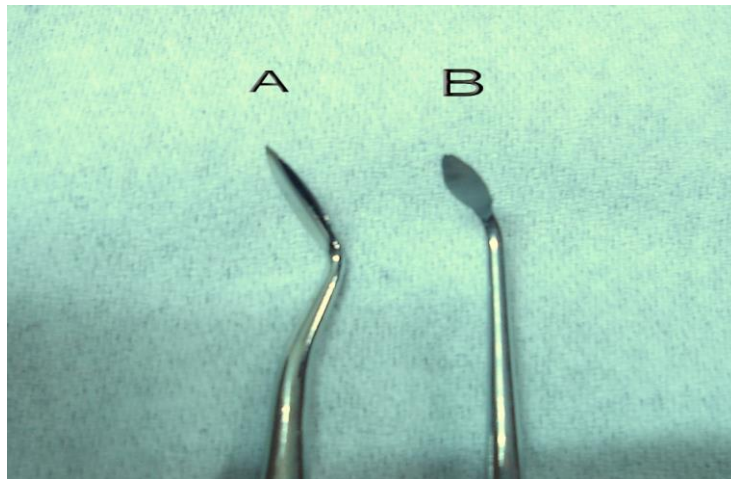


Fig.(12): Carver

Amalgam carrier:- used to carry the amalgam and place into the prepared cavities.



Fig.(13): Amalgam carrier



Hand instrument grasping

1. Pen grasp: - It is similar to that used in holding a pen. Pads of the thumb, index and middle fingers hold the instrument, while the tip of the ring finger, or tips of ring and little fingers, is placed on a nearby tooth surface of the same arch as arrest. The palm of the hand generally is facing away from the operator.

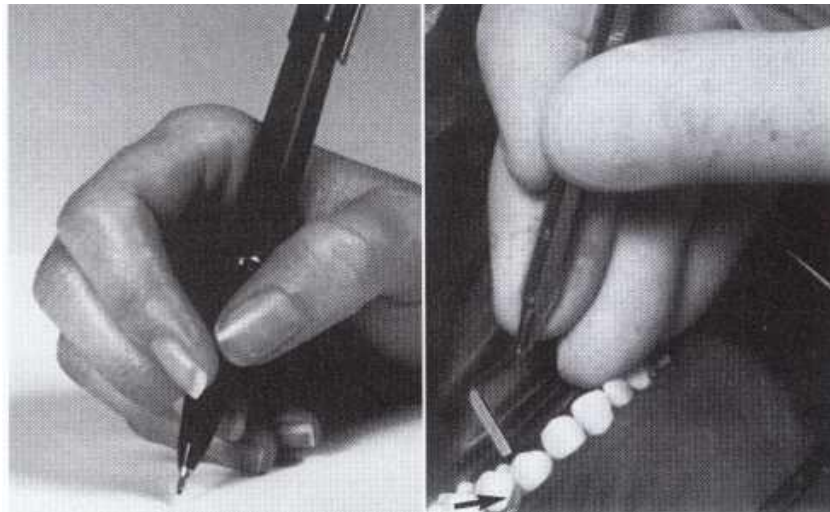


Fig. (14): Pen grasp

2. Inverted pen grasp: - The finger position is the same as of pen grasp, but the hand is rotated so that the palm more toward the operator. This grasping is used mostly for preparing of upper teeth with indirect viewing technique.

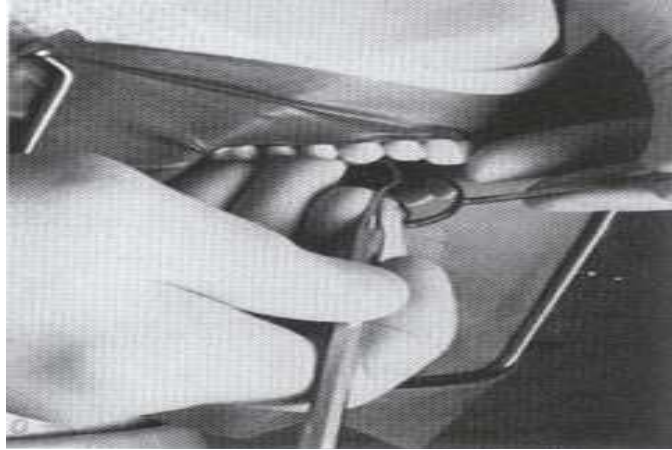

Fig.(15) : Inverted pen grasp

Palm and thumb grasp: - The handle of the instrument is placed in the palm of the hand and grasped by all fingers, while the thumb is free of the instrument and used for resting on a nearby tooth of the same arch

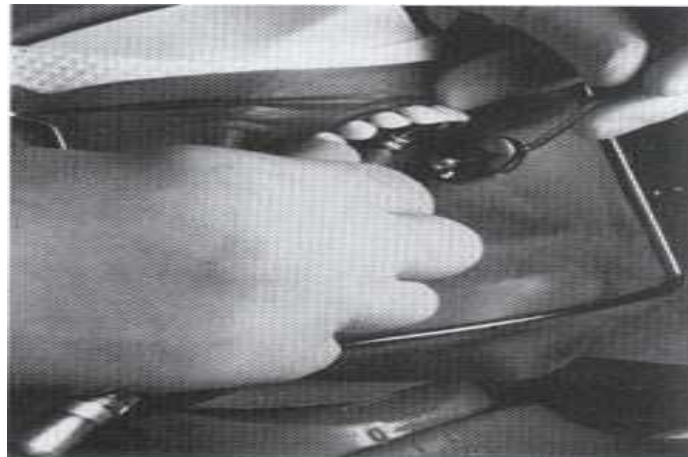


Fig (16):Palm and thumb grasp

Rotary instruments:-

Handpieces:-

Two basic types of handpieces:

- Straight handpiece: used for laboratory work

- contra angle handpiece: used in the mouth.



Jinme Dental Handpiece



Powered by DTYTrade.com

The contra – angle handpiece are classified according to their speed of rotation into:-

Low speed handpiece: have a free running speed range from 500 to 15,000 rpm (revolution per minute).

- used for removal of carious dentin with round bur rotating slowly.
- used with different bur shapes to finish the prepared cavity (e.g. rounding of sharp edges, or flattening of the floor).
- used in finishing and polishing of restorations.

High speed handpiece: - have a free running speed above 160,000 rpm and some have speed up to 500,000 rpm.

- Preferred for cutting enamel and dentin.
- Penetration through enamel and extension of the cavities outline are more efficient at high speed.
- Small diameter burs should be used in the high speed handpiece.

High speed generates considerable heat during cutting, even with small diameter burs and should be used with water coolant and high efficiency evacuation.



Burs:-

A group of instruments that can turn on an axis with different speed of rotation to perform different types of work.


- Its work are either cutting , abrasive, finishing or polishing.
- Burs used for cutting are manufactured from different materials, which may be stainless steel, carbide or diamond.
- The burs have hundreds of shapes and sizes.

Parts of bur:

Shank is the part that fit into the handpiece, accepts the rotation motion from handpiece, and which the bur is locked inside the handpiece head.

Neck is the part of the bur that connects the head to the shank.

Head is the working part of the bur which contains the cutting edges or points.



Burs are classified according to the shapes of their heads.

The basic *bur shapes* are:

Round bur: the head is spherical so it is used for initial entry into the tooth, preparation of retentive holes or for removal of carious dentin.

Inverted cone bur: the head is a cone – shape with the apex of cone directed toward the bur shank. This bur is used for flattening the floor of the cavity, increasing the depth of cavity or for providing undercuts in cavities preparation.

Fissure bur: is an elongated cylindrical head bur used for obtaining the outline form of the cavity and to cut walls, floor, or margins of the cavity, its either straight or tapered.



Sterilization in Operative Dentistry

د.العلاء

Is a term referring to any process that eliminates (removes) or kills all forms of microbial life, including the resistant bacterial spores using physical or chemical means. Sterilization in dentistry is a very important and crucial aspect of providing successful dental treatments. Since most instruments contact mucosa and/or penetrate oral tissues, it is essential that reused instruments be thoroughly cleaned and sterilized by accepted methods that can be routinely tested and monitored.

DISINFECTION:

A much lesser term of sterilization and indicate procedure offering variable measures of control of infection, in this way we not going to kill all living microorganism may viruses kept survive.

Classification of sterilization

- ◆ PHYSICAL METHODS
- ◆ CHEMICAL METHODS
- ◆ COMBINATION OF BOTH

<i>Physical methods</i>	<i>Chemical methods</i>
Moist heat	Alcohols
Dry heat	Aldehydes
Filtration	Halogens
Radiation	Phenols

Methods of sterilization

There are four accepted methods of sterilization:

1. Steam pressure sterilization (autoclave)
2. Chemical vapor pressure sterilization (chemi-clave)
3. Dry heat sterilization (dryclave)
4. Ethylene oxide sterilization

1. STEAM PRESSURE STERILIZATION (AUTOCLAVING)

Sterilization with steam under pressure is performed in a steam autoclave. For a light load of instruments, the time required at 250° F (121° C) is a minimum of 15 minutes at 15 psi pressure.

Time for wrapped instruments can be reduced to 3 minutes if the temperature is raised to approximately 273° F (134° C) to give 20 psi of pressure. Time required for the sterilizer to reach the correct temperature is not included.

Instruments which are sterilized by using autoclave is

Handpieces, orthodontic pliers, impression trays, and surgical instruments.

Advantages of autoclaves

- 1- Autoclaving is the most rapid and effective method for sterilizing cloth surgical packs and towel packs.
- 2- Economical
- 3- Good penetration on all surfaces.
- 4- Short procedure time
- 5- Easily monitored

Disadvantages of autoclaves

- 1- Items sensitive to the elevated temperature cannot be autoclaved.
- 2- Autoclaving tends to rust carbon steel instruments and burs.
- 3- Steam appears to corrode the steel neck and shank portions of some diamond instruments and carbide burs.
- 4- Dulling of unprotected cutting edges.

2. CHEMICAL VAPOR PRESSURE STERILIZATION (CHEMICLAVING)

- Sterilization by chemical vapor under pressure is performed in a Chemiclave.
- Chemical vapor pressure sterilizers operate at 270° F (131° C) and 20 lbs pressure.
- They are similar to steam sterilizers and have a cycle time of about half an hour.
- Like ethylene oxide sterilizers, they must be used with a prescribed chemical by

the manufacture.

● **Instruments which are sterilized by using chemiclave is:**

- Periodontal, restorative and endodontic instruments
- Carbon steel and other corrosion sensitive burs and pliers

Advantages of Chemiclaves

Carbon steel and other corrosion-sensitive burs, instruments, and pliers are said to be sterilized without rust or corrosion.

Disadvantages of Chemiclaves

- 1- Items sensitive to the elevated temperature will be damaged.
- 2- Instruments must be lightly packaged in bags obtained from the sterilizer manufacturer.
- 3- Towels and heavy cloth wrappings of surgical instruments may not be penetrated to provide sterilization.

3-DRY HEAT STERILIZATION (hot air ovens)

It is the most widely used method of sterilization by dry heat. Dry heat sterilization is readily achieved at temperatures above 320° F (160° C) for 1-2 hours. The oven is electrically heated and is fitted with a fan to ensure adequate and even distribution of hot air in the chamber. It is also fitted with a thermostat that maintains the chamber air at a chosen temperature.

Instruments which are sterilized by using hot air oven are :

- Endodontic instruments
- Condensers
- Hand instruments
- Orthodontic pliers
- Surgical instruments
- Burs

Advantages of dry heat

- 1- Carbon steel instruments and burs do not rust, corrode, or lose their temper or cutting edges if they are well dried before processing.
- 2- Economical.
- 3- Easily monitored.

Disadvantages of dry heat

- 1- High temperatures may damage more heat-sensitive items, such as rubber or plastic goods.
- 2- Sterilization cycles are prolonged at the lower temperatures.
- 3- Heavy loads of instruments, crowding of packs, and heavy wrapping easily defeat sterilization.
- 4- Hot air is a bad conductor of heat hence it has less penetrating power.

4 - Ethylene Oxide sterilization

Ethylene oxide sterilization is the best method for sterilizing complex, heat sensitive instruments and delicate materials like rotary handpiece. Ethylene oxide is a gas at a temperature below 100°C. It is highly explosive and inflammable. It is highly penetrative, non-corrosive agent with a bactericidal action. It is used for the sterilization of towels, metal and plastic instruments.

LIQUID STERILANTS/HIGH-LEVEL DISINFECTANTS

- Sterilants used for high-level disinfection of items for reuse are glutaraldehydes at 2% to 3% concentrations; it kills bacterial spores in 6-10 hours.
- Greater dilutions are not encouraged for repeated use.
- Placing wet items into disinfectant trays dilutes the solution.
- Glutaraldehydes are irritating, sensitizing to skin and respiratory passages, and can be toxic as indicated in manufacturers' safety data sheets. Keep trays tightly covered in a well-vented area.
- *Do not use 2% glutaraldehyde solutions to wipe counters or equipment (e.g., dental unit and chair).*

Infection control program in minimum dental office

1. Sterilization of instruments
2. Comprehensive medical history
3. Hepatitis B vaccine to prevent any cross infection
4. Antiseptic and mouthwash
5. Disposal mask and gloves

- 6. Protective eye glass
- 7. Rubber dam
- 8. Surface cleaning and cover tray
- 9. Needle and sharp instrument safety

DENTAL INSTRUMENTS CLASSIFICATION

based on risk of transmission and need of sterilization

- CRITICAL
- SEMI-CRITICAL
- NON-CRITICAL

Category	Definitions	Dental instrument or item	Type of sterilization
Critical	Penetrate soft tissue, contact bone, enters into or contacts the blood stream	Surgical instruments, periodontal scalers, scalpel blades, surgical dental burs.	HEAT STERILIZE between uses or use sterile single-use, DISPOSABLE devices
Semicritical	Contact mucous membranes or non intact skin, will not penetrate tissue, contact bone, enter into or contact blood stream.	Dental mouth mirror, amalgam condenser, reusable dental impression trays, dental handpieces	HEAT STERILIZE or HIGH-LEVEL DISINFECT
Noncritical	Contact intact skin	Radiograph head\cone, blood pressure cuff, facebow	Clean and disinfect using a LOW TO INTERMEDIATE LEVEL DISINFECTANT

Stages for instrument sterilization

- ▶ **Presoaking** - Placing the instrument in a presoak solution until time is available for full cleaning prevents drying and begins to dissolve or soften the debris. Presoak solutions used are detergents
- ▶ **Cleaning** - Clean instruments in an ultrasonic cleaner (preferred), instrument washer, or by hand while wearing proper protection. Ultrasonic cleaners are safest and most efficient ways to clean instruments, ultrasonic cleaning is 9 times more effective than hand cleaning ,it provides fast and thorough cleaning without damage to instruments.
- ▶ **Packaging** - Place instruments in a sealed package or pouch, unless you're going to use them immediately after sterilization.

▶ Sterilization- Sterilize instruments using steam autoclaving, dry-heat, or chemical vapor machines.

▶ Drying or cooling- Store Instruments in a Dry, Protected Area

CLEANING AND DISINFECTION OF DENTAL UNIT AND ENVIRONMENTAL SURFACES

- Countertops and dental unit surfaces that may have become contaminated with patient material should be cleaned with disposable toweling, using an appropriate cleaning agent and water as necessary.

-Surfaces then should be disinfected with a suitable chemical germicide. Including: phenolics, iodophors, and chlorine-containing compounds.

-A fresh solution of sodium hypochlorite (household bleach) prepared daily is an inexpensive and effective intermediate-level germicide. Concentration (1/4 cup of bleach to 1 gallon of water) is effective on environmental surfaces that have been cleaned of visible contamination. Caution should be exercised, since chlorine solutions are corrosive to metals, especially aluminum.

DISINFECTION OF THE DENTAL LABORATORY

Laboratory materials and other items that have been used in the mouth (e.g., impressions, bite registrations, fixed and removable prostheses, orthodontic appliances) should be cleaned and disinfected before and after being manipulated in the laboratory, whether an on-site or remote location and before placement in the patient's mouth.

STERILISATION OF HANDPIECES

After each patient use,

- ▶ run any handpiece that is connected to the dental air/water system, to discharge water and/or air for at least 30 seconds
- ▶ Leave the bur in place while you clean the outside of the handpiece with detergent and warm water.
- ▶ Sterilize in an autoclave.
- ▶ If recommended by the manufacturer, lubricate the handpiece with pressurized oil until clean oil appears from handpiece.

Some dental instruments have components that are heat sensitive or are permanently attached to dental unit water lines. Some items may not enter the patient's oral cavity, but are likely to become contaminated with oral fluids during treatment procedures, including, for example, handles or dental unit attachments of saliva

ejectors, high-speed air evacuators, and air/water syringes. These components should be covered with disposable covers that are changed after each use or, if the surface permits, carefully cleaned and then treated with a chemical germicide having at least an intermediate level of activity.

DISPOSAL OF WASTE MATERIALS

- ▶ Blood, suctioned fluids, or other liquid waste may be poured carefully into a drain connected to a sanitary sewer system.
- ▶ Disposable needles, scalpels, or other sharp items should be placed intact into puncture-resistant containers before disposal.
- ▶ Solid waste contaminated with blood or other body fluids should be placed in sealed, sturdy impervious bags to prevent leakage of the contained

Conservative dentistry

LEC: 5

م.م. العلاج جمال

Cl II amalgam restoration

Preparations involving the proximal surfaces of posterior teeth are termed *Class II.*, the following surfaces are involved:

- Two surface cavity for posterior teeth fig 1A
- Three surface cavity for posterior teeth fig 1B
- Four surface (or more) cavity for posterior teeth fig 1C.

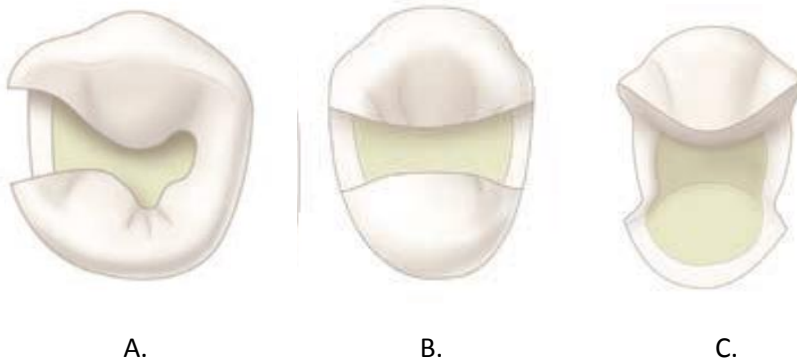


Fig 1: A: two surface cavity, B: three surface cavity, C: four surface cavity

Step 1: Outline Form and Initial Depth:

Establishing the outline form means placing the preparation margins in the positions they will occupy in the final preparation, the typical features of establishing proper outline form and initial depth are:

- Width of the facio-lingual walls of the cavity should be $\frac{1}{4}$ I.C.D.
- Preserving marginal ridge strength (2mm thickness marginal ridge).
- The depth of the preparation into dentin should be 1.5-2mm.

- The extent of the caries lesion affects the outline form of the proposed tooth preparation because the **objective is to extend to sound tooth structure also**. Ideal outline includes all pits & fissures even if its sound to prevent them from caries in the future (**extension for prevention**).

Step 2: resistance form:

May be defined as the shape of the cavity that prevent fracture of the remaining tooth structure and the restoration this includes:

Factors prevent fracture of the tooth

- The facio-lingual width of the preparation should not exceed $\frac{1}{4}$ I.C.D (intercuspal distance).

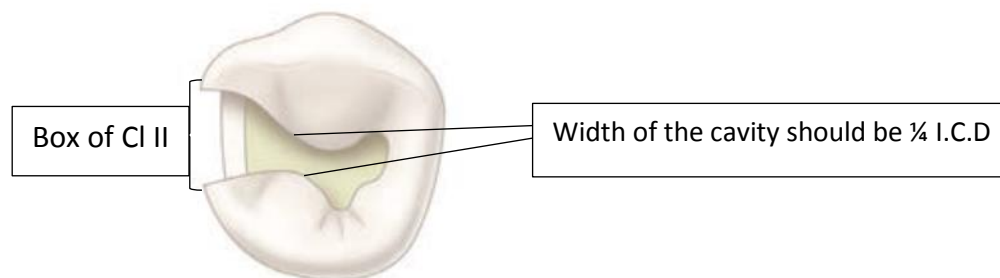


Fig2: CI II cavity preparation occlusal view

- Removal of unsupported enamel by making the margin (90° - 110°) because less than 90° the tooth is more subjected to fracture fig 3.
- Smooth pulpal floor & gingival seat to prevent stress concentration area.

- Mesial & distal walls of the cavity should be parallel and slightly diverge occlusally to be within the enamel rod direction and prevent any unsupported enamel at the marginal ridge.
- All internal line angle should be rounded to prevent stress concentration area fig3.
- Box shape of C1 II fig 2.
- Rounded gingival cavo-surface line angle

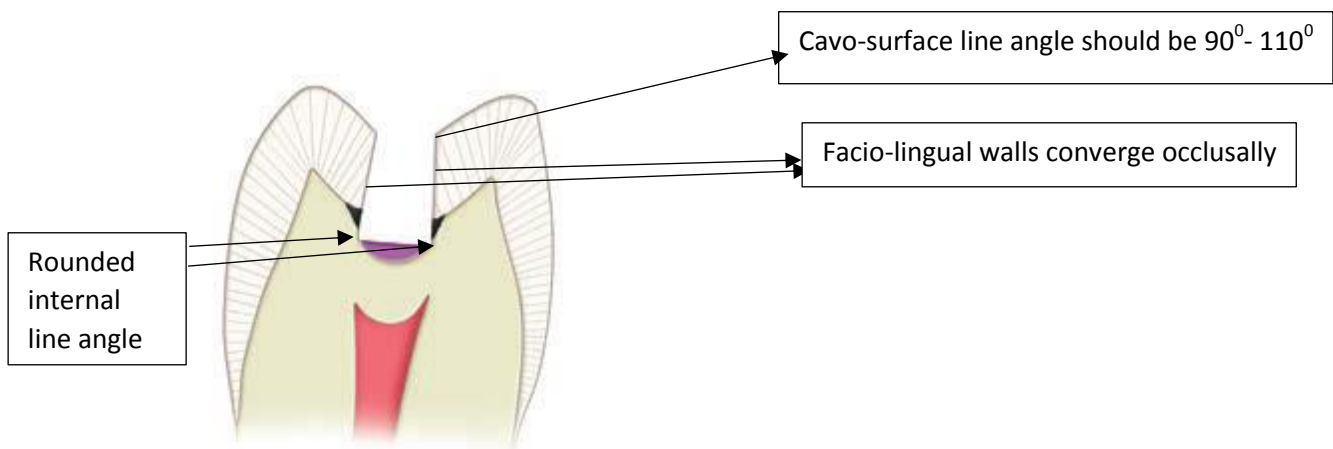


Fig 3: resistance factors which prevent fracture of the tooth

Preventing fracture of restoration

- The margins or Cavosurface line angle should be (90°-110°) if more than this lead to fracture of restoration.
- Facio-lingual width should be ¼ I.C.D because large surface area exposed to more force and fracture occur.
- Occlusal amalgam should have thickness of (1.5-2.0 mm) to resist fracture during function.

- The pulpal floor & gingival seat should be smooth to prevent concentration area on restoration.
- Rounded axio-pulpal line angle.

Step3. Retention form: is the shape of the cavity that permits the restoration to resist displacement through the tipping or lifting force.

To provide retention the cavity have the following:

- Facial & lingual walls should be parallel to each other or converge occlusally (5°) fig3.
- Pulpal floor & gingival seat of the cavity should be flat.
- Dove-tail preparation to increase retention fig4.
- Width of the cavity.
- The occlusal convergence of the box (from proximal view) fig5.
- Retentive grooves or locks in the axiofacial and axiolingual line angle fig5.

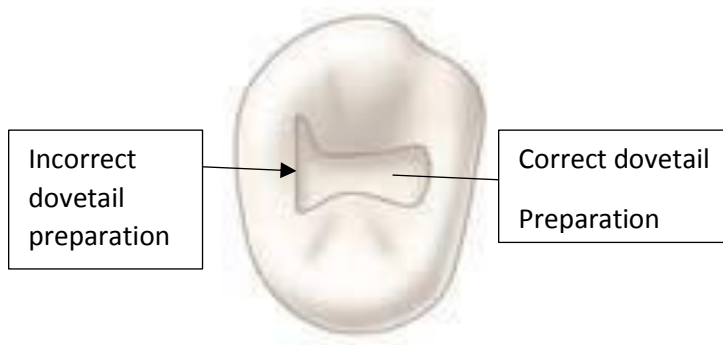


Fig: 4 dovetail

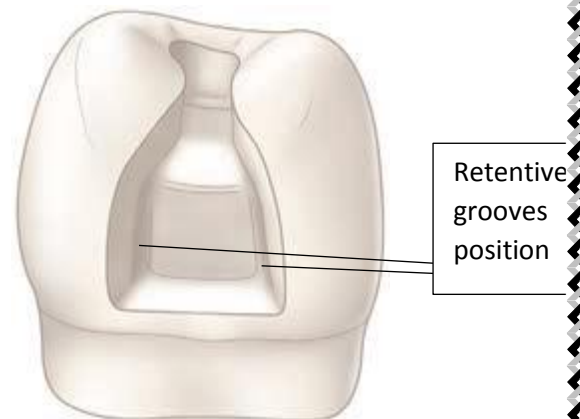


fig 5: proximal view of CIII box

Step 4: Convenience Form:

Convenience form is the shape or form of the preparation that provides for adequate observation, accessibility, and ease of operation in preparing and restoring the tooth.

Step5: Removal of remaining caries

Deep dentinal caries can be removed by using spoon excavator or large round bur with slow speed hand piece.

Step6: Finishing enamel walls

Involve making the wall smooth and removing of unsupported enamel.

Step7: Clean the preparation:

Removal of all debris by washing the cavity and drying it.

Clinically:

Occlusal outline form (occlusal step):

The occlusal outline form of Cl II tooth preparation for amalgam is similar to that for Cl I tooth preparation, enter the pit nearest the involved proximal surface with a punch cut using no.245 bur fig 6 A, the long axis of the bur & the long axis of tooth crown should remain parallel during cutting procedures, the bur should be rotating when applied to the tooth and should not stop rotating until removed.

Proper depth of the initial entry cut is 1.5-2 mm.

While maintaining the same depth & bur orientation move the bur to extend the outline to include the central groove & the opposite pit fig

6 B which provided by dovetail retention form the isthmus width should be as narrow as possible & no wider than $\frac{1}{4}$ I.C.D, it may be necessary to tilt the bur to create facial, lingual slight occlusal convergence & mesial and distal walls to diverge occlusally.

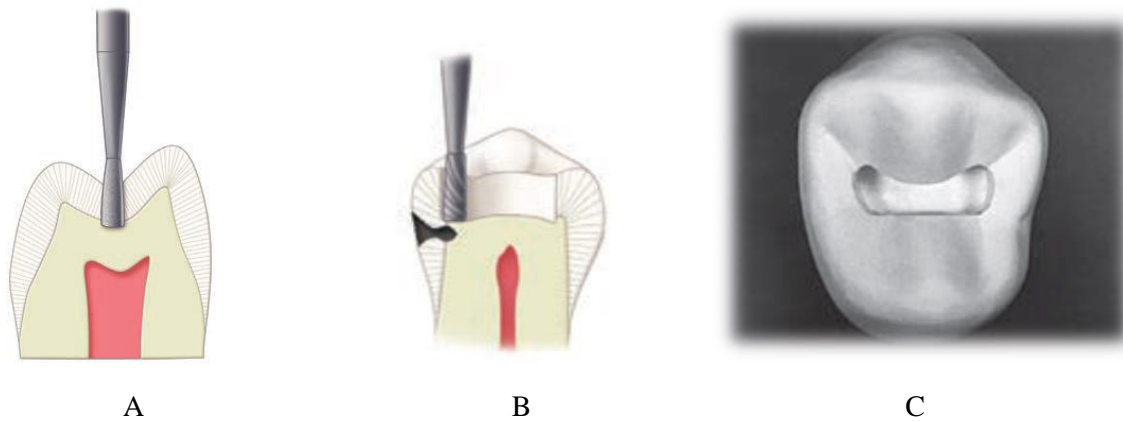


Fig6: A. initial depth, B. bur position to begin the proximal ditch cut. C, C I I cavity preparation

Proximal outline form (proximal box) preparation:

The objectives for extension of proximal margins are to:

- Include all caries, faults or existing restorative material.
- Remove unsupported enamel.
- Establish not more than 0.5 mm clearance with the adjacent proximal surface facially, lingually & gingivally.

The initial procedure in preparing the outline form of the proximal box is the isolation of the proximal enamel by the proximal **ditch cut** fig 7A this is a very important procedure in conservative tooth preparation.

Place the bur over the DEJ in the pulpal floor near the remaining marginal ridge, allow the end of the bur to cut the ditch gingivally then move the bur facially & lingually along the DEJ this lead to create **axial wall** fig 7 B, the ditch should extended gingivally just beyond the caries or

the proximal contact area, the location of final proximal margins (facial, lingual, gingival) should be established with hand instruments (chisel, hatchets, gingival margin trimmers) then remove the weakened enamel along the gingival wall by using the gingival margin trimmer in scraping motion.

Ideally the minimal clearance of the completed gingival margin with the adjacent tooth is 0.5 mm fig 7C.

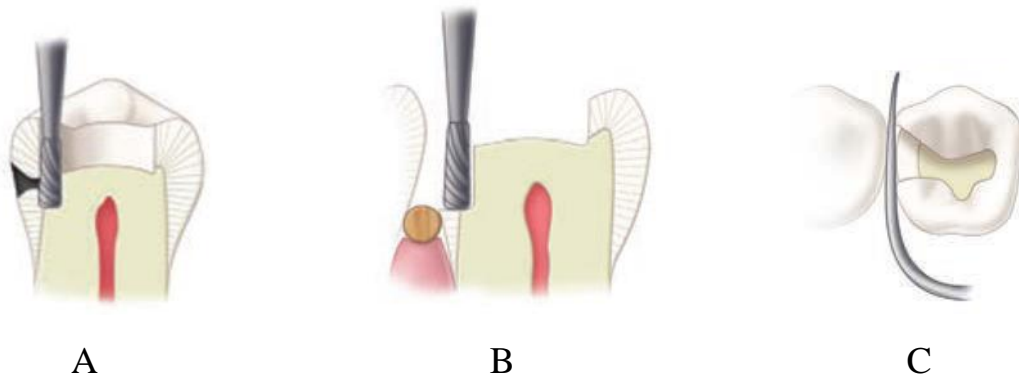


Fig 7: A_The proximal ditch is extended gingivally to the desired level of the gingival wall (i.e., floor). B, box formation. C, clearance of the gingival wall with the adjacent teeth.

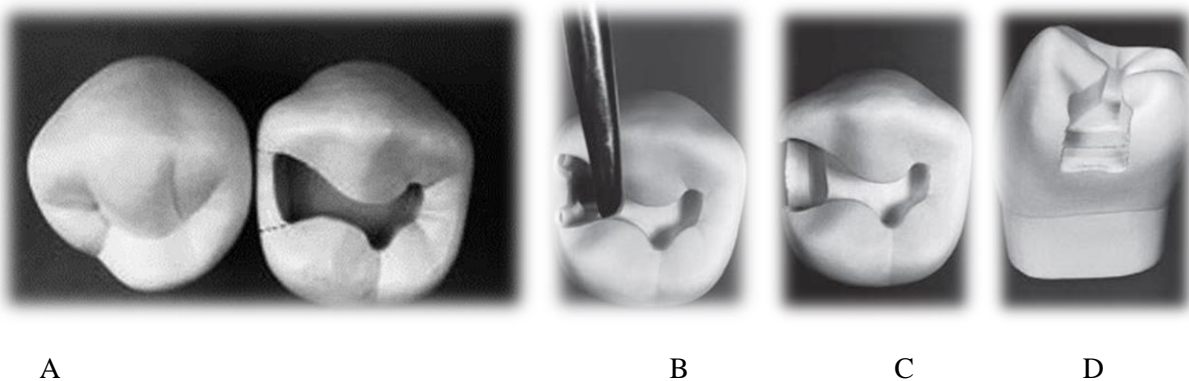



Fig 8: A_The proximal ditch is extended gingivally to the desired level of the gingival wall (i.e., floor). B, box formation. C, clearance of the gingival wall with the adjacent teeth D, proximal view of the tooth.

FINISHED



Conservative dentistry

LEC: 6

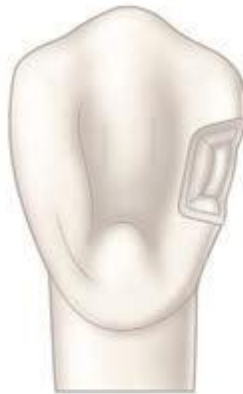Dr. Alalaa

CL III amalgam restoration

CLIII restoration indicated for defects in the proximal surface of incisors and canines without Incisal edge involvement fig1.



a



b

Fig1: a. Cl III caries, b. Cl III cavity

Indications:

Few indications exist for a Class III amalgam restoration. It is generally reserved for **the distal surface of maxillary and mandibular canines** if

- (1) The preparation is extensive with only minimal facial involvement.
- (2) The gingival margin primarily involves cementum.
- (3) Moisture control is difficult.

For esthetic reasons, amalgam rarely is indicated for the proximal surfaces of incisors and the mesial surface of canines.

Contraindications:

Class III amalgam restorations usually are contraindicated in **esthetically** important areas because many patients object to metal restorations that are visible

Advantages:

1. Amalgam restorations are stronger than other Class III direct restorations.
2. They are generally easier to place.
3. Less expensive to the patient.
4. Amalgam restorations are usually easier to finish and polish without damage to the adjacent surfaces.

Disadvantage:

1. Metallic color.
2. Less conservative cavity preparation when compared to that of esthetic restorative materials.

Outline form:

The outline form of the Class III amalgam preparation may include only the proximal surface fig2a. A lingual dovetail may be indicated if one existed previously or if additional retention is needed for a larger restoration fig 2b.

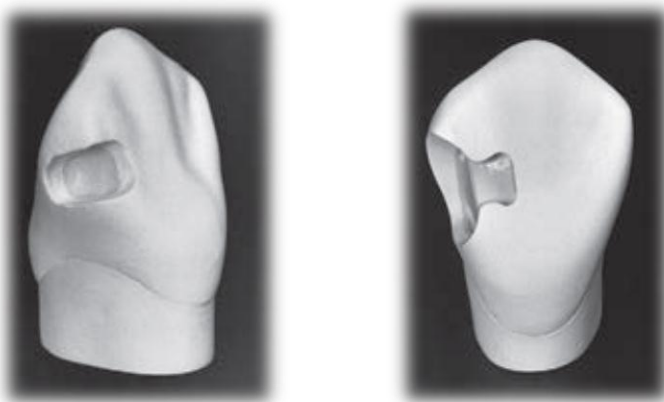


Fig2: a. Cl III preparation from proximal view, b. Cl III with dovetail.

Resistance form:

Resistance form against post-restorative fracture is provided by

- (1) Cavosurface and amalgam margins of 90 degrees.
- (2) Removal of unsupported enamel.
- (3) Sufficient bulk of amalgam (minimal 1-mm thickness).
- (4) Rounded internal angles.
- (5) Conserve the disto-incisal tooth structures as possible to reduce the risk for fracture

Retention form:

Retention form for Cl III preparation is provided by:

- (1) The box-like preparation form.
- (2) Gingival groove, incisal cove, and sometimes a lingual dovetail.

Tooth Preparation

A lingual access preparation on the distal surface of the maxillary canine is described here for esthetic reasons, use of facial approach for a mandibular canine may be indicated if the lesion is more facial than lingual fig3.

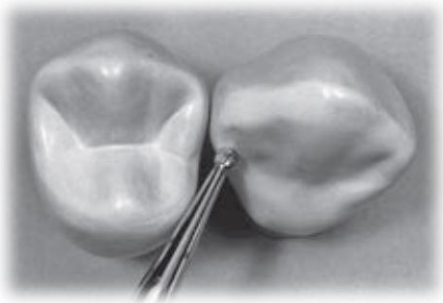


Fig3: initial entry for Cl III which conserve the marginal ridge.

Bur size selection depends on the size of the lesion, bur options may include a no. 2 (or smaller) round bur, the bur is positioned so that the entry cut penetrates into the caries lesion, Ideally, the bur is positioned so that its long axis is perpendicular to the lingual surface of the tooth, but directed at a mesial angle as close to the adjacent tooth as possible, this position conserves the marginal ridge enamel fig3.

Initial axial depth (0.5 mm) inside the DEJ or 0.75 mm axial depth when the gingival margin is on the root surface (in cementum)

(Infected dentin that is deeper than this limited initial axial depth is removed later during final tooth preparation) the cavity of CI III is made in a box-like preparation.

The **gingival retention groove** is prepared by placing a no.14 round bur (rotating at low speed) in the axio-facio-gingival point angle, It is positioned in the dentin to maintain 0.2 mm of dentin between the groove and the DEJ, the rotating bur is moved lingually along the axio-gingival line angle fig4.

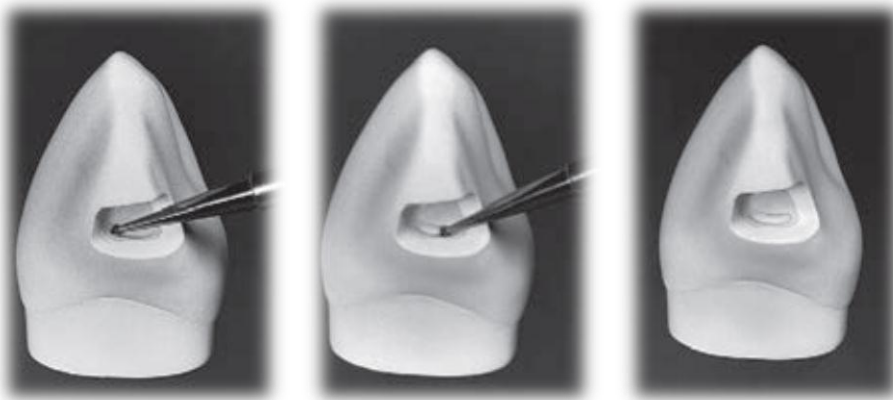


Fig4: Preparing the gingival retention form. A, Position of No. 14 round bur in axio-facio-gingival point angle. B, advancing the bur lingually to prepare the groove along the axio-gingival line angle. C, Completed gingival retention groove.

If less retention form is needed, two gingival **coves** may be used, as opposed to a continuous groove placed in the axio-gingivo-facial and axio-gingivo-lingual point angles, the diameter of the 14 round bur is 0.5 mm, and the depth of the groove should be half this diameter (0.25 mm).

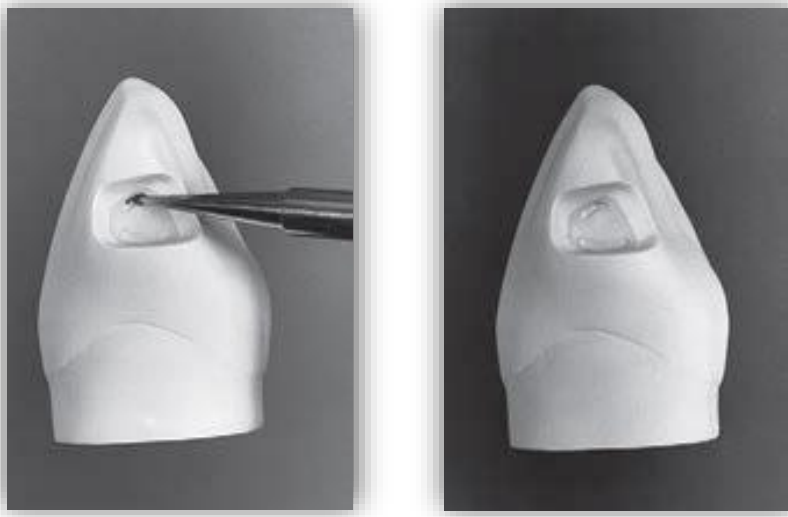



Fig5: Preparing the incisal retention cove. A, Position of No. 14 round bur in the axio-incisal point angle. B, Completed incisal cove.

If a lingual **dovetail** is needed fig6:

- It is prepared only after initial preparation of the proximal portion has been completed. Otherwise, the tooth structure needed for the isthmus between the proximal portion and the dovetail may be removed when the proximal outline form is prepared.
- The lingual dovetail should be conservative, generally not extending beyond the mesio-distal midpoint of the lingual surface; this varies according to the extent of the proximal caries.
- The axial depth of the dovetail should approximate 1 mm.

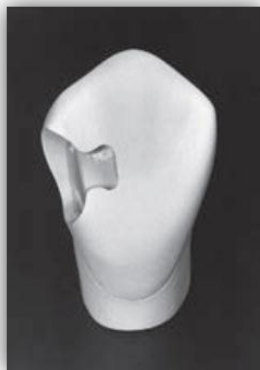

fig 6: lingual dovetail in CI III



Class V amalgam cavity preparation

Lec 7:

م.م العلاء جمال

Definition

Class V Caries: Smooth surface carious lesions located on the gingival/cervical third of labial/buccal and more rarely the lingual surfaces of all teeth.

Simple lesion as it mostly involves one surface of a tooth as shown in fig1.

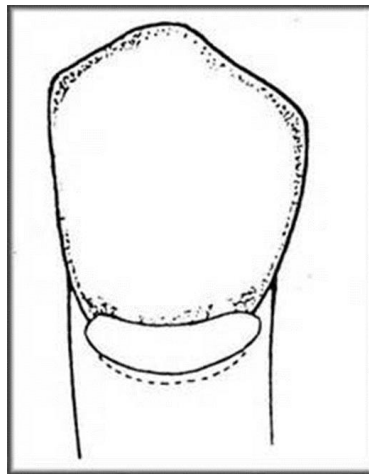


Fig1: CL V

Caries is not only the reason of cavitation, abrasion and erosion may also responsible

- **Erosion:** tooth loss at the cervical area due to nonbacterial acid attack.

- **Abrasion:** tooth loss at the cervical area of the tooth due to abrasive slurry between two surfaces (mechanical action) e.g: tooth brush – dentifrice abrasion.

In both cases there is no caries if we prepare a class V cavity it is better to be filled by amalgam, because of high abrasive resistance of amalgam.

Restorative materials for Class V cavity

- ✓ Amalgam
- ✓ Composite
- ✓ Resin modified GIC
- ✓ Compomers

Indications for amalgam as restorative material

- ✓ Non-esthetic areas
- ✓ Areas where access and visibility are limited
- ✓ Areas where moisture control is difficult
- ✓ Areas those are significantly deep gingivally.

Contraindications for amalgam as restorative material

- ✓ Esthetically important areas

Advantages of amalgam as restorative material

- ✓ Amalgam restorations are stronger than other direct restorations
- ✓ Easier to place
- ✓ less expensive to the patient
- ✓ Usually easier to finish and polish

Disadvantages of amalgam as restorative material

- ✓ The primary disadvantage amalgam restorations are that they are metallic and non-esthetic.
- ✓ The preparation for an amalgam restoration typically requires 90-degree cavo-surface margins specific and uniform axial depths, and incorporation of secondary retentive features, all of which results in a less conservative preparation than that for other esthetic restorative materials.

Clinical technique for class V amalgam preparation

Initial Clinical Procedures

- Local Anaesthesia
- Isolation (rubber dam recommended)

Tooth preparation

I. OUTLINE FORM

- Rounded trapezoid in gingival 1/3.
- Conforms to the tooth shape, typical caries location, and site of plaque accumulation.
- Primarily determined by the location and size of the caries/defect or old restorative material
- Cavosurface margins should be extended to sound tooth structure while maintaining a limited axial depth of 0.5 mm inside the DEJ and 0.75 mm inside the cementum (when on the root surface)

- Using round bur to start entry to the cavity, the direction of the bur should be perpendicular to the buccal (or palatal) surface of the tooth , then using a tapered fissure bur of suitable size, enter the carious lesion to a limited initial axial depth of 0.5 mm inside the DEJ.
- This depth is usually 1 to 1.25 mm total axial depth, depending on the incisogingival/occlusogingival location (The enamel is considerably thicker occlusally and incisally than cervically)
- However, if the preparation is on the root surface, the axial depth is approximately 0.75 mm.
- Extend the preparation incisally, gingivally, mesially, and distally until the cavosurface margins are positioned in sound tooth structure providing the desired outline form
- Preparation of the axial wall depth 0.5 mm inside the DEJ results in a uniform depth for the entire preparation.
- Because the axial wall follows the mesiodistal and incisogingival/occlusogingival contours of the facial surface of the tooth, it will usually be convex in both directions as shown fig 2.
- The mesial, distal, gingival, and incisal walls of the tooth preparation are perpendicular to the external tooth surface to keep the cavosurface angle 90 degree and to follow the direction of enamel rods, they usually diverge facially.
- Consequently, this form provides no inherent retention, and retention form must be provided.

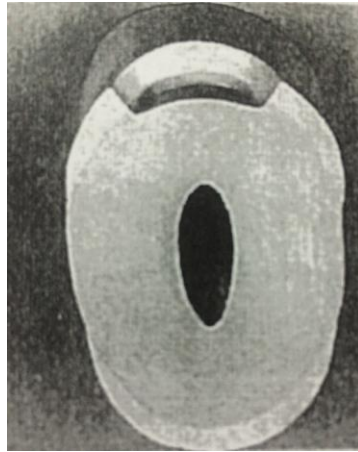


Fig 2: convex axial wall

II. Resistance form

- Depth of the cavity is 1.5 mm: the axial wall of the cavity should not be flat, if we do so will not have even depth of the cavity because of convexity of tooth structure, so the axial wall should be slightly convex.
- cavosurface line angle (90-110).
- Rounded internal line angles
- Removal of unsupported enamel
- Occlusal and gingival walls should be perpendicular to the long axis of the tooth and parallel to each other, any convergence of these walls will create unsupported enamel.

III. Retention form:

- Use a No. 1/4 bur to prepare two retention grooves, one along the incis axial line angle and the other along the gingivoaxial line angle (figure 3) 0.2-0.3mm inside the DEJ
- The handpiece is positioned so that the No. 1/4 bur is directed generally to bisect the angle formed at the junction of the axial wall and the incisal/occlusal or gingival wall

- Ideally the direction of the incisal (i.e., occlusal) groove is slightly more incisal (i.e., occlusal) than axial, and the direction of the gingival groove is slightly more gingival than axial.
- Mesial and distal walls should be slightly diverge.

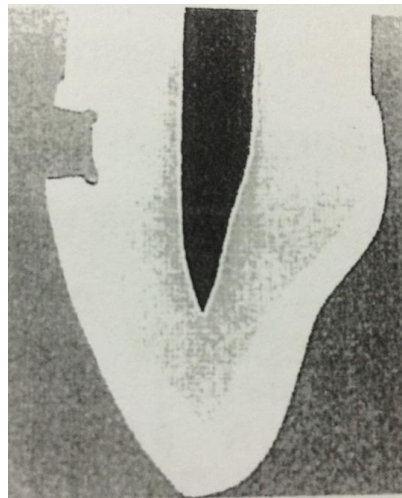


Fig 3: retentive grooves of CLV

III. Final preparation:

- Removal of any remaining infected dentin
- Pulp protection
- Finishing external walls
- Cleaning & inspecting

Summary

- **Outline form** – Rounded Trapezoid
- **Axial Depth-** 1- 1.25 mm (when margins in enamel), 0.75 mm when margins are in cementum (Root surface)
- **Axial wall-** 0.5 mm inside DEJ, Convex in all directions to conform the external tooth contour

- **Divergent Incisal, Gingival, Mesial & Distal walls-** follow the direction of enamel rods
- **Retention features-** Grooves & Coves- 0.2- 0.3 mm inside DEJ using ¼ round bur

Liners and bases material act as pulp protection agents require consideration of: chemical protection, electrical protection, thermal protection, pulpal medication, and mechanical protection (as in figure 1).

Reasons for use of base and lining materials:

1. Insulation against temperature changes and electrical stimuli under metallic restorations such as amalgam.
2. Mechanical protection provides by distributing local stresses from restoration across the underlying dentin surface.
3. To reduce the risk of microleakage.
4. Cementation of cast or ceramic restorations.
5. As a pulp capping.
6. Some have bactericidal or bacteriostatic properties.
7. Prevention of the risk of along-term damage to the pulp-dentin organ from operative treatment.
8. Cementation of orthodontic bands.

The ideal lining material should have these properties:

1. Be compatible with the restorative materials.
2. It should not irritant to the pulp.
3. Prevent injuries of the pulp-dentin from restorative materials.
4. Be insoluble in the oral fluids.
5. Possess sufficient physical strength during insertion of the restoration.
6. Prevent heat/cold conduction from metallic restorations.
7. It should have a bacteriostatic effect eg: zinc oxide eugenol.
8. It should improve the marginal seal and have sealing ability eg: zinc oxide eugenol, so we use it as a temporary restorative material.

9. It should be easy to manipulation and apply.

10. It should be radiopaque in the X-ray.

Two groups of pulp protection materials are available:

- Varnishes and liners
- Cement bases.

The materials may be used alone or in combination, depend on:

- The extent and location of the preparation.
- The restoration material to be used.

Liners: are materials that are placed as thin coating or layer.

Function:-

1. To provide a barrier against chemical irritation. (They do not function as thermal isolators).
2. Reduce marginal leakage around most filling materials (amalgam) so reduce the inflammatory reaction and post-operative sensitivity caused by marginal leakage.
3. Electrical insulation (treatment of galvanic shock).

The need for liners is greatest with metallic restorations that are not well bonded to tooth structure. eg: Varnish, Ca (OH)₂, and resin bond.

Bases:

(Cement bases, typically 1 to 2 mm). Deep parts in the dentin should be covered by a base or a subbase/base combination. The thickness of the base depends on its physical properties, but always allowing adequate thickness for the final restorative material.

Function:

1. Provide thermal insulation.
2. Mechanical protection by resist forces applied during condensation of the restorative materials.
3. A barrier against chemical irritation

The cement materials include:

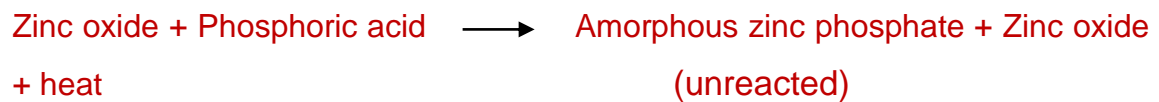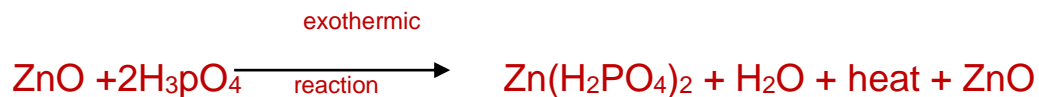
1- Zinc phosphate cement:

It is hard and strong but irritating to the pulp, it is a powder-liquid system. The powder consists mainly of zinc oxide with the addition of magnesium oxide and silicon dioxide.

The liquid consist of ortho-phosphoric acid (40%) with metallic salts that serve to slow down the setting reaction, and water.

Setting reaction:

When the powder is brought into contact with the liquid to begin the cement mix, wetting occurs and chemical reaction is initiated. The surface of the powder is dissolved by the liquid resulting in an exothermic reaction. The initial mixture is highly acidic.



Advantages:

1. Easy to manipulate.
2. High strength necessary for a base.
3. Withstand mechanical trauma.
4. Provide good protection against thermal shock.

Uses:

1. As a base material when high compressive strength is required.
2. To lute cast restorations to the teeth.
3. Cementation of orthodontic bands.
4. Rarely may be used as a temporary cement dressing.

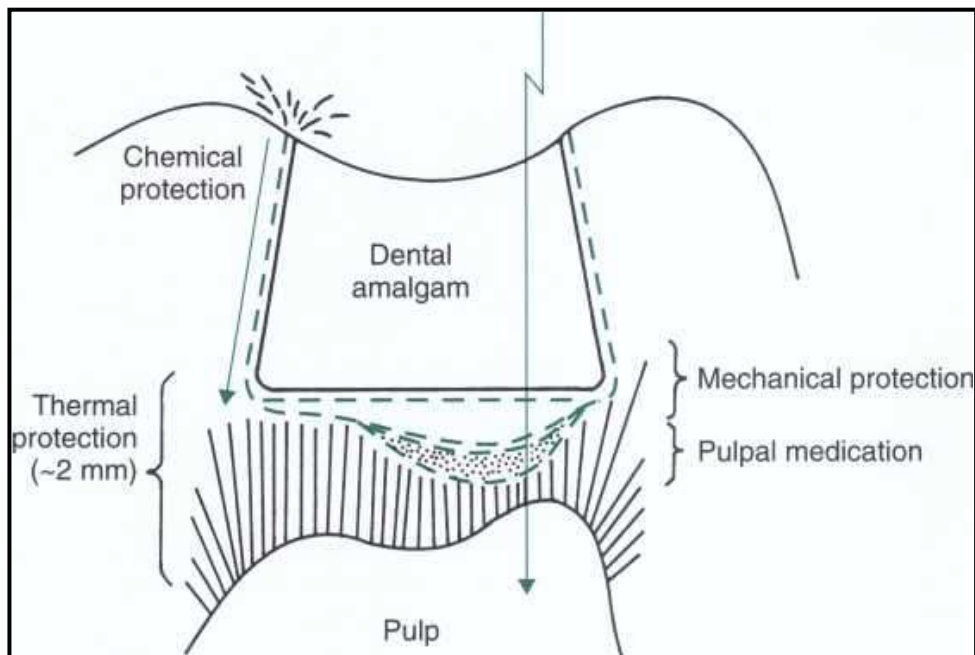


FIG . 1 Schematic view of needs for pulpal protection below metallic restoration. Varnishes, liners, and/or bases may be added to tooth preparation under amalgam for purposes of chemical, electrical, thermal, or mechanical protection, and/or pulpal medication.

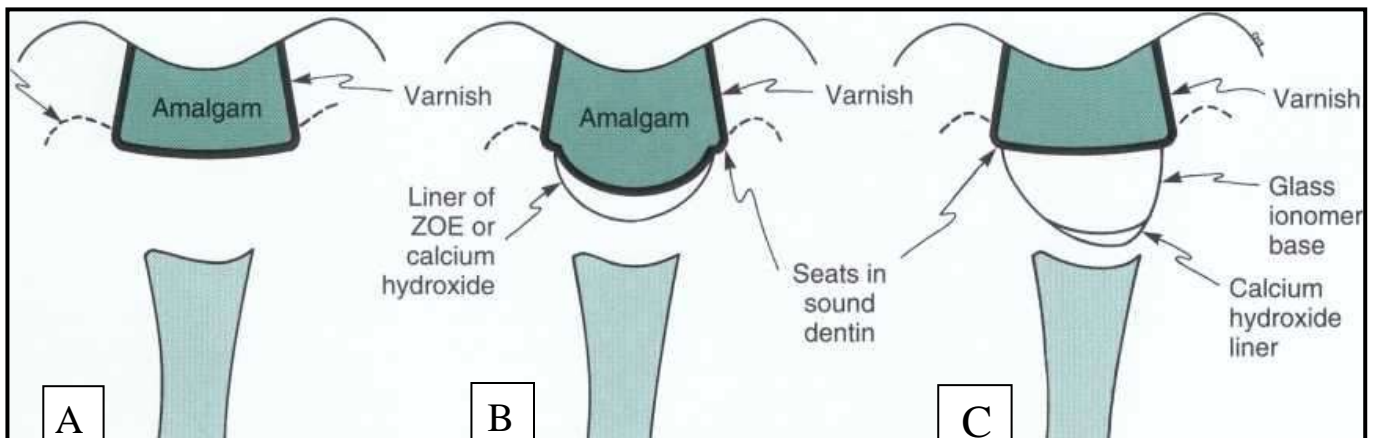


Fig. 2 Schematic examples of use of liners and bases for amalgam restorations. A, For shallow amalgam tooth preparations, varnish or sealer is applied to walls of preparation before insertion of restoration. B, For moderate depth tooth preparations, liners may be placed for thermal protection and pulpal medication. (Note seats in sound dentin for amalgam restoration.) C, In very deep preparation, calcium hydroxide is placed in deepest region in which infected dentin was excavated, and then base of glass ionomer is inserted. Amalgam bonding systems are being advocated as a substitute for liner and varnish, except for calcium hydroxide liner in the deepest region (judged to be within 0.5 mm of pulp).

Characteristic properties of zinc phosphate:

- 1. Consistency:** Two arbitrary consistencies: either luting consistency, or cement base consistency. In luting consistency less powder/liquid ratio is used in order to have creamy mix which is used for cementation of crown and inlays. While in cement base consistency more powder/liquid ratio is used to have putty mix of zinc phosphate cement which may be used as thermal insulator over a thin dentin and as high strength base.
- 2. Viscosity:** It depends on time and temperature of mixing. So mixing should be made on a cool glass slab to reduce the viscosity of mixing.
- 3. Setting time:** It is time elapsed between the end of mixing and the beginning of setting. Setting time of zinc phosphate range from 2 to 8 minutes at 37° C (depending on the product and the mixing consistency).
- 4. Strength:** Influenced by the initial powder and liquid composition, powder/liquid ratio and the manner of mixing, and the handling of the cement during its placement.
- 5. Solubility:** Greater resistance to solubility is obtained by increasing the powder/liquid ratio.
- 6. Dimensional stability:** Zinc phosphate exhibits shrinkage on hardening. This shrinkage can be reduced by increasing powder/liquid ratio and with proper incorporating of powder with liquid during mixing.
- 7. Acidity:** In early manipulation stage the cement is highly acidic, and this acidity reduced with time and become nearly neutral at 48 hours.
- 8. Thermal and electrical conductivity:** Zinc phosphate is desirable to protect against thermal and electrical trauma to the pulp.

Manipulation of zinc phosphate:

The proper amount of powder should be slowly incorporated into the liquid on a cool slab (approximately 21°C) to attain the desired consistency of cement.

- 1) **Mixing slab:** Because the reaction between zinc oxide and phosphoric acid is exothermic reaction, the glass slab should be thick cool and clean.
- 2) **Powder/liquid ratio:** Because an increase in the ratio of powder to liquid generally provide more desirable properties, incorporation as much powder as possible to obtain a particular consistency.
- 3) **Care of the liquid:** When zinc phosphate cement liquid is exposed to a humid atmosphere, it will absorb water, whereas exposed to dry air will lose water. Addition of water cause more rapid reaction result in shorting setting time. While loss of water from liquid will lengthened the setting time. So the cement liquid bottle should be kept tightly closed when not dispensing the material.
- 4) **Mixing procedure:**
 - a) The powder should be divided into several small amounts as in figure (1), so that each may be separately drawn into the liquid and spatulated. The liquid is dispensed to another area on the slab.
 - b) Mixing over a large area: The heat of the reaction is most effectively dissipated when the cement is mixed over a large area of the cooled slab. A long, narrow-bladed stainless steel spatula may be used to spread the cement across this large area (as in figure 2).
 - c) The zinc phosphate should be mixed to a thinner consistency for setting inlays or cementation of crowns. A thick mix or thick consistency (a putty-like mixture) is used when basing material is

required. This will cause lowered initial acidity of the base material, less post operative pain, and ease of placement.

d) Mixing time not more than 60-90 Sec. 15 for each increment.

5. Frozen slab method: In this method a glass slab is cooled in a refrigerator at (6 °C) or a freeze at (-10 °C). A mix of cement is made on the cold slab by adding the powder until the correct consistency is reached. The advantages of the frozen slab method are an increase in the working time and shorter the setting time. This method has been advocated for cementation of bridges with multiple retainers, also for preparing base material for multiple cavities at the same visit, or for cementation of orthodontic bands.

6. Insertion:

- a) The tooth structure should be dry; this will insures better adhesion and a harder set.
- b) Small quantity of cement is rolled lightly into a ball between the thumb and the forth finger then picked up on the point of a probe and carried into the cavity (as in figure 3).
- c) Then the cement shaped with appropriate instrument, either (Ash 49) on the pulpal floor of the cavity, or (Ash 6) to adapt the cement on the axial wall in class II cavity. The instrument coated with the powder of the cement to prevent the cement from sticking to the instrument. The axiopulpal line angle is molded to around angle with the same instrument.
- d) Small excavator is used to remove any excess from the retention grooves or pits and from the cavity walls. Any trimming by burs should be delayed for at least 10 minute after insertion to avoid dislodgment. If need to do that (do it with sharp burs operated at low speed and minimum pressure). Adequate space should be left for the restoration, otherwise it becomes weak and fracture will occur

due to thin restoration. No cement should be extending over any margins of the cavity and in the undercuts.

* When there are one or two spots of caries on the pulpal floor they should be removed by round bur, but without removing the sound dentin around these spots to gain flat pulpal floor, because this may cause pulp exposure. In this case a base material is used in these deep parts to have flat pulpal floor.



Figure (1). Cement powder divided into small increments on a thick glass slab.



Figure (2). Mixing of zinc phosphate is done on a wide area on a glass slab.



Figure (3). A mixed Cement ball is carried by the tip of the probe into the cavity

2- Zinc oxide-eugenol cements (ZOE):

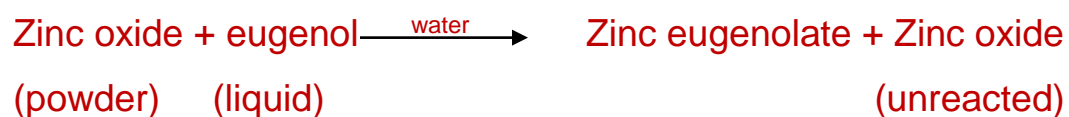
Powder: Zinc oxide with the addition of white rosin to reduce the brittleness of the set cement, and zinc acetate to improve the strength of the cement.

Liquid: eugenol with olive oil as a plasticizer.

Two compositional changes have been used to increase the strength of the cement for luting purposes:

- 1- Methyl methacrylate polymer is added to the powder.
- 2- Alumina (Al_2O_3) is added to the powder and ethoxy benzoic acid to the liquid.

Setting reaction:



- 1- The reaction is not exothermic a cooled mixing slab is not required and the presence of moisture is essential for setting to occur.
- 2- There is no need to incorporate the powder in small increments. The bulk of powder is incorporated in the initial step, and then a series of smaller amounts is added until the mix is complete.
- 3- The average setting time is around 8 minutes.

Properties:

1. Neutral in PH (7) can be safely used in moderately deep cavities without danger to pulp.
2. Has a sedative effect on the pulp so that we use it without any varnish or liner.
3. Radio-opaque.
4. Excellent seal against leakage, so used as temporary restoration.

Uses:

1. As temporary restorations.
2. The modified type used as a crown and bridge cementation and as a cement base.
3. As an endodontic sealer.

* Zinc oxide eugenol Cement is unaccepted as base material under composite restorations because it impaired the setting reaction (polymerization) of composite resin.

3- Zinc polycarboxylate cement:

Zinc polyacrylate cements (or zinc polycarboxylate) are supplied as a powder and a liquid or as a powder that is mixed with water. The liquid is a water solution of polyacrylic acid (32% to 42%). The cement powder is essentially zinc oxide and magnesium oxide. The cement powder that is mixed with water contains the zinc oxide particles coated by 15% to 18% polyacrylic acid.

Properties

- 1- Poly carboxylate cement is one of the dental cement systems which have chemical adhesion to enamel and dentin, by the ability of the carboxylate groups in the cement molecule to chelate to calcium in enamel and dentin.
- 2- The large sizes of the polyacrylic acid molecule, which can't penetrate through dentinal tubules, make this cement low irritant to the pulp, so this cement is used as a base or for cementation with sensitive teeth.
- 3- Short setting time (2-6 minutes).
- 4- This cement is sensitive to disintegration and solubility more than zinc phosphate cement.

Uses:-

- 1- As a luting agent.
- 2- As a base material.
- 3- In orthodontics for cementation of bands.

Manipulation:-

1. Powder/liquid ratio for the base consistency is 2-3 parts of powder to 1 part of liquid by weight. The powder/liquid ratio

- becomes (1.5/1) when using poly carboxylate cement as a luting agent.
2. Dry and cool glass slab are used for mixing, the cooling slows the chemical reaction and thus provide longer working time.
 3. The liquid should not be dispensed until just prior to the time of mixing, to avoid evaporation of water which cause increase in the viscosity and this will cause decrease in strength and higher solubility.
 4. The mix should be completed within 30-40 second.

4- Glass ionomer cement :-

Glass ionomer cements are supplied as a powder and a liquid or may come as capsules. The powder is fluoro-alumino-silicate glass. The liquid typically is a 47.5% solution of 2: 1 polyacrylic acid and itaconic acid copolymer.

Uses:-

- 1- As a base material.
- 2- Luting agent.
- 3- Also can be used as filling material specially of the modified types of glass ionomer cements (CI I, CI III, CI V).
- 4- Fissure sealants.

Properties:

1. The compressive strength is greater than zinc phosphate cement.
2. Glass ionomer cements are very sensitive to contact with water during setting. The field must be isolated completely. If glass ionomer is used as filling material, once the cement has achieved its initial set (about 7 minutes), coat the cement

- surface with a coating agent such as a varnish, because the complete setting reaction takes place in 24 hours.
3. Glass ionomer cement bond to tooth structure chemically by ionic interaction with calcium and/or phosphate ions from the surface of the enamel or dentin. In addition, when the enamel surface is conditioned (etched with 37% phosphoric acid), the bond strength of glass ionomer cement become greater, because acid etching of enamel surface will produce micro porosities on the etched surface that will improve the mechanical retention.
 4. Glass ionomer cement release fluoride, so it has anti cariogenic effect (bacteriostatic or bactericidal), thus this cement can be used in patient with a high caries index.

Classification of glass ionomer cement:

The most practical classification of the Glass ionomer cements is on their clinical usage into:

Type I Glass ionomer cements are the **luting cements**, characterized by low film thickness and rapid set.

Type II Glass ionomer cements are **restorative cements**, with sub-types into two types. **Type II-1** Glass ionomer cements are **aesthetic cements** (available in both conventional and resin-modified presentations) and **Type II-2** Glass ionomer cements are **'reinforced'** cement which are more wear-resistant.

Type III Glass ionomer cements are the **lining cements** and **fissure sealants**, characterized by low viscosity and rapid set.

5- Resin cements:-

Are thin versions of restorative resins (e.g. calibra and panavia resin cements), consist of a resin matrix with inorganic fillers that are bonded to the matrix with monomers. The fillers are silica or glass particles, and the fillers level vary from 40%-80% by weights. The bonding of the cement to enamel be attained by the acid-etch technique. Then bonding agent is used to provide mechanical adhesion of the cement to etched surface of the tooth.

Polymerization of resin cement is achieved either by chemical reaction (self cure), light activation (light cure), or both (dual cure). The self cured composite cement are typically two pastes system (base and catalyst), while the light cure cement is a single component system.

Properties:

- 1- Resin cements are insoluble in oral fluids.
- 2- Higher filler particles loading result in higher mechanical properties (strength and stiffness) and reduce polymerization shrinkage, and a lower coefficient of thermal expansion.
- 3- In some products fluoride is added to act as anticariogenic factor, and reduce the resin cement sensitivities.

Uses:

1. As a luting material either for cast or for tooth colored restorations such as esthetic ceramic and laboratory processed composite restoration.
2. Also resin cement with high filler range can be used as a base material.

Cavity liners:

1- Cavity varnishes:-

They are solutions of natural resins or synthetic resins dissolved in a solvent such as alcohol, chloroform, or acetone. The solvent evaporates, leaving a thin film on the cavity preparation.

Functions:-

- 1- It is placed on enamel and dentin walls to reduce the penetration of oral fluids around amalgam restoration. The cavity varnish inhibited microleakage during the first few weeks. After that the varnish will dissolved by oral fluids and replaced by the corrosion products of the amalgam which form at the amalgam tooth interface.
- 2- Varnish is applied on dentin surfaces to minimize penetration of the acid from zinc phosphate cements by occluding the orifices of the dentinal tubules.
- 3- Reduce post operative sensitivity.

Properties:

- 1- Varnishes, neither posses mechanical strength, nor provides thermal insulation because of thin film thickness.
- 2- When glass ionomer cement is used as abase material, varnish should not be used as subbase, because glass ionomer cement contains fluoride, and varnish prevents fluoride release and reaction with the tooth, also varnish prevents the chemical bonds between tooth and glass ionomer cement.
- 3- Varnish should not be used when the restoration is composite resin. Because varnish inhibits polymerization reaction of

composite resin material. So calcium hydroxide can be used under composite resin.

Manipulation: - Varnish solutions are usually applied by a mean of a small round piece of cotton. A thin layer is applied on the preparation then gently dried with steam of air. A minimum of 2 thin layers should be applied, as the initial layer dries it leaves small voids, so the second layer fills in the voids and produce a more continuous coating. Varnish solutions should be tightly capped immediately after use to minimize loss of solvent. Most varnishes are supplied with a separate bottle of a pure solvent this solvent used to keep the varnish from becoming too thick, also used for removing varnish from external tooth surface.

2- Bonding agent:

Generally bonding agents are unfilled resins which are used for mechanical adhesion of the composite restoration to the conditioned enamel and dentin. The conditioning is achieved by using of 37% phosphoric acid for 15-60 seconds then washing and dryness of the tooth. These bonding agents act as liner for the composite restorations especially for shallow cavities, because they occlude the orifices of dentinal tubules and reduce post operative sensitivities.

Also special bonding agents are introduced as amalgam bond which can act as a liner for amalgam restorations by sealing the cavity against fluid flow and microleakage.

3- Calcium hydroxide: Ca(OH)₂

Usually referred as liner, intermediate base, or pulp capping agent; examples: calcupul, dycal, hydrex. Calcium hydroxide

supplied as a two paste system one is a base and the other is a catalyst.

Properties:

- 1- The set material has an alkaline PH (9.2-11.7), which reduces the acidity of zinc phosphate when used as a sub base material in deep cavities.
- 2- The antimicrobial action of calcium hydroxide makes this material useful in **indirect pulp capping** procedures.
- 3- Calcium hydroxide stimulate the odontoblast cells for the formation of secondary dentin (stimulate the formation of dentinal bridge) when it is put directly over exposed pulp tissue, so calcium hydroxide is used for **direct pulp capping**.
- 4- Water is important component for the setting reaction of calcium hydroxide based liner.

Manipulation:-

Equal lengths of the different colored pastes are dispensed on a paper pad and then mixed into a uniform color (homogenous) and then applied by using of dycal applicator. The setting time is short (about 1-2 minutes); therefore, the mix should be done quickly and then applied on a dry dentin so flow freely and easily. Proper setting requires humidity; place a moist cotton pellet at the opening of the cavity, on top of the newly placed cement for 30 seconds. Be sure that the cotton does not contact the cement. After 30 seconds, check the cement gently with the explorer to ensure that it cannot be penetrated.

* A resin has been added to calcium hydroxide to improve its properties (improve thermal and mechanical properties, reduce solubility) and the setting is performed by light curing.

General Clinical Consideration: -

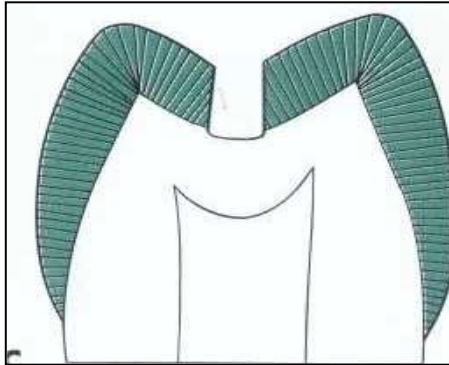
After cavity preparation, certain factors should be taken in consideration during lining placement in the cavity:

- 1- The prepared cavity should be clean and dry before application of lining material. The quadrant of the prepared tooth should be isolated completely from saliva, because the entire lining and base material are sensitive to water during their application and setting.
- 2- All liners and base materials undergo dissolution and disintegration in saliva with time; therefore, they should not reach to the margins of the cavity (except varnishes and bonding agent). So lining is placed on: pulpal floor in CI I, pulpal floor and axial wall in CI II, axial wall in CI III, IV, and V.
- 3- In cavities prepared for amalgam restorations, the base material should not be extended on the walls of the cavity because this material will block the undercuts (convergence of the buccal and lingual walls) which are important for the amalgam retention. Also all the retentive holes, grooves, and pins should be free from lining before amalgam placement.

Cavities can be classified according to their proximity from the pulp into:

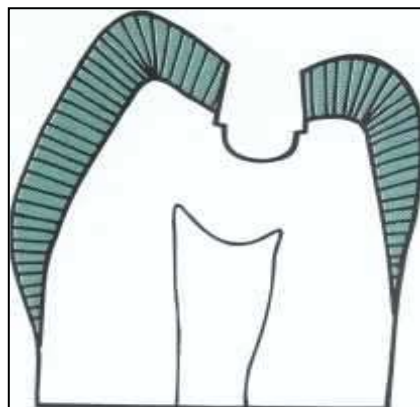
- 1- **Shallow cavity preparation:** - (as in fig bellow) there is no need for pulpal protection, there is a sufficient thickness of

dentin so that no protective base required. For dental amalgam the cavity is coated with two thin coats of a varnish or amalgam bond and restored. For a composite the cavity is etched, coated with a single coat of a bonding agent and restored. Both varnish and the bonding system provide chemical protection.



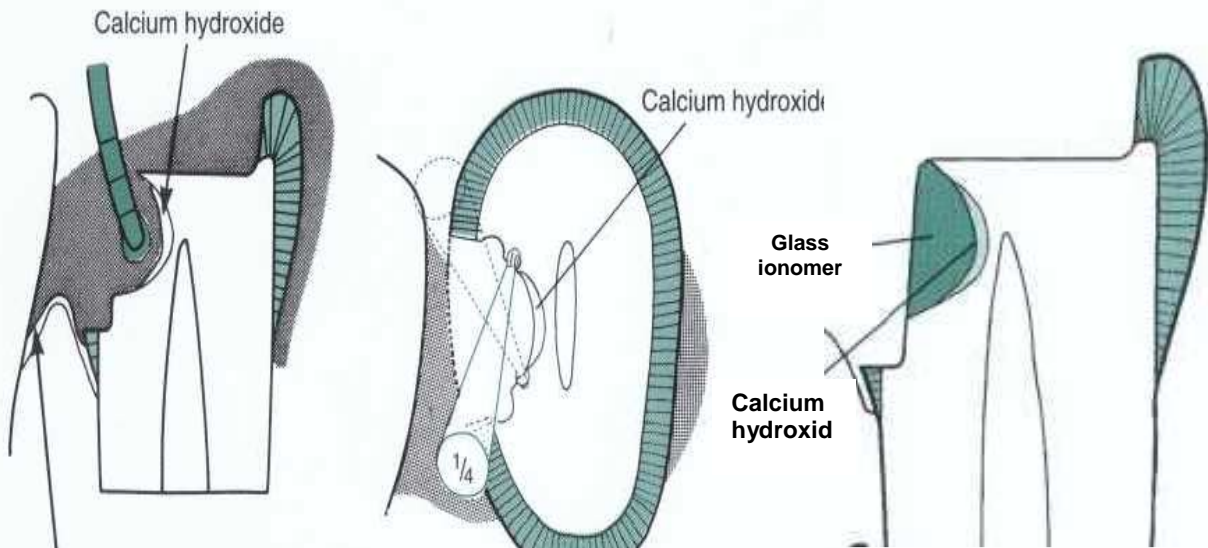
2- Moderately deep cavity: - (as in fig bellow) a prepared cavity that extends into dentin beyond the minimal depth necessary to attain retention and strength for the restorative material.

Varnish is used to coat the floor and walls, then a cement base such as zinc phosphate cement, or modified ZOE cement may be contoured to replace the missing dentine.



3- Deep cavity: - (as in fig bellow) that includes some extension toward the pulp, a liner such as Ca (OH) 2 should be applied on the pulpal and axial walls. On top a cement base is placed

such as zinc phosphate cement, or modified zinc oxide eugenol cement or poly carboxylate cement then a varnish is used to coat the walls. Recently, new protocol prefers the use of dycal with glass ionomer base, because of the present of chemical bonding between the tooth and the glass ionomer cement that will reduce microleakage and the sensitivity postoperatively.



4- Deep cavity with exposure of the pulp: - exposure of a small area of the pulp with no sign or symptoms of degenerating pulp, the choice of conservation pulp capping is recommended. In an isolated clean field, calcium hydroxide is carefully placed over the pulp and the border of dentin which surround the exposure site. A base material is placed on top (such as zinc phosphate or reinforced zinc oxide eugenol), and also glass ionomer cement base is preferred. The restoration of the tooth should be completed as soon as possible. Secondary dentin barrier is likely to be formed within a few weeks.

Conservative dentistry

LEC: 10

Dr. Alalaa

Dental Amalgam

Is an alloy made by mixing liquid mercury (Hg) with the solid particles of the silver-tin dental amalgam alloy (Ag-Sn). The powder silver-tin alloy may contain varying amounts of copper and small amounts of other elements such as zinc. Dental amalgam is the most widely used direct filling material for the posterior teeth since its introduction in the mid of 1800s.

Advantages

- 1- Can be easily contoured to resemble the anatomy of the lost part of the tooth.
- 2- It has a reasonable force resistance.
- 3- Least technique sensitive of all restorative materials.
- 4- Applicable to a broad range of clinical situations.
- 5- Newer formulations have greater long-term resistance to surface corrosion.
- 6- Ease of manipulation by dentist. Can be easily inserted in the cavity.
- 7- Minimal placement time compared to other materials.
- 8- Initially, corrosion products seal the tooth-restoration interface and prevent bacterial leakage.
- 9- One appointment placement (direct material)
- 10- Long lasting if placed under ideal conditions (long service life).
- 11- Economical (Low cost filling).
- 12- No sensitivity to the mouth tissue and, it is not irritant.

Disadvantages

- 1- Some destruction of sound tooth tissue.
- 2- Poor esthetic qualities.
- 3- Long-term corrosion at tooth-restoration interface may result in "ditching" leading to replacement.
- 4- Galvanic response potential exists.
- 5- Concern about possible mercury toxicity.
- 6- Marginal breakdown.

Composition of dental amalgam:

Powder: The alloy powder composed of:

1- **Silver;** it is about 40-70% w.

- ✓ Gives strength.
- ✓ Produce high expansion of the restoration.

2- **Tin;** it is about 20-30% w.

- ✓ Gives contraction.
- ✓ Increase affinity for mercury.
- ✓ Speed the amalgamation.
- ✓ reduce compressive strength
- ✓ Increase the flow of the amalgam.

3- **Copper;** if its concentration is between 15-30% called high copper alloys, and if the concentration is less than 5% called low copper alloys, Copper lead to:

- ✓ Reduce corrosion of the restoration.
- ✓ Minimize the flow.
- ✓ Increasing setting expansion.

4- **Zinc;** if its concentration more than 0.01% the alloy classified as zinc containing alloys, and if it is less classified as zinc free alloys. Zinc:

- ✓ Acts as a scavenger for oxides formed during manufacturing.
- ✓ Help the process of amalgamation.

The alloy particles have different sizes and with different shapes according to the manufacture. If the shapes of the particles are irregular so the alloy is called **lath-cut** alloy, and if they have spherical shape called

spherical alloy, or it may be a mixture of both (lath-cut and spherical particles) so called **admixed** alloy.

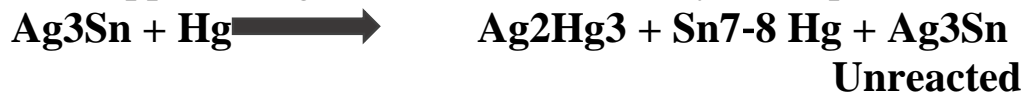Liquid: is pure mercury which is highly dense liquid, very toxic if it's improperly handled. It can be absorbed by skin and it may inhale of its vapor during placing or removal of amalgam restoration. The mercury must be very pure because its impurities may reduce its combination with the alloy.

Amalgam alloys can be classified basically according to:

- 1- Alloy particle geometries, into lathe cut, spherical (these alloys called uni compositional alloys), and admixed alloys.
- 2- Zinc content, into zinc containing, and zinc free alloys.
- 3- Copper content, into high copper and low copper alloys.

Amalgamation:

It is the process of reaction between the mercury and the amalgam alloy. The amalgamation reaction consists of two phenomena which include **solution** and **crystallization**. The amalgam alloy is intimately mixed with liquid Hg to wet the surface of the particles and leads to form at the surface a silver-mercury and tin mercury phases and this crystallization growth leading to cause a hard amalgam. The amalgamation of conventional or low copper amalgam can be described by this equation:



Ag₃ Sn is the silver tin alloy which is called (γ) phase. Ag₂Hg₃ is silver mercury or called (γ₁) phase which is the predominant product of the reaction. Sn₇₋₈ Hg is tin mercury or called (γ₂) phase which is the weakest and the more corrodible phase of the reaction. Also unreacted silver-tin (γ) phase is remaining in the mixture which is the strongest phase. So mixed amalgam can be described as particles of (γ) phase surrounded or bonded by continuous matrix of (γ₁) and (γ₂) phases. While in the high copper alloys the amalgamation process differs in that these alloys contain proper amount of copper causes most, if not all, of the (γ₂)

phase to be eliminated within a few hours after its formation or prevents its formation entirely, therefore, high copper amalgams tend to have superior physical and mechanical properties.

Properties of dental amalgam:

1- Compressive strength: amalgam has high compressive strength for high copper alloy and less for low copper alloy. Because amalgam is brittle material therefore a sudden application of excessive forces to amalgam tend to fracture of amalgam restoration.

2- Tensile strength: Because amalgam is strongest in compression and much weaker in tension and shear, the prepared cavity design should maximize the compression forces in service and minimize tensile and shear stresses resulted from bite forces.

3- Creep: Is permanent deformation under static loads. Under a continued application of force in compression, an amalgam shows a continued deformation, even after the mass has completely set. The maximum allowable creep value for dental amalgam should not exceed 3%. After aging of the amalgam restoration at oral temperature for 6 months the creep value will be reduced. High copper alloys have lower creep values in compared with low copper alloys. So low copper alloys may have high incidence of marginal fracture (ditching of the margin as in figure 1) in compared with high copper alloys.

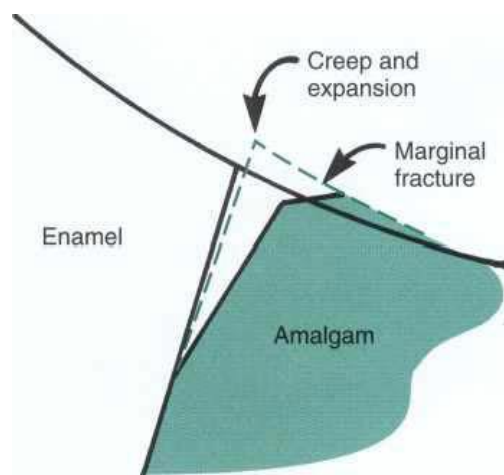


Figure (1) Schematic view of Class I amalgam restoration with expanded margin due to creep that lead to marginal fracture and ditching

4- Dimensional changes: The amalgam undergo shrinkage at the first time after setting (first 20 min.) and after this period the expansion will occur, although, the total change remain negative, and the dimension become constant within 24 hours.

If a contamination of the amalgam with moisture will occur during mixing or condensation, the zinc in the amalgam will decompose water into H₂ and O₂ gases which will lead to excessive delay expansion of the amalgam restoration and this may cause; marginal discrepancy, pitting of the surface of the restoration, compression on the surrounding tooth surface, post- operative pain, fracture of the restoration, and recurrent caries.

5- Corrosion: It is a progressive destruction of the metal by chemical or electrochemical reaction with its environment. The early corrosion products are important to reduce the marginal leakage of the freshly placed restoration. Excessive corrosion can lead to increase porosity, reduce marginal integrity (ditching of the restoration margins), loss of strength, and release of metallic products into the oral environment.

Tarnish of the amalgam is black discoloration of the surface due to chemical corrosion with the sulfide.

Packing of the amalgam alloy:

The amalgam alloys are packed either as powder alone or as a pre weighted capsules containing both the alloy and mercury. The alloy is separated from mercury by membrane which is ruptured during mixing. Manufactures commonly supply capsules containing 400, 600, or 800 mg of alloy with appropriate amount of mercury. The alloy/mercury ratio is determined by the manufacture according to the type of alloy and the size and shape of its particles.

Amalgam mixing (trituration):

In the past the alloy and mercury are mixing manually with mortar and pestle. But now mechanical amalgamator machines give standard produces and can save time. Two types of amalgamator are present; one

type used for mixing of the powder and liquid in different containers, and the other for mixing of pre weighted capsules, or both types are present in one machine. The speed (if possible) and time of mixing should be adjusted according to the manufacture before starting of mixing.

Three types of mixing may be resulted with different appearance and properties:

1- Undermixed (undertriturated) amalgam: which appear dull and crumbly. The mercury does not completely wet the outer surfaces of the particles, so the mass remains soft for a longer period of time, producing an amalgam with a longer working time. Such an amalgam mass contains excessive amounts of porosity, has lower strength, and possesses poorer corrosion resistance.

2- Normal mix: which appear shiny and separated in one mass from the capsule.

3- Overmixed (overtriturated) amalgam: which appear soupy and tend to stick to the inside of the capsule. Over-trituration reduces working time, causing the reaction rate to increase because the amalgamated mass becomes hot. The resulted amalgam has low compressive strength and high creep.

Amalgam condensation:

Condensation of the amalgam inside the cavity is important for:

1- Good adaptation of amalgam to cavity walls and margins.

2- To get compact and homogeneity amalgam restoration and minimal voids, this can effect on the strength of filling.

3- To remove excess of mercury and this reduce the dimensional changes, creep and increase compressive strength of filling.

□ After mixing, the amalgam must be used immediately without prolonging the time between mixing and condensation because this will lead to condensation of partially set amalgam and that may lead to break and fractures in the matrix that has been formed in the mixed amalgam.

□ Cavity to be filled should be kept completely dry during amalgam condensation.

A-Hand condensation:

- 1- There are many hand instruments with many tip shapes and with different sizes.
- 2- Lateral and vertical direction of the condensation provides better adaptation of the amalgam to the cavity walls and floor.
- 3- Amalgam should never be touched with hands to eliminate contaminations.
- 4- The amalgam carried to the cavity in small amount by using of amalgam carrier and condensation should be done immediately to each small increment, because if large amount of the amalgam is putted in the cavity, the condensation will be ineffective to have a properly condensed restoration with low amount of mercury.
- 5- After condensation of each amount, the surface of the amalgam will appear shiny because there is excess of mercury present at the surface. This excess mercury should be removed from the surface of each amount of amalgam before applying the next increment.
- 6- Condensation is continued till we have over-filled cavity, this mean put amount of amalgam above the occlusal surface and this overfilling is important for:
 - a- To ensure that the cavo-surface margins are completely covered to avoid exposure of that margins.
 - b- To be able to do good carving.
 - c- Get rid of excess mercury.

B- Mechanical condensation:

Many mechanical devices are available for condensing amalgam. These devices are more popular and more useful for condensing irregularly shaped alloys when high condensation forces are required.

Amalgam carving:

The main aim of carving the amalgam is for removal of the excess material and maintains the structure of the tooth. There are many instruments that can be used for carving such as carver and spoon excavator.

- after ending of the condensation, the surface of the overfilled amalgam should be burnished by using of a large burnisher with high force moving from the center of the restoration to the margins, this will produce denser amalgam at the margins of the cavity.
- Carving should begin immediately after condensation with suitable size carver. All carving should be done with the edge of the blade perpendicular to the margins as the instrument is moved parallel to the margins. Part of the edge of the carving blade should rest on the unprepared tooth surface adjacent to the preparation margin. Using this surface as a guide helps to produce a continuity of surface contour across the margins.
- Over-carving or deep occlusal grooves carving should not be done on the restoration, because these may thin the amalgam at the margins, invite chipping, and weaken the restoration.
- Under-carving leaves thin portions of amalgam (subject to fracture) on the unprepared tooth surface. Such margins give the appearance that the amalgam has expanded beyond the preparation.
- The mesial and distal fossae should be carved slightly deeper than the proximal marginal ridges.
- After end of carving, post carving burnishing is done by lightly rubbing the carved surface with a burnisher of suitable size and shape to improve smoothness and produce a satin (not shiny) appearance. Post carve burnishing may improve the marginal integrity of high-copper amalgams; it may also improve the smoothness of the restoration.
- After that the occlusion of the restoration must be evaluated, it's done by telling the patient to do light closing to check if there is any high spots in the restoration and this spot look more shiny ;also can be checked by articulating paper, any high spot should be removed before beginning of the initial setting of amalgam.
- Finally; the grooves are enhanced with conical amalgam burnisher and the restoration smoothed by small damp ball of cotton.
- In cervical cavity; the edge of carving instruments must rested on the external tooth surface to prevent over carving; under carving should be avoided as well.

Filling cavities using matrix band:

The matrix-bands are used in compound or complex cavities:

- 1- To have the desired contour of the restoration.
- 2- To substitute the lost wall of tooth cavity especially in class II (mesial or distal or both) also in complex cavities; and also keeps the amalgam in the needed place and contour during condensation.

Matrix bands: They are used for class II cavity fillings; its position must be 2 mm above the marginal ridge. They are available in many thickness; thin bands are widely used. The thicker bands leading to difficulty in establishing good contact point. The band are either precut or been cut from a ribbon or as a copper ring or band fig 3.

Matrix retainer: It's a mechanical device retained the band in its selected position. Retainers classified into:

- 1- Ivory No.1.: Used to surround tooth from one surface MESIAL or DISTAL, and with this retainer perforated bands are used fig 2.

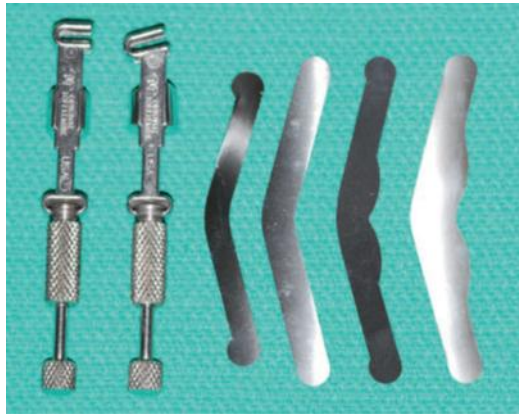

Fig 2: Ivory No.1 and its perforated bands

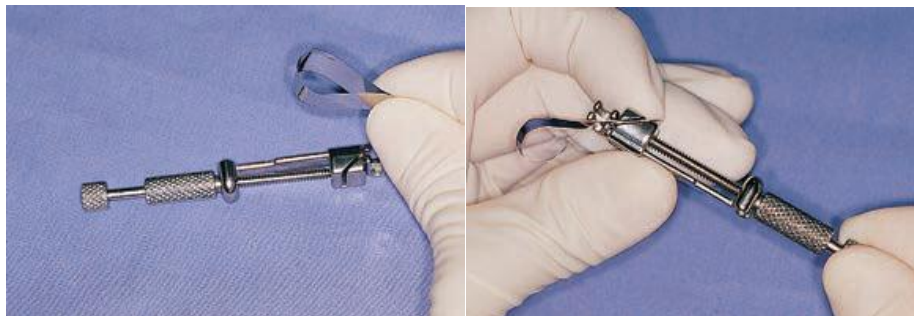
- 2- Ivory No.8 and ivory No.9 (tofflemire retainer): these retainers can be used in MOD cavities. The band surrounds the tooth and the retainer lie in muco-buccal fold. The contrangle-tofflemire can be placed at the lingual side. When there is one missing wall of the tooth circumferential retainer can be used. Attention must be given to have the proper contour of matrix band bucco-lingual and occluso-gingival direction, otherwise the restoration will has defects in its contour. Contouring occur by burnishing the band in the areas corresponding to the proximal surface or surfaces to be restored once the band is positioned around the tooth.

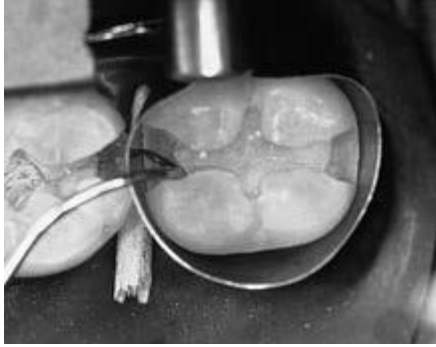
Burnishing means that the metal band has been deformed occluso-gingivally with a suitable burnisher to produce a rounded or convex surface that (when in place around the tooth) will produce a restoration that is symmetric in contour with the adjacent proximal surface. See fig (3).

Figure (3): Straight and contra-angled Universal (Tofflemire) retainers. Bands with varying occlusogingival measurements are available.



The band may be trimmed for the shallower gingival margin, permitting the matrix to extend farther gingivally for the deeper gingival margin on the other proximal surface.





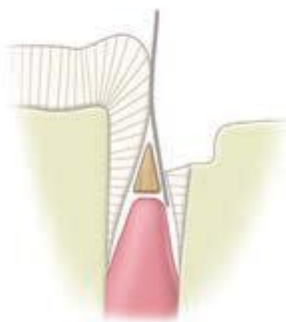
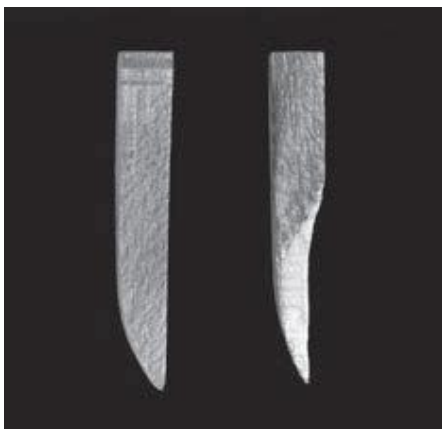Use of the explorer tip (with pressure) to ensure proper adaptation of the band to the gingival margin. In addition, the tip is pressed and dragged along the gingival margin in both directions to ensure removal of any friable enamel.

Wedge: It's a triangular or circular cross section wooden or plastic piece located interproximally to:

- 1- Hold the band tightly against the gingival margin of the cavity.
- 2- Prevent an over hanged filling.
- 3- Provide sufficient separation of teeth to compensate the thickness of band.

The wedge is placed in the gingival embrasure, from the lingual or facial embrasure (whichever is larger), slightly gingival to the gingival margin of the cavity, however the lingual embrasures are larger than the buccal in the posterior teeth. Wedge the band tightly against the tooth and margin, if the wedge is placed occlusal to the gingival margin, the band will be pressed into the preparation, creating an abnormal concavity in the proximal surface of the restoration. See fig 4

Figure (4) A- wedge B- correct wedge position.



Filling done without wedge cause:

1- No contact point with the adjacent tooth, and that leads to food impaction causing gingivitis and caries

2- Overhanging restoration.

□ A contoured matrix putted in place with wedge and with a probe check the adaptation of the band to the cavity gingival margin. After that relaxation of the band quarter or half turn to be sure that a good contact point is obtained. Condensation of amalgam must start at the box of the cavity until the cavity is over filled .At each stage of condensation excess mercury must be removed from the surface because if this excess left it may cause weakness of the restoration.

□ Carving of the filling: Means bringing the filling as near as could to the tooth shape; and that done by removing the excess material then the outer inclination of the marginal ridge is established by carver or probe while the matrix band is still in place.

□ We must not try to remove the band before the reduction of the marginal ridge to its approximate height, else fracture of that margin may occur, as well gross contouring of occlusal surface with large excavator must be done. And then the wedge and retainer removed, after that the band removed bucco-occlusally or lingo-occlusally. Checking of the gingival margin should begin immediately after removal of the band and that done by using a probe; then the carving of the restoration is completed.

Finishing and polishing: This can be done at least 24 hours later; and it is done for:

1- Well finished and polished restoration this will keep the surface smooth and clean so less tarnish and corrosion occur.

2- Rough surface may cause accumulation of food particles leading to secondary caries.

3- Polished surface gives better response to the surrounding soft tissues.

4- We can have more ideal carving and contouring.

5- A small feather edges of amalgam excess left beyond the margins may fractured under stress leaving rough surface and that can be removed during polishing.

For finishing and polishing we use the following:

- 1- Tapered stone bur.
- 2- Round or flamed finishing bur with deferent sizes.
- 3- Rubber cup and pumice with water.
- 4- Thin zinc-oxide with soft cup brush for final shine.

Conservative dentistry

LEC: 11

Dr. Alalaa

Complex Amalgam Restorations

Complex posterior amalgam restorations should be considered when large amounts of tooth structure are missing, when one or more cusps need capping, and when increased resistance and retention forms are needed fig 1.

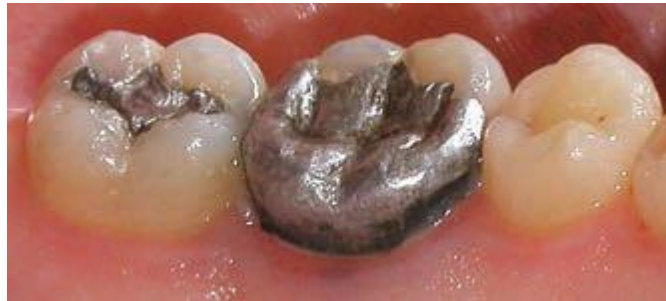

Fig1: Mesio-occluso-disto-facial-lingual (MODFL) complex amalgam

Indications:

- 1- Control restorations in teeth that have a questionable pulpal and/or periodontal prognosis.
- 2- Control restorations in teeth with acute and severe caries.
- 3- Foundations (abutment teeth for fixed prostheses).

Contraindications:

- 1- If the area to be restored is esthetically important for the patient.
- 2- If the tooth cannot be properly restored with a direct restoration because of anatomic and/or functional considerations.

Resistance and Retention Form:

- 1- In a tooth severely involved with caries or, any undermined enamel or weak tooth structure subject to fracture must be removed and restored.

2- When conventional retention features are not adequate because of insufficient remaining tooth structure, pins, slots, and amalgam bonding techniques may be used to enhance retention

3- The retention features needed depend on the amount of tooth structure remaining and the tooth being restored. As more tooth structure is lost, more auxiliary retention is required.

4- Pins, slots, and bonding also provide additional resistance form to the restoration.

5- Capping cusps: (fig 2)

a) When caries is extensive, reduction of one or more of the cusps for capping may be indicated (capping cusps).

b) When the facial-lingual extension of the occlusal preparation exceeds two third the distance between the facial and lingual cusp tips (inter-cuspal-distance), reduction of the cusp(s) for amalgam is usually required for the development of adequate resistance form.

c) The reduction should be 2mm as minimum depth on the occlusal surface of each cusp to be capped using the side of carbide fissure bur, to ensure that the final restoration has restored cusps with a minimal thickness of 2 mm of amalgam

d) The occlusal contour of the reduced cusp should be similar to the normal contour of the unreduced cusp. Any sharp internal corners of the tooth preparation formed should be rounded to reduce stress concentration in the amalgam and thus improve its resistance to fracture from occlusal forces.

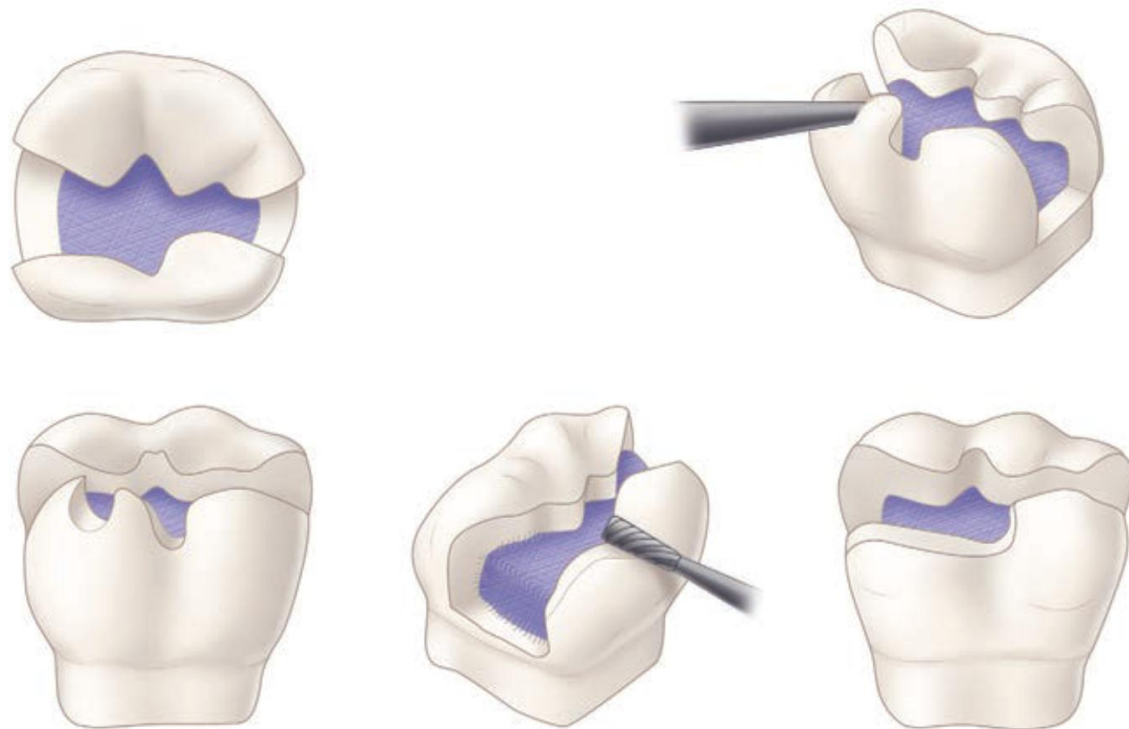


FIG. (2) Capping cusp with amalgam

* When possible, opposing vertical walls should be prepared to be converge occlusally, to enhance primary retention form. The pulpal and gingival walls should be relatively flat and perpendicular to the long axis of the tooth.

Secondary retention means:

Cusp reduction significantly diminishes retention form by decreasing the height of the vertical walls, so secondary retention means are required which may include:

- 1- Coves and locks:** Coves are prepared in a horizontal plane and locks are prepared in a vertical plane. These locks and coves should be prepared before preparing pinholes and inserting pins. (see fig.3 A&C)
- 2- Slots:** which may be prepared along the gingival floor, or in addition to, pinholes (as appear in fig.3 B). The slot should be prepared 0.5 mm pulpal to the dentino-enamel junction and at least 0.5 mm in depth.

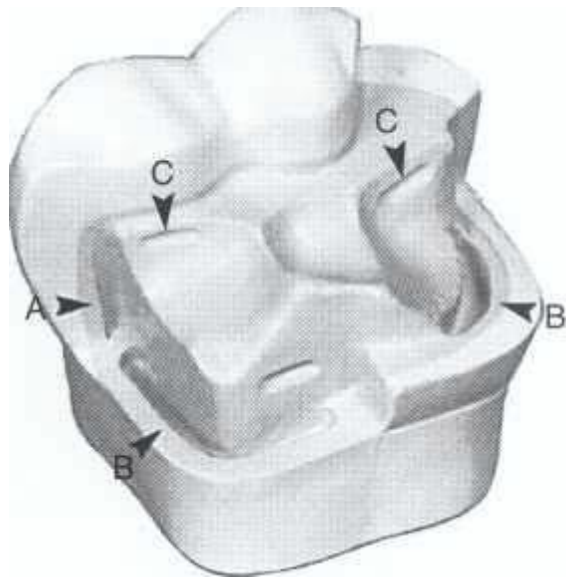


Fig. 3 Locks (A), slots (B), and coves (C).

3- Pins: Pins placed into prepared pinholes provide auxiliary resistance and retention forms.

PIN RETAINED AMALGAM RESTORATION:

It's any filling may needs one or more pins to provide adequate resistance and retention forms.



Fig 4: pin retained amalgam restoration

Advantages:

1- Conservative; means the pin is more conservative in tooth cutting than slot and crown preparation.

- 2- Time value: Pined amalgam needs only one visit; the cast may needs two visits.
- 3- Resistance and retention are better by using pins.
- 4- More economic than cast.

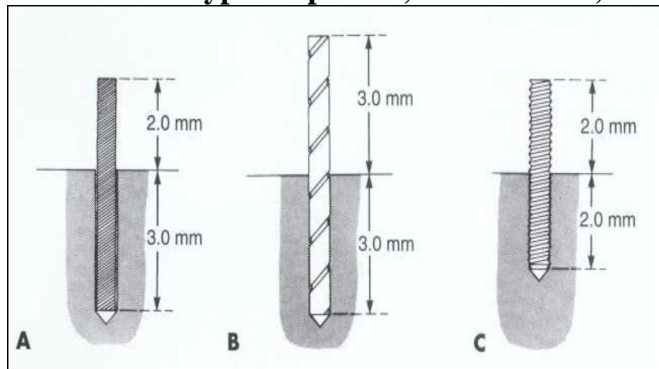
Disadvantages:

- 1- It's difficult to penetrate when there is little dentin left.
- 2- Stress induced into tooth structure.
- 3- Perforation may occur to the pulp or to the external tooth surface.
- 4- Requires at least 4 mm's of occlusal clearance.

Types of pins:

- 1. Self -threading pins:** The pin is retained by threads on pin surface through engaging the dentin when it's inserted. It is the most retentive type of pins and also it is the most widely used than the other types. However, vertical and horizontal stresses can be generated in the dentin when a self-threading pin is inserted causing craze lines in the dentin which are related to the size of the pin. The diameter of pin hole is 0.1 mm smaller than pin diameter .The elasticity of dentin allows the insertion of pin into a hole of smaller diameter. The depth of pin hole is about 1.5-2mm. (Fig 5, C)
- 2. Cemented pins:** Its threaded or serrated stainless steel pins cemented into pin holes 0.05mm larger than the diameter of the pin .The cement used may be any standard dental luting agent such as Zinc phosphate or polycarboxylate cement. The cemented pins produce less stresses in the dentin. The depth of pin hole should be 3 mm. (Fig 5, A)
- 3. Friction-locked pin:** The diameter of the prepared pin hole is 0.025 mm less than diameter of the pin ; the pin is tapped in place retained by resiliency of dentin; Its 2-3 time more retentive than cemented pins; its inserted by specially designed instrument. (Fig5, B)

FIG. 5 Three types of pins. A, Cemented. B, Friction-locked. C, Self-threading.



Factors Affecting the Retention of Pin in Dentin and Amalgam:

1- Type of pin: The self-threading pin is the most retentive, the friction locked pin is intermediate, and the cemented pin is the least retentive.

2- Surface characteristics: The number and depth of the elevations (serrations or threads) on the pin influence retention of the pin in the amalgam restoration. The shape of the self-threading pin gives it the greatest retention value.

3- Orientation, number, and diameter: Retention provided by placing the pins in a non parallel manner; also excessive bending of pins to improve retention in amalgam is not desirable, because bending interfere with the adequate condensation of amalgam around the pin, also bending may weakens the pins. Pins should be bent only to provide an adequate amount of amalgam (approximately 1 mm) between the pin and the external surface of the finished restoration.

4- Extension of pin into amalgam and dentin:

The extension of pin into dentin and amalgam greater than 2 mm is unnecessary for pin retention and is contraindicated to preserve the strength of the dentin and the amalgam. (Fig.5)

Pin Placement Factors and Techniques:

1- Pin size: Two determining factors for selecting the appropriate pin size are the amount of dentin available to safely receive the pin, and the amount of retention desired. In the Thread Mate System (TMS) four sizes of pins are available (from the largest size to smaller size: Regular,

Minim, Minikin and Minuta). The Minikin pins usually the pins of choice for severely involved posterior teeth to reduce the risk of dentin crazing, pulpal penetration, and potential perforation. The Minim pins usually are used as a backup in cases where the pinhole for the Minikin was over prepared. The Regular or largest diameter pin is rarely used because a significant amount of stress in the tooth (dentin and enamel) may be created during its insertion. The Minuta pin is usually too small to provide adequate retention in posterior teeth so this pin can be benefit for providing retention for anterior teeth restorations.

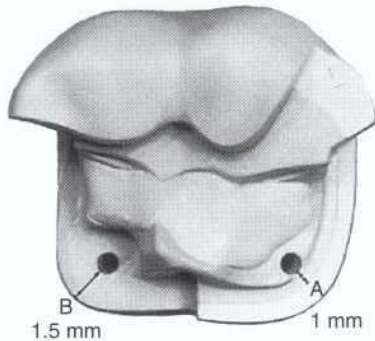
2- Number of pins:

- a- As a rule one pin per cusp or marginal ridge.
- b- The fewest pins possible should be used to achieve the desired retention for a given restoration.
- c- If more than one pin is used, 3-5 mm space between pins is required.
- d- As the number of pins increases the retention of the restoration increases, while an excessive number of pins can fracture the tooth and significantly weaken the amalgam restoration.

3- Location:

- a- Occlusal clearance should be sufficient to provide 2 mm of amalgam over the pin.
- b- Pinholes should be located halfway between the pulp and the DEJ or external surface of the tooth root. The pinhole should be positioned no closer than 0.5 to 1 mm to the DEJ or no closer than 1 to 1.5 mm to the external surface of the tooth. (See Fig. 6)
- c- The pinhole should be parallel to the adjacent external surface of the tooth.
- d- A minimum space of 0.5 mm is required around the circumference of the pin for adequate condensation of amalgam.
- e- Pinholes should be prepared on a flat surface that is perpendicular to the proposed direction of the pinhole.

Fig. 6 Pinhole position. A, Position relative to DEJ. B, Position relative to external tooth surface.



f- Several posterior teeth have anatomic features that may preclude safe pinhole placement. External perforation may result from pinhole placement on these areas:

- i- Over the prominent mesial concavity of the maxillary first premolar.
- ii- Over bifurcation areas of the lower molars and trifurcation areas of the upper molars.
- iii- The distal aspect of mandibular molars and the lingual aspect of maxillary molars because of root angulations of these teeth just apical to CEJ.
- iv- Teeth that are rotated in the arch.
- v- Abnormal tilted teeth. (See Fig 8)

Pinhole preparation:

- 1-** The drill is a twist drill made of aluminum shank, which acts as a heat absorber, and is color coded so that it can be easily matched with the appropriate pin size. A drill with limited depth of 2mm should be used to prepare the hole.
- 2-** When the pinhole locations have been determined, a No. $\frac{1}{4}$ round bur is first used to prepare a hole. The purpose of this hole is to permit more accurate placement of the twist drill and to prevent the drill from "crawling" once it has begun to rotate.
- 3-** Put the hand-piece on clockwise rotation at very low speed (300 to 500 rpm).
- 4-** Prepare the hole parallel to nearest external tooth surface. Align twist drill with external tooth surface. Drill the hole in one continuous motion

until the depth is reached then pulls the drill without stopping the rotation to prevent breaking of the drill while it's in the hole. (See fig. 7)

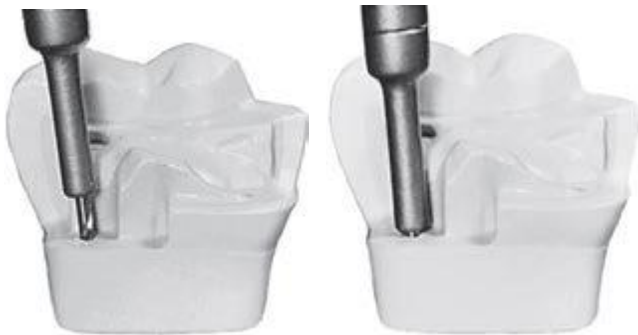

FIG (7): A and B, with twist drill at correct angulation, prepare pinhole in one thrust until depth-limiting portion of drill is reached.

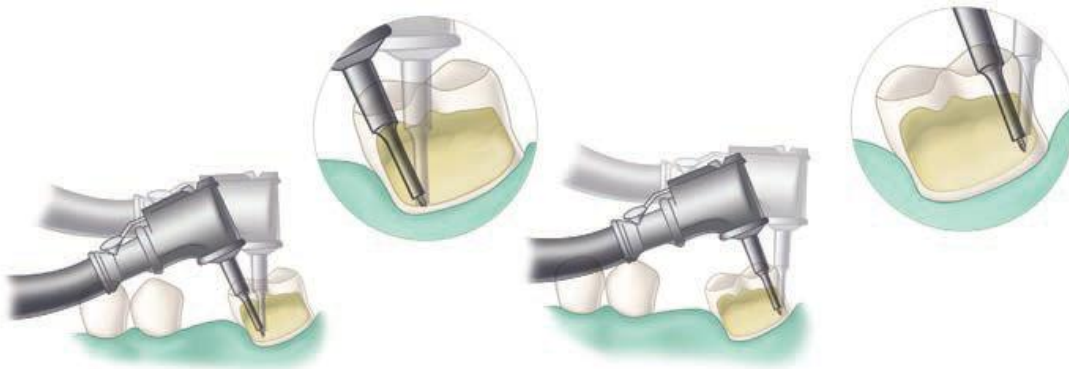



Fig. (8) Care must be exercised when preparing pinholes in mesially tilted molars to prevent external perforation on mesial surface (A) and pulpal penetration on the distal surface (B). Broken line is incorrect angulation of twist drill.


Pin design:

For each of the four sizes of pins, several designs are available: standard, self-shearing, two-in one, Link Series, and Link Plus (Fig. 9). The Link Series and Link Plus pins are recommended. TMS pins are available in titanium or stainless steel plated with gold. When the pin reaches the bottom of the hole, the top portion of the pin shears off, leaving a length of pin extending from the dentin.

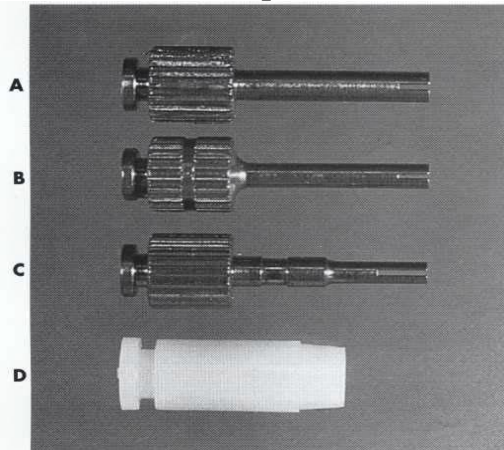
FIG (9) Five designs of TMS pins. A, Standard. B, Self-shearing. C, Two-in-one. D, Link Series. E, Link Plus.



Hand-piece chucks for the Thread Mate System (TMS) regular self-shearing and Minikin pins (A) and TMS Minuta pins (B).



Hand wrenches for TMS pins. (A) TMS regular self-shearing and A, Regular and Minikin. B, Minim. Minikin pins, and (B) TMS Minuta pins C, Minuta. D, Link Series and Link Plus.



Notes:

When pin is placed in the pin hole, the pin should not exceed 2 mm in length in the amalgam, if the length is more than that, the excess should be cut. It is desired to have at least 2 mm of thickness of the amalgam occlusal to the end of the pin to prevent weakening of the restoration.

Possible Problems with Pins:

1- Failure of pin-retained restorations: The failure of pin retained restorations might occur at any of five different locations (Fig. 10). Failure can occur:

- a- Within the restoration (restoration fracture).
- b- At the interface between the pin and the restorative material (pin-restoration separation).
- c- Within the pin (pin fracture).
- d- At the interface between the pin and the dentin (pin-dentin separation).
- e- Within the dentin (dentin fracture).

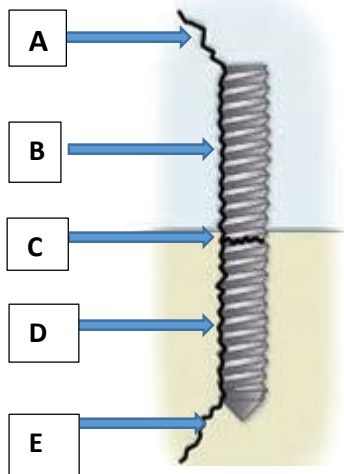


Fig (10) Five possible locations of failure of pin-retained restorations.

- a, Fracture of restorative material;
- b, Separation of pin from restorative material;
- c, Fracture of pin;
- d, Separation of pin from dentin;
- e, Fracture of dentin.

2- Broken drills and broken pins: A twist drill will break if it is stressed laterally or allowed to stop rotating before being removed from the pinhole. Pins also may break during bending, if care is not exercised. The treatment for both broken drills and broken pins is to choose an alternate location, at least 1.5 mm away from the broken item, and prepare another pinhole.

3- Loose pins: The pin should be removed from the tooth and the pinhole re-prepared with the next largest size drill, and the appropriate pin inserted. Preparing another pinhole of the same size 1.5 mm from the original pinhole also is acceptable.

4- Penetration into the pulp and perforation of the external tooth surface:

It is obvious if there is hemorrhage in the pinhole following removal of the drill, also the operator can feel when a penetration or perforation has occurred by an abrupt loss of resistance of the drill to hand pressure. In an asymptomatic tooth, a pulpal penetration is treated as any other small mechanical exposure by control the hemorrhage, then place a calcium hydroxide liner over the opening of the pinhole, and prepare another hole 1.5 to 2 mm away.

Perforation of the external surface of the tooth can occur occlusal or apical to the gingival attachment. When the perforations occur occlusal to the gingival attachment, the pin can be cut off flush with the tooth surface and no further treatment. Or the pin can be removed, if still present, and the external aspect of the pinhole enlarged slightly and restored with amalgam. If the perforations occur apical to the attachment, reflect the tissue surgically, remove the necessary bone, enlarge the pinhole slightly, and restore with amalgam.

FAILURE OF AMALGAM RESTORATION:

The failure of amalgam restoration may include:

1- Secondary caries: Class I and Class II amalgam restorations, caries around margins was the predominant cause of restoration failure. Also

amalgam restoration in high caries incidence individuals may fail as a result of secondary caries.

2- Isthmus fractures or marginal ridge fracture of restoration: the marginal ridge fracture in CI II restoration may be caused by:

- a- Axio-pulpal line angle not rounded in class II cavity.
- b- Marginal ridge left too high.
- c- Improper removal of the matrix.

3- Tooth fractures: Excessive tooth cutting or excessive caries, may resulted in large cavity with thin walls that cannot withstand occlusal forces, and will cause tooth fracture. Also sharp internal line angles may cause stress concentration of the restoration on the tooth walls and lead to fracture.

4- Improper marginal adaptation and marginal fractures:

Marginal deterioration of amalgam restorations are mainly caused by the following factors:

- a- Improper marginal preparation.
- b- Improper carving and finishing.
- c- Excess mercury.
- d- Use of low copper amalgam.
- e- Amalgam expansion.

5- Other reasons: these includes faults in the clinical procedures during amalgam placement such as: gingival overhang of the restoration (due to not or improper using of the wedge), improper contact area with the adjacent tooth which will lead to periodontal problems.

It is introduced commercially in 1962 by Bowen of the National Bureau of Standards most popular tooth colour material consist of a continuous polymeric or resin matrix in which an inorganic fillers is dispersed.

Indications:

1. Classes I, II, III, IV, V and VI restorations
2. Foundations or core buildups
3. Fissure sealants and conservative composite restorations (preventive resin restorations)
4. Esthetic enhancement procedures
 - Partial veneers
 - Full veneers
 - Tooth contour modifications
 - Diasthema closures
5. Cements (for indirect restorations)
6. Temporary restorations

Contraindications:

1. An operating area that cannot be adequately isolated.
2. Class V restorations that are not aesthetically critical.
3. Restorations that extend into the root surface (may exhibit gap formation).

Advantages:

1. Aesthetics
2. conservative of tooth structure removal (less extension; uniform depth not necessary; mechanical retention usually not necessary)
3. less complex when preparing the tooth

4. low thermal conductivity
5. bonded to tooth structure resulting in good retention, low micro leakage, minimal interfacial staining, and increased strength of remaining tooth structure
6. Repairable

Disadvantages

1. may result to gap formation, usually occurring on root surfaces as a result of the forces of polymerization shrinkage of the composite material
2. restoration is more difficult, time-consuming, costly (compared to amalgam restorations)
3. Are more technique sensitive because the operating site must be appropriately isolated and the placement of etchant, primer, and adhesive on the tooth structure (enamel and dentin) is very demanding of proper technique
4. May exhibit greater occlusal wear in areas of high occlusal stress or when all of the tooth's occlusal contacts are on the composite material
5. Have a higher linear coefficient of thermal expansion, resulting in potential marginal percolation if an inadequate bonding technique is utilized

Composition

A. Organic Resin – forms the matrix

-dimethacrylate monomer (BIS-GMA)

B. Inorganic filler

- inhibits deformation of the matrix

- reduce the coefficient of thermal expansion of the resin matrix

e.g. fused silica, crystalline quartz, lithium aluminum silicate, borosilicate glass

- better mechanical properties, such as compressive strength;

- greater aesthetics;

- confers radio-opacity

C. Coupling Agent

- unite the resin with the filler
- stress absorber of the filler and resin

D. Initiator System – activate the setting mechanism

E. Stabilizers

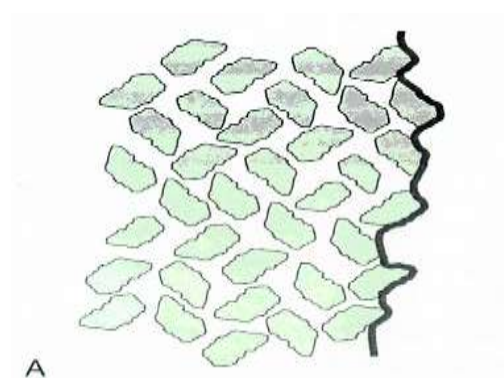
F. Pigments

Classification

1. Conventional
2. Microfilled
3. Hybrid -Flowable - Packable
4. Nano-composite (nanofilled) - Completely nanofilled - Nanohybrids
5. Reinforced

Conventional Composites

1. contains 75-80% inorganic filler by weight
2. average particle size $8\mu\text{m}$
3. large size particle and extremely hard filler
4. rough surface structure, strontium and barium glass (radiopaque)



Microfilled Composites

1. introduced in the late 1970
2. polishable
3. smooth lustrous surface similar to tooth enamel

4. particle size is 0.01 – 0.04 μ m
5. contains 35-60% inorganic filler by weight
6. some of physical and mechanical properties are inferior; wear resistant
7. low modulus of elasticity (allow restoration to flex)
8. high resin content results in an increased coefficient of thermal expansion and lower strength




Use of Microfilled Composites

- used for low stress restorations, buccal and lingual surfaces of class III and class V

Hybrid Composites

1. combines the properties of conventional and microfilled
2. contains 75-85% inorganic filler by weight
3. particle size is 0.4 – 1 μ m
4. physical properties is superior to conventional
5. predominant direct aesthetic resin
6. have universal clinical applicability



Use of Hybrid Composites

- used in moderate stress restorations where strength and wear resistance are more important than surface luster; Class I, class II, class IV

Flowable composites

1. flows into cavity due to lower viscosity
2. have lower filler content

3. inferior physical properties (lower wear resistance, lower strength)
4. used in small class I, pit and fissure sealant, marginal repair materials, as the first increment placed as a liner under hybrid or packable composites
5. easy to use
6. good wet ability
7. favourable handling properties are popular features
8. clinical indications for their use are limited.

Packable (Condensable) composites

1. more viscous, “thicker, stiffer feel”
2. have filler particle feature that prevents sliding of the filler particle by one another
3. easier restoration of proximal contact
4. similar to the handling of amalgam

Nanofill composites

1. Contain filler particles that are extremely small (0.005-001 microm.)
2. Because of these small particles a high filler levels can be generated in the restorative material, resulting in good physical properties and esthetics
3. Nanofills highly polishable
4. These materials are likely to become a popular composite restorative material choice

Completely nanofilled resins

Contain nano-meter sized particles throughout the resin particles

Nanohybrids resins

Consist of large partials surrounded by nano-meter sized particles

Reinforced composites

It consists of a combination of a resin matrix, randomly orientated E-glass fiber and inorganic particulate fillers.

Used as base filling material in high stress bearing areas especially in large cavities of vital and non- vital posterior teeth

Classification according to the method of activation:

1. Chemically-activated composites:

Also they are called self -curing composite resins. Most commonly available as two-paste system composed of a catalyst and base materials. When these two components are property mixed, the polymerization process is chemically activated. The rate of set is uniform through the bulk of the material causing a gradual increase in viscosity at room temperature. Hence the material have a limited working time, making the technique time sensitive with the increased possibility of air bubble incorporation during mixing of the two pastes and thus affecting the composite physical and mechanical properties .

2. Light-activated: composites:

Light activated materials afford a number of advantages over chemically activated ones. The light curable materials are single components, and require no mixing, and so have reduced porosity, and better resistance to wear and abrasion. The working time is virtually that chosen by the clinicians, and the material hardens rapidly when exposed to light. The components of light -activated composites are contained in single paste system. The mixture is supplied in various shades in disposable syringes. These syringes are made of opaque plastic to protect the material from exposure to light.

3. Dual cured composites:

Combine self curing and light curing materials .The self curing rate is slow and is designed to cure only those portions that are not adequately light cured Specially in the interproximal areas where the access is limited and require special approaches to guarantee adequate light curing energy

Lec 13 Light -activation sources:

Dr. Alalaa

1. Ultraviolet light source:

The introduction of photopolymerization to dentistry began in the late 1960s. Initially, ultraviolet cured pit and fissure sealant were put into clinical practice, UV radiation cause possible eye problems that might develop in office personnel and the possibility of selectively altering the oral flora of the patient's mouth through exposure to ionizing radiation.

2. Visible light sources:

A- Quartz-Tungsten-halogen (QTH) light source:

A modified light source delivery was introduced in the form of the handheld dental curing light.

Visible radiation passed through the infrared filter, is then further filtered by a band pass filter, providing energy restricted to a narrow visible light region where the absorbance of the photoinitiator is maximum, so that, only blue light is emitted. However, only the wavelengths around 470 nm are strongly absorbed by the Composite.

B- Argon laser lights

When laser technology provided sources that emitted high-intensity light within the energy band required by the photoinitiator in light-activated dental materials, the dental industry developed this type of curing source for the practitioner. The argon-ion laser provides high output energy at 488 nm for rapid polymerization of commercially available dental restorative

C. Short-Arc Xenon Sources (Plasma-Arc Curing lights (PAC)):

In the mid 1990s, Xenon arc light units were introduced in restorative dentistry as alternative for rapid light curing. Manufacturers claimed that these sources can effectively reduce clinical exposure

duration to only 1 to 10-seconds or some manufacturers claimed that composites could be adequately polymerized in less than 1 second.

D. Blue light- emitting diode curing units (LED) s

The blue LED has become available in output wavelengths that fell within the spectral absorbance of a common dental photoinitiator (CQ). The intensity of these devices has increased at a rapid rate, and now commercial devices are available for the photopolymerization of dental composites. Instead of the hot filaments used in halogen bulbs, LED, use junction of doped semiconductors for generation light.

Polymerization:

Resin composite restoratives solidify by means of the chemical process termed polymerization. The polymerization of the resin matrix produces a gelation in which the restorative material is transformed from a viscous-plastic into a rigid-elastic phase. During the early stages of polymerization, monomers are mainly converted into polymeric chains.

After a certain degree of conversion has been attained, the predominant reaction is the cross-linking of the polymeric chains, resulting in a strong polymeric network.

Factors affecting polymerization shrinkage stress:

1-Factors related to the cavity design:

Stress developed during curing can be minimized by consideration of the ratio between the bonded and unbonded surface area (c- factor). When this ratio increases, as in Class I and Class V situations, increase the shrinkage stress loading on the tooth- resin interface leading to de bonding.

2-Factors related to the placement technique:

The second factor that might reduce polymerization shrinkage is to insert resin composites in increments to reduce the volume of the resin that is shrinking during polymerization.

3-Factors related to the composite formulation:

Nonbonded microfiller particles have been found to produce significant decreases in polymerization stress by acting as stress-relieving sites within the composite.

Acid Etching:

- A physical process that creates a microscopically rough enamel surface (enamel tags)
- first successful technique developed to bond dental materials to tooth structure
- acid used is 37% ortho-phosphoric acid
- sometimes referred to as conditioner

Smear Layer: When a rotary or handheld instrument is used on dentin it creates a special surface texture called a smear or smear layer that closes off the dentinal tubules. This layer is lightly adhered to the dentin surface and contains tooth cuttings, saliva, bacteria, and other surface debris

Enamel Etching

Enamel consists of organic and inorganic components. Application of 37% phosphoric acid removes about 10 microns of enamel to expose prisms of enamel rods and create the classic honeycomb effect. Acid also increases surface energy for better wetting of the enamel. Resins flow into micromechanical retentive areas. Resin tags fill microscopic holes to provide retention. Retention is about 30 MPa.

Acid etching is done for a minimum of 15 to 30 seconds. Thorough rinsing for 10 seconds removes acid and dissolved calcium phosphates.

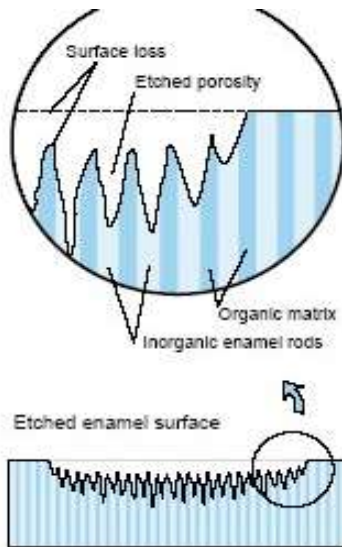


Figure 8-3. Schematic diagram depicting how acid etching produces microporosities in enamel.

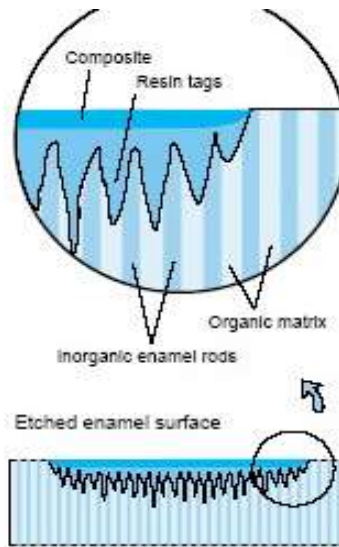


Figure 8-4. Schematic diagram depicting how resin tags penetrate the microporosities produced by acid etching of enamel.

- Over-etching results to formation of crystals (precipitates) that inhibits bonding
- Built-in quality control check – if properly etched it appears frosty or chalky white.

Dentin Etching

- 37% ortho-phosphoric acid
- removes the smear layer from the surface of the of the dentin as well as the plugs of material forces into dentinal tubules during cavity preparation.
- decalcifies a layer of dentin several microns thick. Time: 10-15 seconds

If the etched tooth surfaces are contaminated with saliva or blood, they need to be reetched. Such a reetching procedure requires only 5 seconds.

Adhesion to Dentin

Conditioning or Etchant (E):- dentin etching time 15 sec only

- Removes the smear layer.
- Exposes the intertubular and peritubular collagen.
- Opens the tubules.
- Decreases the surface free energy.

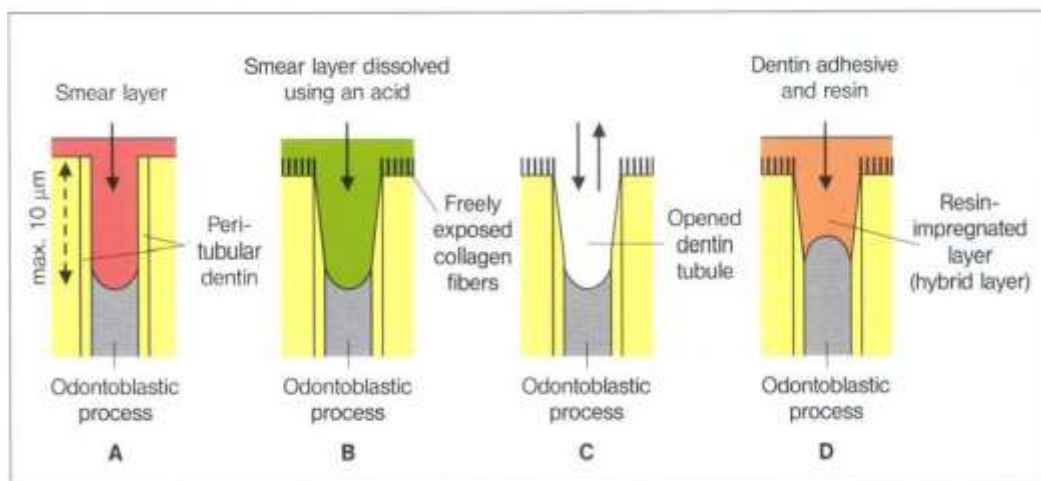
Primer (P):-

- Includes bifunctional molecules hydrophilic and hydrophobic).
- Envelops the external surface of collagen fibrils.
- Re-establishes surface free energy to levels compatible with more hydrophobic restorative materials

Bonding Agent (B): (Adhesive resin)

- Includes monomers that are mostly hydrophobic such as Bis-GMA
- Copolymerize with the primer molecules penetrates and polymerizes into interfibrillar spaces to serve as a structural backbone to hybrid layer.

Adhesion to Dentin protects the pulp, because after removal of the smear layer with a mild acid (conditioner) the opened dentin wound was sealed with a hydrophilic resin, for example, HEMA (primer) and a bonding agent (adhesive). During this treatment a dentin surface impregnated with resin (hybrid layer) is formed that guarantees an optimal dentin wound closure which is acid resistant and prevents bacteria penetrating.



Effect of the total etch technique on the opening of the dentin canals

A- Prepared cavity

B -The smear layer is dissolved through treatment with phosphoric acid

C- The acid and the dissolved smear layer are washed away using a water-air spray

D- Forming the hybrid layer with a dentin adhesive

Current strategies for Adhesion of Resin to Dentin:

I-Total etch adhesive

A- Three step total etch adhesive:

Etchant (E) + Primer (P) + Bonding Agent (B)

B- One-bottle total –etch (two step total-etch adhesive):

Etchant (E) +Primer and Bonding agent (PB)

II-Self-etch adhesive:

A- Two –bottle self-etch:

Etchant and Primer (EP) + Bonding (B)

B- All-in-one self-etch (EPB) we call it single application:

-it demineralises and penetrates dentin simultaneously leaving a precipitate on the hybrid layer.

- Forms a thin layer of adhesive.
- a multi-coat approach is recommended.

Adhesive strategies – principles:

- 1- Acid etch will remove smear layer with collagen fibers upright, tubules open, primer and adhesive penetrate.
- 2- Leave smear intact, tubules plugged, partially demineralize smear layer with self- etching primer and replaced with resin filler in to tubular dentin.

Since their introduction in 1955, dental bonding agents have evolved from no-etch to total-etch (fourth- and fifth-generation) to the more recent, self-etch systems (sixth- and seventh-generation). The newest adhesive system, seventh-generation, combines the acid, primer, and bond in one bottle, which requires a single step with no mixing or etching.

Thirty-six primary anterior teeth were randomly divided into 3 groups of 5th generation (Single Bond 2), 6th generation (Clearfil SE) and 7th generation (Single Bond Universal) bonding agents.

Seventh-generation bonding agents have water as a solvent

Seventh-generation bonding agents offer good bond strengths to tooth structure and less technique sensitivity than etch-and-rinse (total-etch) and sixth-generation bonding agents. They may be excellent choices for bonding direct and indirect resin and all-ceramic posterior restorations.

6th-generation bonding agents are self-etching, which means that they do not need phosphoric acid to demineralize tooth structure. They contain a self-etching primer that demineralizes and primes the tooth structure simultaneously. They also utilize a hydrophobic adhesive that bonds more readily to composites.

fifth generation bonding agents primer and adhesives are in same bottle.

4th generation 3-step system

5th generation 2-step system

Third generation attempted to deal with smear layer and dentinal fluid

The **third generation** bonding systems introduced a very important change: the acid etching of the dentin in an effort to modify or partially remove the smear layer

Lec 14 CLASS V RESTORATIONS CLINICAL TECHNIQUE FOR DIRECT CLASS III, CLASS IV AND

Dr. Alalaa

CAVITY PREPARATION FOR COMPOSITE RESTORATIONS

Three designs of tooth preparations for composite restorations, and sometimes they are used in combination. The designs include:

- (1) Conventional (2) Beveled conventional (3) Modified

Class III Tooth Preparation:

There is a choice between facial or lingual entry into the tooth

Indications for Lingual Approach

- 1- To conserve facial enamel for enhanced esthetics.
- 2- Carious lesion is positioned lingually.
- 3- Lesion is accessible from the lingual. Advantages:-

- 1- Color matching of the composite is not as critical.
- 2- Discoloration or deterioration of the restoration is less visible.

Indications for Facial Approach

- 1- The carious lesion is positioned facially
- 2- Teeth are irregularly aligned, making lingual access undesirable.
- 3- Extensive caries extent into the facial surface.
- 4- Faulty restoration that was originally placed at the facial.

Conventional Class III

Indicated for restorations involving the root surface

1. Using a No. ½, 1, 2 round bur prepare the outline form on the root surface
2. Extend the preparation into sound walls
3. Extend pulpally 0.75mm in depth
4. The gingival/cervical and incisal wall is perpendicular to the root surface (box like design)
5. A continuous groove retention can be prepared 0.25 mm (½ of diameter of bur) into dentin of the gingival and incisal walls with a ¼ round bur.
6. The groove is placed at the junction of the axial and the external walls.
7. Clean preparation and inspect the final preparation.

Bevelled Conventional Class III

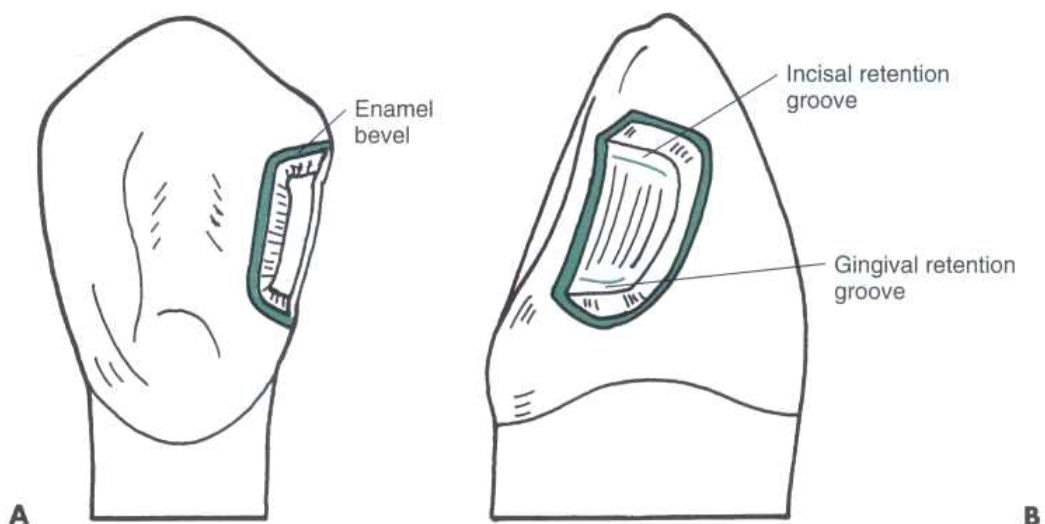
- Indicated for replacing an existing defective restoration in the crown portion of the tooth
- When restoring a large carious lesion for which the need for increased retention and/or resistance form is anticipated.

Lingual Access

1. Use a round bur No. 1/2, 1, 2 depending on the size of the caries to enlarge the opening sufficiently to allow for caries removal.
2. Extend external walls to sound tooth structure using a straight bur
3. Extend the gingival and incisal walls up to extent of caries or location of old restoration.

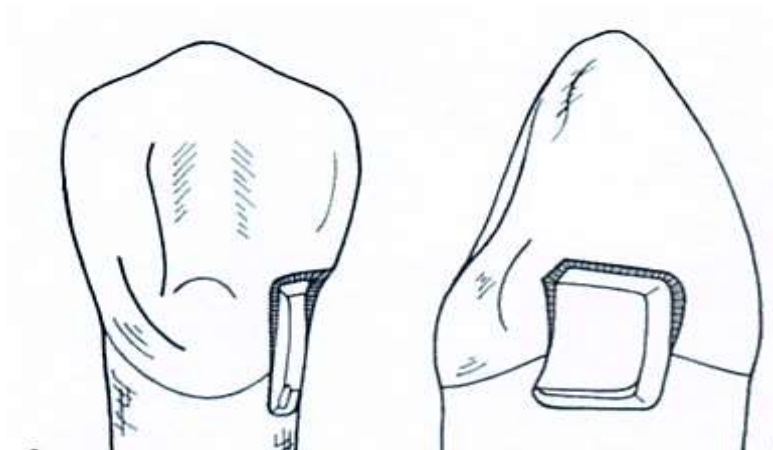
Unless necessary, DO NOT:

- include the proximal contact.
 - extend into the facial surface.
 - extend subgingivally
4. Create an initial axial wall depth of 0.2mm into the dentin/DEJ (approximately 0.75 – 1.25mm in depth)
 5. Axial wall is convex, following the external contour of the tooth.
 6. Remove all remaining infected dentin, using a round bur or small spoon excavator.
 7. Remove friable enamel at the margins.
 8. If necessary, prepare retention (grooves or coves)
 - prepare it along the gingivoxial line angle, and sometimes at the incisioaxial line angle 0.25 mm with a ¼ round bur.



9. Place cavosurface bevel or flare at the enamel except at the gingival margin area.

10. Use a flame shape or round bur resulting in a 45 degrees angle to the external tooth surface.
11. Bevel width should be 0.25 to 0.5mm.
12. Clean the preparation of any debris and inspect final preparation.

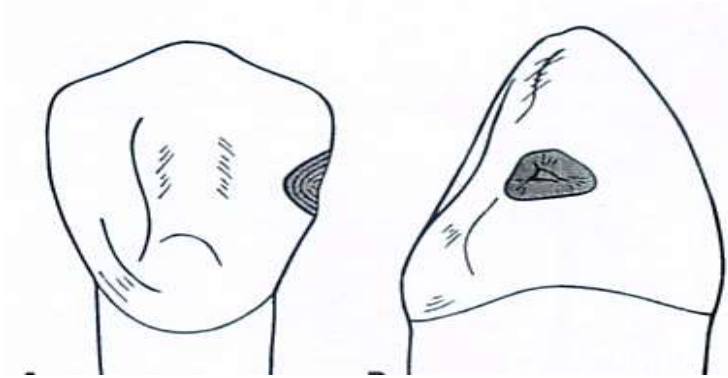


Facial Access

- same stages and steps are followed
- procedure is simplified because of easy access

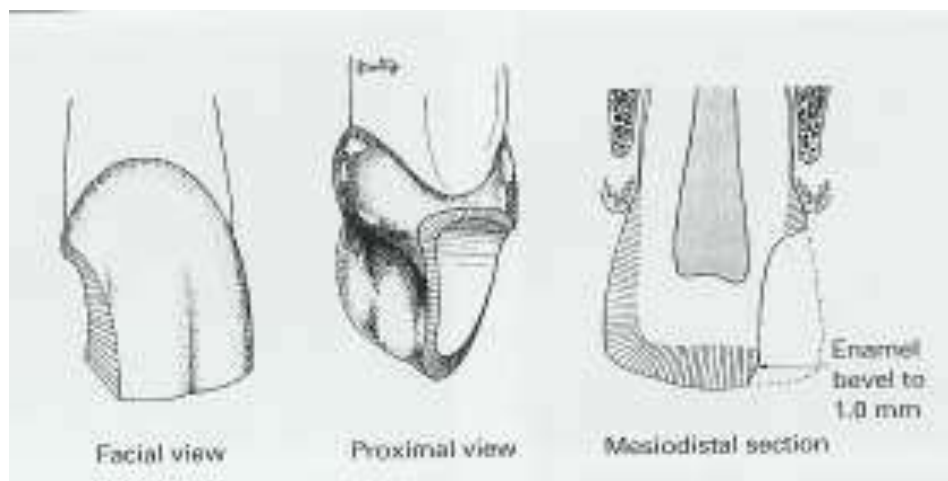
Modified Class III

- most used type of cavity preparation.
 - indicated for small and moderate lesions or faults.
 - designed to be as conservative as possible.
 - preparation walls have no specific shapes or forms.
 - preparation design appears to be scooped or concave
1. Use a 1/2, 1, 2 round bur, point of entry is within the incisogingival dimension of the lesion, perpendicular to the enamel surface.
 2. Remove all remaining caries or defect.



3. No attempt is made to create a uniform axial wall.
4. Place cavosurface bevel or flare at the enamel except at the gingival margin area.
5. Use a flame shape or round bur resulting in a 45 degrees angle to the external tooth surface.
6. Bevel width should be 0.25 to 0.5mm.
7. Clean the preparation of any debris and inspect final preparation.

Class IV Tooth Preparation



- preoperative assessment of occlusion is very important (placement of margin in noncontact areas)

- shade selection is more difficult
- preparation is similar to Class III except that the preparation for class IV is extended to the incisal angles

For fracture: If no caries or pulpal involvement a bevel is the only preparation necessary 1.0-2 mm enamel bevel should be placed around the periphery of the cavity

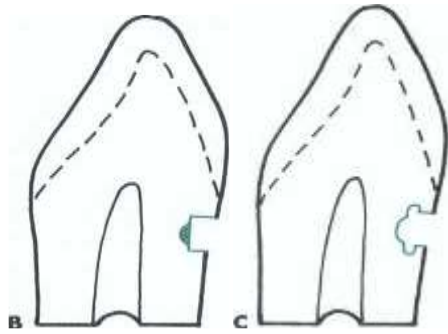
Use of Pins:

* Retentive pins are not needed because the adhesive technique provides sufficient retention for the restoration

Class V Tooth Preparation

Conventional

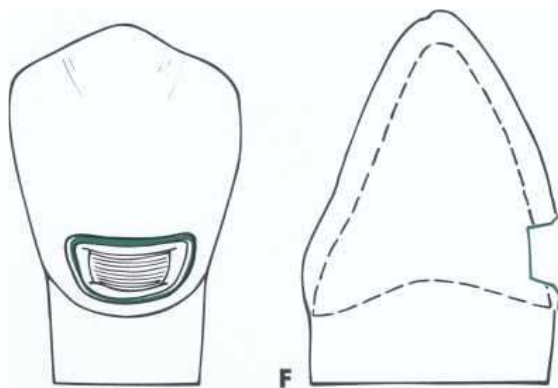
- the feature of the preparation include a 90 degree cavosurface angle, uniform depth of the axial line angle, and sometimes, groove retention form.
 - conventional design is indicated only for portion of the lesion extended onto the root surface
1. Use a tapered fissure (No. 700, 701, or 271) or No.1 or 2 round bur.
 2. Make entry at 45 degrees angle to tooth surface, this should result to a 90 degree cavosurface.
 3. Axial depth is 0.75 mm to strength of preparation wall, strength of composite and placement of retention groove
 4. Axial should follow contour of the tooth.
 5. Extent of outline form is dictated by the carious lesion extent.
 6. Remove remaining carious lesion
 7. Prepare retention groove (similar to Class III preparation)
 8. Clean preparation



Bevelled Conventional Class V

- Indications

1. replacement of defective class V restorations
2. large carious lesion
 - exhibits 90 degrees of cavosurface
 - axial wall depth is uniform (0.2mm or 0.5 when retention groove is to placed)

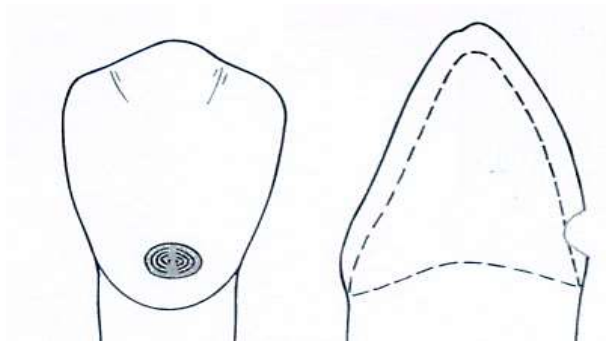


- groove is not indicated when periphery of tooth preparation is located in enamel.
- remove all infected dentin
- clean preparation

Modified Class V

- indicated for small and moderate lesion and lesion entirely in the enamel
- no effort to prepare a butt-joint

- no retention groove
- lesion is scooped out
- preparation has divergent wall
- axial wall does not have uniform depth
- prepare tooth with round or elliptical instrument
- preparation is extended initially no deeper than 0.2 mm
- no effort is made to prepare a 90 degree cavosurface margins.
- infected enamel is removed with a round bur or excavator.



Restorative Technique

1. Determine shade of tooth

Shade Selection:

After caries removal and cavity preparation shade selection was done using shade guide

Restorative Technique

1. Determine shade of tooth
2. Clean the tooth preparation using slurry of pumice, polishing cup.

3. Isolate the tooth, preferably with a rubber dam or cotton rolls, to keep the prepared teeth from saliva, blood, debris and other fluids..
4. Protect adjacent unprepared tooth from the acid etchant with a polyester strip apply the wedge.
5. Apply the gel etchant 0.5 beyond the prepared margins onto the adjacent unprepared tooth.
6. Etchant is left undisturbed for 15 seconds.
7. The area is washed to remove the etchant.
8. Dry the tooth structure
9. Bonding system is applied on all tooth structure that has been etched with a microbrush or other suitable applicators
- 10-Application of Bonding Agent: Application of the bonding agent and then cured for 10 seconds.
11. Incrementally place composite material and cure.
12. **Curing of the Composite:** The material is cured using the light curing machine for 20 seconds for every increment of composite that was placed.
13. **Finishing and Polishing:** The use of polishers with enhancers and polishing paste were done after the trimming of the excess composites.

Fluoride – Releasing Materials

Fluoride exists only in combination with other elements as a fluoride compound. It is present in the body in bone and teeth. The fluoride's effect is to serve as an aid for both the mineralization of developing tooth enamel prior to tooth eruption and for remineralization of surface enamel. The combination of these fluoride effects greatly reduce occurrence of dental caries. Fluoride is incorporated in tooth structure when small amounts are swallowed daily while the teeth are forming. Fluoride becomes concentrated in the outer enamel surfaces when applied after teeth erupt into the mouth. Dental plaque and saliva act as fluoride reservoirs to enhance the remineralization process.

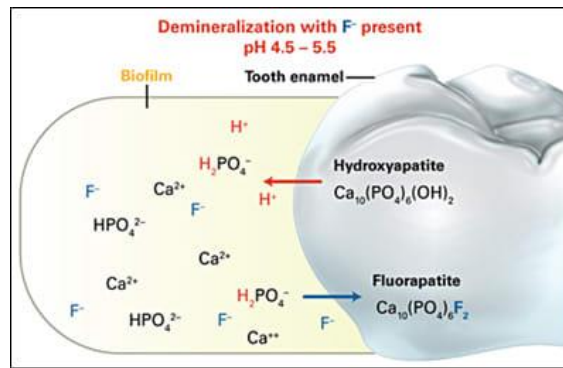
Mechanism of Action of Fluoride:

1- Inhibition of demineralization:

The mechanism is that it binds calcium and phosphate dissolving as a result of the acid penetration in to the dental tissue.

2- Enhancing remineralization:

The fluoride from topical sources enhances remineralization by speeding up the growth of a new surface on the partially demineralized subsurface crystals in the caries lesion, fluoride adsorb to the crystal surface and attract calcium ions followed by phosphate ions leading to new mineral formation.



3- Antimicrobial action:

Fluorides interfere with the decay-causing bacteria colonizing on teeth and reduce their acid production by reduce carbohydrate metabolism, thus slowing demineralization.

Fluoride Varnish:

Fluoride varnish has been found to be effective in preventing caries on permanent teeth. Fluoride varnish also has recently been shown to prevent or reduce caries in the primary teeth of young children.

How is the varnish applied?

Application is quick and easy: small droplets of varnish are applied directly to the tooth surface.

Glass ionomer cements:

Glass ionomer cements release fluoride by two mechanisms, which are the dissolution and diffusion. The large release of fluoride ion during the first few days after replacement declines rapidly during the first week and stabilizes after 2-3 month. Fluoride release normally takes place from the matrix into the adjacent environment but, in the presence of a high fluoride concentration in the month, fluoride ion can be taken up into the cement again. Glass ionomer materials, can therefore be regarded as a fluoride reservoir.

Their main characteristics are:

1. An ability to chemically bond to enamel and dentine with insignificant heat formation or shrinkage.

2. Biocompatibility with the pulp and periodontal tissues.
3. Fluoride release producing a cariostatic and antimicrobial action.
4. Less volumetric setting contraction; and a similar coefficient of thermal expansion to tooth structure.

These advantages have made them successful as luting cements and lining materials. However, as a restorative material, their sensitivity to moisture and low mechanical strength and wear resistance make them the least durable. This may be adequate for primary teeth because they will exfoliate in a number of years.

Resin-modified glass ionomer cements:

The fluoride release of the RMGICs would be affected by methacrylate-components and the polymerization systems. The contribution from the dissolution mechanism is, however very little because of the presence of the hydrophobic resin which will repel the water.

Their main characteristics are:

1. Resin-modified glass ionomer cements bond chemically to enamel and dentine with insignificant heat formation or shrinkage of material during the hardening reaction. So that the cement can firmly adhere to both enamel and dentine without signs of marginal leakage.
2. Shear bond strength of the resin-modified cement to dentine is significantly higher than that of conventional glass ionomer cement and the bond is a stable one.
3. Resin-modified glass ionomers have the advantage of being able to directly bond to resin composite, making them useful in glass ionomer/composite laminate restorations.
4. The resin modified glass ionomers are also highly biocompatible to the pulp and it has better adaptation and seal to the cavity preparation than conventional glass ionomer materials.

5. The final set structure shows a dramatic increase in compressive strength but is rather brittle and comparatively low in tensile strength and has low abrasion resistance making it unsuitable for high stress - bearing areas such as posterior teeth.

6. The fluoride release from and uptake by the resin-modified products was higher than or the same as that of conventional glass ionomers and has no adverse effect on the bond strength.

7. resin-modified glass ionomers have greater curing shrinkage than the conventional chemically-cured cements. Incremental placement techniques should always be used to ensure complete curing at depth and to minimize polymerization shrinkage.

Clinical use

Usually came as two-paste system . It has a longer working time. It sets sharply once the polymerization reaction is initiated by light. Most manufacturers state that immediate polishing can be carried out after light-curing. However, the setting reaction will continue slowly for at least 24 hours and the best result can be obtained if finishing is delayed. When immediate polishing is required, care must be taken not to overheat the restoration as this may cause excessive drying and cracking and may prevent setting of the ionomeric component. Highly desirable, alternative to amalgam for restoring primary teeth, and as a liner/base material.

Composite

In recent years, resin composite has been formulated to release fluoride. A slow release of small amount of fluoride from composite resin would be advantageous even more than periodic high concentration of fluoride applications.

Resin cements

It consists of a resin matrix with inorganic fillers that are bonded to the matrix with monomers. Polymerization of resin cement is achieved either by chemical reaction (self cure), light activation (light cure), or both (dual cure). The self cured composite cement are typically two pastes system (base and catalyst), while the light cure cement is a single component system. In some products fluoride is added to act as anti cariogenic factor, and reduce the resin cement sensitivities.

Polyacid-modified resin composites (compomers)

Recently, other resin-ionomer hybrid restoratives have been marketed as multipurpose materials or are resins that may release fluoride but have only limited glass ionomer properties. One such new material is the 'compomer' which contains the major ingredients of both composites (resin component) and glass ionomer cements (polyalkenoate acid and glass fillers component) except for water. The fluoride release from compomers has been demonstrate, more than composite but at lower level from that of GICs. Although low, the level of fluoride release has been reported to last at least 300 days.

Their main characteristics are:

1. It have two different mechanisms are responsible for the formation of adhesive bonds to the cavity wall. One of these is the self-adhesive property of the restorative itself, it can bond to both enamel and dentine without acid etching by carboxyl (-COOH) groups, the functional carboxyl groups can form ionic bonds with the calcium ions of the tooth surface. The second mechanism is adhesion to the tooth surface through the primer/adhesive system.
2. Can only be hardened through light-curing.
3. It has a significantly less bond strength to dentine than other resin-modified glass ionomer cements and chemically cured glass ionomer.

4. Often one component with an adhesive system.
5. Little is known about the clinical wear performance on the recently marketed compomer restorative materials.
6. Recently, studies have found that the release of fluoride by compomers was significantly less than resin modified glass ionomer cement more than other fluoride releasing resin composite. However, the antibacterial action decreased significantly over time. In addition, the caries inhibition effect of compomer restorative material was higher than the conventional type of resin composite.
7. Radiopacity of compomers is differing from that of dentine and it slightly higher than that of enamel. This value is considered to be desirable for radiographic detection of recurrent caries and offers an easy method for documentation of dental work.

Clinical use:

Ease of manipulation is another advantage of the compomer restoratives. Similar to resin composites, since the adhesive can provide sufficient bond strength for retention, no acid etching procedure is required prior to placement of the restorative. The consistency makes it easy to apply and contour without stickiness and, therefore, less time will be required for final finishing. These properties are especially beneficial in treating children because restorations usually can be completed much faster and within the tolerance of the child patient. A recent study has shown that curing shrinkage is similar to that of the conventional hybrid resin composites. Therefore, placement in increments of 3 mm or less is recommended for Dyract AP, 2 mm or less for other newer compomers, and then each to be cured for at least 40 seconds. Finishing can be undertaken immediately after curing using fluted tungsten carbide finishing burs or polishing discs.

They may or may not have the typical features of true glass ionomers such as chemical adhesion to tooth structures and long-term fluoride release.

Therefore, they should be used carefully, closely following the instructions of the manufacturers because different handling methods may influence their clinical behavior. It is used as liner/base, restoration, fissure sealant.

Amalgam

Fluoride containing amalgams have been shown to have anticaries properties that is sufficient to inhibit the development of caries in cavity walls. Studies have shown that the concentration of fluoride in the saliva by fluoriden releasing amalgams is sufficient to enhance remineralization. Therefore, fluoride releasing amalgam restorations may have a favourable effect on initial demineralization in the mouth. Restorative materials show an initial release that is significant. However, this release of fluoride decreases to minor amounts after 1 week.