

## Evaluation of Apical Transportation and Curve Straightening of Curved Root Canals after Preparation with Different Nickel - Titanium Rotary Systems (Comparative in Vitro Study)

Yasameen H. Motea <sup>(1)</sup>

### Key words

Rotary system, canal curvature, transportation, digital radiograph.

### Abstract

The goals of endodontic preparation were to shape and clean the space of the root canal and remove microorganisms, affected dentin and pulp, the apical foramen and the canal curve should be protected from being transported during endodontic canal preparation. The aim of this study was to evaluate the curve straightening of curved root canals and apical transportation after preparation with four rotary systems. Forty mesial roots of the lower 1st molars teeth only the mesiobuccal canals were used, these roots were immersed into cold clear acrylic, the teeth roots divided into four groups according to rotary system used for preparation of the canals (ten roots for each group):. group I: ProTaper Next rotary system, group II: IRaCe Plus rotary system, group III: HeroShaper rotary system, group IV: ProTaper rotary system, instrumentation were done to size 30 master apical file and with copious irrigation, total amount of 10 ml of 2.5% of sodium hypochlorite (NaOCl) then rinsed the canals with distilled water 5 ml. radiograph was taken for all roots before and after instrumentation in one direction buccolingual using digital radiograph system. The degree of curve straightening of the root canal and the apical transportation were measured using Image J software and Adobe photoshop CS6 software. Statistical analysis was done and the result showed that group IV had the highest mean values in curve straightening and apical transportation, there were significant difference between group IV and all of the other groups and there were non-significant difference between group I, group II and group . All the four used rotary systems produced adequate geometry during canal preparations. However, some apical transportation in ProTaper group was seen, which might need a caution when used protaper in instrumentation of curved canal.

### Introduction:

The effective endodontic treatment was depended mainly on thorough shaping and cleaning of the root canals <sup>(1,2)</sup>. A primary goal of shaping was to maintain the original direction and outline of the root canal. However, in curved canals this was

Baghdad. difficult because of all the techniques that used for canals preparation had tendency to divert the canal away from its axis and change the canal curvature <sup>(3)</sup>. Changing the curvature of the canal resulted in an more incidence of ledge, canal transportation, elbow formation, zip and stripping <sup>(3,4)</sup>. These difficulties in preparation of curved canals

(1)Assist. Lec., Department of Conservative Dentistry, College of Dentistry, University of

had prompted the manufacture of new instruments, preparation methods<sup>(5)</sup>. The the American Endodontists Association defined transportation as the canal wall structure removal on the outside curve in the apical half of the canal due to the files tendency to restore themselves during canal preparation to their original linear shape<sup>(6)</sup>.

The manufacturing of nickel-titanium (NiTi) rotary instrumentation had transformed the root canal treatment by reducing the errors associated with root canal preparation and the time needed to finish the preparation<sup>(7,8)</sup>. Different NiTi file systems had different features such as the taper, number of spirals or flutes, depth of flutes and cross sectional design. The system that were chosen had affected on the preparation of the root canal, particularly with curved canals<sup>(9)</sup>. Several methodologies were used to evaluate different NiTi instruments shaping ability, these methods including sectioning technique, simulated root canal model, radiographic comparison<sup>(10)</sup>, Double digital radiographic techniques<sup>(11)</sup> and micro-computed tomography<sup>(12,13)</sup>

The objective of this study would be to evaluate the amount apical transportation and the degree of curve straightening in curved root canals after preparation by four different nickel titanium rotary systems.

### Materials and method:

Forty extracted lower 1st molar were used in this study from the University of Baghdad, College of Dentistry clinics . The, pulpal status, gender and reason for extraction did not consider and the teeth selection were done according to the following criteria : the tooth had a curved mesial root (angles between 20° and 40°) with separated canals and separated apical foramina , mature , Patent apical foramen and there were no cracks, resorptions or fractures in the roots.

### Samples preparation:

The teeth kept in solution of distilled water and in the room temperature degree any calculus and soft tissue remnants on the root surface were removed with sharp curette. A light cure device and

magnifying eye lens used to verify the root surfaces for any visible cracks or fractures. The crown portion and the distal roots of all teeth removed at the cemento enamel junction level by the application of diamond disc bur in a straight high speed handpiece with water coolant. Only the mesiobuccal canals were used in this study. Barbed broach used to remove the pulpal tissue and established the working length (WL) with 15 K file, which was entered in each root canal until the tip of the file appeared from the apical foramen under %20 magnification. The length was established by subtracting 1 mm from the length measured when the tip of the file was first appeared from the foramen.

The roots were immersed in plastic mold that were filled with clear cold cure acrylic and to standardize the mounted roots position throughout the preparation procedure a bench vice was used.

For the purpose of standardizing the before and after preparation radiographs a radiographic platform was fabricated, it was prepared with the aid of a radiographic positioner for posterior teeth and a central carrier stand of wax block.

The teeth were then placed in the radiographic platform with special marks to ensure repositioning of the specimens and allowed successive digital radiograph image.

The resin blocks were fitted in the platform perfectly so the cone from the specimen and the specimen distance from the sensor were kept constant throughout the study.

Preinstrumentation digital radiograph were obtained in a buccolingual direction with the size 15 k-file (Dentsply/Maillefer, Switzerland) which introduced into the canal to its working length and exposure time (0.12 second) these radiographic image were used to measure the roots canal curvature before instrumentation by using the Image J Software and according to Schneider's method Figure 1.

In this method canal curvature was obtained by drawing a straight line along the root canal longitudinal axis in the coronal third and drawing second straight line from the root foramen to intersect with the first line in the area where the canal was began to drift from the tooth

long axis. This method was given the deflection angle between the intersecting lines.

#### **Instrumentation of the root canal:**

The roots were randomly divided into four groups (ten roots each) according to instrumentation systems used. All the mesiobuccal root canals prepared using crown-down technique. The canals instrumented up to their total working length. In all groups the preparations were performed with an electrical motor (X-Smart, Dentsply Maillefer,), a 16:1 reduction contra-angle handpiece, the speed and torque levels suggested by manufacturers for each instrument.

**Group I:** The canals in this group were prepared using ProTaper Next rotary system (Dentsply Maillefer/ Switzerland) with constant speed of rotation 300 rpm and lightly apical pressure, controlled torque endodontic motors were adjusted up to 5.2 Ncm according to manufacturer's instruction.

The Pro Taper Next files were used with a brushing Movement, away from external root canal concavities, to facilitate file progression apically and flute unloading. Pro Taper Next files followed the root canal until reaching the working length.

With NaOCl irrigation, follow and brush, along the canal glide path, first ProTaper Next X1 (017/04) file used until reached the working length then ProTaper Next X2 (025/06) was used exactly the same as ProTaper Next X1 file, until the length was passively reached, then the foramen was gauged with a hand file size 25 and if this file was snugged at length, the canal is shaped, disinfected and if size 25 file was loosed at working length, then continued preparing the canal with ProTaper Next X3file (30/07) then gauged the apical foramen with a hand file size 30/02, If the 30/02 file was snugged at working length, the shape was completed.

In this study group all the canals used which had apical foramen was still larger than size 25 and the hand file size 25/02 was loosed at working length and it could be pushed past length and all the canals finished to size ProTaper Next X3 (30/07).

#### **Group II:**

The canals in this group were prepared using IRaCe Plus rotary system (FKG Dentaire/ Switzerland) with constant speed of rotation 600 rpm and lightly apical pressure, a control torque endodontic motors were adjusted up to 1.5 Ncm according to manufacturer's instruction.

This system was used with curved canal with long back and forth gentle strokes, with NaOCl irrigation, the R1(15/06) was introduced in the canal until reached the working length if R1 did not reach the length then R1a (20/02) and R2b (25/02) were used up to length then continued shaping with R2(25/04) up to length and finished the preparation with R3(30/04).

#### **Group III:**

The canals in this group were prepared using HeroShaper (Micro Mega, France) rotary system with constant speed of rotation 600 rpm and lightly apical pressure, a control torque endodontic motors were adjusted up to 1.2 Ncm according to manufacturer's instruction.

The yellow sequences HeroShaper files were used with curved canal with short in and out movement using light pressure, with NaOCl irrigation the first yellow file with black rubber stopper (20/06) would be introduced to 2/3 of the length the second yellow file with gray rubber stopper (20/04) would be introduced to the full length then continued the preparation with red file (25/04) to full length and finished the preparation with blue file (30/04) to full length.

#### **Group IV:**

The canals in this group were prepared using ProTaper (Dentsply Maillefer/ Switzerland) rotary system with constant speed of rotation 350 rpm and lightly apical pressure, a control torque endodontic motors were adjusted from 1.5-3 Ncm according to manufacturer's instructions, with NaOCl irrigation the shaping file S1 and Sx introduced into coronal 2/3 of the canal then the shaping files S1, S2 used to full length, the shaping files were used with brushing movement to prepare the canal then the apical third were finished using the finishing file

F1(20/0.07) , F2 (25/0.08) and F3 (30/0.09) respectively with no brushing movement.

Irrigation with amount of 10 ml of 2.5 % of sodium hypochlorite NaOCl was used for all the root canals irrigation then rinsed with of distilled water 5 ml to prevent formation the crystals of NaOCl , then the root canals were dried with size 30 paper points.

#### **Assessment the degree of straightening of the root canals:**

After instrumentation, the master apical rotary files of each system size 30 were introduced into the canals to full length. By using radiographic platform, each tooth radiographed from the buccolingual view in the same position as in preinstrumentation radiographs and the postoperative angle of curvature was measured with the Image J Software and the same principle of the method of Schneider Figure 1, which previously prescribed.

The difference between the original degree of canal curvature and that after instrumentation gave the reduction in the degree of curvature of the canals after instrumentation .

The post instrumentation curvature degree was subtracted from the pre instrumentation curvature degree and these results represented degree of straightening.

#### **Assessment of apical root canals transportation:**

All the radiographic images were imported to Adobe Photoshop CS6 software to analyze the deviation of the original root canal path in apical third by superimposing the post instrumentation image onto its corresponding pre instrumentation image. Small translation and rotation movements used to produce a fit between the images until their external contours coincided and could not be differentiated, to calculate the apical transportation the the files tip was magnified to 100%. and the distance between size 15 file tip in preinstrumentation image and the final file size 30 tip in postinstrumentation image was measured in millimeter by using adobe photoshop CS6 after calibration of

the software to convert pixels into millimeter units and recorded at 1 mm short of the length and this would be represented of canal transportation Figure 2 .

#### **Results:**

This study showed the following results canals Table 1: for root canal curve straightening the highest and the lowest mean values were seen at group VI ProTaper rotary system (11.07 ) and group II IRaCe plus rotary system (6.90) respectively, for apical transportation of the canals the highest mean values were seen at group VI ProTaper rotary system (0.74) and the lowest mean values were seen at group II IRaCe plus rotary system (0.44) The rest mean values for the other groups were fluctuating between these values.

ANOVA test and the least significance difference test (LSD) were used to compare between the four rotary systems and to evaluate the significant differences between each of the two rotary systems for the amount of apical transportation and the degree curve straightening of curved canals. The results showed the following for curve straightening of the root canals Table. 2:

1. There were non -significant difference ( $p \geq .05$ ) between group I ProTaper Next , group II IRaCe plus and group III HeroShaper .
2. There were significant difference ( $p \leq .05$ ) between group IV (ProTaper) and group I (ProTaper Next ) , group II (IRaCe plus) , group III ( HeroShaper).

The results showed the following for the amount of apical canal transportation Table. 2:

1. There were non- significant difference ( $p \geq .05$ ) between group I (ProTaper Next ) , group II (IRaCe plus) and group III ( HeroShaper).
2. There were significant difference ( $p \leq .05$ ) between group IV (ProTaper) and group I (ProTaper Next ) .
3. There were highly significant difference ( $p \leq 0.00$ ) between group IV (ProTaper) and group II (IRaCe plus), group III ( HeroShaper).

## Discussion

Forty extracted, human molars teeth selected for this study. Although complex anatomy of the root and dentin structure variability of extracted human teeth affected the standardization of experimental groups, teeth provided conditions the same as the clinical situation. Resin blocks simulated canals were used to standardize conditions<sup>(14)</sup>. Bertrand et al. demonstrated that the use of resin blocks might not represent clinical conditions because it did not reflect dentinal structure and rigidity<sup>(15)</sup>. Resin block was not ideal for rotary files studying due to variation in structures between dentin and resin<sup>(16)</sup>, the heat generated might soften the resin so that instrument's blade and might bind or break<sup>(17)</sup>. The canal transportation of endodontic rotary instruments had become an interest subject in the literature of endodontic. Many reports on preserving original root canal curvature had focused on instrument design or composition<sup>(18)</sup>.

When the curved root canals were shaped, it was necessary to protect the curve of canal and avoid flattening that might affect the canal integrity, especially in the internal part of the curve<sup>(19)</sup> and at the apex<sup>(2)</sup>. When a Ni-Ti file prepare a curved canal, it had the ability to recover its original shape because of the property of pseudoelasticity. This situation caused decrease in the angle curvature<sup>(20)</sup>.

Several techniques used to evaluate the shaping ability of NiTi instruments, such as radiographic technique, sectioning technique and micro-computed tomography (micro-CT). Each one of these methods had distinct disadvantages and advantages. For example, the sectioning technique was invasive and restricted to previously determined levels<sup>(21)</sup> and results in unknown changes in tissue and material loss<sup>(22)</sup>. Micro-CT was not cost effective. The radiographic technique which used in this study was noninvasive, easy to use, inexpensive and potentially informative but only used to record two-dimensional changes<sup>(23)</sup>. This method measured the transportation projection and not the real transportation, because teeth did not always display their

maximum curvatures in the buccolingual or mesiodistal planes. From the results of the present study group IV( ProTaper rotary system) caused straightening in canal curvature and produced more apical transportation than other groups these results might be attributed to The features a Protaper System such as progressive taper along its shank and that might be related to the larger diameter of F3, this file had an apical taper of 0.09, which was much larger for the apical diameter when compared with some of the other used groups. The larger taper of the F3 instrument increased the tip stiffness, which resulted in transportation<sup>(24)</sup>. The common way to increase flexibility of the file was to decrease the file metal mass by increasing the number of flutes or spirals per unit length; increasing the depth of the flutes and decreasing the core diameter of the file, taper or size<sup>(25)</sup>. Thus, an increase in the taper was directly related to the cross-sectional area increased and decreased flexibility<sup>(26)</sup>. The increase in the taper cause reduction in instrument flexibility, the size of the taper was considering a key factor in root canal apical transportation<sup>(25)</sup>. Other reasons that ProTaper caused apical transportation more than other file system used in this study might be related to the ProTaper did not have radial lands, this was other cause of apical transportation because radial land kept the file centered in the root canal and prevented transportation straightening of the canal curve<sup>(27)</sup>. Other rotary systems used in this study showed less canal transportation and adequacy regarding maintenance of canal curvature these results might be related to special design features that each of these systems had, for example ProTaper Next rotary system was manufactured from M wire and not nickel titanium alloy. These added metallurgical benefit allowed for more flexible instruments<sup>(28)</sup>. According to the manufacturer description HeroShaper files had triple helix cross section allowed a positive cutting. The tip was non cutting tip that innovated to follow the canal anatomy and had radial land that kept the file centered in canal so reduced apical transportation<sup>(29)</sup>. IRaCe rotary system had many features that were important in

reducing apical transportation such as exclusive Safety rounded tip for perfect guidance and perfect centering the instrument in the canal, in addition to the basic sequence the IRaCe plus system had two highly flexible instruments (with taper of 0 .02) allowed treatment of more difficult cases (narrow, highly curved and calcified canals). IRaCe had triangular cross-section with sharp

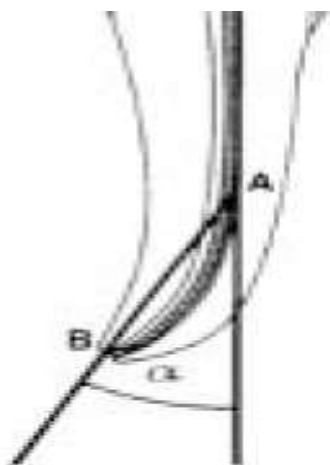


Fig.(1): Determination angle of curvature ( $\alpha$ ) by Schneider method.

Table (1): Mean value & standard deviation of curve straightening & apical transportation of root canals in four rotary systems groups.

Studied groups	N	curve straightening		apical transportation	
		Mean	$\pm$ SD	Mean	$\pm$ SD
ProTaper Next	10	7.17	4.21	0.56	0.13
IRaCe plus	10	6.90	1.50	0.44	0.17
HeroShaper	10	7.00	2.68	0.46	0.11
ProTaper	10	11.07	6.32	0.74	0.28

### Conclusion:

This study demonstrated that all the four used preparation systems produced adequate geometry after canal preparations. However, some canal transportation in ProTaper group was evident, which might need a caution that apical use of larger and greater taper instrument should be carefully considered in curved canals.

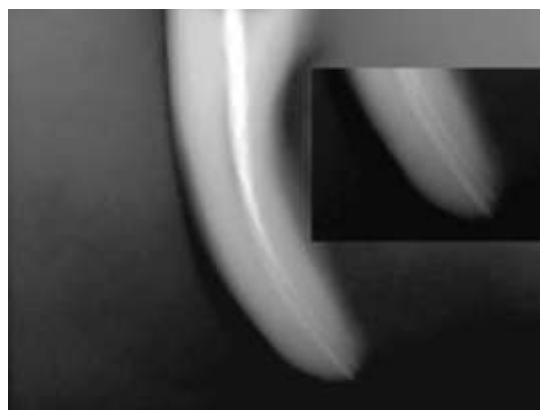


Fig.(2): Determination apical transportation.

Table (2) :The Least Significance Difference test (LSD) of curve straightening & apical transportation of root canals between the four rotary systems.

Studied groups		(LSD test) curve straightening		(LSD test) Apical transportation	
		p-value	Sig.	p-value	Sig.
ProTaper Next	IRaCe plus	0.88	N.S	0.15	N.S
	Hero Shaper	0.93	N.S	0.21	N.S
	ProTaper	0.04	S	0.04	S
IRaCe plus	Hero Shaper	0.96	N.S	0.84	N.S
	ProTaper	0.03	S	0.00	H.S
Hero Shaper	ProTaper	0.03	S	0.00	H.S

\*S =significant \*N.S= non significant, \*H.S=highly significant

## References:

- 1- Weine FS. The use of non ISO-tapered instruments for canal flaring. *Compend Dent Educ* 1996;17:651-7.
- 2- Gulabivala K, Patel B, Evans G, Ng YL. Effects of mechanical and chemical procedures on root canal surfaces. *Endod Topics* 2005;10:103–22.
- 3- Abou-Rass M, Frank L, Glick H. The anti-curvature filing method to prepare the curved root canal. *J Am Dent Assoc* 1980;101:792–4.
- 4-Weine FS, Kelly RF, Lio PJ. The effect of preparation procedures on original canal shape and on apical foramen shape. *J Endod* 1975;1:255–62.
- 5- Hankins, P. J. & ElDeeb, M. E. An evaluation of the Canal Master, balanced force, and step-back techniques. *J. Endod.*, 22(3):123- 30, 1996.
- 6- American Association of Endodontists. *Glossary of Endodontic Terms*. 7th ed. Chicago: AAE; 2003.
- 7- Short A, Morgan A, Baumgartner C. A comparison of canal centering ability of four instrumentation techniques. *J Endod* 1997;23:503–7.
- 8- Park H. A comparison of greater taper files, Profiles, and stainless steel files to shape curved root canals. *Oral Surg Oral Med Oral Pathol Oral Radiol* 2001; 9:715–8.
- 9- Fernando Duran-Sindreu, Marc Garc\_ia, Juan Gonzalo Olivieri, Montse Mercad\_e, Sergio Morell, Miguel Roig,, A Comparison of Apical Transportation between FlexMaster and protaper. 2009;9:315–10.
- 10- Barthel CR, Gruber S, Roulet JF. A new method to assess the results of instrumentation techniques in the root canal. *J Endod* 1999;25:535–8.
- 11- Garc\_ia M, Duran-Sindreu F, Mercad\_e M, et al. A comparison of apical transportation between profile and RaCe rotary instruments. *J Endod* 2012; 38:990–2.
- 12- Gergi R, Rjeily JA, Sader J, Naaman A. Comparison of canal transportation and centering ability of twisted files, Pathfile-ProTaper system, and stainless steel hand K-files by using computed tomography. *J Endod* 2010;36:904–7.
- 13- Yamamura B, Cox TC, Heddaya B, et al. Comparing canal transportation and centering ability of endosequence and vortex rotary files by using microcomputed tomography. *J Endod* 2012;38:1121–5.
- 14- Dummer PM, Alodeh MH, al-Omari MA. A method for the construction of simulated root canals in clear resin blocks. *Int Endod J*. 1991;24(2):63-6.
- 15- Bertrand MF, Lupi-Pegurier L, Medioni E, Muller M, Bolla M. Curved molar root canal preparations using Hero 642 rotary nickel-titanium instruments. *Int Endod J*.2001;34(8):631-6.
- 16-Thompson SA, Dummer PM. Shaping ability of ProFile.04 Taper Series 29 rotary nickel-titanium instruments in simulated root canals. Part 1. *Int Endod J*. 1997;30(1):1-7.
- 17- Thompson SA, Dummer PM. Shaping ability of Lightspeed rotary nickel-titanium instruments in simulated root canals. Part 1. *J Endod*. 1997;23(11):698-702.
- 18- Peters OA, Paque F. Root canal preparation of maxillary molars with the selfadjusting file: a micro-computed tomography study. *J Endod* 2011;37:53–7.
- 19-Abou-Rass M, Frank AL, Glick DH: The anticurvature filing method to prepare the curved root canal. *J Am Dent Assoc*, 1980; 101: 792-794.



- 20- Schäfer E, Erler M, Dammaschke T. Comparative study on the shaping ability and cleaning efficiency of rotary Mtwo instruments: part 1—shaping ability in simulated curved canals. *Int Endod J* 2006;39:196–202.
- 21- Rhodes JS, Ford TR, Lynch JA, Liepins PJ, Curtis RV. Micro-computed tomography: a new tool for experimental endodontology. *Int Endod J*. 1999;32(3):165-70.
- 22- Gambill JM, Alder M, del Rio CE. Comparison of nickel-titanium and stainless steel hand-file instrumentation using computed tomography. *J Endod*. 1996;22(7):369-75.
- 23- Dowker SE, Davis GR, Elliott JC. X-ray microtomography: nondestructive three-dimensional imaging for in vitro endodontic studies. *Oral Surg Oral Med Oral Pathol Oral Radiol Endod*. 1997;83(4):510-6.
- 24- Dobó-Nagy C, Serbán T, Szabó J, et al. A comparison of the shaping characteristics of two nickel-titanium endodontic hand instruments. *Int Endod J* 2002;35: 283–8.
- 25- McSpadden JT. *Mastering Endodontic Instrumentation*. Chattanooga, TN: Cloudland Institute; 2007.
- 26- Javaheri HH, Javaheri GH. A comparison of three Ni-Ti rotary instruments in apical transportation. *J Endod* 2007;33:284–6.
- 27- Zarana S, Kunjal M. Design feature of rotary instruments endodontics. *The Journal of Ahmedabad Dental College and Hospital* 2011; 2(1):6-11
- 28- Gutmann JL, Gao Y (2012) Alteration in the inherent metallic and surface properties of nickel titanium root canal instruments to enhance performance, durability and safety: a focused review. *Int Endod J* 45:113-128
- 29- Mohamed AS, Mohamed M, Abd El-Azeem . Comparative study of the efficiency newly introduced rotary nickel titanium instruments in shaping of curved canal. *Cairo Dental Journal* 2008; (3), 447:456
- 30- Saber SE<sup>1</sup>, Nagy MM, Schäfer E. Comparative evaluation of the shaping ability of ProTaper Next, iRaCe and Hyflex CM rotary NiTi files in severely curved root canals. *Int Endod J*. 2015 Feb;48(2):131-6.